



HAL
open science

Management of a superinfected pyoderma gangrenosum after pacemaker implant

Halim Marzak, Jean-Jacques von Hunolstein, Dan Lipsker, Michel Chauvin,
Olivier Morel, Laurence Jesel

► **To cite this version:**

Halim Marzak, Jean-Jacques von Hunolstein, Dan Lipsker, Michel Chauvin, Olivier Morel, et al..
Management of a superinfected pyoderma gangrenosum after pacemaker implant. HeartRhythm Case
Reports, 2019, 5 (2), pp.63 - 65. 10.1016/j.hrccr.2017.12.006 . hal-03890470

HAL Id: hal-03890470

<https://hal.science/hal-03890470>

Submitted on 8 Dec 2022

HAL is a multi-disciplinary open access archive for the deposit and dissemination of scientific research documents, whether they are published or not. The documents may come from teaching and research institutions in France or abroad, or from public or private research centers.

L'archive ouverte pluridisciplinaire **HAL**, est destinée au dépôt et à la diffusion de documents scientifiques de niveau recherche, publiés ou non, émanant des établissements d'enseignement et de recherche français ou étrangers, des laboratoires publics ou privés.

Management of a superinfected pyoderma gangrenosum after pacemaker implant



Halim Marzak, MD,* Jean-Jacques Von Hunolstein, MD,* Dan Lipsker, MD, PhD,[†]
Michel Chauvin, MD, PhD,* Olivier Morel, MD, PhD,* Laurence Jesel, MD*

From the *Université de Strasbourg, Service de Cardiologie, Nouvel Hôpital Civil, Strasbourg, France, and
[†]Université de Strasbourg and Clinique Dermatologique, Hôpital Civil, Strasbourg, France.

Introduction

Pyoderma gangrenosum (PG) is a rare inflammatory neutrophilic dermatosis. We report a case of PG triggered by pacemaker (PM) implant. In the field of cardiac devices, physicians should think about this rare diagnosis in all rapidly expanding postoperative lesions. The delayed diagnosis can lead to serious consequences. Device reimplantation is possible with the help of adequate immunosuppressive therapies.

Case report

A 72-year-old man without medical history underwent a dual-chamber PM implant in the left prepectoral area for 2:1 atrioventricular block. Immediate course was uneventful and he was discharged the following day. At day 4, he consulted for an inflammatory, infiltrating, and necrotic lesion in the implant area. In the same time, he developed fever (38.1°C), and biological inflammatory syndrome with negative blood cultures and antibiotics (amoxicillin / clavulanic acid, 1 g 3 times/day) were started. An infectious lesion was suspected. A swab of the lesion came back positive after culture for *Staphylococcus epidermidis*. At day 7, the inflammatory area became darker despite antibiotics. Blood cultures were still negative. Dermatologists diagnosed PG (Figure 1) and systemic corticosteroids (1 mg/kg) were started. Antibiotics were continued for 3 weeks to prevent secondary infection and systemic corticosteroids were tapered down. At day 20, PG-specific lesions decreased under corticoids. Local healing was favorable with regression of necrotic aspect (Figure 2).

At day 45, the patient developed septic shock. The area of PM evidenced a disunited scar with pus whereas PG-specific

necrotic lesions had disappeared completely. Blood cultures were positive for *S aureus* and antibiotics were started again. PM and leads were explanted after vegetations were excluded by transesophageal echocardiography. Thereafter the patient developed a new PG lesion on the left arm at a peripherally inserted central catheter (PICC) line insertion for antibiotics administration (Figure 3A). Corticosteroids were increased and colchicine (1 mg/day), an antineutrophilic therapy, was started. Local skin state and biological evolution were favorable after 1 month treatment. At telemetric monitoring, 2:1 atrioventricular block motivated the discussion for a new PM implantation. A single-chamber leadless PM limiting tissue cut and damage was excluded because of a PM syndrome risk. An epicardial PM was not recommended after discussion with dermatologists because of possible involvement of deep tissue lesions in PG recurrence. Finally an endovascular dual-chamber PM was decided. To limit PG recurrence, a first intravenous injection of anti-TNF-alpha antibody (infliximab at 5 mg/kg) was administered and colchicine (1 mg/day), corticoids (1 mg/kg), and antibiotics were continued. Five days after infliximab was given, a right-side dual-chamber PM was successfully reimplanted. The skin of the scar area was clean with no inflammatory syndrome, allowing patient discharge 4 days after implantation. A second anti-TNF-alpha antibody injection (5 mg/kg) was administered 15 days after the first one. Antibiotics were stopped after 2 weeks, corticosteroids were gradually decreased to 0.5 mg/kg, and colchicine was continued for a few months. At 2-month follow-up after PM implant, the skin lesion was cured but still open (Figure 3B). It had been sutured easily 1 month later by the plastic surgeon. One-year follow-up was uneventful. At the same time, the PM area remained clean without any inflammatory syndrome.

KEYWORDS Anti-TNF antibody; Corticosteroid; Neutrophilic dermatosis; Pacemaker implant; Pyoderma gangrenosum
(Heart Rhythm Case Reports 2019;5:63–65)

Address reprint requests and correspondence: Dr Halim Marzak, Pôle d'activité medico-chirurgicale cardio-vasculaire, Nouvel Hôpital Civil, 1, place de l'Hôpital, F-67091 Strasbourg cedex, France. E-mail address: halim.marzak@chru-strasbourg.fr.

Discussion

PG is a rare inflammatory neutrophilic dermatosis manifesting as painful ulcers, violaceous necrotic lesions, and sterile infiltration of polynuclear neutrophils in the skin.¹ PG can be idiopathic but is often associated with inflammatory bowel diseases,² hematologic malignancies, and rheumatologic

KEY TEACHING POINTS

- In the field of cardiac device implantation, physicians should think about the rare diagnosis of pyoderma gangrenosum in all rapidly expanding postoperative lesions. A delayed diagnosis can lead to serious consequences. Early diagnosis helps to start early corticosteroid treatment onset.
- Pyoderma gangrenosum can be idiopathic but is often associated with inflammatory bowel diseases, hematologic malignancies, and rheumatologic disorders. Further investigations should be done to diagnose associated pathologies.
- The diagnosis of pyoderma gangrenosum is clinical. The main differential diagnosis remains infectious lesions. Cutaneous biopsy is not mandatory and only allows to exclude other pathologies such as infection, vasculitis, and malignancy. Collaboration with dermatologists is crucial.
- In case of pyoderma gangrenosum after device implantation, careful reimplantation is possible with the help of adequate associated treatment therapies, usually involving steroids, colchicine, dapsone, cyclosporine, or TNF-blocking agents.

disorders. We report the case of a patient presenting PG at the site of PM implantation and of PICC line insertion, a phenomenon referred to as pathergy, which is very characteristic of PG. The patient had no medical history and no bowel or hematologic disease. During follow-up, no other associated pathology could be evidenced. Although the diagnosis was rapidly made with the help of dermatologists, and corticosteroids were rapidly introduced with favorable effect on PG lesion, a secondary infection occurred.

The diagnosis of PG is often delayed, after antibiotic treatment fails. The diagnosis of PG should be evoked in any unusual necrotic ulcer despite optimal care. An early diagnosis will help to start early management and corticosteroid therapy onset to limit extension and minimize sequelae. This diagnosis is usually clinical. A cutaneous biopsy is not mandatory and helps only to exclude other pathologies such as vasculitis, infection, and malignancy.

Finally, in our case report the combination of systemic corticosteroids, colchicine, and anti-TNF therapy allowed a new PM implantation without recurrence of PG.

Treatment is always challenging in PG. Although a small trial has been published in favor of infliximab (46% [6/13 patients]) compared with placebo (6% [1/17 patients]; $P = .025$), no randomized controlled trials have been performed to evaluate other therapies.^{3,4}

Oral systemic corticosteroid (0.5–2 mg/kg/day) is considered as the first therapeutic option. In case of aggressive and

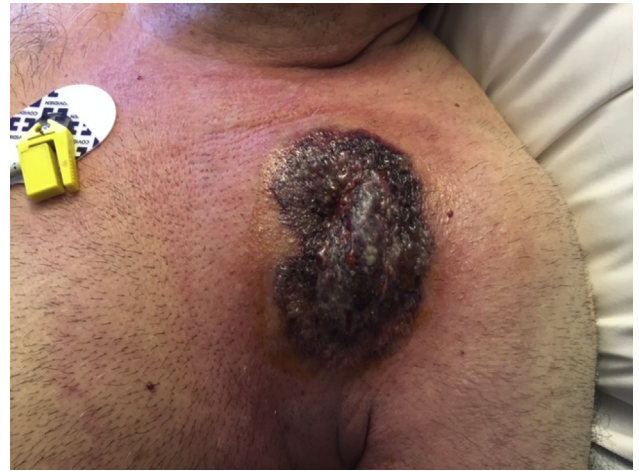

Figure 1 Pyoderma gangrenosum–specific initial lesion at day 7 after pacemaker implant.

resistant forms, other immunosuppressive drugs such as cyclosporine or TNF-blocking agents can be used in combination with systemic corticosteroids. No local treatment is considered effective in PG. Only cleaning with physiological serum and hydrocolloid bandage are recommended in local treatment of PG.

In the field of cardiac device implantation, physicians should think about this rare diagnosis in all rapidly expanding postoperative lesions; postsurgery PG is already a classic entity. The delayed diagnosis can lead to serious consequences, as this initially sterile polynuclear infiltration lesion can later get infected. If the pathophysiological mechanisms are still not clearly elucidated, neutrophilic dermatoses can be assigned to autoinflammatory diseases with abnormal activation of innate immunity. In case of PG after PM implant, careful device reimplantation is possible with the help of adequate associated treatment therapies, usually involving steroids, colchicine, dapsone, cyclosporine, or TNF-blocking agents.

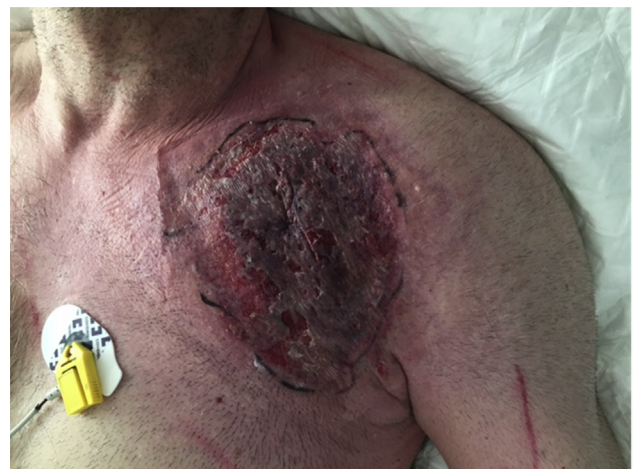

Figure 2 Pyoderma gangrenosum lesion with start of regression of necrotic lesions at day 20 after pacemaker implant.

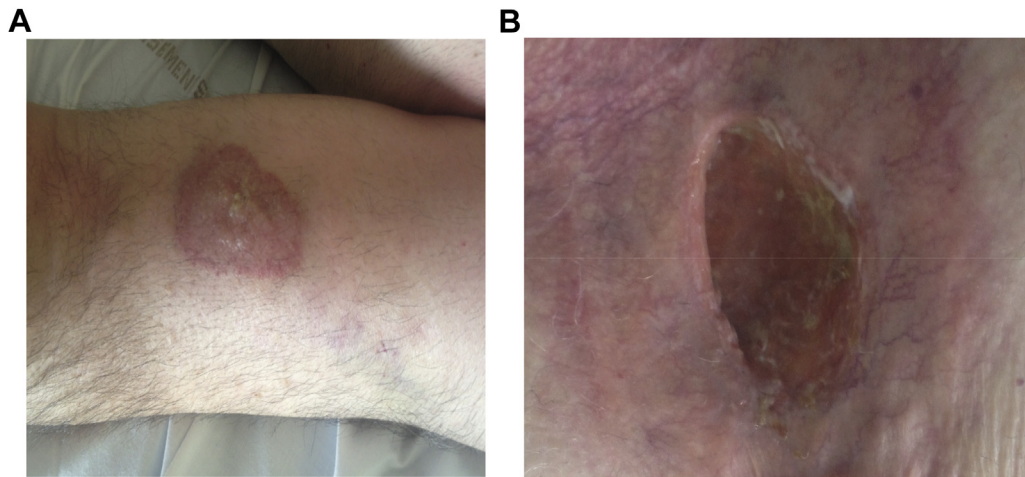


Figure 3 **A:** The patient developed a new pyoderma gangrenosum lesion on the left arm at a peripherally inserted central catheter line insertion. **B:** At 2-month follow-up after pacemaker implant, the skin lesion was cured but still open.

References

1. Marzano AV, Borghi A, Meroni PL, Cugno M. Pyoderma gangrenosum and its syndromic forms: evidence for a link with autoinflammation. *Br J Dermatol* 2016;175:882–891.
2. Selvapatt N, Barry J, Roberts PR. Pyoderma gangrenosum complicating an implantable cardioverter defibrillator wound in a patient with ulcerative colitis. *Europace* 2009;11:1482.
3. Craig FF, Thomas KS, Mitchell EJ, et al. UK Dermatology Clinical Trials Network's STOP GAP trial (a multicentre trial of prednisolone versus ciclosporin for pyoderma gangrenosum): protocol for a randomised controlled trial. *Trials* 2012;28:51.
4. Brooklyn TN, Dunnill MG, Shetty A, et al. Infliximab for the treatment of pyoderma gangrenosum: a randomised, double blind, placebo controlled trial. *Gut* 2006;55:505–509.