



HAL
open science

Second-degree burn induced by high-concentration topical capsaicin with mobility sequelae: a case report

Kilian Trin, Justine Perino, Marion Allouchery, Helene Geniaux, Ghada Miremont, Francesco Salvo

► To cite this version:

Kilian Trin, Justine Perino, Marion Allouchery, Helene Geniaux, Ghada Miremont, et al.. Second-degree burn induced by high-concentration topical capsaicin with mobility sequelae: a case report. Pain Practice, In press, 23 (2), pp.216-219. 10.1111/papr.13175 . hal-03887809

HAL Id: hal-03887809

<https://hal.science/hal-03887809v1>

Submitted on 7 Dec 2022

HAL is a multi-disciplinary open access archive for the deposit and dissemination of scientific research documents, whether they are published or not. The documents may come from teaching and research institutions in France or abroad, or from public or private research centers.



L'archive ouverte pluridisciplinaire **HAL**, est destinée au dépôt et à la diffusion de documents scientifiques de niveau recherche, publiés ou non, émanant des établissements d'enseignement et de recherche français ou étrangers, des laboratoires publics ou privés.



Distributed under a Creative Commons Attribution - NonCommercial - NoDerivatives 4.0 International License

CASE REPORT

Second-degree burn induced by high-concentration topical capsaicin with mobility sequelae: A case report

Kilian Trin MD^{1,2}  | Justine Perino PharmD^{1,3} | Marion Allouchery PharmD, PhD^{3,4,5} |
Hélène Géniaux PharmD⁶ | Ghada Miremont MD¹ | Francesco Salvo MD, PhD^{1,3} 

¹Service de Pharmacologie Médicale, Centre Régional de Pharmacovigilance de Bordeaux, CHU de Bordeaux, Bordeaux, France

²Univ. Bordeaux, Bordeaux, France

³Inserm, Bordeaux Population Health Research Center, Team Pharmacoepidemiology, UMR 1219, Univ. Bordeaux, Bordeaux Cedex, France

⁴Service de Pharmacologie Clinique et Vigilances, CHU de Poitiers, Poitiers, France

⁵Faculté de Médecine, Université de Poitiers, Poitiers, France

⁶Service de Pharmacologie, Toxicologie et Pharmacovigilance, CHU de Limoges, Limoges, France

Correspondence

Francesco Salvo, Inserm, Bordeaux Population Health Research Center, Team Pharmacoepidemiology, UMR 1219, Univ. Bordeaux, 33076 Bordeaux Cedex, France.
Email: francesco.salvo@u-bordeaux.fr

Abstract

High-concentration topical capsaicin is used as a second-line treatment for neuropathic pain. Transient, mild burning sensation and erythema are expected adverse drug reactions. Here, we report the first case of second degree burn after the application of a high-concentration topical capsaicin patch with secondary mobility sequelae. Nine months after the application, neuropathic pain still remained and the patient described mobility difficulties in daily activities, preventing her from returning to work. This report aims to raise the question of the benefit/risk ratio of high concentration topical capsaicin.

KEYWORDS

adverse drug reaction, capsaicin, neuropathic pain, pharmacovigilance, sequelae

INTRODUCTION

According to the International Association for the Study of Pain (IASP), peripheral neuropathic pain is caused by a lesion or disease of the peripheral somatosensory nervous system and is more frequent in women and in people over 60.^{1,2} Oral treatments such as tricyclic antidepressants and serotonin-norepinephrine reuptake inhibitors are classically used as first-line treatments for central or peripheral neuropathic pain.³ Lidocaine plasters can also be used as a first-line treatment for focal peripheral neuropathic pain.

Capsaicin is a chemical compound, extracted from chillies, responsible for the burning sensation in the mouth when eating spicy food. Its local anesthetic and analgesic properties are due to its agonist action on

Transient Receptor Potential Vanilloid type 1 (TRPV1) located in the small-diameter sensory neurons in the skin, mucous membranes and central nervous system.⁴ Capsaicin reversibly activates cutaneous nociceptors expressing TRPV1 receptors, leading to a release of vasoactive neuropeptides. This can trigger firstly pain and erythema at the application site; thereafter, capsaicin causes desensitization of skin nociceptors to various stimuli, and thus relieves pain.

Capsaicin is classically used at low concentrations (<1%) as an active ingredient in topical medications for several indications, such as arthritis, post-herpetic pain or diabetic neuropathy.⁵ In 2009, a 14 × 20 cm skin patch containing a high-concentration (8%) of capsaicin (Qutenza®) received a European market authorization for the management of peripheral neuropathic pain in

This is an open access article under the terms of the [Creative Commons Attribution-NonCommercial-NoDerivs](https://creativecommons.org/licenses/by-nc-nd/4.0/) License, which permits use and distribution in any medium, provided the original work is properly cited, the use is non-commercial and no modifications or adaptations are made.

© 2022 The Authors. *Pain Practice* published by Wiley Periodicals LLC on behalf of World Institute of Pain.

adults, alone or in combination with other drugs. This patch was also approved the same year by the Food and Drug Administration (FDA) for the treatment of neuropathic pain associated with postherpetic neuralgia. It is also approved since 2020 by the FDA for neuropathic pain associated with diabetic peripheral neuropathy of the feet. It must be used by a physician or by trained healthcare professionals under the supervision of a physician, only in a hospital setting.

High-concentration topical capsaicin in humans showed a good safety profile because of poor systemic exposure through rapid elimination from circulation.⁶ The most part of its adverse drug reactions are mild and transient application site disorders, usually preventable with local cooling, topical anesthetic or systemic analgesics.⁷ More severe application site disorders such as second-degree burns could occur, but their clinical presentation is not precisely described and their frequency remains unknown.

Here we report the case of a 41-year-old woman who experienced a second-degree burn on the leg leading to mobility sequelae after the first application of a high-concentration capsaicin patch.

DESCRIPTION OF THE CASE

A 41-year-old woman underwent surgery for the management of a cyst, located on the posterior part of the proximal fibula-tibial joint, suspected of causing left knee

pain. Removal of the cyst did not provide pain relief and was followed by multiple surgeries, such as neurolysis of the fibular and the external popliteal sciatic nerves, an osteotomy of the neck of the fibula and a left superior tibio-fibular arthrodesis. Facing absence of results and even pain worsening with extension to the entire leg, neuropathic pain has been diagnosed. Non-steroidal anti-inflammatory drugs (NSAIDs) and physiotherapy were prescribed as first-line treatments. Then, because the patient experienced adverse drug reactions related to NSAIDs use (digestive pain, malaise and dizziness), and a poor efficacy of the treatment, skin patch containing high-concentration of capsaicin was initiated.

During her day-hospital admission, a patch of high-concentration topical capsaicin was applied for 60 min, as recommended. Firstly, burning sensation was experienced by the patient when the patch was applied, then a large erythema appeared when the patch was removed. The nurse applied cold to the erythema zone and the patient remained under surveillance for approximately 2 h. No preventive medication was used before or during the patch use. The patient continued local cooling at home. The burning pain gradually increased throughout the day and the patient estimated it at 10/10 using a visual analogue scale. During the following night, the skin redness rapidly evolved towards very painful blisters at the front of the leg. The morning after, she was admitted at the emergency unit. The skin burn corresponded precisely to the area where the patch was applied, with the largest blister measured at 7 cm of diameter (Figure 1, panel A).

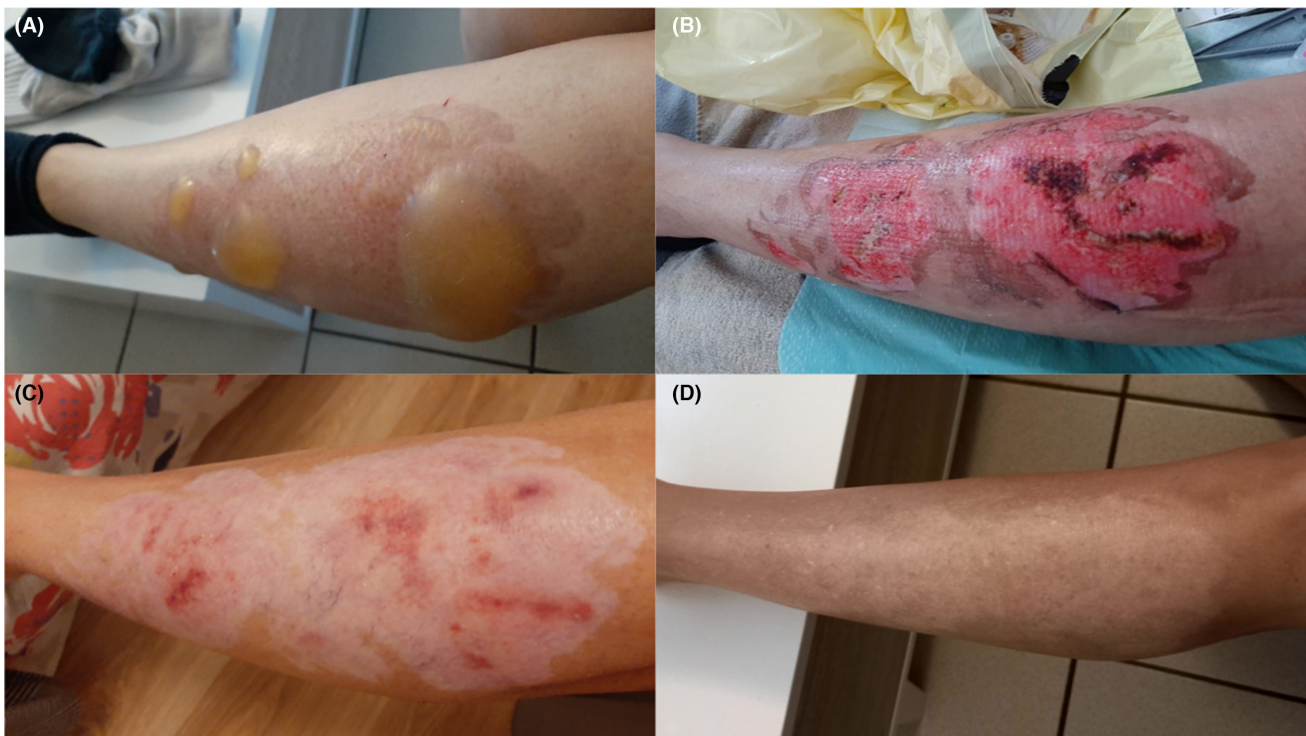


FIGURE 1 The burn area at different follow-up times after the patch application. Panel A: Day 1. Panel B: Week 1. Panel C: Month 3. Panel D: Month 9.

Due to the presence of tense blisters, a diagnosis of a superficial second-degree burn was made. For 2 months, a nurse came every 2–3 days to the patient's home to clean the wound and change the dressings, after which the patient took care of her wound herself.

At 1 week, a large wound was observed (Figure 1, panel B), while she experienced new difficulties in walking, pain and paresthesia from the third week. Subsequently, a corticosteroid-based cream was prescribed by the dermatologists and led to a progressive healing of the wound (Figure 1, panel C,D).

At nine months, neuropathic pain still remained with difficulties in daily activities and the need to use a cane when she stands. Since the use of the patch, she still has not been able to return to her job as a childminder.

Her current pain treatment consists solely of paracetamol on demand, with limited effectiveness.

DISCUSSION

Literature is very scarce about the risk of burn after capsaicin patch application. A case of a third-degree burn induced by high concentration topical capsaicin in a 57-year-old man has been already detailed.⁸ In this case, the fourth application of the patch on the left hip has led rapidly to a second-degree burn, and necrosis 2 days after. Seven months later, no functional impairment or sequelae, apart from aesthetics, have been reported. One “application site burn” has been also reported in a randomized clinical trial, but not further described.⁹ The summary of product characteristics raises the possibility of second-degree burns, but its frequency remains unknown. An analysis of VigiBase, the WHO global database of individual case safety reports, made on 15 March 2022, showed 45 cases of second-degree burns (3.2% of the overall reported adverse events) and two cases of third degree burns (0.1%) related to high concentration topical capsaicin.¹⁰ These cases are reported more frequently in women (78.3%). All age groups are concerned, with significant proportions of patients aged 18–44 years (26.1%) (age was missing in 37% of reports). Since 2017, the number of reported second-degree burns is increasing, with 3 cases reported per year in 2016 and 2017, 6–8 cases reported per year between 2018 and 2020 and 12 cases in 2021. Most of the reported second-degree burns were from France (75.6%); this could be due to a wider use of this treatment compared with other countries, but no data are available in this regard.

In the case we report, the responsibility of the capsaicin patch is strongly established since the occurrence of the burn is consistent with its pharmacological properties. Moreover it appeared shortly after application and strictly in the zone of the patch application site. Concerning mobility sequelae, a role of the burns cannot be excluded, but it could also be due to the natural evolution of her neurological disorders.

High-concentration topical capsaicin is reserved for hospital use. Its conditions of use are quite complex: patient needs to stay in a well-ventilated room, and the administration has to be complied by a trained team equipped with protective glasses, masks and nitrile gloves. Accidental exposure can lead to transient erythema and burning sensation (mucous membranes being particularly sensitive), eye pain, eye and throat irritation and coughing. However, no recommendations are available for the protection of the patient during the application of the patch, nor for the length of the hospital supervision. The patient should be advised not to touch the treated area, and to wear gloves for 1 or 2 days if the patch is applied on her/his hand. The patch should be applied on healthy, hairless, washed and thoroughly dried skin for 60 min in the concerned area, and no more than 30 min if pain is localized in the foot.

Besides its possible danger, its efficacy seems to be limited. A post-marketing surveillance study about high concentration topical capsaicin revealed a treatment success rate of 21.8% on neuropathic pain and a prospective observational study reports an improvement of the pain in 25.2% and 32.0% of patients (depending on the test).^{11,12} Moreover, new hyperesthesia or allodynia appeared in 1.1%–3.6% of patients after application.¹² Therapeutic alternatives exist and could be preferentially used before high-concentration topical capsaicin patch.¹³ Furthermore, a French observational cost-consequences study shows that its use resulted in additional costs for the hospital, without any benefit on the cost of care for each patient.¹⁴

To our knowledge, we report the first well-documented case-report of second-degree burn induced by the application of a high-concentration topical capsaicin patch with secondary mobility sequelae, possibly related to its application.

This clinical observation and previous data on this risk raise questions about the benefit/risk ratio of this drug. Further studies are needed to assess the frequency of this serious adverse event, and the place of high concentration topical capsaicin in the therapeutic arsenal for neuropathic pains. In particular, before prescription, clinicians should be aware of its complex use, its potentially severe adverse effects, its limited efficacy, the existence of various alternatives and its high cost.

AUTHOR CONTRIBUTIONS

KT collected the data, performed the analysis and wrote the article. JP, MA, HG and GM contributed to data collection and analysis. FS contributed to data analysis and supervised the work.

CONFLICT OF INTEREST

All the authors declare that they have no conflict of interest.

DATA AVAILABILITY STATEMENT

The data that support the findings of this study are available from the corresponding author upon reasonable request.

INFORMED CONSENT

Informed consent was obtained from the patient.

ORCID

Kilian Trin  <https://orcid.org/0000-0002-7650-645X>

Francesco Salvo  <https://orcid.org/0000-0003-3210-7171>

REFERENCES

- Raja SN, Carr DB, Cohen M, Finnerup NB, Flor H, Gibson S, et al. The revised International Association for the Study of Pain definition of pain: concepts, challenges, and compromises. *Pain*. 2020;161(9):1976–82.
- Bouhassira D. Neuropathic pain: definition, assessment and epidemiology. *Rev Neurol (Paris)*. 2019;175(1–2):16–25.
- Moisset X, Bouhassira D, Avez Couturier J, Alchaar H, Conradi S, Delmotte MH, et al. Pharmacological and non-pharmacological treatments for neuropathic pain: systematic review and French recommendations. *Rev Neurol (Paris)*. 2020;176(5):325–52.
- Schumacher MA. Transient receptor potential channels in pain and inflammation: therapeutic opportunities. *Pain Pract*. 2010;10(3):185–200.
- Derry S, Moore RA. Topical capsaicin (low concentration) for chronic neuropathic pain in adults. *Cochrane Database Syst Rev*. 2012;(9):CD010111.
- Babbar S, Marier J-F, Mouksassi M-S, Beliveau M, Vanhove GF, Chanda S, et al. Pharmacokinetic analysis of capsaicin after topical administration of a high-concentration capsaicin patch to patients with peripheral neuropathic pain. *Ther Drug Monit*. 2009;31(4):502–10.
- Kern K-U, Nowack W, Poole C. Treatment of neuropathic pain with the capsaicin 8% patch: is pretreatment with lidocaine necessary? *Pain Pract*. 2014;14(2):E42–50.
- Brunet F, Rimlinger C-A. Capsaïcine et nécrose cutanée. *Douleurs Éval Diagn Trait*. 2020;21(5–6):191–4.
- Haanpää M, Cruccu G, Nurmikko TJ, McBride WT, Docu Axelarad A, Bosilkov A, et al. Capsaicin 8% patch versus oral pregabalin in patients with peripheral neuropathic pain. *Eur J Pain*. 2016;20(2):316–28.
- Lindquist M. VigiBase, the WHO global ICSR database system: basic facts. *Drug Inf J*. 2008;42:409–19.
- Lantéri-Minet M, Perrot S. QAPSA: post-marketing surveillance of capsaicin 8% patch for long-term use in patients with peripheral neuropathic pain in France. *Curr Med Res Opin*. 2019;35(3):417–26.
- Gálvez R, Navez M-L, Moyle G, Maihöfner C, Stoker M, Ernault E, et al. Capsaicin 8% patch repeat treatment in nondiabetic peripheral neuropathic pain: a 52-week, open-label, single-arm, safety study. *Clin J Pain*. 2017;33(10):921–31.
- Attal N. Pharmacological treatments of neuropathic pain: the latest recommendations. *Rev Neurol (Paris)*. 2019;175(1–2):46–50.
- Schweitzer M, Caillet J-B, Paillet C, Baude C, Fagnoni P, Aulagner G, et al. Étude coût-conséquences sur la capsaïcine en patch cutané dans un CHU français. *Thérapies*. 2015;70(4):359–68.

How to cite this article: Trin K, Perino J, Allouchery M, Géniaux H, Miremont G, Salvo F. Second-degree burn induced by high-concentration topical capsaicin with mobility sequelae: A case report. *Pain Pract*. 2022;00:1–4. <https://doi.org/10.1111/papr.13175>