



**HAL**  
open science

# Man-eating termites: Osteolytic lesions upon human skulls perpetrated by subterranean termites (Insecta: Isoptera)

Jean-Bernard Huchet

## ► To cite this version:

Jean-Bernard Huchet. Man-eating termites: Osteolytic lesions upon human skulls perpetrated by subterranean termites (Insecta: Isoptera). 3rd meeting of the international Conference in Funerary Archaeoentomology (ICFAE), Jun 2019, Bordeaux, France. hal-03887626

**HAL Id: hal-03887626**

**<https://hal.science/hal-03887626>**

Submitted on 6 Dec 2022

**HAL** is a multi-disciplinary open access archive for the deposit and dissemination of scientific research documents, whether they are published or not. The documents may come from teaching and research institutions in France or abroad, or from public or private research centers.

L'archive ouverte pluridisciplinaire **HAL**, est destinée au dépôt et à la diffusion de documents scientifiques de niveau recherche, publiés ou non, émanant des établissements d'enseignement et de recherche français ou étrangers, des laboratoires publics ou privés.




Distributed under a Creative Commons Attribution 4.0 International License

# Man-eating termites

## Osteolytic lesions on human skulls perpetrated by subterranean termites (Insecta : Isoptera)

Jean-Bernard HUCHET<sup>1,2,3</sup>



### 1. INTRODUCTION

Among non-human biological agents (carnivores, rodents, bacteria, roots etc.), different orders of arthropod are significantly involved in the taphonomic processes of bone degradation. Although often dramatic, such osteolytic lesions remain poorly documented. In this regard, the Palaeontologist Thomas M. Kaiser (2010: 119) points out: "Insect damage to bone is one of the great unknowns to taphonomy, and comparative data are still rare".

Lesions in the bone matrix result from two distinct processes, one not excluding the other: mechanical (action of the mandibles) or chemical (proteolytic enzymes contained in digestive juices) origin. Both types of bioerosion have significant effects on bones.

Osteolytic lesions caused by insects (perforations, local bone gaps, erosion of the cortex exposing the underlying trabecular bone etc.) simulate certain degenerative or infectious bone pathologies (e.g. syphilis, periostitis, osteomyelitis, multiple bone myeloma). Conversely, these taphonomic artifacts can sometimes mask or even destroy any trace of possible "true" pathological surface lesions.

Finally, some bone defects, and more particularly circular perforations within the skull, may suggest traumatic injuries or simulate certain peri- or postmortem anthropic interventions (i.e. trepanation). Their recognition and characterization are therefore of real interest for anthropologists, archaeozoologists and paleopathologists.

1

Egyptian skull of the Middle Kingdom (Dayr al-Barsha / c. 2055-1650 BC) showing severe damage and partial destruction of the parietal bone due to the action of subterranean termites. The topography of the lesions, affecting only the left side of the skull, indicates that this part was lying on the ground at the time of infestation (Photos Dr. Toshi Dupras (University of Central Florida) and Dayr al-Barsha Expedition (Katholieke Universiteit Leuven, Belgium)).

### 2. TERMITES (ISOPTERA)

#### 2.1. General information

Termites are the only representatives of the order Isoptera. This taxon, particularly diversified worldwide, includes seven distinct families, 295 genera and nearly 2900 species (Constantino, 2007).

Regarding their biology, termites are traditionally divided into three ecological groups: drywood termites, dampwood termites and subterranean termites. Among these three entities, subterranean termites are undoubtedly the ones that cause the most damage to dwellings (degradation of wood and its derivatives) but also to bone remains.

#### 2.2. The impact of termites in the taphonomic processes of osteolytic degradation

According to current knowledge, three of the seven families of Isoptera (Termitidae, Mastotermitidae and Rhinotermitidae) have been identified as taphonomic agents causing bioerosion on human and animal bones.

On human remains, osteolytic lesions resulting from the action of Isoptera are relatively unknown to archaeologists and paleopathologists (fig. 1, 4, 5, 6). The lack of knowledge of the osteophagous behaviour of subterranean termites and the bioerosions resulting from this activity has led some former authors to attribute these alterations to certain pathologies or to various anthropogenic practices (see inset box below).

### Termites, pseudo-cannibalism and pseudopathologies

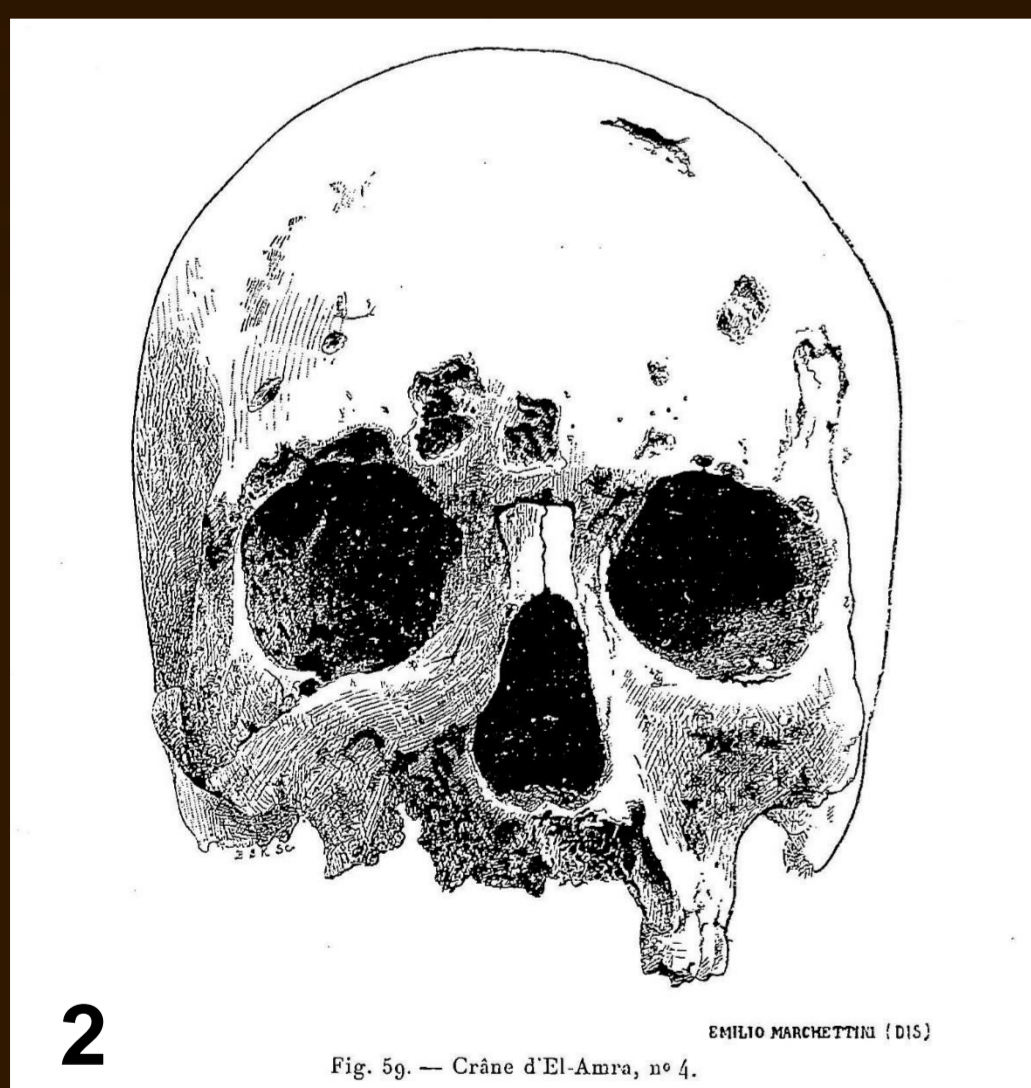


Figure 2. Pseudopathological case. Skull of a young Egyptian male individual (El-Amra necropolis) described as "syphilitic" by the anthropologist D. Fouquet (in De Morgan, 1897). The multiple pits visible in the figure correspond to bioerosions due to subterranean termites.

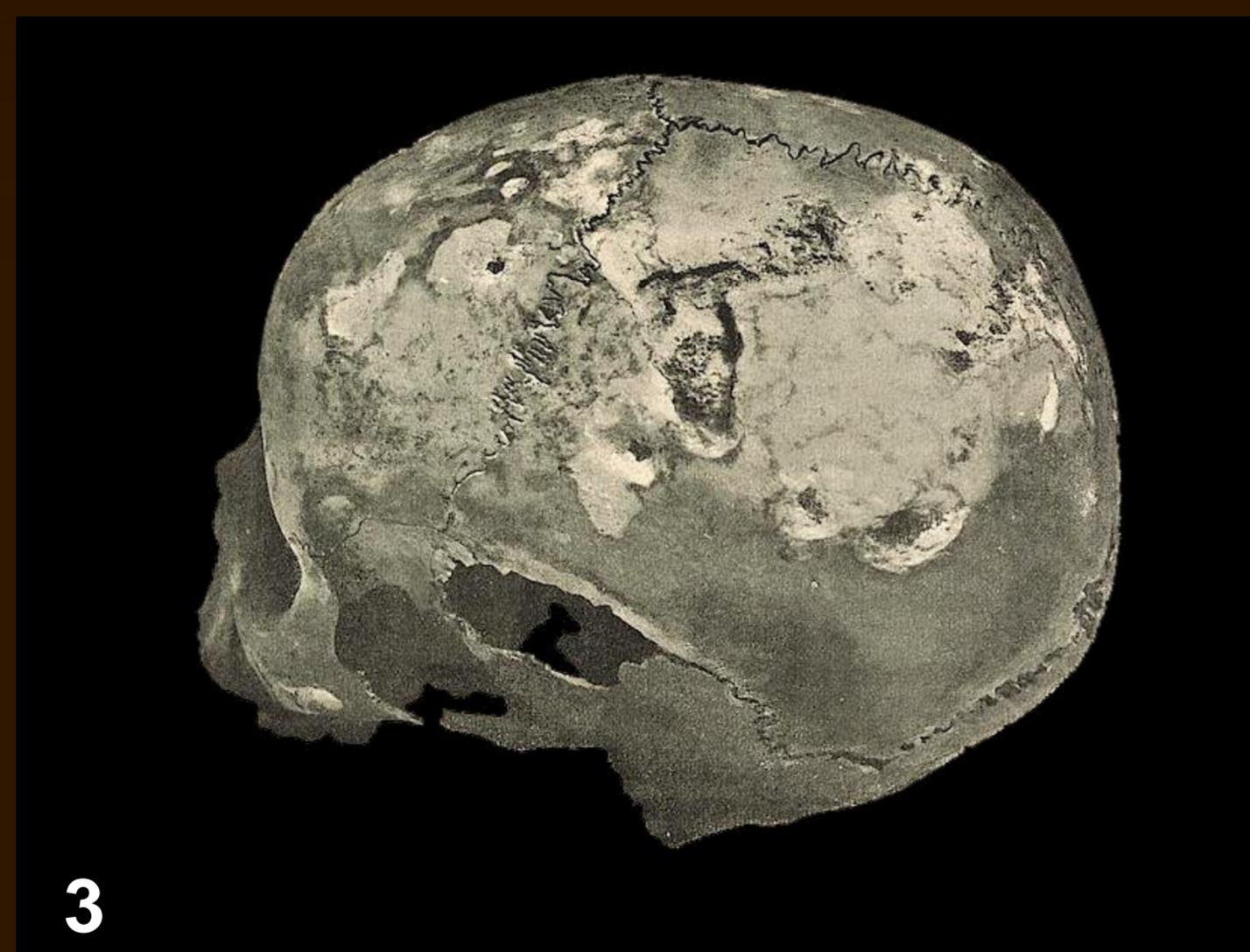
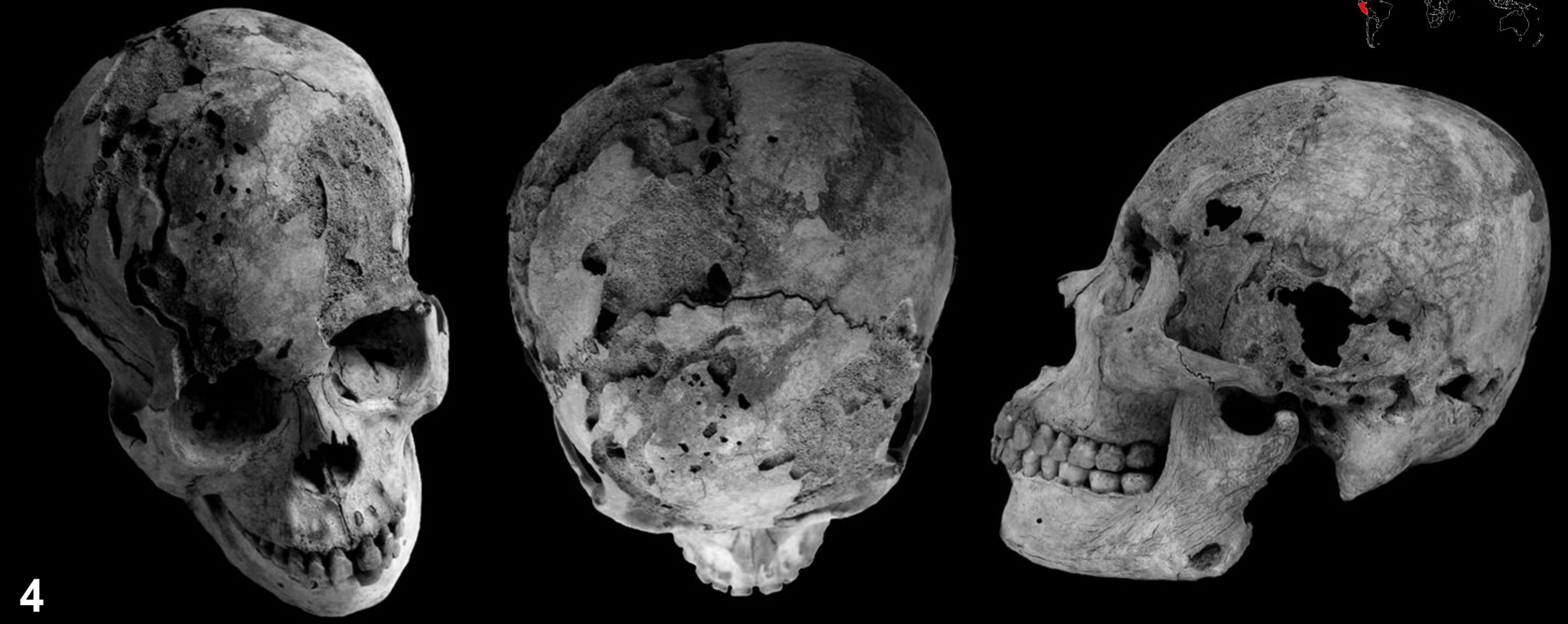

Figure 3. Pseudopathological case. Skull of a young Egyptian woman (Rôda) described as "syphilitic" by Lortet (1907: 212). The osteolytic lesions visible on this picture, causing the wrong retrospective diagnosis (pseudopathologic case), refer to subterranean termite activity. Adopted from Lortet (1907).

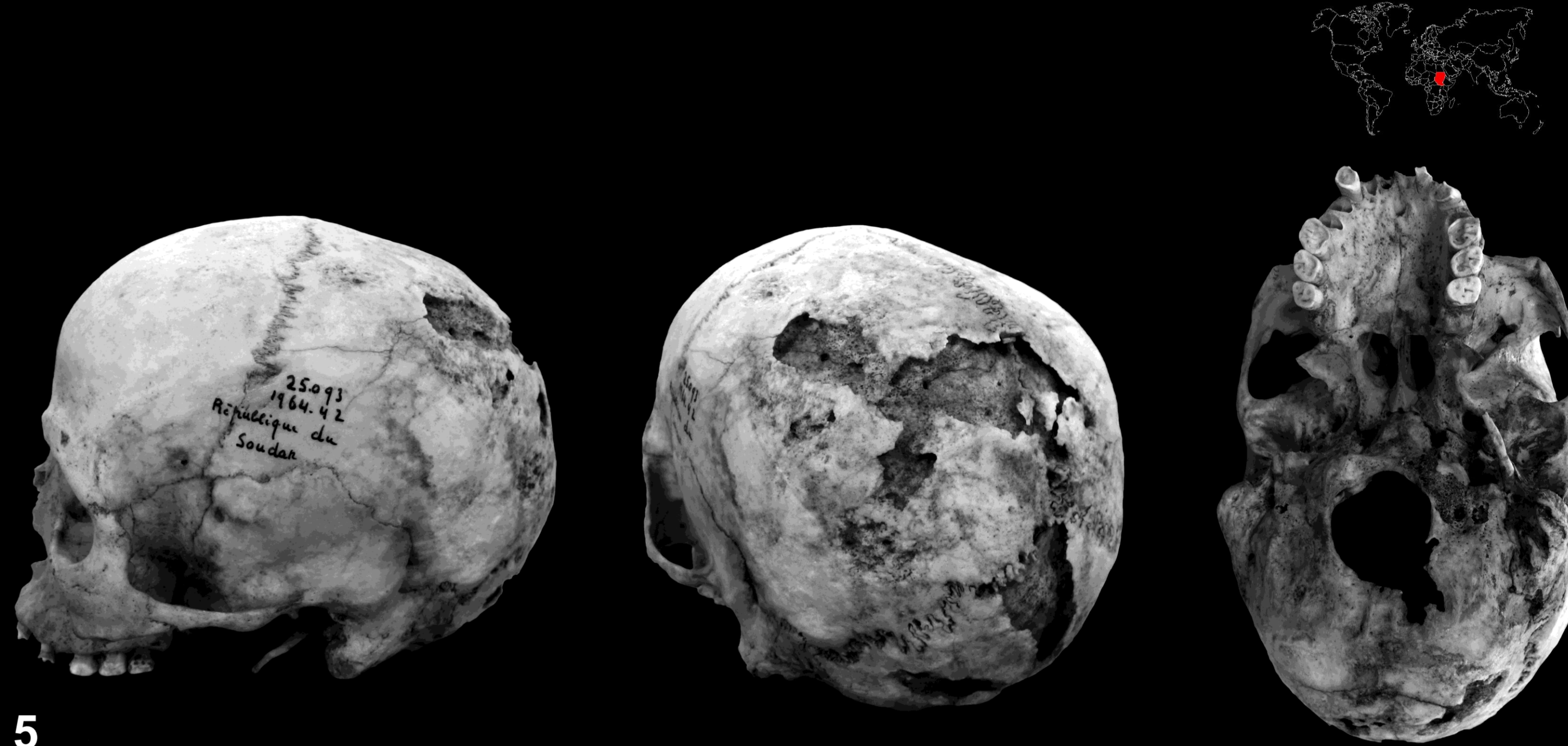
W. Mr. Flinders Petrie and J. E. Quibell (1896), both famous English Egyptologists, suggested that some modifications registered on human remains (skulls and long bone epiphyses) from the Naqada and Ballas sites provided irrefutable evidence of **cannibalism practices** in Ancient Egypt. One year later, in J. De Morgan's important monograph "Research on the Origins of Egypt" (1897), the anthropologist D. Fouquet attributed some skull perforations to **trepanning practices** (p. 361): "(...) what seems to me to be beyond dispute is the nature of the perforations and erosions of the skull. These are undoubtedly trepanations, used for therapeutic purposes".

The interpretation of various bioerosions present upon some skulls as being of a syphilitic nature remains undoubtedly one of the most famous examples of retrospective diagnostic error (Fouquet in De Morgan, 1897: 368): "(...) All deformed and ulcerated bones of South Negadah, El-Amra, Kawamil (...) seem to have been originated by the same cause, syphilis. (...) The aim is therefore not to destroy the scientific error that led to the introduction of syphilis in Europe in the 15th century, but only to provide a new proof after all the evidence that has already been provided" (fig. 3). A similar case from Rôda (Egypt) was later described by Lortet (1907: 212): "This skull (...) has an extremely remarkable bone alteration over its entire surface, its syphilitic origin cannot leave any doubt" (fig. 3).



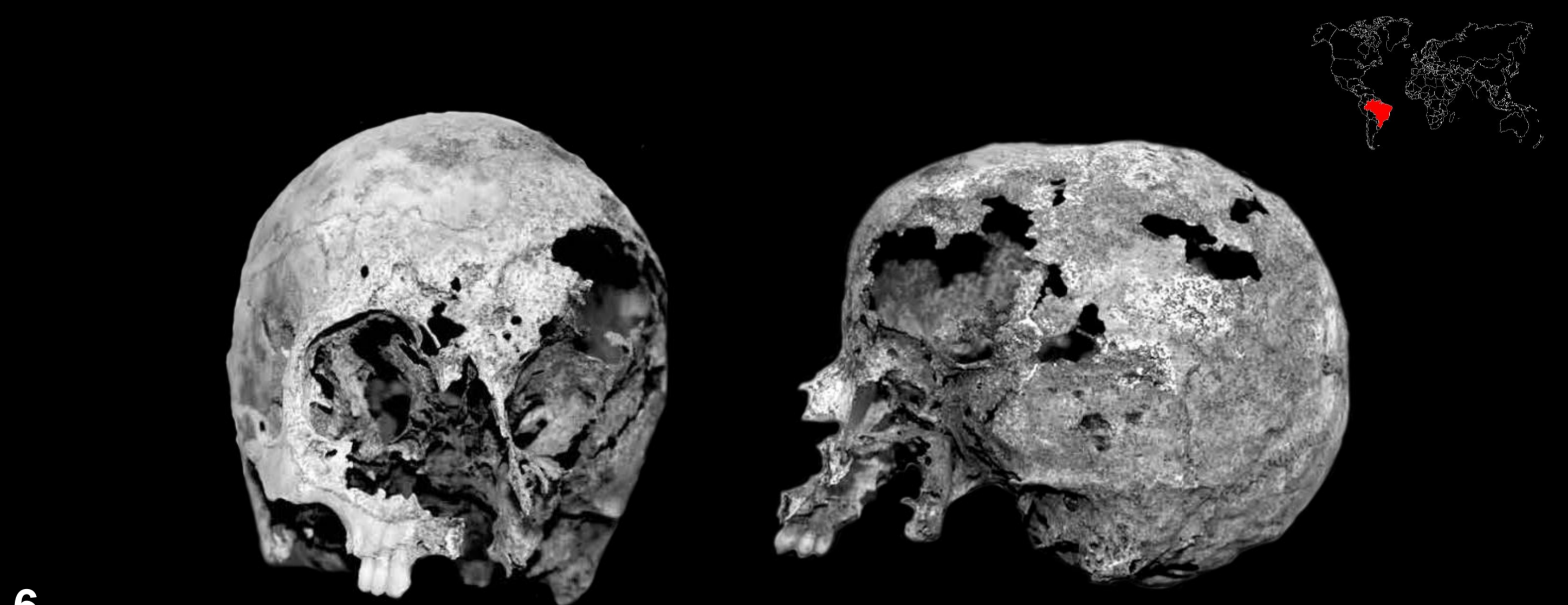4

Different views of a skull from the Mochica civilization (Peru) showing major osteolytic damage due to the subterranean termite *Amitermes lunae* Scheffrahn. (Notice the strong abrasion of the frontal bone and right parietal bone, the presence of numerous perforations and subcortical galleries characteristic of isopteran activity) (photos D. Deverly, J.-B. Huchet).



5

Different views of a skull from the Meroitic period (Akasha, Sudan) showing major osteolytic damage due to subterranean termites (collections from the MNHN anthropology laboratory, Paris / ref. AE 6-1 - 25 033, leg. Vercoutter 1964-42) (photos: E. Hanus, J.-B. Huchet, 2013)



6

Skull of a conceptionist nun (Monastery of Luz, Sao Paulo, Brazil, 19th century) showing severe bioerosions due to the activity of the subterranean termite *Coptotermes gestroi* (Wasmann) (Rhinotermitidae : Coptotermitinae). From: Fuzinato et al., 2010.


### 3. DIAGNOSTIC CHARACTERISATION

The analysis of bones degraded by termites leads to the identification of different gradients of osteolytic alterations, classified by ascending order of destruction: superficial imprints of mud galleries (i.e., shelter tubes) on the cortex (fig. 7), local, more or less generalized abrasion of the compact bone which can reach the diploe (fig. 8), deeper effects including notably cupules, fossae, perforations and galleries beneath the cortex (fig. 4, 5) and, lastly, the complete destruction of certain bones (fig. 1, 6).

The lesions are more or less generalized to the whole skeleton or localized on the bone surface in contact with the substratum, depending respectively on whether the bones were buried or remained exposed to open-air.

Although there is, a priori, no preferential topographical localization of lesions within the skeleton, some constants are, however, observed among the osteolytic degradation processes. Thus, when the skull is modified, bioerosions are frequently located along the skull sutures. Another characteristic signature of termite activity is the presence of circular or elliptical depressions, perforating or not, with their bevelled outer edge tilting obliquely towards the centre of the lesion.

Finally, the most characteristic signature of termite activity on bones are surface star-shaped traces, which correspond to the furrows left by mandibles on the bone surface and on the periphery of the perforations (fig. 9).



7

Superficial traces of subterranean termites tunnelling on a skull from the Meroitic period (Sai Island, Sudan, photo B. Maureille). Multiple perforations (pits) on the parietals and occipital are visible.

a

b

Parietal bone fragment in exocranial (a) and endocranial (b) views showing significant abrasion due to the bioerosive action of the termite *Amitermes lunae* Scheffrahn. The presence of lighter areas indicates that some lesions have been perpetrated on dry bone (Huaca de la Luna, Peru). (Photo C. Favart).

9

Characteristic star-shaped traces generated by subterranean termite mandibles on the outer table of a skull of an immature individual (Sai Island, Sudan) (photo: M. Guillon).

### 4. CONCLUSION

Traces on bones related to isopteran activity are undoubtedly among the most frequent taphonomic alterations found both in the fossil record and in archaeological context.

Although the osteolytic lesions perpetrated by these insects show significant diversity, the existence of several discriminating criteria, isolated or combined (tunnelling, galleries, star-shaped traces, circular or elliptical depressions) facilitates retrospective diagnosis.

**Acknowledgements:** Many thanks to Dr Amoret Whitaker (University of Winchester) for having reviewed this work and for English improvement.