



**HAL**  
open science

## Progression of left anterior descending artery dissection due to stent implantation for spontaneous coronary artery dissection of left circumflex artery: a case report

Kensuke Matsushita, Jessica Ristorto, Olivier Morel, Patrick Ohlmann

### ► To cite this version:

Kensuke Matsushita, Jessica Ristorto, Olivier Morel, Patrick Ohlmann. Progression of left anterior descending artery dissection due to stent implantation for spontaneous coronary artery dissection of left circumflex artery: a case report. *European Heart Journal. Case Reports*, 2019, 3 (4), pp.1 - 6. 10.1093/ehjcr/ytz173 . hal-03884768

**HAL Id: hal-03884768**

**<https://hal.science/hal-03884768v1>**

Submitted on 5 Dec 2022

**HAL** is a multi-disciplinary open access archive for the deposit and dissemination of scientific research documents, whether they are published or not. The documents may come from teaching and research institutions in France or abroad, or from public or private research centers.

L'archive ouverte pluridisciplinaire **HAL**, est destinée au dépôt et à la diffusion de documents scientifiques de niveau recherche, publiés ou non, émanant des établissements d'enseignement et de recherche français ou étrangers, des laboratoires publics ou privés.



Distributed under a Creative Commons Attribution - NonCommercial 4.0 International License

# Progression of left anterior descending artery dissection due to stent implantation for spontaneous coronary artery dissection of left circumflex artery: a case report

Kensuke Matsushita <sup>1,2</sup>, Jessica Ristorto <sup>1</sup>, Olivier Morel<sup>1,2</sup>, and Patrick Ohlmann<sup>1\*</sup>

<sup>1</sup>Université de Strasbourg, Pôle d'Activité Médico-Chirurgicale Cardio-Vasculaire, Nouvel Hôpital Civil, Centre Hospitalier Universitaire, 1 place de l'Hôpital, 67091 Strasbourg, France; and <sup>2</sup>UMR 1260 INSERM, Nanomédecine Régénérative, Faculté de Pharmacie, Université de Strasbourg, 74 route du Rhin, 67401 Illkirch, France

Received 17 April 2019; first decision 4 June 2019; accepted 13 September 2019; online publish-ahead-of-print 9 October 2019

## Background

Spontaneous coronary artery dissection (SCAD) is a rare disease that predominantly affects woman. Percutaneous coronary intervention (PCI) is recommended only in patients with ongoing ischaemia because it carries a high risk of procedural complications in SCAD patients.

## Case summary

A 51-year-old woman was admitted to our institution owing to severe chest pain. Coronary angiography showed a diffuse narrowing and radiolucent luminal flap which runs parallel to the vessel wall in the proximal left circumflex coronary artery and SCAD was diagnosed. After PCI was undertaken, optical coherence tomography disclosed a circular haematoma at the stent distal segment and an intimal tear at the distal left main coronary artery. A conservative approach was decided owing to patient stability without evidence of ongoing ischaemia and normal coronary flow. Thirty minutes later, the patient started to complain of chest pain with the ST-segment elevation in leads I, aVL, and V2–3. Coronary angiography demonstrated a total occlusion of the second diagonal branch and double lumen morphology at the proximal portion of left anterior descending with TIMI2 distal flow suggesting the extension of coronary dissection. Optical coherence tomography imaging revealed that the entry door of the dissection was located where the small intimal tear was found. Percutaneous coronary intervention was successfully performed, and the patient was discharged without any complication.

## Discussion

Although the underlying mechanism of recurrent SCAD remain largely unknown, our case suggests that the residual inlet of the dissection may associate with the extension of the coronary dissection.

## Keywords

Spontaneous coronary artery dissection • Optical coherence tomography • Percutaneous coronary intervention • Case report

## Learning points

- Novel intracoronary imaging can be valuable both in confirming the diagnosis and in guiding treatment decisions in patients with spontaneous coronary artery dissection (SCAD).
- Longitudinal extension may occur when the entry of the dissection is left after percutaneous coronary intervention for SCAD. As in our case, the distinct dynamic morphological features can be unravelled by optical coherence tomography.

\* Corresponding author. Tel: +33 3 69 55 05 82, Fax: +33 69 55 17 37/17 99, Email: [Patrick.Ohlmann@chru-strasbourg.fr](mailto:Patrick.Ohlmann@chru-strasbourg.fr)

Handling Editor: Gabor G. Toth

Peer-reviewers: Sameh Shaheen, Michel Zeitouni, Rafael Vidal-Perez, Panagiotis Xaplanteris, and Blazej Michalski

Compliance Editor: Mohammed Majid Akhtar

Supplementary Material Editor: Ross Thomson

© The Author(s) 2019. Published by Oxford University Press on behalf of the European Society of Cardiology.

This is an Open Access article distributed under the terms of the Creative Commons Attribution Non-Commercial License (<http://creativecommons.org/licenses/by-nc/4.0/>), which permits non-commercial re-use, distribution, and reproduction in any medium, provided the original work is properly cited. For commercial re-use, please contact [journals.permissions@oup.com](mailto:journals.permissions@oup.com)

## Introduction

Spontaneous coronary artery dissection (SCAD) is defined as an epicardial coronary dissection that is not associated with atherosclerosis or trauma and not iatrogenic.<sup>1</sup> Recent studies suggest that SCAD may be a cause of up to 1–4% of acute coronary syndrome cases overall<sup>2–5</sup> and up to 35% of myocardial infarction in woman under 50 years old.<sup>5–7</sup> Two theories of how SCAD develops have been described.<sup>1</sup> The first theory proposes that the primary pathological event is the development of intimal tear, which allows blood from the true lumen (TL) to enter and generate a false lumen (FL). The second theory proposes that the primary event is a spontaneous haemorrhage arising from the vasa vasorum within the vessel wall. The high-risk period of severe deterioration appears to be within 6 days of presentation especially in patients with isolated intramural haematoma revealed by coronary angiography.<sup>8</sup> Intracoronary imaging may play a major role in the accurate diagnosis of these elusive unique conditions.<sup>9–12</sup> We describe a unique case with a severe deterioration of SCAD after primary percutaneous coronary intervention (PCI). The images from optical coherence tomography (OCT) just before the extension of coronary dissection helped us in understanding the mechanism.

## Timeline

Day	Events
Day 1 first procedure	A 51-year-old woman presented with inferior ST-segment elevation myocardial infarction. Spontaneous coronary artery dissection of left circumflex coronary artery was diagnosed and percutaneous coronary intervention was successfully performed.
Day 1 second procedure	Thirty minutes after the first procedure, she complained of chest pain and coronary angiography suggested the extension of coronary dissection to left anterior descending (LAD). Percutaneous coronary intervention was performed from left main coronary artery to LAD.
Day 9 discharge	The patient was discharged with in a stable condition.

## Case presentation

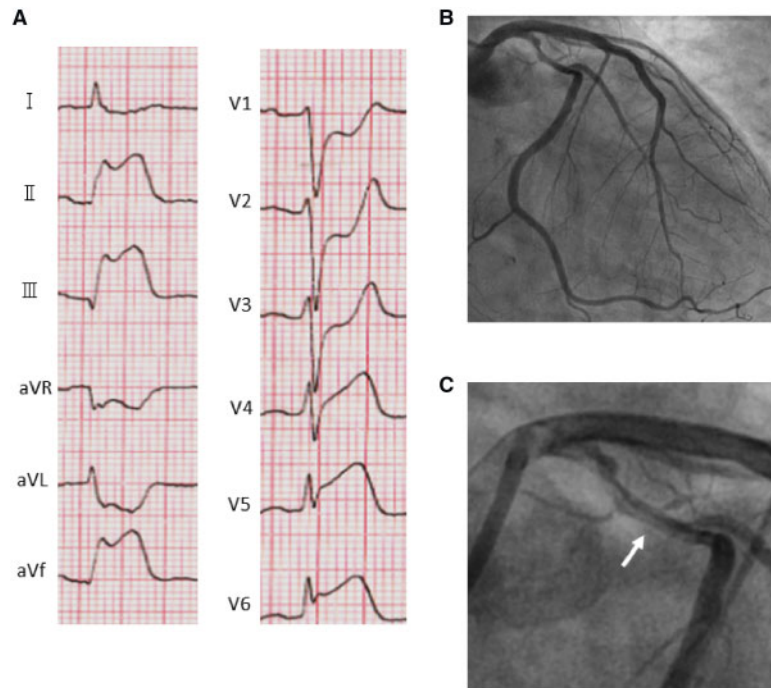
A 51-year-old woman with a previous history of hypertension, dyslipidaemia, cigarette smoking, and cerebral infarction due to vertebral artery dissection presented with inferolateral ST-segment elevation myocardial infarction (*Figure 1A*). Urgent coronary angiography demonstrated a diffuse narrowing in the proximal left circumflex coronary artery (LCX) (*Figure 1B*; [Supplementary material online, S1](#)) with Thrombolysis In Myocardial Infarction (TIMI) flow grade 2. A radio-lucent luminal flap which runs parallel to the vessel wall was observed

(*Figure 1C*) and Type 1 SCAD was diagnosed. After insertion of a SION blue (Asahi Intecc Co., Aichi, Japan) wire with the intention of performing intracoronary imaging, the artery flow collapsed to TIMI 0. An immediate PCI was undertaken with implantation of everolimus-eluting stent (SYNERGY 3.5 × 38 mm, Boston Scientific, Natick, MA, USA), and the angiography revealed a mild stenosis at distal of the stent without impairment of coronary flow ([Supplementary material online, S2](#)). Optical coherence tomography disclosed a circular haematoma with the presence of a false double lumen at the stent distal segment and an intimal tear at the distal left main coronary artery (LMCA) (*Figure 2*). A conservative approach was decided owing to patient stability without evidence of ongoing ischaemia and normal TIMI flow.

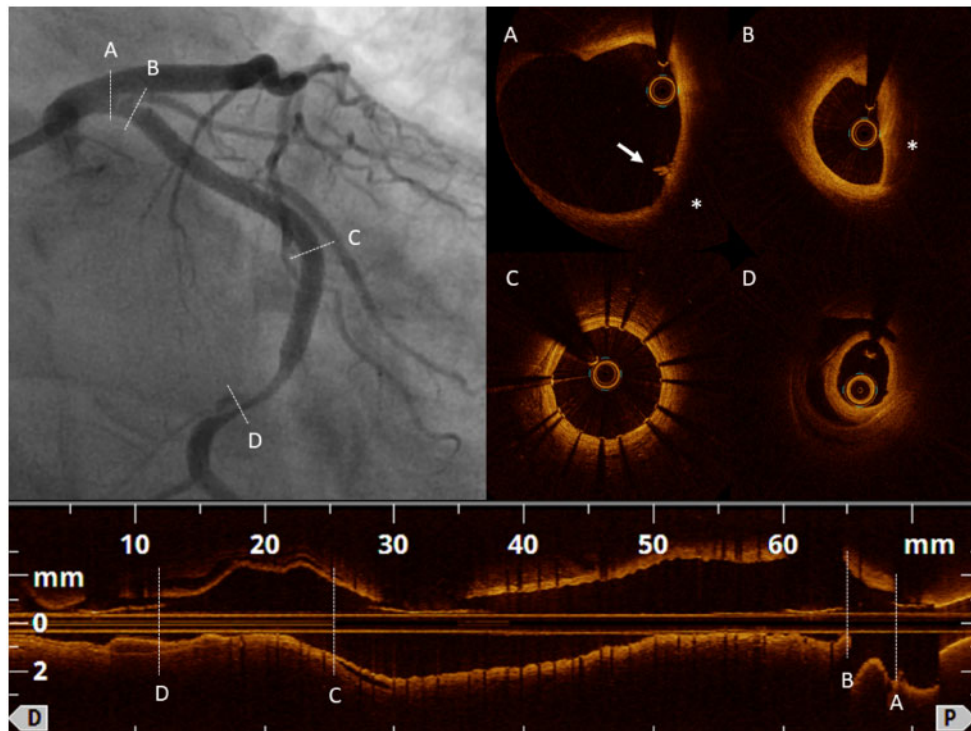
Thirty minutes later, she started to complain of chest pain and the electrocardiogram revealed ST-segment elevation in leads I, aVL, and V2–3 (*Figure 3A*). Coronary angiography demonstrated a double lumen morphology at the proximal portion of the left anterior descending (LAD) with TIMI2 distal flow suggesting the extension of coronary dissection and a total occlusion of the second diagonal branch (*Figure 3B*; [Supplementary material online, S3](#)). Optical coherence tomography imaging revealed that the true arterial lumen was compressed by the FL between the proximal and middle portion of the LAD (*Figure 4*; [Supplementary material online, S4](#)). The dissection began from the point where the small intimal tear was found in the final OCT pullback of the first procedure. Since the guidewire was in the FL, attempt to select the TL by using SION blue (Asahi Intecc Co.) was performed. After unsuccessful attempts, intravascular ultrasound (IVUS) was used to guide the wire into the TL (*Figure 5*). Optical coherence tomography evaluation after rewiring showed that the guidewire had been successfully placed in the TL and everolimus-eluting stent (SYNERGY 4.0 × 32 mm, Boston Scientific) was implanted from the body of the LMCA to the proximal LAD. Because of the residual stenosis at the ostial LCX, everolimus-eluting stent (SYNERGY 3.5 × 12 mm, Boston Scientific) was implanted followed by a kissing balloon inflation. Although angiography revealed a residual dissection at the distal end of the stent, the patient was asymptomatic with normalized ST-segment elevation and normal LAD flow ([Supplementary material online, S5](#)). A conservative medical approach with dual antiplatelet therapy was decided and the patients were transferred to the coronary care unit. Echocardiography immediately after the procedure revealed hypokinesis at the anterolateral and inferolateral segments with a left ventricular ejection fraction of 37%, but it improved to 50% at Day 3. In the absence of in-hospital complications, she was discharged at Day 9. Magnetic resonance angiography (MRA) was performed 1 month later to screen fibromuscular dysplasia (FMD). Although no stenosis was observed in the renal arteries, FMD was suspected by an irregularity of the right internal carotid artery and an aneurysm at the right vertebral artery ([Supplementary material online, S6](#)).

## Discussion

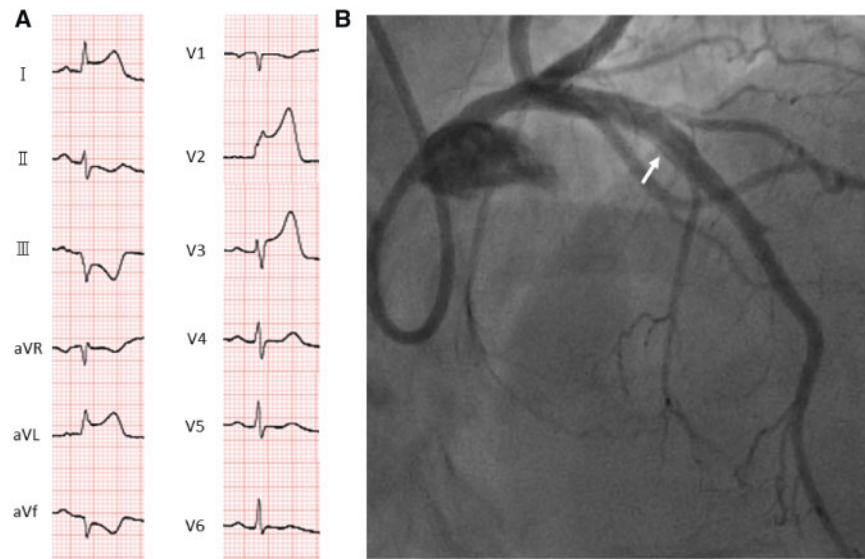
Spontaneous coronary artery dissection is an important, non-atherosclerotic cause of myocardial infarction and sudden death especially in young individuals. Predisposing conditions include FMD, systemic inflammatory disease, peripartum, and connective tissue disorders.<sup>13</sup>



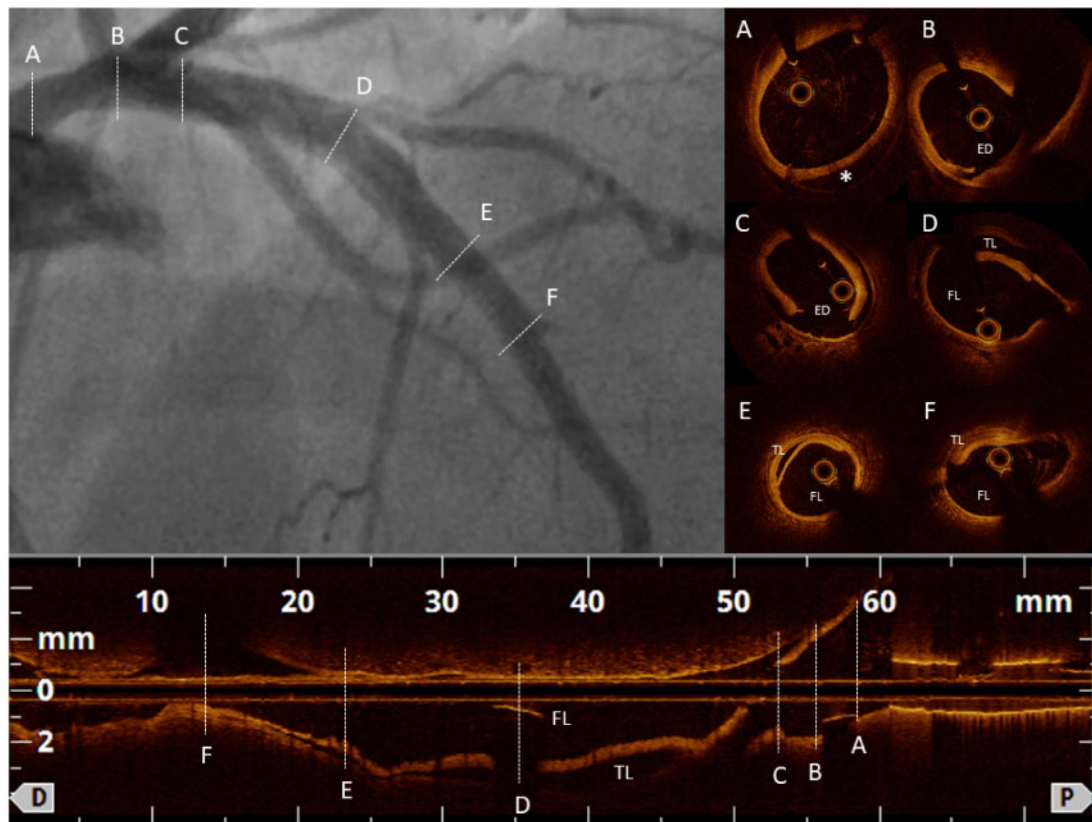
**Figure 1** (A) ST-segment elevations were detected in electrocardiogram leads II, III, aVf, V4–6. (B and C) Coronary angiogram revealed a diffuse lumen narrowing with double lumen on the proximal segment of the left circumflex (arrow).



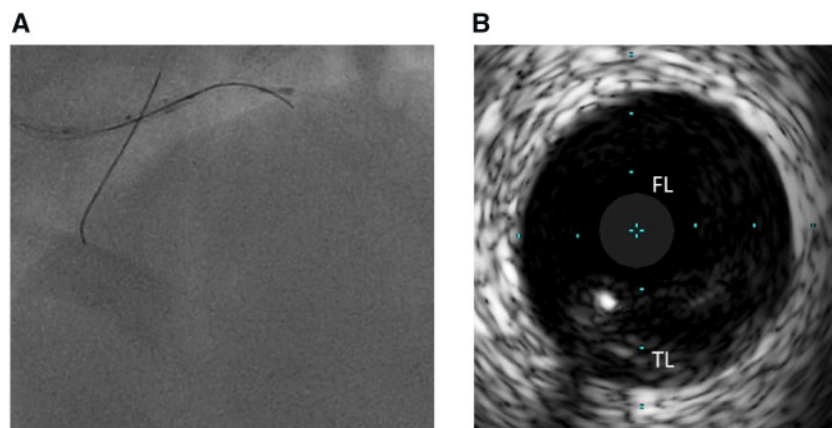
**Figure 2** (A and B) Optical coherence tomography evaluation after stenting demonstrated an image suggestive of intramural haematoma from the proximal left circumflex to left main coronary artery (\*). Intimal tear was observed above the haematoma at the distal LMCA (arrow). (C) Good stent expansion and apposition. (D) A false double lumen created by the haematoma was found at distal to the stent.



**Figure 3** (A) ST-segment elevations were detected in electrocardiogram leads I, aVL, V2–3. (B) Coronary angiogram showing radiolucent lumens at the middle portion of the left anterior descending coronary artery (arrow) and the second diagonal branch occlusion.



**Figure 4** (A) Optical coherence tomography pullback at the left main coronary artery disclosing an image suggestive of intramural haematoma (\*). (B and C) Entry door of the dissection was identified at the distal left main coronary artery. (D and E) The true lumen was compressed by the false lumen between the proximal and middle portion of the left anterior descending coronary artery. (F) Second diagonal branch was completely obstructed by the false lumen. ED, entry door; FL, false lumen; TL, true lumen.



**Figure 5** (A) Intravascular ultrasound guided bailout was performed for selecting the true lumen. (B) The guidewire was successfully placed in the true lumen. FL, false lumen; TL, true lumen.

The most frequent is FMD which occurs predominantly in middle-aged females with few cardiovascular risk factors.<sup>14</sup> Imaging of extra-coronary vascular beds is recommended for patients with SCAD to identify abnormalities such as aneurysms, dissections, and irregularities.<sup>14</sup> As in our case, MRA could be helpful for the diagnosis of FMD, and may be preferred in patients with diabetes, renal insufficiency or iodine-contrast intolerance.

Conservative therapy is generally favoured for management of acute SCAD.<sup>1,8,14,15</sup> Since observational studies have shown consistently that PCI for the treatment of SCAD is associated with an increased risk of complication,<sup>1,15,16</sup> percutaneous coronary intervention is recommended only in high-risk patients with ongoing ischaemia, left main artery dissection, or haemodynamic instability.

This case has described that the SCAD progressed from the entry door in LMCA to LAD after the stent implantation in LCX. We could hypothesize that the intimal tear at the LMCA which was documented by OCT just after the LCX stenting was responsible for the second event. The initial OCT images of the second procedure clearly revealed that the dissection was arising from the same location where the intimal tear was found. It remains unclear whether the intimal flap was originally located or was associated with the stent implantation. However, it would be justifiable to consider that the initial stenting to the LCX may have obstructed the inflow of the FL which allowed the haematoma to extend to the LAD. To the best of our knowledge, this is the first demonstration of patients with SCAD that the dissection has extended to another major coronary artery after stent implantation. Although the incidence appears to be low, it may be necessary to recognize that stent implantation may cause an extension of the dissection to another coronary artery when the entry door of the dissection remained at LMCA.


Intravascular ultrasound use was beneficial to select the TL compressed by the FL in the present case. Optical coherence tomography has superior ability to visualize the TL-intima interface as compared with IVUS<sup>9,17</sup> so that it could nicely depict FL/intramural haematoma of SCAD. Although, imaging with OCT requires high pressure

contrast which carries a potential risk of extension of the FL, recent studies suggest that this can be performed safely.<sup>14,18,19</sup> On the other hand, IVUS has an advantage over OCT in terms of enabling a more complete vessel visualization and providing a real-time view. The present case highlights the importance of OCT for diagnosis and strategy planning, and IVUS for the assistance of PCI to lead the guidewire into the compressed TL of SCAD.

## Conclusion

Although PCI is recommended in SCAD patients with high-risk features, caution should be taken for the longitudinal extension to the untreated coronary artery when the entry of the dissection is left in the LMCA.

## Lead author biography



Kensuke Matsushita has joined the team of cardiovascular intervention at University Hospital of Strasbourg since 2018. His research interests have been centered in the areas of intracoronary imaging, coronary physiology, and structural heart disease intervention.

## Supplementary material

Supplementary material is available at *European Heart Journal - Case Reports* online.

## Funding

Kensuke Matsushita has received scholarship from Uehara Memorial Foundation.

**Slide sets:** A fully edited slide set detailing this case and suitable for local presentation is available online as [Supplementary data](#).

**Consent:** The author/s confirm that written consent for submission and publication of this case report including image(s) and associated text has been obtained from the patient in line with COPE guidance.

**Conflict of interest:** none declared.

## References

- Hayes SN, Kim ESH, Saw J, Adlam D, Arslanian-Engoren C, Economy KE, Ganesh SK, Gulati R, Lindsay ME, Mieres JH, Naderi S, Shah S, Thaler DE, Tweet MS, Wood MJ. Spontaneous coronary artery dissection: Current state of the science: a scientific statement from the American Heart Association. *Circulation* 2018;**137**: e523–e557.
- Tweet MS, Hayes SN, Pitta SR, Simari RD, Lerman A, Lennon RJ, Gersh BJ, Khambatta S, Best PJM, Rihal CS, Gulati R. Clinical features, management, and prognosis of spontaneous coronary artery dissection. *Circulation* 2012;**126**: 579–588.
- Mortensen KH, Thuesen L, Kristensen IB, Christiansen EH. Spontaneous coronary artery dissection: a Western Denmark Heart Registry study. *Catheter Cardiovasc Interv* 2009;**74**:710–717.
- Vanzetto G, Berger-Coz E, Barone-Rochette G, Chavanon O, Bouvaist H, Hacini R, Blin D, Machecourt J. Prevalence, therapeutic management and medium-term prognosis of spontaneous coronary artery dissection: Results from a database of 11,605 patients. *Eur J Cardiothorac Surg* 2009;**35**:250–254.
- Nishiguchi T, Tanaka A, Ozaki Y, Taruya A, Fukuda S, Taguchi H, Iwaguro T, Ueno S, Okumoto Y, Akasaka T. Prevalence of spontaneous coronary artery dissection in patients with acute coronary syndrome. *Eur Heart J Acute Cardiovasc Care* 2016;**5**:263–270.
- Nakashima T, Noguchi T, Haruta S, Yamamoto Y, Oshima S, Nakao K, Taniguchi Y, Yamaguchi J, Tsuchihashi K, Seki A, Kawasaki T, Uchida T, Omura N, Kikuchi M, Kimura K, Ogawa H, Miyazaki S, Yasuda S. Prognostic impact of spontaneous coronary artery dissection in young female patients with acute myocardial infarction: A report from the angina pectoris-myocardial infarction multicenter investigators in Japan. *Int J Cardiol* 2016;**207**:341–348.
- Rashid HNZ, Wong DTL, Wijesekera H, Gutman SJ, Shanmugam VB, Gulati R, Malaipan Y, Meredith IT, Psaltis PJ. Incidence and characterisation of spontaneous coronary artery dissection as a cause of acute coronary syndrome—a single-centre Australian experience. *Int J Cardiol* 2016;**202**:336–338.
- Waterbury TM, Tweet MS, Hayes SN, Eleid MF, Bell MR, Lerman A, Singh M, Best PJM, Lewis BR, Rihal CS, Gersh BJ, Gulati R. Early natural history of spontaneous coronary artery dissection. *Circ Cardiovasc Interv* 2018;**11**:e006772.
- Paulo M, Sandoval J, Lennie V, Dutary J, Medina M, Gonzalo N, Jimenez-Quevedo P, Escaned J, Bañuelos C, Hernandez R, Macaya C, Alfonso F. Combined use of OCT and IVUS in spontaneous coronary artery dissection. *JACC Cardiovasc Imaging* 2013;**6**:830–832.
- Alfonso F, Paulo M, Gonzalo N, Dutary J, Jimenez-Quevedo P, Lennie V, Escaned J, Bañuelos C, Hernandez R, Macaya C. Diagnosis of spontaneous coronary artery dissection by optical coherence tomography. *J Am Coll Cardiol* 2012;**59**: 1073–1079.
- Saw J, Mancini GBJ, Humphries KH. Contemporary review on spontaneous coronary artery dissection. *J Am Coll Cardiol* 2016;**68**:297–312.
- Ohlmann P, Weigold G, Kim S-W, Hassani S-E, Escolar E, Pichard AD, Kent KM, Satler L, Suddath WO, Waksman R, Weissman NJ. Images in cardiovascular medicine. Spontaneous coronary dissection: computed tomography appearance and insights from intravascular ultrasound examination. *Circulation* 2006;**113**: e403–e405.
- Saw J, Starovoytov A, Humphries K, Sheth T, So D, Minhas K, Brass N, Lavoie A, Bishop H, Lavi S, Pearce C, Renner S, Madan M, Welsh RC, Lutchmedial S, Vijayaraghavan R, Aymong E, Har B, Ibrahim R, Gornik HL, Ganesh S, Buller C, Matteau A, Martucci G, Ko D, Mancini GBJ. Canadian spontaneous coronary artery dissection cohort study: in-hospital and 30-day outcomes. *Eur Heart J* 2019; **40**:1188–1197.
- Adlam D, Alfonso F, Maas A, Vrints C, Al-Hussaini A, Bueno H, Capranzano P, Gevaert S, Hoole SP, Johnson T, Lettieri C, Maeder MT, Motreff P, Ong P, Persu A, Rickli H, Schiele F, Sheppard MN, Swahn E. European Society of Cardiology, acute cardiovascular care association, SCAD study group: a position paper on spontaneous coronary artery dissection. *Eur Heart J* 2018;**39**:3353–3368.
- Tweet MS, Eleid MF, Best PJM, Lennon RJ, Lerman A, Rihal CS, Holmes DR, Hayes SN, Gulati R. Spontaneous coronary artery dissection: revascularization versus conservative therapy. *Circ Cardiovasc Interv* 2014;**7**:777–786.
- Rogowski S, Maeder MT, Weilenmann D, Haager PK, Ammann P, Rohner F, Joerg L, Rickli H. Spontaneous coronary artery dissection: Angiographic follow-up and long-term clinical outcome in a predominantly medically treated population. *Catheter Cardiovasc Interv* 2017;**89**:59–68.
- Kubo T, Shinke T, Okamura T, Hibi K, Nakazawa G, Morino Y, Shite J, Fusazaki T, Otake H, Kozuma K, Itoji T, Kaneda H, Serikawa T, Kataoka T, Okada H, Akasaka T. Optical frequency domain imaging vs. Intravascular ultrasound in percutaneous coronary intervention (opinion trial): one-year angiographic and clinical results. *Eur Heart J* 2017;**38**:3139–3147.
- Nishiguchi T, Tanaka A, Taruya A, Ozaki Y, Nakai M, Teraguchi I, Ota S, Kuroi A, Kameyama T, Yamano T, Yamaguchi T, Matsuo Y, Ino Y, Kubo T, Hozumi T, Akasaka T. Prognosis of spontaneous coronary artery dissection treated by percutaneous coronary intervention with optical coherence tomography. *J Cardiol* 2017;**70**:524–529.
- Motreff P, Malcles G, Combaret N, Barber-Chamoux N, Bouajila S, Pereira B, Amonchot A, Citron B, Lussion J-R, Eschaliere R, Souteyrand G. How and when to suspect spontaneous coronary artery dissection: novel insights from a single-centre series on prevalence and angiographic appearance. *EuroIntervention* 2017; **12**:e2236–e2243.