



Body awareness disorders: dissociations between body-related visual and somatosensory information

Laure Pisella, Laurence Havé, Yves Rossetti

► To cite this version:

Laure Pisella, Laurence Havé, Yves Rossetti. Body awareness disorders: dissociations between body-related visual and somatosensory information. *Brain - A Journal of Neurology* , 2019, 10.1093/brain/awz187 . hal-03871695

HAL Id: hal-03871695

<https://hal.science/hal-03871695v1>

Submitted on 9 Dec 2022

HAL is a multi-disciplinary open access archive for the deposit and dissemination of scientific research documents, whether they are published or not. The documents may come from teaching and research institutions in France or abroad, or from public or private research centers.

L'archive ouverte pluridisciplinaire **HAL**, est destinée au dépôt et à la diffusion de documents scientifiques de niveau recherche, publiés ou non, émanant des établissements d'enseignement et de recherche français ou étrangers, des laboratoires publics ou privés.

Body awareness disorders: dissociations between body-related visual and somatosensory information

This scientific commentary refers to 'The antero-dorsal precuneal cortex supports specific aspects of bodily awareness', by Herbert et al. (doi:10.1093/brain/awz179).

Information about the body arrives in numerous forms: tactile, proprioceptive, nociceptive, vestibular, visual, motor, cognitive and semantic. Only a limited proportion of this input is processed consciously and we remain unaware of many of the processes necessary to maintain postural control and to perform actions. Body cognition is frequently viewed as dyadic or triadic, with a distinction made between the body schema and the body image (Longo et al., 2010; Pitron et al., 2018). Body awareness disorders (BADs) are uncommon in neurology. They may involve distorted perception or reduced awareness of parts of the body or an impaired ability to localize them, feelings of strangeness, loss of agency, and illusory feelings of movement or even of having supernumerary limbs.

BADs are often associated with syndromes arising as a result of parietal lobe lesions (Fig. 1), although they may also occur following lesions in other locations. Lesions may give rise to deficits in either the body image or the body schema. Unilateral neglect, for example, typically results from a right hemisphere lesion and may manifest in the body schema domain (motor neglect, directional hypokinesia

or bradykinesia) or the body image domain (e.g. tactile extinction or allochiria, personal neglect, anosognosia for hemiplegia, hemiasomatognosia, somatoparaphrenia). Optic ataxia and apraxias—which reflect body schema deficits—may result from lesions of either the left or right hemispheres. Left posterior parietal lobe lesions can lead to Gerstmann syndrome, involving finger agnosia (an inability to distinguish the fingers on the hand) and left-right disorientation, which may also apply to body parts, both of which can be considered body image impairments. An anterior lesion of the left superior parietal lobule including the precuneus has been reported to cause illusory drift followed by fading limb in the absence of vision (Wolpert et al., 1998). However, no such body image impairment was reported in association with optic ataxia following posterior lesion of the left or right superior parietal lobule; by contrast these latter patients produced large localization errors in a proprioceptive pointing task, indicating body schema deficits (Blangero et al., 2007). While BADs are widely acknowledged to be associated with syndromes consecutive to parietal lobe lesions, the reasons for their presence or absence in individual patients have often been something of a mystery. In this issue of *Brain*, Herbert and co-workers provide a possible explanation for the scarcity of BADs and their non-systematic association with the more

classical parietal syndromes: BADs may arise only when a lesion of posterior parietal cortex also involves the medial area, i.e. the precuneus, and more specifically the antero-dorsal precuneus (Herbert et al., 2019).

Neuroimaging data have implicated the antero-dorsal precuneus in strikingly heterogeneous functions ranging from motor coordination, drawing and imitation to working memory and subject-verb integration (from the *Neurosynth* online tool http://neurosynth.org/locations/6_-52_66_3/). By contrast, human brain lesions rarely affect this medial brain territory, explaining why BADs after parietal stroke, and specific neuropsychological reports on this region both remain scarce. But while circumscribed precuneus lesions are rather rare, Herbert et al. managed to identify and assess 14 patients who underwent surgery for glioma infiltrating the precuneus. They tested a large number of neuropsychological functions prior to, 5 days after, and 3 months after the surgery. However, the main aim of the study was to assess the BADs that were frequently observed in these patients, mostly at the acute stage. Seven of the patients showed BADs, which allowed Herbert et al. to functionally distinguish the antero-dorsal and the postero-dorsal precuneal regions. In addition, they mapped the functional connectivity of these two anatomical seeds in healthy controls. Herbert et al. established that the resection

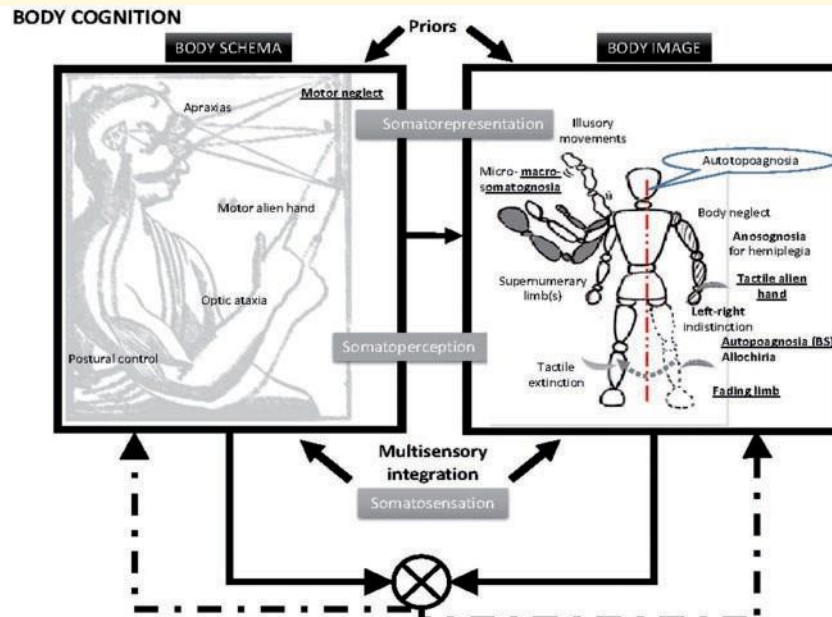


Figure 1 Classification of body schema and body image disorders along the dimension proposed by Longo et al. (2010). 'Somatosensation' corresponds to primary sensory processing, 'somatopercception' to the localization of somatic and postural stimuli subtended by the parietal lobes, and 'somatoprepresentation' to general semantic knowledge and body consciousness about arrangement and metric properties of body parts subtended by the frontoparietal network. Schematic representation of their functional relationship based on Rossetti et al. (2005) and Pitron et al. (2018).

cavity of the seven patients showing BADs always included the antero-dorsal part of the precuneus. The resting state analysis revealed that this antero-dorsal region is involved in a broad sensorimotor network, suggesting that body schema disorders may result in body image ones. There are indeed complex interactions between body schema and body image but the body schema seems to have some primacy over the body image (Rossetti et al., 2005; Pitron et al., 2018). The most frequent BADs observed by Herbet et al. were tactile alien hand, fading limb, motor neglect and tactile autotopagnosia. Moreover, these symptoms were often associated (Patients P2 and P11 present both tactile alien hand and fading limb, Patient P6 presents motor neglect, tactile alien hand and autotopagnosia, Patient P14 shows tactile alien hand and autotopagnosia). What are the mechanisms underlying these typically precuneus-related BADs?

When a limb is visible, its proprioceptive and visual localizations will differ slightly but will be integrated into an averaged position estimate.

In the absence of direct vision of the limb, this position estimate will drift toward the proprioceptive location. This body schema perturbation is revealed by the progressive movement drift repeatedly observed toward the same non-random location when a healthy individual alternates pointing movements between two visual targets in the dark (Smeets et al., 2006). When a large location mismatch is experimentally induced between vision and proprioception in healthy subjects, it has been shown to be resolved by selective fading of the affected limb (Hogendoorn et al., 2009) or to impair tactile perception on this limb (Folegatti et al., 2009). Reciprocally, while touch may not provide additional information about finger position in space, as fingertip tactile stimuli should remain independent from the postural configuration of the upper limb, additional tactile information nevertheless improves proprioceptive localization (Mikula et al., 2018). This may be due to the fact that tactile and proprioceptive information are ultimately coded within the same population of

posterior parietal neurons within high level spatial representations. Antero-dorsal precuneus damage may affect multisensory integration and specifically lead the visual and proprioceptive experiences of a limb to largely depart from each other. Consequences may include feelings of strangeness when the limb is visible or of illusory movement when vision of the limb is prevented inducing a large position estimate drift. Moreover, if the limb proprioceptive representation has low weighting, its perception when visual feedback is removed may fade and it may disappear not only from body image but also from body schema (fading limb and motor neglect, respectively). Such neurologically induced visual-proprioceptive mismatch also affects tactile perception on the limb concerned. If the proprioceptive limb representation is unstable, it may result in tactile autotopagnosia. If it fades from body image, it may produce tactile alien hand.

When an additional primary somatosensory deficit is present, as in Patient P2 of Herbet et al. whose

Glossary

Alien hand syndrome: A deficit in recognizing a hand as one's own when its view is occluded. Herbet et al. describe a tactile version in which they apply tactile stimuli to a patient's unseen limb, and the patient does not feel that the stimuli have been applied to his or her own body. A 'motor alien hand' refers to the occurrence of purposeful movements that are unintended. When these movements are antagonistic to the other hand, they are described as an 'anarchic hand'. Patients may also experience a feeling of having supernumerary limbs.

Apraxias: Patients with apraxias have difficulty with more complex movements (tool use, dressing, bathing, writing, drawing, etc).

Autotopoagnosia: Refers to patients who are impaired at pointing to parts of their own body named by an experimenter. Herbet et al. describe a tactile version of autotopoagnosia, where patients are asked to name unseen body parts that receive tactile stimulation. This deficit does not necessarily apply to others' body parts (heterotopoagnosia).

Body image: Typically refers to the mental representation of one's own body, arising from all sources of sensory and cognitive information, whereas body schema is used to describe the unconscious use of sensory information by the motor system to maintain body posture and produce accurate movements. Brain lesions may result in deficits for either or both types of body representation.

Fading limb: Corresponds to a subjective experience in which a limb that cannot be seen drifts in position, before its perception fades from consciousness.

Hypokinesia and bradykinesia: Slowness in the initiation and execution, respectively of goal-directed movements toward the contralesional side.

Micro- and macro-somatognosia: Enlarged or reduced perception of body part size, whereas hemiasomatognosia describes the loss of perception for one side of the body, which may lead to somatoparaphrenia, i.e. a delusional belief that a paralysed body part belongs to someone else.

Motor neglect: A peculiar manifestation of unilateral neglect, in which patients fail to spontaneously use their contralesional limb in the absence of any motor or somatosensory deficits. As for spatial neglect this condition is typically seen following right hemisphere lesions. For example, a patient may struggle to remove an item from its packaging using only one hand, even though they can perform the task easily when instructed to use both hands.

Optic ataxia: In the absence of a primary sensory or motor deficit, patients with optic ataxia have difficulty with reaching and grasping movements.

Personal neglect: Disregard for and decreased exploration of the contralesional half of the body. Typically, the left part of the face is not shaved or made up.

Precuneus: Medial part of the posterior parietal cortex, between the occipital (cuneus) and the anterior parietal (paracentral lobule) cortices, well located for visual-somatosensory integration.

Tactile extinction: Simultaneous tactile stimulation of the two sides of the body results in the disappearance of the otherwise normal contralesional sensation, whereas in allochiria a contralesional stimulus is referred to the ipsilesional side.

resection cavity extended to the paracentral lobule, macrosomatognosia may also be observed. We had the opportunity to follow a patient (Patient IK) who exhibited sustained BADs for several years following surgery for an extradural haemorrhage. These disorders notably included macrosomatognosia of the right upper limb, in association with tactile autotopoagnosia (without heterotopoagnosia) and tactile but also motor alien hand (which has also been reported after right precuneus damage, Darby et al., 2018). Patient IK's left parietal cortex lesion included the precuneus, and it also impaired primary proprioceptive function in isolation. During tactile examination with a blindfold, Patient IK exhibited fully normal thresholds but he would often complain that he had no idea where the stimulus was applied. He would even sometimes burst out: 'you cannot touch me here because it is not on my body!'. Over several years, Patient IK spontaneously reported the perception of

three right upper limbs: a visual one, an imagined one and a somatosensory one. These three hands were more independent of each other during the night, when the patient was lying in bed in the dark. Interestingly, Patient IK also initially complained of hand levitation, i.e. his contralesional hand would raise itself in the air and remain floating until he looked at it. In daily life, he could be surprised by the sight of his right hand grasping the mirror while he was driving his car, as if his hand was levitating devoid of any notion of agency. In other experimental conditions, the patient was asked to sit at a table, with his right hand hidden under the table. An examiner sat behind him, and placed his own hand on the table, to the right of the patient. Within a few seconds, Patient IK's body cognition took ownership of the alien hand despite his knowing that this was obviously impossible. He was horrified or disgusted whenever he saw the alien right hand moving while his own remained hidden. In addition, the

patient often became distressed when the examiner removed his arm from the table without having warned him. In short, this patient was facing conflicting perceptions and representations at different levels (sensory and cognitive) in the absence of vision of his own hand.

Contrary to the general idea that BADs are predominantly associated with neglect and right hemisphere damage, the literature, in line with the Herbet et al. data, does not provide evidence for such hemispheric lateralization. This is consistent with the idea that BADs result from body schema deficits that are usually not lateralized to one hemisphere (like optic ataxia). One might think that this absence of hemispheric lateralization of the BADs in Herbet et al. may be related to the fact that the deficits exhibited by their patients are predominantly present at the acute post-operative stage. Indeed, in the case of neglect, acute studies often report that symptoms are as frequent following lesions of either hemisphere. It is

only at the chronic stage that the right hemisphere specialization is revealed. One may speculate that the same phenomenon applies to BADs. However, two of four patients presenting with BADs at 3 months post-surgery had a left hemispheric lesion in Herbet et al. and Patient IK showed chronic BADs for several years also following a left hemispheric lesion. This suggests that BADs may not be lateralized even at the chronic stage. Unlike some overt impairments such as dressing apraxia, BADs may alter body cognition more implicitly and remain undetected. Following Herbet et al. it is therefore recommended to researchers and clinicians to carefully interview and examine patients for BADs when the antero-dorsal precuneus is lesioned, irrespective of the hemispheric side.

Laure Pisella,¹ Laurence Havé^{1,2} and Yves Rossetti^{1,3}

- 1 ImpAct Team, Lyon Neuroscience Research Center, Villeurbanne, France
- 2 Hôpital d'instruction des armées Desgenettes, Lyon, France

3 Plate-forme Mouvement et Handicap, Centre de Recherche en Neurosciences de Lyon, Bron, France

Correspondence to: Laure Pisella
E-mail: laure.pisella@inserm.fr

doi:10.1093/brain/awz187

Competing Interests

The authors report no competing interests.

References

- Blangero A, Ota H, Delporte L, Revol P, Vindras P, Rode G, et al. Optic ataxia is not only 'optic': impaired spatial integration of proprioceptive information. *Neuroimage* 2007; 36 (Suppl 2): T61–8.
- Darby RR, Joutsa J, Burke MJ, Fox MD. Lesion network localization of free will. *Proc Natl Acad Sci USA* 2018; 115: 10792–7.
- Folegatti A, de Vignemont F, Pavani F, Rossetti Y, Farnè A. Losing one's hand: visual-proprioceptive conflict affects touch perception. *PLoS One* 2009; 4: e6920.

- Herbet G, Lemaitre A-L, Moritz-Gasser S, Cochereau J, Duffau H. The antero-dorsal precuneal cortex supports specific aspects of bodily awareness. *Brain* 2019; 142: 2207–14.
- Hogendoorn H, Kammers MP, Carlson TA, Verstraten FA. Being in the dark about your hand: resolution of visuo-proprioceptive conflict by disowning visible limbs. *Neuropsychologia* 2009; 47: 2698–703.
- Longo MR, Azañón E, Haggard P. More than skin deep: body representation beyond primary somatosensory cortex. *Neuropsychologia* 2010; 48: 655–68.
- Mikula L, Sahnoun S, Pisella L, Blohm G, Khan AZ. Vibrotactile information improves proprioceptive reaching target localization. *PLoS One* 2018; 6; 13: e0199627.
- Pitron V, Alsmith A, de Vignemont F. How do the body schema and the body image interact? *Conscious Cogn* 2018; 65: 352–8.
- Rossetti Y, Rode G, Farnè A. Implicit body representation in action: a neuropsychological approach. In: De Preester H, Knockaert V, editors. *Body Image and Body Schema*. Benjamins, Amsterdam; 2005. p. 111–115.
- Smeets JB, van den Dobbelaars JJ, de Grave DD, van Beers RJ, Brenner E. Sensory integration does not lead to sensory calibration. *Proc Natl Acad Sci USA* 2006; 103: 18781–6.
- Wolpert DM, Goodbody SJ, Husain M. Maintaining internal representations: the role of the human superior parietal lobe. *Nat Neurosci* 1998; 1: 529–33.