



HAL
open science

“Idiopathic Eosinophilic Vasculitis”: Another Side of Hypereosinophilic Syndrome? A Comprehensive Analysis of 117 Cases in Asthma-Free Patients

Guillaume Lefèvre, Amélie Leurs, Jean-Baptiste Gibier, Marie-Christine Copin, Delphine Staumont-Sallé, Frédéric Dezoteux, Cécile Chenivresse, Benjamin Lopez, Louis Terriou, Eric Hachulla, et al.

► To cite this version:

Guillaume Lefèvre, Amélie Leurs, Jean-Baptiste Gibier, Marie-Christine Copin, Delphine Staumont-Sallé, et al.. “Idiopathic Eosinophilic Vasculitis”: Another Side of Hypereosinophilic Syndrome? A Comprehensive Analysis of 117 Cases in Asthma-Free Patients. *Journal of Allergy and Clinical Immunology: In Practice*, 2020, 8 (4), pp.1329-1340.e3. 10.1016/j.jaip.2019.12.011 . hal-03869830

HAL Id: hal-03869830

<https://hal.science/hal-03869830v1>

Submitted on 29 Nov 2024

HAL is a multi-disciplinary open access archive for the deposit and dissemination of scientific research documents, whether they are published or not. The documents may come from teaching and research institutions in France or abroad, or from public or private research centers.

L’archive ouverte pluridisciplinaire **HAL**, est destinée au dépôt et à la diffusion de documents scientifiques de niveau recherche, publiés ou non, émanant des établissements d’enseignement et de recherche français ou étrangers, des laboratoires publics ou privés.



Distributed under a Creative Commons Attribution - NonCommercial 4.0 International License

1 **“Idiopathic eosinophilic vasculitis”: another side of hypereosinophilic**
2 **syndrome? A comprehensive analysis of 117 cases in asthma-free patients**

3 Guillaume Lefèvre, MD, PhD ^{a,b,c,d*}, Amélie Leurs, MD ^{c*}, Jean-Baptiste Gibier, MD ^{a,e},
4 Marie-Christine Copin, MD, PhD ^{a,e}, Delphine Staumont-Sallé, MD, PhD ^{a,f}, Frédéric
5 Dezoteux, MD ^{a,f}, Cécile Chenivesse, MD, PhD ^{a,g}, Benjamin Lopez, MD ^b, Louis Terriou,
6 MD ^{a,b,c}, Eric Hachulla, MD, PhD ^{a,c}, David Launay, MD, PhD ^{a,c}, Nicolas Etienne, MD ^{a,c},
7 Myriam Labalette, MD, PhD ^{a,b}, Pascal DeGroot, MD ^{a,h}, François Pontana, MD, PhD ^{a,i},
8 Thomas Quemeneur, MD ^j, Pierre-Yves Hatron, MD, PhD ^{a,c}, Nicolas Schleinitz, MD, PhD
9 ^{a,k}, Jean-François Viallard, MD, PhD ^{a,l}, Mohamed Hamidou, MD, PhD ^{a,m}, Thierry Martin,
10 MD, PhD ^{a,n}, Chafika Morati-Hafsaoui, MD^{a,o}, Matthieu Groh, MD ^{a,p}, Marc Lambert, MD,
11 PhD ^c, Jean-Emmanuel Kahn, MD, PhD ^{a,q} for the CEREO – French National Reference
12 Center for Hypereosinophilic Syndromes

13 * both authors contributed equally to this work

- 14 a. Centre de Référence National des Syndromes Hyperéosinophiliques (CEREO), France
15 b. Univ. Lille, CHU Lille, Institut d’Immunologie, F-59000 Lille,
16 c. Univ. Lille, CHU Lille, Département de Médecine Interne et Immunologie Clinique,
17 Centre de Référence des Maladies Auto-immunes Systémiques Rares du Nord et
18 Nord-Ouest de France (CeRAINO), F-59000 Lille, France
19 d. Univ. Lille, Inserm, CHU Lille, U995 - LIRIC - Lille Inflammation Research
20 International Center, F-59000 Lille, France
21 e. Univ. Lille, CHU Lille, Institut de Pathologie, Centre de Biologie Pathologie, F-59000
22 Lille, France
23 f. Univ. Lille, CHU Lille, Département de Dermatologie, F-59000 Lille, France
24 g. Univ. Lille, CHU Lille, Département de Pneumologie et Immuno-Allergologie, Centre
25 de compétence Maladies Pulmonaires Rares, F-59000 Lille, France

- 26 h. Univ. Lille, CHU Lille, Département de Cardiologie, Institut National de la Santé et
27 de la Recherche Médicale, U1019, F-59000 Lille, France
- 28 i. Univ. Lille, CHU Lille, Département de Radiologie Cardiovasculaire, F-59000 Lille,
29 France
- 30 j. Centre Hospitalier de Valenciennes, Département de Médecine Interne, F-59300
31 Valenciennes, France
- 32 k. Aix-Marseille Univ, APHM, Département Médecine Interne Hôpital de la Timone,
33 Marseille, France.
- 34 l. CHU Bordeaux, Service de Médecine Interne, Hôpital Haut Lévêque, Pessac , France.
- 35 m. CHU Nantes, Service de Médecine Interne, CHU Hôtel-Dieu, Nantes, France
- 36 n. CHU Strasbourg, Service d'immunologie clinique Nouvel Hôpital Civil, F-67091
37 Strasbourg, France.
- 38 o. CH Annecy Genevois, Service de Médecine Interne, Annecy, France.
- 39 p. Hôpital Foch, Département de Médecine Interne, F-92151 Suresnes, France
- 40 q. Hôpital Ambroise Paré, Service de Médecine Interne, Assistance Publique-Hôpitaux
41 de Paris, F-92100 Boulogne Billancourt, France

42

43 **Corresponding author:**

44 Guillaume Lefèvre MD, PhD, Institut d'Immunologie, Centre de Biologie-Pathologie-
45 Génétique, CEREO, Centre de Référence Maladies Rares des Syndromes
46 Hyperéosinophiliques, CHRU Lille, F-59037 Lille cedex, France; tel.: +33-320-445-572; fax:
47 + 33-320-446-954; e-mail: guillaume.lefevre@chru-lille.fr

48

49 **Manuscript word count:**

50 4363

51 **Tables count:** 1

52 **Figures count:** 5

53 **Funding:** This research did not receive any specific grant from funding agencies in the
54 public, commercial, or not-for-profit sectors.

55

56 **Key words:** eosinophilic disorder, eosinophilic vasculitis, eosinophilic granulomatosis with
57 polyangiitis; hypereosinophilic syndrome.

58

59 **Conflicts of interest:** GL reports consulting or advisory fees from Shire, Astra-Zeneca and
60 Sanofi-Genzyme, research grant and travel and accommodation expenses from Octapharma,
61 Shire and GSK. CC reports consulting or advisory fees from Astra-Zeneca, Teva, GSK and
62 Sanofi-Genzyme. MH: Travel and accommodation expenses from GSK and Novartis. JFV
63 reports consulting and advisory fees from Shire and LFB. DL reports consultant
64 arrangements, research grant and travel and accommodation from Actelion, GSK,
65 Octapharma, Pfizer and Shire. MG reports consulting or advisory fees from Astra-Zeneca and
66 GlaxoSmithKline. JEK reports consulting or advisory fees from Astra-Zeneca, consulting or
67 advisory fees, research grant and travel and accommodation expenses from GSK.

68 **ABSTRACT**

69 **Background:** The absence of asthma may rule out a diagnosis of eosinophilic granulomatosis
70 with polyangiitis (EGPA) in patients with hypereosinophilic syndrome (HES) and features of
71 vasculitis.

72 **Objective:** To describe eosinophilic vasculitis (EoV) as a possible manifestation of HES in
73 asthma-free patients.

74 **Methods:** We screened our hospital database and the literature for patients with HES who
75 met the following four criteria: (i) histopathologic or clinical features of EoV (biopsy-proven
76 vasculitis with predominant eosinophilic infiltration of the vessel wall and/or features of
77 vasculitis with tissue and/or blood hypereosinophilia (>1.5 G/L)), (ii) no other obvious causes
78 of reactive eosinophilia, organ damage, and vasculitis, (iii) the absence of antineutrophil
79 cytoplasmic antibodies, and (iv) the absence of current asthma.

80 **Results:** Ten of our 83 (12%) asthma-free patients with HES and 107 additional cases in the
81 literature met the criteria for EoV. After a critical analysis of the patients' clinical and
82 laboratory characteristics and outcomes, we identified 41 cases of single-organ EoV (coronary
83 arteritis: n=29; temporal arteritis: n=8; cerebral vasculitis: n=4). Of the 76 remaining patients
84 with EoV, the most frequent manifestations (>10%) were cutaneous vasculitis (56%),
85 peripheral neuropathy (24%), thromboangiitis-obliterans-like disease (16%), fever (13%),
86 central nervous system involvement (13%), deep venous thrombosis (12%), and nonasthma
87 lung manifestations (12%). Blood hypereosinophilia >1.5 G/L was observed in 79% of
88 patients and necrotizing vasculitis was observed in 44%.

89 **Conclusions:** Our results suggest that idiopathic EoV (HES-associated vasculitis) can be
90 classified as an eosinophilic-rich, necrotizing, systemic form of vasculitis that affects vessels
91 of various sizes in asthma-free patients.

92

93 **KEY MESSAGES**

94

95 **1. What is already known about this topic?**

96 In the context of eosinophilia, systemic vasculitis is mainly considered to be a hallmark of
97 eosinophilic granulomatosis with polyangiitis (EGPA). Numerous single cases of eosinophilic
98 vasculitis (EoV) have been reported in asthma-free patients.

99 **2. What does this article add to our knowledge?**

100 Idiopathic EoV is an eosinophil-rich, non-granulomatous necrotizing vasculitis occurring in
101 asthma-free ANCA-negative patients. Along with tissue infiltrates, fibrosis and/or thrombosis,
102 EoV should be considered as an additional manifestation of eosinophil-related organ damage
103 occurring in HES.

104 **3. How does this study impact current management guidelines?**

105 We propose some easy-to-apply criteria for idiopathic EoV, taking the differential diagnoses
106 into account according to the current classifications. As a HES-related vasculitis, idiopathic
107 EoV treatment may be copied from HES, including anti-interleukin-5 therapies.

108

109 **ABBREVIATIONS LIST**

110 AEC, absolute eosinophil count

111 ANCA, antineutrophil-cytoplasmic-antibody

112 CEREO, French National Reference Centre for HES

113 CHCC2012, 2012 Revised International Chapel Hill Consensus

114 CRP, C-reactive protein

115 CSs, corticosteroids

116 EGPA, eosinophilic granulomatosis with polyangiitis

- 117 EoV, eosinophilic vasculitis
- 118 ESR, erythrocyte sedimentation rate
- 119 GERMOP/ERS, Groupe d'Etudes et de Recherche sur les Maladies Orphelines
Pulmonaires/European Respiratory Society
- 121 HES, hypereosinophilic syndrome
- 122 IV, intravenous
- 123 MM, mononeuritis multiplex
- 124 PAN, polyarteritis nodosa
- 125 SO-EoV, single-organ EoV
- 126 TAO, thromboangiitis obliterans

127 **1. Introduction**

128 Blood and tissue eosinophilia are reported in many inflammatory, allergic, infectious and
129 neoplastic disorders. Whatever the underlying disease, the clinical manifestations and organ
130 damage induced by tissue eosinophilia are heterogeneous and rarely specific. When both
131 clonal and the most frequent causes for reactive eosinophilia have been ruled out, the
132 physician should consider the diagnosis of idiopathic hypereosinophilic syndrome (HES).
133 HES is defined by organ damage and/or dysfunction attributable to tissue eosinophilia when
134 the absolute eosinophil count (AEC) is persistently over 1.5 G/L (1,2). Eosinophils' mediators
135 can promote inflammation, fibrosis and thrombosis by activating and damaging endothelial
136 cells, as in endomyocardial fibrosis. Histology-based and animal studies providing evidence
137 for eosinophil-related endothelial damage in the cavities of the heart are scarce (3,4).
138 Moreover, few data are available as to a potential eosinophil-toxicity of peripheral vessels
139 (5). However, the toxic effects of eosinophils and their products on endothelial cells may lead
140 to similar types of vessel damage (for an extensive review, see (6))

141 In the context of eosinophilia, vasculitis is mainly considered to be a hallmark of eosinophilic
142 granulomatosis with polyangiitis (EGPA) (7–9). The latter is defined as an eosinophil-rich,
143 necrotizing, granulomatous vasculitis affecting small-to-medium vessels and associated with
144 asthma and eosinophilia (9). Although EGPA is classified as an antineutrophil-cytoplasmic-
145 antibody (ANCA)-associated vasculitis, only 30% of affected patients actually have ANCAs.
146 After eosinophilia and granuloma, the third important characteristic of EGPA is asthma (9),
147 which is usually a severe, late-onset form (10). Differentiating between HES and ANCA-
148 negative EGPA can be challenging (11,12). A recent European Respiratory Society and
149 European Federation of Internal Medicine-endorsed nomenclature suggested to restrict the use
150 of “EGPA” to patients with eosinophilic asthma and genuine features of vasculitis (either
151 biopsy-proven or strong clinical surrogates *e.g.* palpable purpura, coronaritis, mononeuritis

152 multiplex (MM)) (11,12). We recently performed a comparative study of 166 patients meeting
153 criteria for EGPA and/or HES and demonstrated that C-reactive protein (CRP) level was a
154 sound diagnostic biomarker able to accurately differentiate HES vs. EGPA (with low levels
155 being suggestive of HES). In the latter study, we unexpectedly evidenced that several asthma-
156 free and ANCA-negative HES patients had biopsy-proven eosinophilic vasculitis (EoV)
157 and/or clinical features of vasculitis (including cerebral vasculitis and MM (13). Hence, we
158 sought to determine whether EoV could be distinguished from primary vasculitis (*e.g* EGPA)
159 and be considered as an additional manifestation of HES.

160

161 **2. Methods**

162 *2.1. Personal cases*

163 We performed a retrospective, observational, single-center study at Lille University Hospital
164 (Lille, France), which is a member of the French National Reference Centre for HES
165 (CEREO). Details of all the cases have been published recently (13). In the present study, we
166 considered the subset of asthma-free patients meeting criteria for HES (1).

167

168 *2.2. Systemic literature review*

169 We searched both PubMed and EMBase databases for original articles, case reports, and
170 letters to the editor reporting cases of EoV published between January 1978 and December
171 2018 (see the selection process in this article's Online Repository).

172 After considering the 2012 Revised International Chapel Hill Consensus (CHCC2012) (9), the
173 nomenclature for EGPA recently proposed by the Groupe d'Etudes et de Recherche sur les
174 Maladies Orphelines Pulmonaires/European Respiratory Society (GERMOP/ERS) taskforce
175 (11), and the 2011 consensus proposal on criteria and classification of eosinophilic disorders
176 (1), we selected patients with idiopathic EoV meeting the following criteria:

- 177 (i) At least one of the following histopathologic or clinical features of vasculitis:
- 178 a. Any organ manifestation associated with biopsy-proven necrotizing vasculitis
- 179 and predominant eosinophilic infiltration of the vessel wall, and/or
- 180 b. Any organ manifestation associated with a biopsy demonstrating perivascular
- 181 eosinophilic infiltrates, and leukocytoclastic capillaritis and/or eosinophilic
- 182 infiltration of the vessel wall, and/or
- 183 c. Any case of blood hypereosinophilia >1.5 G/L associated with a clinical
- 184 manifestation consistent with the involvement of vasculitis, e.g. palpable
- 185 purpura, myocardial infarction caused by proven coronaritis, cerebral
- 186 vasculitis, MM, and digital necrosis.
- 187 (ii) The absence of other disorders or conditions causing eosinophil-induced organ
- 188 damage and secondary vasculitis, i.e. underlying inflammatory, infectious
- 189 (hepatitis B or C viruses, human immunodeficiency viruses, etc.), neoplastic or
- 190 drug-induced disorders (including cholesterol embolization syndrome)
- 191 (iii) The absence of ANCA, and
- 192 (iv) No persistent/active asthma on diagnosis, and no history of persistent unexplained
- 193 cough, dyspnea, or wheezing.

194 Isolated, perivascular eosinophilic infiltration, isolated microthrombi, and multiple arterial or

195 venous thromboses in the absence of vessel wall abnormalities were not considered to be

196 features of vasculitis. Features of vasculitis reported in the setting of FIP1L1-PDGFRA-

197 related chronic eosinophilic leukemia, CD3-CD4+ T cell-associated lymphocytic HES and

198 other identified causes of “reactive” (e.g. drug-induced, parasitic infection or malignancy)

199 eosinophilia were not collected in this study.

200

201 3. Results

202 *3.1. Personal case series*

203 Our retrospective, systematic analysis of local cases of systemic eosinophilic disorders
204 identified 82 ANCA-negative, asthma-free patients with HES. Ten of these patients (12%)
205 met the criteria for EoV; the patients' clinical and histopathologic characteristics are
206 summarized in Table I.

207 Five of the 10 patients presented with biopsy-proven, organ-restricted EoV and slight-to-
208 massive tissue eosinophilia: cutaneous vasculitis with digital necrosis (patient #1), livedo
209 racemosa with persistent angioedema (#2), ischemic eosinophilic colitis (#3), chronic
210 pneumoniae (#4), and pruritic erythematous papules with eosinophilic-leukocytoclastic
211 vasculitis (#5). Biopsies from patients #1-4 were retrieved for analysis (Figure 1). Although
212 material for the detection of eosinophil granules in vasculitis areas was available for 2 patients
213 only (#3-4), extracellular eosinophil granules in the vessel wall were detected in both cases
214 (Figure E1).

215 In all 5 remaining cases of patients presenting with systemic EoV (MM, n=4; cerebral
216 vasculitis, n=1), features of vasculitis were also associated with non-vasculitic eosinophilic
217 manifestations, *e.g.* myositis, eosinophilic gastroenteritis, and erythematous papules. (Table
218 I).

219

220 *3.2. Systematic review of the literature*

221 EMBase and MEDLINE searches are detailed in this article's Online Repository (Figure E2).
222 The selected publications reported on a total of 107 asthma-free patients meeting the criteria
223 for EoV (14–90).

224 Overall, considering all 117 identified cases of EoV (our 10 cases + 107 in the literature
225 review), the male/female ratio was 1.05 but varied according to the organ involved (see
226 below). The median [interquartile range] age was 43 [30.5;55]. An exact AEC was quoted for

227 83 cases, and the AEC was reported as being normal or elevated for 4 other cases; on this
228 basis, an AEC >0.5 G/L was observed in 70 of the 87 cases (80%), and an AEC >1.5 G/L was
229 observed in 57 of the 83 cases (69%). In 70 of the 117 cases, EoV was limited to a single
230 organ – predominantly isolated coronary EoV (n=29) (Figure E3).

231

232 *3.3. Description of personal and previously published cases of EoV as a function of the*
233 *organ involved.*

234 *3.3.1. Cutaneous EoV*

235 Clinical findings. Forty patients displayed cutaneous EoV. Several types of lesions were
236 described in varying levels of detail in 35 cases. The most common features were pruritic
237 papular lesions or urticaria (n=24), purpuric papules or infiltrated purpura (n=10),
238 angioedema or localized swelling (n=9), digital necrosis (n=5, with a thromboangiitis
239 obliterans (TAO)-like disease in 4 cases), pruritic erythema (n=4), erythematous nodular
240 lesions (n=4), skin ulcers (n=3), and alopecia (n=1). Only one case of livedo racemosa,
241 associated with persistent angioedema on the face and neck, was reported (personal
242 observation #2). The skin lesions were located variously on the hands & fingers (n=21 cases),
243 arms (n=15), legs (n=28), feet (n=16), trunk (n=12), buttocks (n=4) and face or neck (n=9).

244 Histopathological findings. In addition to eosinophil infiltrates in the vessel wall, the main
245 associated characteristics were perivascular eosinophil infiltrates in all 40 cases, and
246 necrotizing vasculitis in 23 cases (57.5%). We noted reports of fibrinoid necrosis in 14 cases
247 (35%), leukocytoclasia in 9 (22.5%), and granulomatous lesions in two (5%).

248

249 *3.3.2. Coronary arteritis and myocarditis*

250 Clinical findings. Heart involvement was reported in 36 cases, restricted to coronary arteries
251 in 35 cases. We also noted acute myocarditis without coronary involvement in a patient with

252 systemic EoV (with MM, cerebral inflammatory lesions, and chronic rhinosinusitis with
253 polyps) (case #6). . Thirty-one (89%) patients died, and 26 of them (74%) died in a context of
254 sudden cardiac arrest. Previous chest pain was reported in 20 of the 31 cases (57%).

255 Radiological and histopathological findings. Some cases had one or more macroscopic
256 arterial lesions, such as dissection in 20 cases (with no atheroma or features of Marfan's
257 disease) (14,22,29,33,39,43,51,62,71,72), coronary aneurysm in 5 cases (of which 4 had
258 systemic disease) (36,47,61,64,74), and/or intimal fibrosis with luminal obstruction in 6 cases
259 (20,66,74,76). Coronary spasm was confirmed by coronary angiography in 1 case (76). Aortic
260 aneurysm was observed in two cases in which vasculitis and/or eosinophilic infiltrates in the
261 aortic wall were also reported (36,64), and one case featured aneurysmal carotid arteries with
262 vessel wall thrombi (47). According to the available autopsy data (n=29), predominantly
263 eosinophilic infiltrates were found in the adventitia and/or periadventia in 23 cases, in the
264 media in 5, in the intima in 2, and at unspecified sites in 2. Giant cells (n=3) and granuloma
265 (n=2) were rarely observed. Myocarditis (defined as extensive eosinophilic infiltration of the
266 myocardium) was associated with coronaritis in 2 cases (40,74), and extensive periadvential
267 eosinophilic infiltration of the adjacent myocardium was observed in one case (39). Focal or
268 widespread myocardial fibrosis was also reported in 7 cases (20,51,72,74,76), and a
269 subendocardial distribution was indicated in 3 of these (76).

270

271 3.3.3. *Peripheral nervous system*

272 Clinical findings. Eighteen patients had peripheral nervous system involvement. A large
273 majority of cases featured MM (n=15), 2 with distal symmetric polyneuropathy, and one with
274 undefined neuropathy.

275 Histopathological findings. Biopsy-proven EoV was observed in the skin (n=11), muscle
276 (n=1) and gallbladder (n=1).

277

278 3.3.4. *Temporal arteritis*

279 Clinical findings. Thirteen cases presented temporal arteritis. The reported symptoms were
280 headaches and/or painful temporal swelling (n=5) (16,19,26,63,87), transient loss of vision
281 (n=2) (19,26), pain-free temporal swelling (n=2) (18,25,27,45,59), and scalp tenderness and
282 jaw claudication (n=2) (31,89).

283 Histopathological findings. Giant cells were observed in two patients (aged 23 and 30,
284 respectively), (18,25), and granuloma was observed in another case (45). Only 2 of the 13
285 patients had an elevated erythrocyte sedimentation rate (ESR), although a histopathologic
286 examination did not show any features of giant cell arteritis (31,89). The main types of arterial
287 damage were mild-to-severe, occlusive intimal fibrosis and thickening (n= 10) (16,18,19,25–
288 27,45,59,63), aneurysms (n=2) (26,87), and pseudoaneurysms (n=1) (18). Focal thromboses
289 were also reported (n=6) (16,18,19,26,63,87). In histopathologic descriptions, predominantly
290 eosinophilic infiltrates were located in the media (n=1) (25), the intima (n=1), (45) in all 3
291 layers (n=5) (16,18,27,63,87), or at unspecified sites (n=6) (19,26,31,59,89). Perivascular
292 eosinophils were reported in 3 cases (18,26,59).

293

294 3.3.5. *TAO-like disease*

295 Clinical findings. Twelve cases of TAO-like disease were identified. The typical diagnostic
296 features of TAO were Raynaud's phenomenon (n=9) (16,27,28,30,34,42,65,87), absent and/or
297 diminished distal pulses (n=3) (27,28,42), and digital necrosis (n=10)
298 (16,27,28,30,34,42,48,77,87). Six patients were described as heavy smokers (16,27,30,34,42,48).

299 Radiological and histological findings. When reported, the angiography, Doppler ultrasound
300 or other imaging results always suggested the presence of TAO, with various obstructions
301 and/or widespread alterations in blood flow in distal arteries (n=11)

302 (16,28,30,34,42,44,48,65,77,87). In two cases, an arterial biopsy confirmed the presence of EoV
303 (16,30). In 7 cases, a biopsy confirmed the presence of EoV at another site, including the skin
304 (n=4) (27,34,48,65), the superficial temporal artery (n=3) (16,27,87) and muscle (n=1) (48).

305

306 3.3.6. *Central nervous system*

307 Clinical findings. Eight cases of cerebral vasculitis were identified. In one case, EoV also
308 involved the spinal cord (81).

309 Radiological and histological findings. Overall, the radiologic findings included an irregular
310 enhancement of the brain parenchyma (27), infarction due to arterial dissection (69) and
311 intracerebral hemorrhage on a computerized tomography scan (32,52), multiple arterial
312 narrowing on angiography (52), ischemic lesions in multiple brain areas (case #6), T2/FLAIR
313 hyperintense lesions with gadolinium enhancement on T1-weighted magnetic resonance
314 imaging MRI (32,56,70,81). In the four cases of isolated cerebral vasculitis, the blood AEC
315 was normal; eosinophilia in the cerebrospinal fluid was found in only one case (32), and the
316 diagnosis required a brain biopsy in all cases.

317

318 3.3.7. *Deep venous thrombosis*

319 Clinical findings. Nine patients with EoV developed deep vein thrombosis (DVT). It
320 variously affected the hepatic veins (n=4) (23,80,82), portal vein (n=4) (58,80,90), lower limbs
321 (n=4) (46,77,80), upper limbs (77), renal veins (46) and pulmonary arteries (n=3) (46,58,77).

322 Histopathological findings. Biopsy-proven EoV was observed in the venous wall in two cases
323 (55,80) and at other sites in all other cases.

324

325 3.3.8. *Lung and ENT involvement*

326 Clinical findings. As defined in our inclusion criteria, none of the patients had current asthma.
327 Only one patient of our series (personal case #2) and one patient identified in the literature
328 review had a history of childhood asthma (48). Only 7 patients had a history of chronic
329 sinusitis and/or allergic rhinitis (16,24,58,78,79,83) (case #6). None of the patients in this series
330 was reported as having developed asthma after the diagnosis of EoV. Nine patients had lung
331 involvement. Cough and/or dyspnea were reported in 7 patients and were associated with
332 hemoptysis in 2 cases.

333 Radiological and histopathological findings. Lung infiltrates (n=6) (21,38,58,67,88,90)
334 associated with pleural effusion (n=1) (21) or nodular cavitary lung lesions (n=1) were
335 reported (17). In a context of blood eosinophilia (AECs ranging from 1 to 20.3 G/L),
336 bronchoalveolar fluid analysis was never performed to confirm alveolar eosinophilia.
337 However, a transbronchial lung biopsy detected EoV in one case (21), and EoV in the lung
338 was diagnosed in an autopsy study after a sudden cardiac death (40). Furthermore, biopsy-
339 proven EoV was found at other sites in all 7 cases (notably cutaneous EoV in 6 cases). Lastly,
340 two cases of isolated lung involvement and biopsy-proven lung EoV were reported: a case of
341 congenital interstitial lung disease with chylothorax (38), and one of our patients with fixed
342 lung infiltrates (personal case #2).

343

344 *3.3.9. Other cases with biopsy-proven vasculitis or clinical manifestations suggestive*
345 *of vasculitis*

346 Three patients developed manifestations of ocular disease encountered in systemic vasculitis:
347 retinal vasculitis (n=1) (84), scleritis (n=1) (24), and episcleritis (n=1) (21). Another patient
348 had an occluded central retinal artery, as a manifestation of vasculitis or an embolism (from
349 an aneurysm of the aortic sinus) (36). One patient developed isolated ischemic EoV of the
350 digestive tract (personal case #3).

351 In 6 cases with systemic disease, unexpected histological features of EoV were found in
352 organs that are not typical sites for vasculitic lesions, such as the gallbladder (n=2) (83,84),
353 urethra (n=1) (24), fascia (58), and thymus (17). Unexpected findings were also found in
354 cases of EoV limited to one organ, with one case of EoV associated with prostatitis (15), and
355 one case of eosinophilic fasciitis (86). Lastly, fever and arthralgia/arthritis were reported in 10
356 and 5 cases, respectively.

357

358 *3.3.10. Other non-vasculitic manifestations associated with EoV*

359 Fifteen patients developed other typical clinical manifestations of HES, such as skin lesions
360 (variously described as reddish plaques, erythema, swelling, erythematous papules,
361 subcutaneous nodules, skin rashes, etc.) (48,69,83,84) (personal cases #9 and 10), eosinophilic
362 fasciitis (52,69), arterial thrombosis (in the brain or the digestive tract) (34,46), liver nodules
363 and/or dysfunction (35,57), spleen enlargement and/or infiltration by eosinophils (23,69,74),
364 eosinophilic colitis (83) (case #9), eosinophilic meningoencephalitis (case #7), inflammatory
365 white matter lesions (case #8), and eosinophilic myositis (personal case #8). Biopsies were
366 collected in the great majority of these cases but no features of EoV were found. Lymph node
367 enlargement were also described in 7 cases but two of the latter had necrotizing EoV in lymph
368 nodes adjacent to areas of cutaneous or venous EoV (55,89). Lastly, two cases of renal
369 involvement were reported: a biopsy was not performed in the first case (despite the presence
370 persistent proteinuria and hematuria), and membranous glomerulonephritis (with no
371 eosinophilic infiltrates) was diagnosed in the second case (21,27).

372

373 *3.4. Treatments*

374 First-line treatments and short-term outcomes were reported for 40 cases of organ-restricted
375 EoV. In the 13 cases of skin-restricted EoV, corticosteroids (CSs; oral: n=9; topical: n=3;
376 intravenous (IV): n=1) were effective in all cases (Table E1).
377 Interestingly, 5 of the 6 cases of isolated temporal artery EoV did not relapse after surgical
378 excision and did not require treatment with CSs (CSs were given in one case, and no
379 information was available for the remaining case).
380 In the 19 other cases of organ-restricted EoV (cerebral vasculitis: n=4; MM: n=4; TAO-like
381 disease: n=4; pulmonary EoV: n=2; portohepatic DVT, prostatitis, fasciitis, ischemic colitis,
382 and coronaritis: n=1 each), partial or complete remission was obtained with CSs alone in 13
383 cases, with CSs and another treatment (cyclophosphamide, imatinib or plasma exchange) in 4,
384 and spontaneously in a case of isolated MM.

385 First-line treatments and short-term outcomes were reported for 42 cases of systemic EoV:
386 patients were variously treated with oral CSs (n=25), IV CSs and then oral CSs (n=7), topical
387 CSs alone (n=2) or oral CSs in combination with immunosuppressants in 5 cases
388 (cyclophosphamide: n=4; cyclosporine: n=1).

389 Medium-to-long term outcomes were reported in 62 of the 82 patients with either organ-
390 restricted or systemic EoV that had received at least one course of treatment. The length of
391 follow-up was hardly ever reported. One case (2%) had complete, spontaneous remission, 24
392 (39%) patients had complete remission and did not relapse during discontinuation, 16 (26%)
393 were treated with low-dose maintenance CSs alone, and 19 (31%) were treated with a
394 combination of a CSs and another treatment (with various levels of effectiveness; Table E1).
395 Interestingly, mepolizumab was efficient in all 3 treated patients that previously required
396 high-dose CSs and/or had failed to second-line immunosuppressants like cyclophosphamide
397 (n=1) or azathioprine (n=1). Only two deaths (3%) were reported: one in the context of
398 progressive disease and an infectious adverse event, and one death of unknown cause (n=1).

400 **4. Discussion**

401 Here, we report on the largest case series (n=10) and a comprehensive literature review of
402 patients with idiopathic EoV (n=107) after exclusion of EGPA, systemic vasculitides and all
403 other conditions associated with either reactive or clonal eosinophilia. We suggest a number
404 of easy-to-apply criteria for the differential diagnosis with other vasculitides, and advocate
405 that EoV (HES-associated vasculitis) should be considered both as an additional HES-
406 defining feature as well as an additional cause of secondary variable-vessel size vasculitis
407 (especially in the context of non-granulomatous features and mild systemic inflammation).

408 Firstly, we reported on 10 personal cases of EoV associated with unexplained
409 hypereosinophilia. We retrospectively made this diagnosis in two situations: a histopathologic
410 demonstration of an eosinophilic vasculitic process in at least one damaged organ, or (if a
411 histopathologic analysis was unavailable) a clinical manifestation consistent with an
412 eosinophilic vasculitic process. In the four available biopsies, we observed slight-to-massive
413 tissue infiltration of eosinophils (which is consistent with HES) and eosinophil infiltrates in
414 the arterial wall (which is consistent with a vasculitis process).

415 Secondly, we decided to perform a systematic review of the literature and then consider
416 whether EoV could be considered as an entity in its own right. To do so, we used positive
417 diagnostic criteria (for EoV and HES) and negative diagnostic criteria (to rule out all reactive
418 etiologies of eosinophilia, and all other types of vasculitis). The main differential diagnoses
419 that should be considered in the setting of vasculitis with blood and/or tissue eosinophilia are
420 detailed in Figure 2. Considering that EoV was diagnosed in the absence of asthma in ANCA-
421 negative HES patients, the CHCC2012 criteria for a diagnosis of EGPA were not met. If we
422 consider our patients in whom blood eosinophilia and extravascular eosinophils were nearly
423 constant features, and the other 1990 American College of Rheumatology (ACR) criteria for

424 EGPA (neuropathy, pulmonary infiltrates and paranasal sinus abnormalities), 8 patients met
425 the 1990 ACR criteria (21,28,67,79,83,88,90)(case #6). Given that granuloma was only
426 reported in three cases of EoV with a systemic presentation, we argue that EoV is mostly a
427 non-granulomatous vasculitis (in contrast to EGPA), and that these asthma-free patients
428 meeting 4 other 1990 ACR criteria might represent exceptions to the CHCC2012 diagnostic
429 classification of EGPA. However, it is also noteworthy that neither alveolar hemorrhage nor
430 necrotizing glomerulonephritis were reported. The differential diagnosis of EoV included
431 other types of vasculitis like microscopic polyangiitis, granulomatosis with polyangiitis,
432 polyarteritis nodosa (PAN), giant cell arteritis, Takayasu's arteritis, and Kawasaki's disease:
433 these conditions are not associated with high blood and/or tissue eosinophilia, and may
434 present with a high ESR and a high CRP level (91). Conversely, as previously reported, HES
435 (and subsequently EoV) seems to be characterized by a normal or slightly elevated CRP level.
436 In this line, a CRP level below 36 mg/L was evidenced in 26 of the 31 (84%) documented
437 EoV patients, which is suggestive of HES rather than EGPA (13). One can also consider a
438 differential diagnosis with PAN: since (i) none of our patients had gastrointestinal or kidney
439 microaneurysms or arterial hypertension, (ii) the elevations in the ESR and the serum CRP
440 levels were smaller those typically seen in PAN, and (iii) blood or tissue eosinophilia was not
441 a hallmark of PAN in the largest yet published series, we consider that a differential diagnosis
442 can be based on these discriminant criteria (92–94). Last, since this comprehensive review
443 excluded all cases of vasculitis associated with conditions that might have contributed to
444 secondary eosinophilia and/or organ damage, we postulate that “idiopathic” EoV be a distinct
445 entity that should be added to updated nomenclatures of vasculitis (9,95) rather than merely
446 being described as a pattern of injury (96).

447 The fact that 12% of our ANCA-negative, asthma-free patients with HES had EoV, and that
448 numerous patients also had non-vasculitic features of HES (e.g eosinophilic myositis, lung

449 infiltrates, eosinophilic fasciitis, colitis, ..), prompts us to think that EoV might be a
450 significant feature of HES. Indeed, in HES classifications, EoV was previously classified as a
451 dermatologic disease accompanied by eosinophilia, but 67.5% of our cases had
452 extracutaneous manifestations (n=27/40) (1). Interestingly, pruritic lesions (including those
453 with biopsy-proven EoV) were reported in more than two thirds of cases and may be a
454 hallmark of EoV because pruritus is rarely observed in other types of systemic vasculitis.

455 In the classical view of eosinophil-induced organ damage in HES, tissue infiltrates are often
456 accompanied by tissue fibrosis, thrombosis and/or the extracellular deposition of eosinophil-
457 derived proteins (97). Strikingly, all of these features were observed in damaged vessels of
458 EoV patients: predominant eosinophilic infiltration of the vessel wall were seen in all
459 available cases (according to our suggested definition of biopsy-proven EoV), some severe
460 occlusive intimal fibrous thickenings were associated with eosinophilic infiltrates (mainly in
461 temporal arteritis and coronary arteritis), focal arterial and/or venous thrombosis were found
462 in 19 of the 64 cases (30%), and finally, the detection of extracellular eosinophilic granules
463 were reported in 8 cases (23,37,53,80)(cases #3-4, Figure E1). Persistently activated
464 eosinophils can damage endothelial cells by releasing cytotoxic eosinophil-derived cationic
465 proteins and reactive oxygen species, and by activating local coagulation and inducing the
466 formation of vessel wall thrombi (6,98). Eosinophil granule proteins may be deposited in
467 tissues in the absence of detectable intact eosinophils, as in other tissues or diseases like
468 eosinophilic esophagitis (99). The direct toxicity of activated eosinophils and extracellular
469 granules may be responsible of vascular wall necrosis in small-to-medium sized vessels, and
470 the occurrence of dissected arteries and aneurysms in medium-to-large sized vessels (Figure
471 3A). Given that eosinophils are able to impair vessel wall integrity through the same
472 mechanisms as in tissue damage in HES, we suggest that EoV may correspond to HES-
473 induced secondary vasculitis.

474 According to the CHCC2012, single-organ vasculitis should be considered when vasculitis in
475 a single organ has no features that indicate that it is a limited expression of a systemic
476 vasculitis. Our work suggests that EoV restricted to the cerebral (n=4), coronary (n=29) and
477 temporal arteries (n=8) could also be considered as single-organ EoV (SO-EoV) for several
478 reasons: (i) the AEC is often normal (as in cerebral artery EoV and temporal artery EoV), (ii)
479 the outcome can be favorable in the absence of treatment or after surgical excision (as in
480 temporal artery EoV), (iii) because it is rarely encountered in the setting of systemic disease
481 (as in coronary artery and temporal artery EoV) and/or (iv) isolated EoV is diagnosed
482 postmortem in a large majority of cases (as in coronary EoV). From this standpoint, we
483 suggest that that the term “eosinophilic vasculitis” can be used for all situations other than the
484 SO-EoV defined above (i.e. isolated temporal, cerebral and coronary EoV) (Figure 3B).

485 After pooling the remaining 76 cases of EoV, we analyzed the frequency of clinical
486 manifestations, detailed in Figure 4. An AEC >0.5 or $>1.5\text{G/L}$ was present in 64 of 72 (89%)
487 and 54 out of 68 cases (79%), respectively. Necrotizing vasculitis was found in 28 out of 64
488 cases (44%). In view of the histopathologic and/or imaging features and the CHCC2012
489 nomenclature, we consider that EoV involved small vessels in 63 cases (83%) (e.g. the skin,
490 MM, gallbladder, etc.), medium-sized vessels in 17 cases (22%) (e.g. mesenteric veins, and
491 digital, cerebral or coronary arteries, etc.) and/or large vessels in 17 cases (22%) (e.g. tibial,
492 ulnar, and carotid arteries, the aorta, etc.) (Figure 3B). Even though small vessels were
493 predominantly involved, we suggest that EoV may be considered as a variable vessel
494 vasculitis (such as Behcet’s disease and Cogan’s syndrome in CHCC2012).

495 The last main reason for considering EoV as a manifestation of HES is the clinical
496 management of this condition. Indeed, most of the cases of EoV were successfully treated
497 with CSs alone - and even with topical CSs alone in some instances. Our literature review was
498 limited by the retrospectively collected data reported by the investigators. However, EoV may

499 have a good overall prognosis. Indeed, around 40% of patients did not relapse after tapering
500 of the first-line treatment), 26% required low-dose maintenance treatment with CSs, and (if
501 we exclude post-mortem diagnoses of coronary EoV) only two deaths were reported
502 (including one in an uncontrolled disease). The high CSs response rate (close to 100%) and
503 the different disease courses (single-flare, recurrent flares, and/or chronic disease) are once
504 again suggestive of HES (100); hence, mepolizumab (or benralizumab) might be good CSs-
505 sparing treatments.

506 In conclusion, and even though our literature review was limited by the variable amounts of
507 data reported by the investigators, we suggest some easy-to-apply criteria and definitions for
508 EoV (Figure 5). We advocate that EoV (HES-associated vasculitis) should be considered both
509 as an additional HES-defining feature as well as an additional cause of secondary variable-
510 vessel size vasculitis (especially in the context of non-granulomatous features and mild
511 systemic inflammation). Moreover, anti-interleukin-5 agents (which are highly effective in
512 both HES and EGPA (101–103)) may be a sound therapeutic approach in patients requiring
513 steroid-sparing agents. Further studies and discussion will be needed to determine whether
514 asthma status is the best criterion for characterizing the EoV spectrum in ANCA-negative
515 patients.

Acknowledgments

We thank Dr. David Fraser (Biotech Communication SARL, Ploudalmézeau, France) for copy-editing assistance.

REFERENCES

1. Valent P, Klion AD, Horny H-P, Roufosse F, Gotlib J, Weller PF, et al. Contemporary consensus proposal on criteria and classification of eosinophilic disorders and related syndromes. *J Allergy Clin Immunol.* 2012;130:607-612.
2. Simon H-U, Rothenberg ME, Bochner BS, Weller PF, Wardlaw AJ, Wechsler ME, et al. Refining the definition of hypereosinophilic syndrome. *J Allergy Clin Immunol.* 2010;126:45-9.
3. Shah AM, Brutsaert DL, Meulemans AL, Andries LJ, Capron M. Eosinophils from hypereosinophilic patients damage endocardium of isolated feline heart muscle preparations. *Circulation.* 1990;81:1081-8.
4. Tai PC, Hayes DJ, Clark JB, Spry CJ. Toxic effects of human eosinophil products on isolated rat heart cells in vitro. *Biochem J.* 1982;204:75-80.
5. Rohmer J, Groh M, Samson M, London J, Jachiet M, Rouzaud D, et al. Distal ischemia as the initial presentation of hypereosinophilic syndrome-related arterial involvement: A case study and literature review. *Autoimmun Rev.* 2019;18:828-30.
6. Roufosse F. L4. Eosinophils: how they contribute to endothelial damage and dysfunction. *Presse Medicale Paris Fr* 1983. 2013;42:503-7.
7. Churg J, Strauss L. Allergic granulomatosis, allergic angiitis, and periarteritis nodosa. *Am J Pathol.* 1951;27:277-301.
8. Lanham JG, Elkon KB, Pusey CD, Hughes GR. Systemic vasculitis with asthma and eosinophilia: a clinical approach to the Churg-Strauss syndrome. *Medicine (Baltimore).* 1984;63:65-81.
9. Jennette JC, Falk RJ, Bacon PA, Basu N, Cid MC, Ferrario F, et al. 2012 revised International Chapel Hill Consensus Conference Nomenclature of Vasculitides. *Arthritis Rheum.* 2013;65:1-11.
10. Cottin V. Eosinophilic Lung Diseases. *Clin Chest Med.* 2016;37:535-56.
11. Cottin V, Bel E, Bottero P, Dalhoff K, Humbert M, Lazor R, et al. Revisiting the systemic vasculitis in eosinophilic granulomatosis with polyangiitis (Churg-Strauss): A study of 157 patients by the Groupe d'Etudes et de Recherche sur les Maladies Orphelines Pulmonaires and the European Respiratory Society Taskforce on eosinophilic granulomatosis with polyangiitis (Churg-Strauss). *Autoimmun Rev.* 2017;16:1-9.

12. Lefèvre G, Ackermann F, Kahn J-E. Hypereosinophilia with asthma and systemic (non-vasculitic) manifestations: Eosinophilic granulomatosis with polyangiitis or hypereosinophilic syndrome? *Autoimmun Rev.* 2017;16:208–9.
13. Leurs A, Chenivresse C, Lopez B, Gibier J-B, Clément G, Groh M, et al. C-reactive protein as a diagnostic tool in differential diagnosis of hypereosinophilic syndrome and ANCA-negative eosinophilic granulomatosis with polyangiitis. *J Allergy Clin Immunol Pract.* 2019;7:1347-135
14. Robinowitz M, Virmani R, McAllister HA. Spontaneous coronary artery dissection and eosinophilic inflammation: A cause and effect relationship? *Am J Med.* 1982;72:923–8.
15. Yonker RA, Katz P. Necrotizing granulomatous vasculitis with eosinophilic infiltrates limited to the prostate. Case report and review of the literature. *Am J Med.* 1984;77:362–4.
16. Ferguson GT, Starkebaum G. Thromboangiitis obliterans associated with idiopathic hypereosinophilia. *Arch Intern Med.* 1985;145:1726–8.
17. Jessurun J, Azevedo M, Saldana M. Allergic angiitis and granulomatosis (Churg-Strauss syndrome): report of a case with massive thymic involvement in a nonasthmatic patient. *Hum Pathol.* 1986;17:637–9.
18. Bollinger A, Leu HJ, Brunner U. Juvenile arteritis of extracranial arteries with hypereosinophilia. *Klin Wochenschr.* 1986;64:526–9.
19. Lie JT, Michet CJ. Thromboangiitis obliterans with eosinophilia (Buerger's disease) of the temporal arteries. *Hum Pathol.* 1988;19:598–602.
20. Kajihara H, Kato Y, Takanashi A, Nakagawa H, Tahara E, Otsuki T, et al. Periarteritis of Coronary Arteries with Severe Eosinophilic Infiltration. *Pathol - Res Pract.* 1988;184:46–52.
21. Chen KR, Ohata Y, Sakurai M, Nakayama H. Churg-Strauss syndrome: report of a case without preexisting asthma. *J Dermatol.* 1992;19:40–7.
22. Burkey D, Love J, Fanning J, Lambrew C. Multiple spontaneous coronary artery dissections in a middle aged woman: support for an underlying eosinophilic arteritis predisposing to intimal disruption. *Cathet Cardiovasc Diagn.* 1993;30:303–5.
23. Chen KR, Pittelkow MR, Su D, Gleich J, Newman W, Leiferman KM. Recurrent cutaneous necrotizing eosinophilic vasculitis. A novel eosinophil-mediated syndrome. *Arch Dermatol.* 1994;130:1159–66.
24. Walsh I, Loughridge WG, Keane PF. Eosinophilic vasculitis (Churg-Strauss syndrome) involving the urethra. *Br J Urol.* 1994;74:255–6.
25. Fielding DI, Brown IG. Temporal arteritis in a young patient with a normal erythrocyte sedimentation rate. *Aust N Z J Med.* 1994;24:66–7.
26. Tomlinson FH, Lie JT, Nienhuis BJ, Konzen KM, Groover RV. Juvenile temporal arteritis revisited. *Mayo Clin Proc.* 1994;69:445–7.

27. Grishman E, Wolfe D, Spiera H. Eosinophilic temporal and systemic arteritis. *Hum Pathol.* 1995;26:241–4.
28. Song YW, Kim HA, Song KY. Eosinophilic fasciitis with occlusive vasculitis and gangrene of the finger. *J Rheumatol.* 1995;22:356–9.
29. Bateman AC, Gallagher PJ, Vincenti AC. Sudden death from coronary artery dissection. *J Clin Pathol.* 1995;48:781–4.
30. Hachulla E, Hatron PY, Janin A, Robert Y, Devulder B. [Digital arteritis, thrombosis and hypereosinophilic syndrome: an uncommon complication]. *Rev Med Interne.* 1995;16:434–6.
31. Lesser RS, Aledort D, Lie JT. Non-giant cell arteritis of the temporal artery presenting as the polymyalgia rheumatica-temporal arteritis syndrome. *J Rheumatol.* 1995;22:2177–82.
32. Fountain NB, Eberhard DA. Primary angiitis of the central nervous system associated with cerebral amyloid angiopathy: report of two cases and review of the literature. *Neurology.* 1996;46:190–7.
33. Basso C, Morgagni GL, Thiene G. Spontaneous coronary artery dissection: a neglected cause of acute myocardial ischaemia and sudden death. *Heart.* 1996;75:451–4.
34. Shimizu T, Kagawa H, Katsura K, Shirai K, Yamanaka Y, Kishimoto Y, et al. Polyangiitis overlap syndrome. *Intern Med Tokyo Jpn.* 1997;36:524–7.
35. Jang KA, Lim YS, Choi JH, Sung KJ, Moon KC, Koh JK. Hypereosinophilic syndrome presenting as cutaneous necrotizing eosinophilic vasculitis and Raynaud's phenomenon complicated by digital gangrene. *Br J Dermatol.* 2000;143:641–4.
36. Okinaka T. Coexistence of giant aneurysm of sinus of Valsalva and coronary artery aneurysm associated with idiopathic hypereosinophilic syndrome. *Heart.* 2000;84:7e–7.
37. Launay D, Delaporte E, Gillot JM, Janin A, Hachulla E. An unusual cause of vascular purpura: recurrent cutaneous eosinophilic necrotizing vasculitis. *Acta Derm Venereol.* 2000;80:394–5.
38. Resch B, Popper HH, Urlesberger B, Müller WD. Pulmonary eosinophilic vasculitis in a neonate with congenital chylothorax. *Pediatr Pulmonol.* 2002;33:501–4.
39. Salmo E, Callaghan J. Spontaneous coronary artery dissection in a healthy postmenopausal woman. *Med Sci Law.* 2002;42:126–8.
40. Val-Bernal JF, Mayorga M, García-Alberdi E, Pozueta JA. Churg–Strauss syndrome and sudden cardiac death. *Cardiovasc Pathol.* 2003;12:94–7.
41. Sakuma-Oyama Y, Nishibu A, Oyama N, Saito M, Nakamura K, Kaneko F. A case of recurrent cutaneous eosinophilic vasculitis: successful adjuvant therapy with suplatast tosilate. *Br J Dermatol.* 2003;149:901–3.

42. Gotlib V, Darji J, Bloomfield K, Chadburn A, Patel A, Braunschweig I. Eosinophilic variant of chronic myeloid leukemia with vascular complications. *Leuk Lymphoma*. 2003;44:1609–13.
43. Zagelidou H, Leodari R, Roupa Z, Maras D, Sapountzi-Krepia D, Terzis A. Death From Spontaneous Coronary Artery Dissection in a Healthy Postmenopausal Woman: *Am J Forensic Med Pathol*. 2004;25:176–7.
44. Naito AT, Minamino T, Tateno K, Nagai T, Komuro I. Steroid-responsive thromboangiitis obliterans. *Lancet Lond Engl*. 2004;364:1098.
45. Andonopoulos AP, Melachrinou M, Yiannopoulos G, Meimaris N. Juvenile temporal arteritis: a case report and review of the literature. *Clin Exp Rheumatol*. 2004;22:379–80.
46. Liao Y-H, Su Y-W, Tsay W, Chiu H-C. Association of cutaneous necrotizing eosinophilic vasculitis and deep vein thrombosis in hypereosinophilic syndrome. *Arch Dermatol*. 2005;141:1051–3.
47. Poommipanit PB, Lensky M, Tobis J. Eosinophilic arteritis with coronary aneurysms and stenoses. *J Invasive Cardiol*. 2005;17:266–9.
48. Matsunaga R, Soma Y, Watabe H, Hosaka E, Yamasaki E, Obara W, et al. Thromboangiitis obliterans associated with peripheral blood and eosinophilic cellulitis-like skin lesions. *Int J Dermatol*. 2005;44:615–7.
49. Imashuku S, Kakazu N, Ueda I, Morimoto A, Harada H, Teramura T, et al. Response to Imatinib Mesylate in a Patient with Idiopathic Hypereosinophilic Syndrome Associated with Cyclic Eosinophil Oscillations. *Int J Hematol*. 2005;81:310–4.
50. Tsunemi Y, Saeki H, Ihn H, Tamaki K. Recurrent Cutaneous Eosinophilic Vasculitis Presenting as Annular Urticarial Plaques. 2005;85:380-1.
51. Lepper PM, Koenig W, Möller P, Perner S. A Case of Sudden Cardiac Death Due to Isolated Eosinophilic Coronary Arteritis. *Chest*. 2005;128:1047–50.
52. Cecchi PC, Caramaschi P, Pinna G, Schwarz A, Bricolo A. Haemorrhagic stroke and vasculitic-like cerebral angiography in a patient with eosinophilic fasciitis. Case report. *J Neurosurg Sci*. 2006;50:119–22.
53. Tanglertsampan C, Tantikun N, Noppakun N, Pinyopornpanit V. Indomethacin for Recurrent Cutaneous Necrotizing Eosinophilic Vasculitis. 2007;90:3.
54. Chao C-C, Hsieh S-T, Shun C-T, Hsieh S-C. Skin Denervation and Cutaneous Vasculitis in Eosinophilia-Associated Neuropathy. *Arch Neurol*. 2007;64:959.
55. Abdulwahab A, Almoallim H, Khan N. Isolated eosinophilic mesenteric vasculitis with extensive thrombosis and splenic infarction in a 13-year-old boy. *Clin Rheumatol*. 2006;26:254–7.

56. Sommerville RB, Noble JM, Vonsattel JP, Delapaz R, Wright CB. Eosinophilic vasculitis in an isolated central nervous system distribution. *J Neurol Neurosurg Psychiatry*. 2007;78:85–8.
57. Hayashi M, Kawaguchi M, Mitsuhashi Y, Suzuki T. Case of hypereosinophilic syndrome with cutaneous necrotizing vasculitis. *J Dermatol*. 2008;35:229–33.
58. Song JK, Jung SS, Kang SW. Two cases of eosinophilic vasculitis with thrombosis. *Rheumatol Int*. 2008;28:371–4.
59. Ito K, Hara H, Okada T, Terui T. Hypereosinophilic syndrome with various skin lesions and juvenile temporal arteritis. *Clin Exp Dermatol*. 2009;34:e192–5.
60. Nakajima H, Nakamura T. Thrombotic eosinophilic vasculitis. *Clin Exp Dermatol*. 2009;34:e69–71.
61. Puri R, Dundon BK, Leong DP, Khurana S, Worthley MI. Hypereosinophilic syndrome associated with multiple coronary aneurysms. *Int J Cardiol*. 2009;133:e43–45.
62. Stoukas V, Dragovic LJ. Sudden Deaths from Eosinophilic Coronary Monoarteritis: A Subset of Spontaneous Coronary Artery Dissection. *Am J Forensic Med Pathol*. 2009;30:268–9.
63. Neshar G, Oren S, Lijovetzky G, Neshar R. Vasculitis of the temporal arteries in the young. *Semin Arthritis Rheum*. 2009;39:96–107.
64. Wieser M, Emmert MY, Rusch D, Weber B, Grünenfelder J, Falk V, et al. Impressive combination of multiple sinus valsalvae and coronary aneurysms due to hypereosinophilic syndrome. *Ann Thorac Surg*. 2010;90:e77.
65. Jandus, Bianda, Alerci, Gallino, Marone. Eosinophilic vasculitis: an inhabitual and resistant manifestation of a vasculitis. *Vasa*. 2010;39:344–8.
66. Arena V, Valerio L, Arena E, De-Giorgio F, Stigliano E, Monego G, et al. Isolated eosinophilic coronary arteritis. *J Clin Pathol*. 2010;63:469–71.
67. Basak RB, Narchi H, Bakir M, Joshi S, Conca W. Churg-strauss syndrome without respiratory symptoms in a child. *Indian J Dermatol*. 2011;56:84–6.
68. Kiorpelidou D, Gaitanis G, Zioga A, Tsili AC, Bassukas ID. Chronic Periaortitis (Retroperitoneal Fibrosis) Concurrent with Recurrent Cutaneous Eosinophilic Vasculitis. *Case Rep Dermatol Med*. 2011;2011:1–4.
69. van Gaalen J, van Dijk EJ, van Deuren M, de Leeuw F-E. Dissection of the posterior inferior cerebellar artery in the hypereosinophilic syndrome. *J Neurol*. 2011;258:2278–80.
70. Amara AW, Bashir K, Palmer CA, Walker HC. Challenges in diagnosis of isolated central nervous system vasculitis. *Brain Behav*. 2011;1:57–61.
71. Fengping Y, Jue H, Qingchun Y, Fangxing H. A Case of Sudden Death Due to Spontaneous Coronary Artery Dissection: *Am J Forensic Med Pathol*. 2011;32:312–3.

72. Omalu B, Hammers J, DiAngelo C, Moore S, Luckasevic T. Autopsy features of sudden death due to isolated eosinophilic coronary arteritis: Report of two cases. *J Forensic Nurs.* 2011;7:153–6.
73. Mendoza FA, Purohit S, Kenyon L, Jimenez SA. Severe Eosinophilic Syndrome Associated with the Use of Probiotic Supplements: A New Entity? *Case Rep Rheumatol.* 2012;2012:1–3.
74. Norita K, de Noronha SV, Sheppard MN. Sudden cardiac death caused by coronary vasculitis. *Virchows Arch.* 2012;460:309–18.
75. Sugiyama M, Nozaki Y, Ikoma S, Kinoshita K, Funauchi M. Successful Treatment with Tacrolimus in a Case of the Glucocorticoid-Dependent Recurrent Cutaneous Eosinophilic Vasculitis. *Ann Dermatol.* 2013;25:252.
76. Kajihara H, Tachiyama Y, Hirose T, Takata A, Saito K, Murai T, et al. Eosinophilic coronary periarteritis (vasospastic angina and sudden death), a new type of coronary arteritis: report of seven autopsy cases and a review of the literature. *Virchows Arch.* 2013;462:239–48.
77. Law AD, Varma S, Varma N, Khadwal A, Prakash G, Suri V, et al. Eosinophilic Vasculitis: Time for Recognition of a New Entity? *Indian J Hematol Blood Transfus.* 2014;30(Suppl 1):325–30.
78. Ratzinger G, Zankl J, Eisendle K, Zelger B. Eosinophilic leukocytoclastic vasculitis - a spectrum ranging from Wells' syndrome to Churg-Strauss syndrome? *Eur J Dermatol EJD.* 2014;24:603–10.
79. Ishibashi M, Kawahara Y, Chen K-R. Spectrum of cutaneous vasculitis in eosinophilic granulomatosis with polyangiitis (Churg-Strauss): a case series. *Am J Dermatopathol.* 2015;37:214–21.
80. Fujita K, Ishimaru H, Hatta K, Kobashi Y. Hypereosinophilic syndrome as a cause of fatal thrombosis: two case reports with histological study. *J Thromb Thrombolysis.* 2015;40:255–9.
81. Schneider R, Tsai JP, Munoz DG, Selchen DH. Eosinophilic CNS vasculitis can mimic demyelinating disease of the brain and spinal cord. *Neurology.* 2015;84:543–4.
82. Sawada C, Taniai M, Kawashima M, Ishiguro N. Recurrent cutaneous eosinophilic vasculitis. *Eur J Dermatol EJD.* 2016;26:108–9.
83. Ye L, Lu X, Xue J. Eosinophilic granulomatosis with polyangiitis complicated by cholecystitis: a case report and review of the literature. *Clin Rheumatol.* 2016;35:259–63.
84. Zeng M, Liu X, Liu Y. Eosinophilic Granulomatosis with Polyangiitis Presenting with Skin Rashes, Eosinophilic Cholecystitis, and Retinal Vasculitis. *Am J Case Rep.* 2016;17:864–8.
85. Riyaz N, Sasidharanpillai S, Hazeena C, Aravindan KP, Bindu CS, Silpa KN. Recurrent Cutaneous Eosinophilic Vasculitis: A Rare Entity. *Indian J Dermatol.* 2016;61:235.

86. Minami S, Fujimoto N, Takahashi T, Nakanishi T, Tanaka T. A case of refractory eosinophilic fasciitis with eosinophilic vasculitis. *Eur J Dermatol.* 2016;26:319-20.
87. MacDiarmid M, Nepogodiev D, Tiwari A, Duddy M, Carey M, Jobanputra P. Eosinophilic angiitis presenting with a true, fusiform, temporal artery aneurysm. *Clin Case Rep.* 2017;5:769-73.
88. Yener GO, Tekin ZE, Demirkan NÇ, Yüksel S. Eosinophilic granulomatosis with polyangiitis without respiratory symptoms or asthma in an adolescent: case report and literature review. *Rheumatol Int.* 2018;38:697-703.
89. Kobayashi T, Kanno K, Kikuchi Y, Kakimoto M, Kawahara A, Kimura K, et al. An Atypical Case of Non-asthmatic Eosinophilic Granulomatosis with Polyangiitis Finally Diagnosed by Tissue Biopsy. *Intern Med.* 2019;58:871-875
90. Wolf F, Glick K, Elias M, Mader R. Portal Vein Thrombosis and Thrombocytopenia in Eosinophilic Granulomatosis with Polyangiitis: A Paradox? *Eur J Case Rep Intern Med.* 2018;5:1.
91. Monach PA. Biomarkers in vasculitis. *Curr Opin Rheumatol.* 2014;26:24-30.
92. Watts R, Lane S, Hanslik T, Hauser T, Hellmich B, Koldingsnes W, et al. Development and validation of a consensus methodology for the classification of the ANCA-associated vasculitides and polyarteritis nodosa for epidemiological studies. *Ann Rheum Dis.* 2007;66:222-7.
93. Henegar C, Pagnoux C, Puéchal X, Zucker J-D, Bar-Hen A, Le Guern V, et al. A paradigm of diagnostic criteria for polyarteritis nodosa: analysis of a series of 949 patients with vasculitides. *Arthritis Rheum.* 2008;58:1528-38.
94. Pagnoux C, Seror R, Henegar C, Mahr A, Cohen P, Le Guern V, et al. Clinical features and outcomes in 348 patients with polyarteritis nodosa: a systematic retrospective study of patients diagnosed between 1963 and 2005 and entered into the French Vasculitis Study Group Database. *Arthritis Rheum.* 2010;62:616-26.
95. Khoury P, Grayson PC, Klion AD. Eosinophils in vasculitis: characteristics and roles in pathogenesis. *Nat Rev Rheumatol.* 2014;10:474-83.
96. Sunderkötter CH, Zelger B, Chen K-R, Requena L, Piette W, Carlson JA, et al. Nomenclature of Cutaneous Vasculitis: Dermatologic Addendum to the 2012 Revised International Chapel Hill Consensus Conference Nomenclature of Vasculitides. *Arthritis Rheumatol Hoboken NJ.* 2018;70:171-84.
97. Valent P, Gleich GJ, Reiter A, Roufosse F, Weller PF, Hellmann A, et al. Pathogenesis and classification of eosinophil disorders: a review of recent developments in the field. *Expert Rev Hematol.* 2012;5:157-76.
98. Gleich GJ, Frigas E, Loegering DA, Wassom DL, Steinmuller D. Cytotoxic properties of the eosinophil major basic protein. *J Immunol Baltim Md.* 1979;123:2925-7.
99. Peterson KA, Cobell WJ, Clayton FC, Krishnamurthy C, Ying J, Pease LF 3rd, Saffari H, Georgelas A, Fang J, Gleich GJ, Leiferman KM. Extracellular Eosinophil Granule

Protein Deposition in Ringed Esophagus with Sparse Eosinophils. *Dig Dis Sci.* 2015;60:2646-53

100. Kahn JE, Groh M, Lefèvre G. (A Critical Appraisal of) Classification of Hypereosinophilic Disorders. *Front Med.* 2017;4:216.
101. Rothenberg ME, Klion AD, Roufosse FE, Kahn JE, Weller PF, Simon H-U, et al. Treatment of patients with the hypereosinophilic syndrome with mepolizumab. *N Engl J Med.* 2008;358:1215–28.
102. Roufosse FE, Kahn J-E, Gleich GJ, Schwartz LB, Singh AD, Rosenwasser LJ, et al. Long-term safety of mepolizumab for the treatment of hypereosinophilic syndromes. *J Allergy Clin Immunol.* 2013;131:461-467.
103. Wechsler ME, Akuthota P, Jayne D, Khoury P, Klion A, Langford CA, et al. Mepolizumab or Placebo for Eosinophilic Granulomatosis with Polyangiitis. *N Engl J Med.* 2017;376:1921–32.

TABLE I. Clinical and histopathologic characteristics of vasculitis in 10 ANCA-negative, asthma-free patients with HES

Patients	Age/ Sex	Symptoms of vasculitis	Main histopathologic findings
#1	27/M	Pruritic papules with digital necrosis	Skin (prurigo): massive infiltration of eosinophils, necrotizing vasculitis with eosinophils in the vessel wall, fibrinoid necrosis
#2	45/M	Livedo racemosa, persistent angioedema	Skin: massive infiltration of eosinophils, eosinophilic vasculitis with eosinophils in the vessel wall, arteriolar thrombosis
#3	46/F	Ischemic colitis	Colon (resected necrotic segment): massive infiltration of eosinophils, eosinophilic vasculitis with eosinophils in the vessel wall, multiple arteriolar thromboses
#4	51/M	Chronic eosinophilic pneumonia	Lung: massive infiltration of eosinophils, eosinophilic vasculitis with eosinophils in the vessel wall, arteriolar thrombosis
#5	43/F	Erythematous papules, recurrent urticaria, arthralgia	Skin (papules): leukocytoclastic vasculitis and perivascular infiltrates of eosinophils
#6	43/F	Mononeuritis multiplex, acute myocarditis and pericarditis, inflammatory cerebral white matter lesions, chronic rhinosinusitis with nasal polyposis	<i>not available</i>
#7	67/M	Cerebral vasculitis, distal symmetric polyneuropathy	<i>not available</i>
#8	72/F	Mononeuritis multiplex, myositis, meningoencephalitis	Muscle: eosinophilic infiltrates with no vasculitis. Cerebrospinal fluid: hypercellularity, 25% eosinophils
#9	56/M	Mononeuritis multiplex, erythematous papules, eosinophilic gastroenteritis	Skin and digestive tract: eosinophilic infiltrates with no vasculitis
#10	72/M	Mononeuritis multiplex, erythematous papules	Skin: dermal eosinophilic infiltrates with no vasculitis, flame figures (Well's syndrome)

Age: age at diagnosis; ANCA, antineutrophil cytoplasmic antibody; F, female; M, male; HE, hypereosinophilia.

FIG 1. Representative histopathologic features of vasculitis in ANCA-negative, asthma-free patients with HES.

Left panel: patients #1 to 4 respectively developed prurigo (and digital necrosis, not shown), chronic eosinophilic pneumonia, ischemic colitis (arrow), and livedo racemosa.

Middle/right panels: hematoxylin-eosin staining revealed slight- (#4) to-massive (#1,2,3) perivascular eosinophilic infiltrates, eosinophils in the arterial wall (black arrows), fibrinoid necrosis with red cell extravasation (white arrows), arteriolar thrombosis (red arrows), and endothelial damage (blue arrows) (see Table I for details).

ANCA: anti-neutrophilic cytoplasmic autoantibody; HES: hypereosinophilic syndrome

FIG 2. Suggested diagnostic algorithm in case of vasculitis associated with blood and/or tissue hypereosinophilia.

AAV, ANCA-associated vasculitis; ACPAs, Anti-citrullinated protein antibodies; ANCA, anti-neutrophilic cytoplasmic autoantibody; CEREO, Centre de Référence National des Syndromes Hyperéosinophiliques; CT-scan, computerized tomography scan; EGPA, EoV, eosinophilic vasculitis; HES, hypereosinophilic syndrome; HBV/HCV, hepatitis B/C virus; HIV, human immunodeficiency virus; Ig, immunoglobulins; MRA, magnetic resonance angiography

FIG 3. Main histopathological features according to the vessel size and classification of EoVs according to their extent (B), adapted from [9]

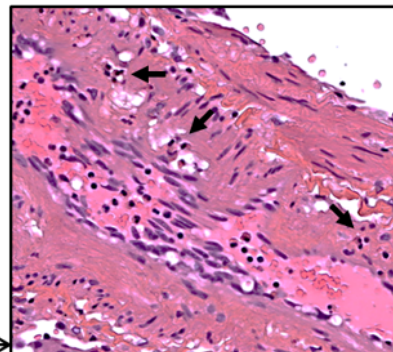
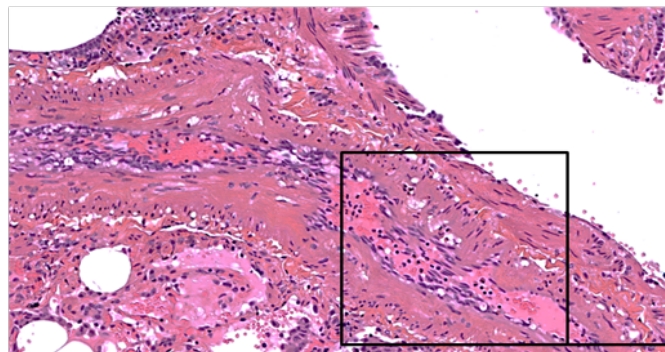
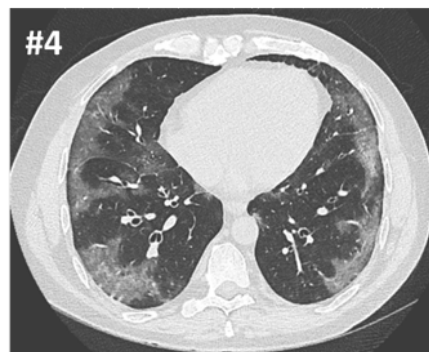
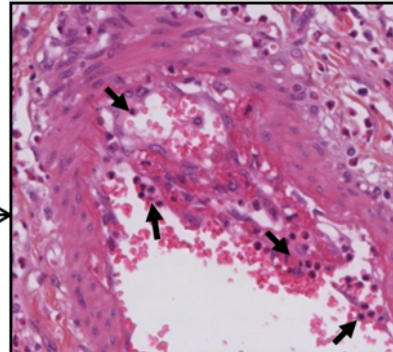
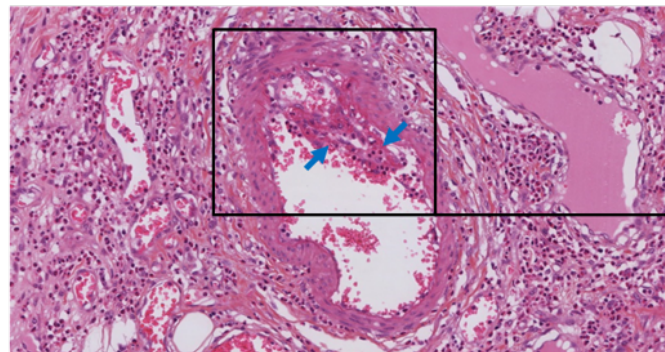
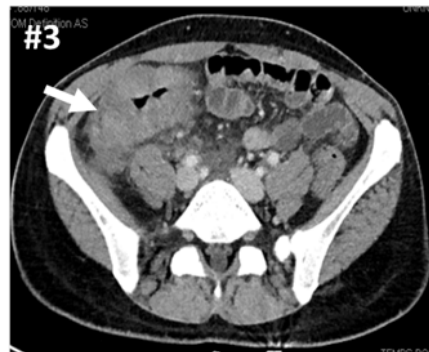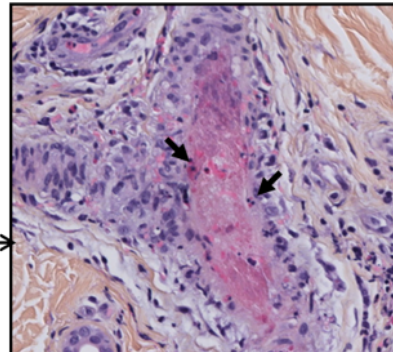
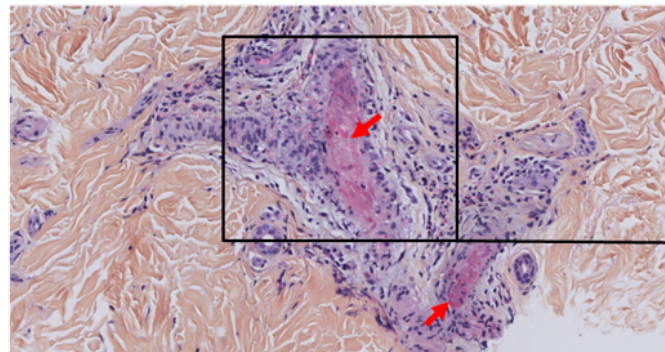
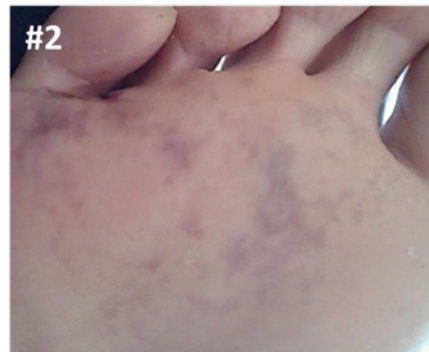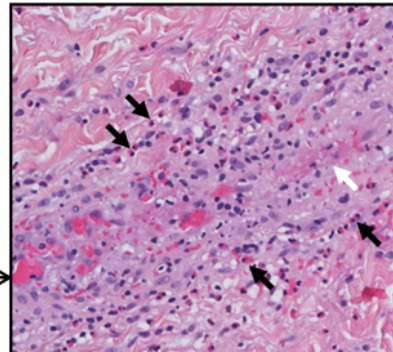
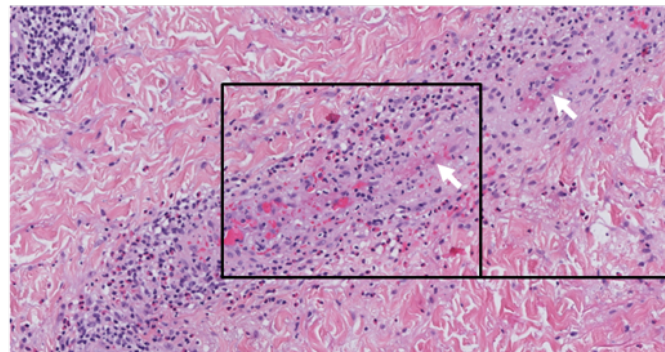
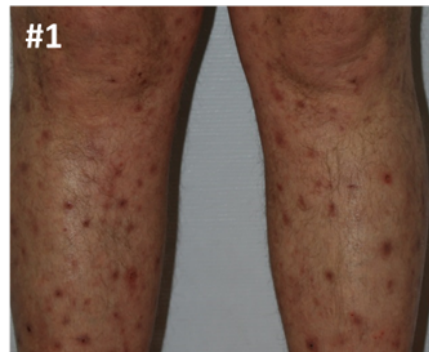
EoV, eosinophilic vasculitis; HES, hypereosinophilic syndrome

FIG 4. Clinical manifestations in EoV patients (n=76).

ENT: ear, nose and throat; HMG: hepatomegaly; LN: lymph node; NS: nervous system; SMG: splenomegaly; TAO-like disease: thromboangiitis-obliterans-like disease; SMG: splenomegaly

FIG 5. CEREO's suggested definition for idiopathic EoV (HES-associated vasculitis)

ANCA: anti-neutrophilic cytoplasmic autoantibody; CEREO: Centre de Référence National des Syndromes Hyperéosinophiliques; EoV: eosinophilic vasculitis; HES: hypereosinophilic syndrome.



Hypereosinophilia and vasculitis

Active asthma

No asthma
(confirmed by spirometry)

EGPA

ANCA, ACPA, Cryoglobulinemia
Deposits of Ig and/or complement
Infiltrates with IgG4+ plasma cells
Glomerulonephritis, alveolar hemorrhage
Gastrointestinal and/or kidney microaneurysms
HIV, HCV, HBV, syphilis

Presence

Consider AAV, immune complex vasculitis, infectious vasculitis, HBV/HCV-associated polyarteritis nodosa, IgG4-related disease, rheumatoid arthritis

Absence

Testing for FIP1L1-PDGFR fusion gene
T-cell immunophenotyping
Drug-induced eosinophilia
Neoplasia-associated eosinophilia
Other inflammatory condition

Presence

Consider chronic eosinophilic leukemia, lymphocytic variant HES and/or reactive vasculitis

Absence

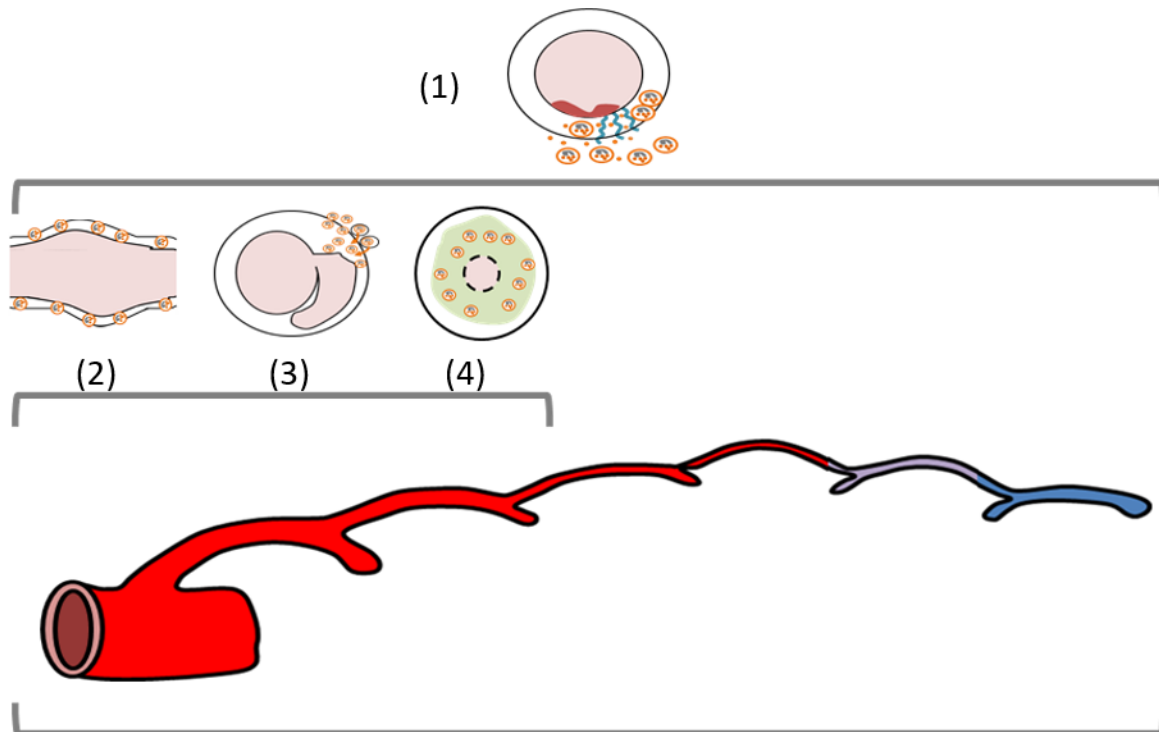
CEREO's suggested criteria fulfilled: confirm idiopathic EoV diagnosis and assess disease progression

Complete peripheral vascular examination (+/- doppler and chest CT-scan)

Biopsy of damaged organs if possible

Imaging: aorta and its branches, brain MRA, coronary calcium scan

A **Main histopathological features in EoV** are inflammatory eosinophilic infiltrates in vessel walls, and variously, extracellular eosinophilic granules deposition, necrosis, focal thrombosis, and perivascular eosinophils (1). In medium-to-large vessels, aneurysms (2), dissection (3), and/or occlusive intimal fibrosis (4) can also be observed.



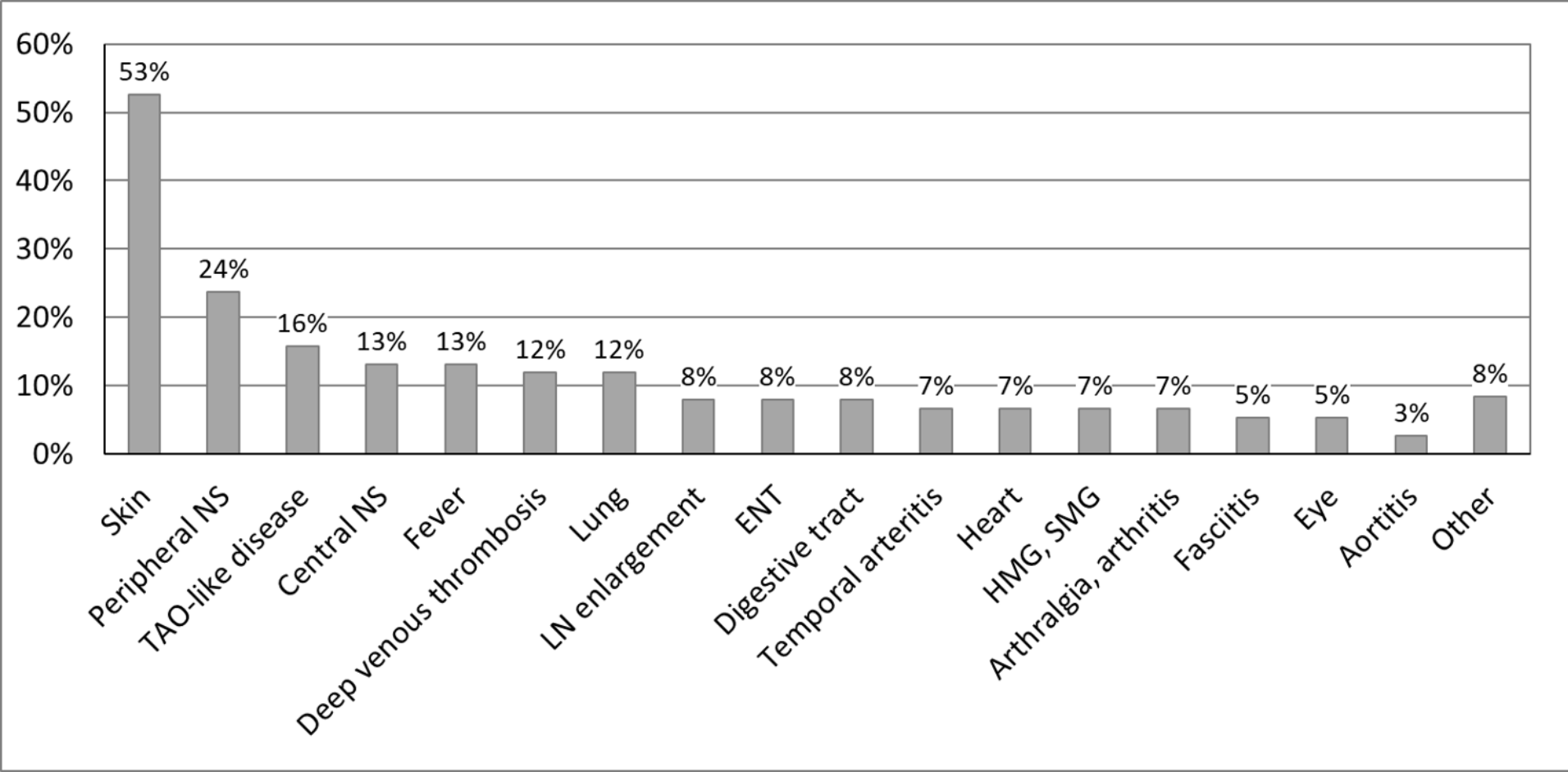
B

Idiopathic EoV (or idiopathic HES-associated vasculitis) (n=76)

Involved vessels can be small -(83%), medium- (22%) and/or large-sized (22%) (variable vessel vasculitis)

Single-organ EoV (n=41)

Isolated coronary (n=29), temporal (n=8), cerebral EoV (n=4)



All four of the following criteria must be met:

1. At least one of the following histopathologic or clinical features of vasculitis

- a. Any organ manifestation associated with biopsy-proven necrotizing vasculitis and predominant eosinophilic infiltration in the vessel wall (and/or marked deposition of eosinophil granule proteins), and/or
- b. Any organ manifestation associated with biopsy-proven perivascular eosinophilic infiltrates, and leukocytoclastic capillaritis, and/or eosinophilic infiltration in the vessel wall (and/or marked deposition of eosinophil granule proteins), and/or
- c. Any case of blood hypereosinophilia >1.5 G/L associated with a clinical manifestation consistent with the involvement of vasculitis, such as palpable purpura, myocardial infarction caused by proven coronaritis, cerebral vasculitis, mononeuritis simplex, digital necrosis, etc...

2. The absence of other disorders or conditions causing eosinophil-induced organ damage and secondary vasculitis (i.e underlying inflammatory, infectious, neoplastic or drug-induced disorders)

3. The absence of ANCA

4. No persistent/active asthma on diagnosis (and no history of persistent unexplained cough, dyspnea, wheezing, etc..).

Coronary arteritis, temporal arteritis and cerebral arteritis may be considered as *idiopathic single-organ EoV* when there is no other organ involvement (e.g. coronary EoV, temporal EoV, etc..). The term *EoV* may be suitable for all other situations, even when the disease appears to be restricted to a single organ or vascular territory.