



HAL
open science

Challenges in interpreting sacroiliac magnetic resonance imaging for the diagnosis of axial spondyloarthritis

Zakaria El Ouali, Laure Gossec

► To cite this version:

Zakaria El Ouali, Laure Gossec. Challenges in interpreting sacroiliac magnetic resonance imaging for the diagnosis of axial spondyloarthritis. *Joint Bone Spine*, 2023, 90 (1), pp.105470. 10.1016/j.jbspin.2022.105470 . hal-03863478

HAL Id: hal-03863478

<https://hal.science/hal-03863478>

Submitted on 9 Dec 2022

HAL is a multi-disciplinary open access archive for the deposit and dissemination of scientific research documents, whether they are published or not. The documents may come from teaching and research institutions in France or abroad, or from public or private research centers.

L'archive ouverte pluridisciplinaire **HAL**, est destinée au dépôt et à la diffusion de documents scientifiques de niveau recherche, publiés ou non, émanant des établissements d'enseignement et de recherche français ou étrangers, des laboratoires publics ou privés.

El Ouali Z, Gossec L. Challenges in interpreting sacroiliac magnetic resonance imaging for the diagnosis of axial spondyloarthritis. *Joint Bone Spine*. 2022 Sep 29;90(1):105470. doi: 10.1016/j.jbspin.2022.105470.

Challenges in interpreting sacroiliac magnetic resonance imaging for the diagnosis of axial spondyloarthritis

Authors :

Zakaria El Ouali¹ (ORCID ID 0000-0002-4997-6464)

Laure Gossec^{1,2} (ORCID ID 0000-0002-4528-310X)

Affiliations:

¹Rheumatology department, Pitié Salpêtrière hospital, AP-HP, Paris 75013, France

²Sorbonne Université, INSERM UMRS 1136, Institut Pierre Louis d'Épidémiologie et de Santé Publique, Paris 75013, France

Corresponding author: Zakaria El Ouali

E-mail address: dr.elouali.zakaria@gmail.com

Address: Service de Rhumatologie du Pr Bruno Fautrel, hôpital Pitié-Salpêtrière AP-HP, Paris 75013, France

Disclosures: No relevant disclosures for this article.

Funding: None.

Keywords: spondyloarthritis, MRI, sacroiliitis, healthy subjects

Word count: 1272

Axial spondylarthritis (axSpA) is a generic term referring to a spectrum of chronic inflammatory rheumatic diseases involving the axial spine, and belonging to the family of spondyloarthritis (SpA) (1). Magnetic resonance imaging (MRI) plays a key role in the work-up of axSpA. While late forms of axSpA can be easy to diagnose, early forms are difficult to detect using plain radiographs. The lack of imaging structural damage, which can sometimes take months to years to appear (2), contributes to a diagnostic delay of two to eleven years (3). Inflammation is however an early feature of axSpA, that can be detected on MRI. MRI has not only facilitated the diagnosis, it has also led to a significant reduction of the diagnostic delay (4). The Assessment of SpondyloArthritis International Society (ASAS) proposed classification criteria in 2009 including MRI features (Table 1) (5). AxSpA, as defined by ASAS, includes patients with structural damage in the sacroiliac joints (SIJ) assessable on plain radiographs (commonly referred as radiographic axSpA), but also patients without radiologic sacroiliitis, called non-radiographic axSpA (nr-axSpA) (Table 1) (1). Nr-axSpA often includes MRI abnormalities. Sacroiliitis on MRI was described in the initial ASAS criteria as “active (acute) inflammation of sacroiliac joints on MRI, highly suggestive of sacroiliitis associated with SpA” (5). In a more recent consensus, the ASAS/OMERACT MRI working group defined positive sacroiliac joint MRI as “either at least 2 inflammatory lesions in form of bone marrow edema (BME) in one slice, or only one BME lesion in at least 2 consecutive slices” (6–8). However, the specificity of the ASAS definition of positive MRI is a matter of debate (4). Inflammation on SIJ MRI can also be found in patients without axSpA, leading to a false “positive MRI” according to the ASAS definition (4). In the present paper, we will review the frequency of these false positive MRI findings, and discuss the factors that may explain inflammation in the absence of axSpA.

Initial preliminary data from 2018 onwards indicate that sacroiliitis could be seen in healthy subjects (Table 2). In 2018, de Winter et al. compared SIJ MRI of healthy subjects to those of patients with axSpA and patients with chronic back pain (9). Of the 47 healthy volunteers, 11 (23.4%) had a positive SIJ MRI versus 43/47 (91.5%) axSpA patients. Later, other small studies showed the presence of BME and fatty lesions in patients without axSpA, particularly in women with postpartum buttock/pelvic pain (3–39%, table 2) (10), and subjects aged over 30 (17%) (11). These studies raised concerns about the lack of specificity of MRI in the diagnosis of axSpA, but were considered exploratory, and the results had little impact on clinical practice. Recently, Baraliakos et al. investigated the frequency of BME and fatty

lesions in a large general population-based study (12). In all, 793 volunteers aged less than 45 years were evaluated, of whom a surprisingly high number, 136 (17.2%) had SIJ BME (12). The investigators also found abnormalities on the spine, with a relatively high frequency of inflammatory (27%) and fatty spinal MRI lesion (81%) suggestive of axSpA (12). Could this high rate be explained by poor interpretation? MRI sequences performed for the SIJ (i.e., Short-TI Inversion Recovery (STIR) sequence without T1-weighted sequences) were not those ideally recommended by ASAS (8). It is important to note that the site of the elementary lesion was not taken into account, although it has been shown that fat lesions and/or erosions located centrally or posteriorly in the SIJ are particularly significant and should be investigated further (13). However, 2 trained readers evaluated the MR images independently to assess BME. There was good agreement in the evaluation of the images between the readers, made up of a team of rheumatologists and radiologists, guided by an experienced reader (12). This study indicates that MRI both on SIJ and the spine, may overrate inflammation. It is possible the some patients, taken from the general population, had axSpA or low back pain (12). This study was cross-sectional without follow-up, making it impossible to assess later diagnoses. Overall, the large size of the study allowed to confidently confirm the presence of sacroiliitis in healthy subjects.

What are the factors involved in SIJ inflammation in healthy subjects (Figure 1)? First of all, age seems to have an impact. Renson et al. showed elegantly that sacroiliitis was more frequently detected in older age categories, going from 2.8% in the 20-29 category, to 17.9% in the 40-49 age group (11). It is possible that either mechanical stress or osteoarthritis may contribute to those findings. Moreover, physical activity is also a parameter leading to SIJ inflammation (Table 2). Of 22 elite ice hockey players and 20 recreational runners before and after running, 41% and 30-35% respectively fulfilled the ASAS definition of active sacroiliitis, with the posterior lower ilium being the most affected SI joint region, while no erosion was found (14). Similarly, intense standardized physical training increased the rate of positive SIJ MRI in military recruits after 6 weeks of intense standardized physical training (36% positive SIJ MRI after 6 weeks versus 23% at baseline) (15). However, SIJ erosions on MRI were present at the same rate both at baseline and after the 6 weeks of training (27%). These results indicate that it may be useful to ask patients to rest for a few days before undergoing MRI. However, the duration of cessation of efforts has not been explored. Another state with SIJ inflammation is postpartum. As could perhaps be expected, in 35 women within the first 10 days after giving birth, 27 (77%) had sacroiliac BME, and 60% fulfilled the ASAS definition of a positive MRI (16). After 6 months, 46% of the women still had BME, and 15% had a positive MRI. More surprisingly, after 12 months, 12% of the subjects still had a positive MRI (16). These findings were confirmed in similar studies (17, 18). It appears that postpartum has long standing effects.

False positive MRIs in daily practice could lead to overdiagnosis of axSpA, and potentially overtreatment (19, 20). We propose some elements to avoid overdiagnosis. It is important to perform the proper MRI sequences to analyze the SIJ in accordance with the ASAS/OMERACT recommendations, which are the T1-weighted and the STIR sequences (8). Moreover, the development of expertise in reading SIJ MRI is fundamental. The aim is to learn how to distinguish inflammatory lesions that may signal axSpA, from inflammatory lesions caused by other conditions, and to improve interobserver agreement (21). The interpretation should take into account the location and the extent of the SIJ lesions, the existence of erosion or fatty metaplasia, and anterior involvement of the lumbar spine (22). Of note, the interpretation of MRI should take into account both inflammatory and structural lesions, since taken separately, none of them have perfect specificity. More attention could be paid to structural damage, since the development of new sequences like the volumetric interpolated breath-hold examination (VIBE) have improved the detection of erosions in the SIJ compared with a standard T1-weighted sequence (23). It is possible that the current definition of SIJ MRI abnormalities used for the classification of axSpA is too wide and should be reconsidered. On a global level, clinical findings remain key elements in the investigation of SpA, particularly extra-articular manifestations such as uveitis, dactylitis, psoriasis, or

signs of inflammatory bowel disease (4). In the absence of such clinical symptoms, caution is needed when interpreting a “positive MRI”.

In conclusion, inflammatory SIJ MRI lesions suggestive of axSpA can be present in healthy subjects. SIJ MRI should be interpreted with caution and clinical expertise must remain at the forefront of the diagnosis of axSpA.

Table 1. Role of imaging in the ASAS classification criteria for axSpA (derived from [5])

Entry criterion: patients with ≥ 3 months back pain and age at onset <45 years		
Arm 1 : Radiographic axSpA	Arm 2 : Non-radiographic axSpA	SpA features
Sacroiliitis on plain radiograph according to the modified New York criteria + ≥ 1 feature of SpA	Sacroiliitis on MRI according to the ASAS consensus definition + ≥ 1 feature of SpA OR HLA-B27 + ≥ 2 other features of SpA	<ul style="list-style-type: none"> • Inflammatory back pain • Arthritis • Enthesitis (heel) • Uveitis • Dactylitis • Psoriasis • Crohn’s/colitis • Good response to NSAIDs • Family history for SpA • HLA-B27 • Elevated CRP

axSpA: axial spondyloarthritis ; ASAS: Assessment of SpondyloArthritis International Society. CRP: C-reactive protein. NSAIDs: non-steroidal anti-inflammatory drugs. SpA : spondyloarthritis.

Table 2. Frequency of positive sacroiliac MRI findings outside of axSpA (9-12, 14-18, 24).

Study population	Ref	n	Gender	Age, years	% positive MRI
Healthy subjects	(11)	36	M + F	20-29	3%
	(11)	31	M + F	30-39	16%
	(11)	28	M + F	40-49	18%
	(12)	793	M + F	37.3 ± 6.3	17%
	(10)	29	M	30.9 ± 6.4	0%
	(9)	47	M + F	30.9 ± 6.5	23%
Physical activity / athletes					
Long-distance runners	(10)	23	M + F	32.7 ± 6.2	4%
Runners	(9)	24	M + F	34.3 ± 7.7	13%
Military recruits after 6 weeks of training	(15)	11	M	25 ± 0.8	36%
Ice hockey players	(14)	22	M	25.9 ± 4.6	41%
Recreational runners	(14)	20	M + F	27.2 ± 5.4	30-35%
Postpartum					
Within 10 days of delivery	(16)	35	F	29.7 ± 2.62	77%
Early postpartum period	(17)	30	F	34.0	63%
Given birth within 12 months	(18)	60	F	31.2 ± 4.5	33%
Given birth more than 24 months	(18)	144	F	38.3 ± 6.2	21%
Without buttock and/or pelvic pain	(10)	14	F	33.1 ± 4.1	21%
With buttock and/or pelvic pain	(10)	46	F	32.6 ± 3.3	41%
With back pain	(9)	7	F	30.1 ± 7.2	57%
Low back pain					
Lumbar disc herniation	(10)	25	M + F	35.2 ± 5.7	8%
Chronic back pain	(9)	47	M + F	30.7 ± 6.5	6%
Low back pain	(24)	1037	M + F	33 (27-37)	21%

axSpA: axial spondyloarthritis ; F: female ; M: male ; n: number of subjects ; MRI: magnetic resonance imaging ; % positive MRI: percentage of the patients with positive MRI according to the ASAS definition.

The frequency of positive MRI in patients with axSpA ranged 56-92% in studies (9,10).

Figures

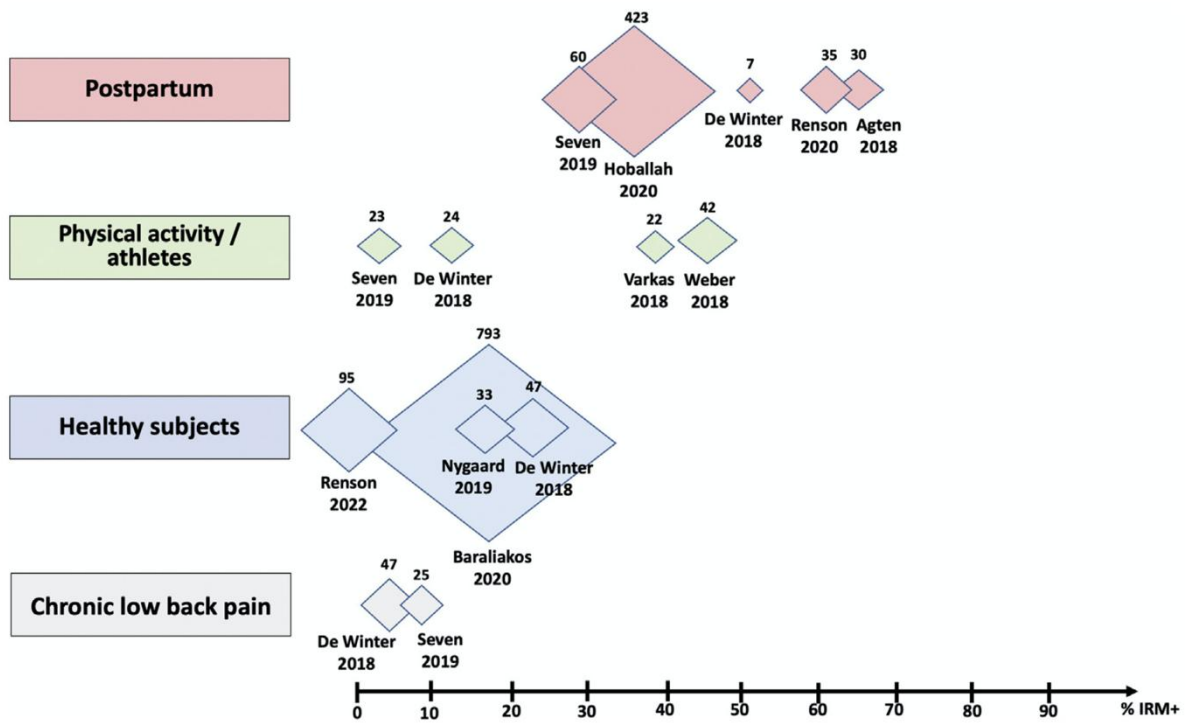


Figure 1. Factors of positive sacroiliac MRI findings outside of axSpA (9-12, 14-18, 24). The size of the diamonds reflects the number of patients. % IRM +: percentage of the patients with positive MRI according to the ASAS definition.

References

1. Sieper J, Poddubnyy D. Axial spondyloarthritis. *The Lancet*. 2017;390:73–84.
2. Dougados M, Sepriano A, Molto A, van Lunteren M, Ramiro S, de Hooge M, et al. Sacroiliac radiographic progression in recent onset axial spondyloarthritis: the 5-year data of the DESIR cohort. *Ann Rheum Dis*. 2017;76:1823–8.
3. Zhao SS, Pittam B, Harrison NL, Ahmed AE, Goodson NJ, Hughes DM. Diagnostic delay in axial spondyloarthritis: a systematic review and meta-analysis. *Rheumatology*. 2021 6;60:1620–8.
4. Robinson PC, van der Linden S, Khan MA, Taylor WJ. Axial spondyloarthritis: concept, construct, classification and implications for therapy. *Nat Rev Rheumatol*. 2021;17:109–18.
5. Rudwaleit M, van der Heijde D, Landewe R, Listing J, Akkoc N, Brandt J, et al. The development of Assessment of SpondyloArthritis international Society classification criteria for axial spondyloarthritis (part II): validation and final selection. *Ann Rheum Dis*. 2009;68:777–83.
6. Rudwaleit M, Jurik AG, Hermann KGA, Landewe R, van der Heijde D, Baraliakos X, et al. Defining active sacroiliitis on magnetic resonance imaging (MRI) for classification of axial spondyloarthritis: a consensual approach by the ASAS/OMERACT MRI group. *Ann Rheum Dis*. 2009;68:1520–7.
7. Lambert RGW, Bakker PAC, van der Heijde D, Weber U, Rudwaleit M, Hermann KGA, et al. Defining active sacroiliitis on MRI for classification of axial spondyloarthritis: update by the ASAS MRI working group. *Ann Rheum Dis*. 2016;75:1958–63.
8. Maksymowych WP, Lambert RG, Østergaard M, Pedersen SJ, Machado PM, Weber U, et al. MRI lesions in the sacroiliac joints of patients with spondyloarthritis: an update of definitions and validation by the ASAS MRI working group. *Ann Rheum Dis*. 2019;78:1550–8.
9. de Winter J, de Hooge M, van de Sande M, de Jong H, van Hooft L, de Koning A, et al. Magnetic Resonance Imaging of the Sacroiliac Joints Indicating Sacroiliitis According to the Assessment of SpondyloArthritis international Society Definition in Healthy Individuals, Runners, and Women With Postpartum Back Pain. *Arthritis Rheumatol*. 2018;70:1042–8.
10. Seven S, Østergaard M, Morsel-Carlsen L, Sørensen IJ, Bonde B, Thamsborg G, et al. Magnetic Resonance Imaging of Lesions in the Sacroiliac Joints for Differentiation of Patients With Axial Spondyloarthritis From Control Subjects With or Without Pelvic or Buttock Pain: A Prospective, Cross-Sectional Study of 204 Participants. *Arthritis Rheumatol*. 2019;71:2034–46.
11. Renson T, de Hooge M, De Craemer AS, et al. Progressive increase in sacroiliac joint and spinal mri lesions in healthy individuals in relation to age [published online ahead of print, 2022 Apr 18]. *Arthritis Rheumatol*. 2022;10.1002/art.42145. doi:10.1002/art.42145
12. Baraliakos X, Richter A, Feldmann D, Ott A, Buelow R, Schmidt CO, et al. Frequency of MRI changes suggestive of axial spondyloarthritis in the axial skeleton in a large population-based cohort of individuals aged <45 years. *Ann Rheum Dis*. 2020;79:186–92.

13. Seven S, Østergaard M, Morsel-Carlsen L, Sørensen IJ, Bonde B, Thamsborg G, Lykkegaard JJ, Pedersen SJ. Anatomic Distribution of Sacroiliac Joint Lesions on Magnetic Resonance Imaging in Patients With Axial Spondyloarthritis and Control Subjects: A Prospective Cross-Sectional Study, Including Postpartum Women, Patients With Disc Herniation, Cleaning Staff, Runners, and Healthy Individuals. *Arthritis Care Res (Hoboken)*. 2021;73:742-754.
14. Weber U, Jurik AG, Zejden A, Larsen E, Jørgensen SH, Rufibach K, et al. Frequency and Anatomic Distribution of Magnetic Resonance Imaging Features in the Sacroiliac Joints of Young Athletes: Exploring “Background Noise” Toward a Data-Driven Definition of Sacroiliitis in Early Spondyloarthritis. *Arthritis Rheumatol*. 2018;70:736–45.
15. Varkas G, de Hooge M, Renson T, De Mits S, Carron P, Jacques P, et al. Effect of mechanical stress on magnetic resonance imaging of the sacroiliac joints: assessment of military recruits by magnetic resonance imaging study. *Rheumatology*. 2018 1;57:508–13.
16. Renson T, Depicker A, De Craemer AS, Deroo L, Varkas G, de Hooge M, et al. High prevalence of spondyloarthritis-like MRI lesions in postpartum women: a prospective analysis in relation to maternal, child and birth characteristics. *Ann Rheum Dis*. 2020;79:929–34.
17. Agten CA, Zubler V, Zanetti M, Binkert CA, Kolokythas O, Prentl E, Buck FM, Pfirrmann CWA. Postpartum Bone Marrow Edema at the Sacroiliac Joints May Mimic Sacroiliitis of Axial Spondyloarthritis on MRI. *AJR Am J Roentgenol*. 2018;211:1306-1312.
18. Hoballah A, Lukas C, Leplat C, Taourel P, Pialat JB, Sans N, Ramos-Pascual S, Cyteval C. MRI of sacroiliac joints for the diagnosis of axial SpA: prevalence of inflammatory and structural lesions in nulliparous, early postpartum and late postpartum women. *Ann Rheum Dis*. 2020;79:1063-1069.
19. Ortolan A, Lorenzin M, Doria A, Ramonda R. The Risk of overdiagnosis and overtreatment in spondyloarthritis. *Scandinavian Journal of Rheumatology*. 2022;51:241–2.
20. Wendling D, Claudepierre P, Goupille P, Pham T, Prati C. Tight control and treat-to-target in axial spondyloarthritis. Where are we? *Joint Bone Spine*. 2022;89:105263.
21. Rueda JC, Arias-Correal S, Vasquez AY, Calvo E, Peña P, Porrás M, et al. Interobserver Agreement in Magnetic Resonance of the Sacroiliac Joints in Patients with Spondyloarthritis. *International Journal of Rheumatology*. 2017;2017:1–5.
22. Herrada I, Devilliers H, Fayolle C, Attané G, Loffroy R, Verhoeven F, et al. Diagnostic performance of sacroiliac and spinal MRI for the diagnosis of non-radiographic axial spondyloarthritis in patients with inflammatory back pain. *Joint Bone Spine*. 2021;88:105106.
23. Diekhoff T, Greese J, Sieper J, Poddubnyy D, Hamm B, Hermann KA. Improved detection of erosions in the sacroiliac joints on MRI with volumetric interpolated breath-hold examination (VIBE): results from the SIMACT study. *Ann Rheum Dis*. 2018;77:1585-1589.
24. Arnbak B, Jensen TS, Egund N, Zejden A, Hørslev-Petersen K, Manniche C, et al. Prevalence of degenerative and spondyloarthritis-related magnetic resonance imaging

findings in the spine and sacroiliac joints in patients with persistent low back pain. Eur Radiol. 2016;26:1191–203