



## Next generation sequencing of Tunisian Leigh syndrome patients reveals novel variations: impact for diagnosis and treatment

Meriem Hechmi, Majida Charif, Ichraf Kraoua, Meriem Fassatoui, Hamza Dallali, Valerie Desquiret-Dumas, Céline Bris, David Goudenège, Cyrine Drissi, Saïd Galaï, et al.

### ► To cite this version:

Meriem Hechmi, Majida Charif, Ichraf Kraoua, Meriem Fassatoui, Hamza Dallali, et al.. Next generation sequencing of Tunisian Leigh syndrome patients reveals novel variations: impact for diagnosis and treatment. Bioscience Reports, 2022, 42 (9), 10.1042/BSR20220194 . hal-03861081

**HAL Id: hal-03861081**

**<https://hal.science/hal-03861081>**

Submitted on 19 Nov 2022

**HAL** is a multi-disciplinary open access archive for the deposit and dissemination of scientific research documents, whether they are published or not. The documents may come from teaching and research institutions in France or abroad, or from public or private research centers.

L'archive ouverte pluridisciplinaire **HAL**, est destinée au dépôt et à la diffusion de documents scientifiques de niveau recherche, publiés ou non, émanant des établissements d'enseignement et de recherche français ou étrangers, des laboratoires publics ou privés.

**Next generation sequencing of Tunisian Leigh syndrome patients reveals novel variations: impact for diagnosis and treatment.**

Meriem Hechmi<sup>1,2</sup>, Majida Charif<sup>3,4</sup>, Ichraf Kraoua<sup>5,6</sup>, Meriem Fassatoui<sup>1,5</sup>, Hamza Dallali<sup>1,5</sup>, Valerie Desquiret-Dumas<sup>3,7</sup>, Céline Bris<sup>3,7</sup>, David Goudenège<sup>3,7</sup>, Cyrine Drissi<sup>8</sup>, Saïd Galai<sup>9</sup>, Slah Ouerhani<sup>10</sup>, Vincent Procaccio<sup>3,7</sup>, Patrizia Amati-Bonneau<sup>3,7</sup>, Sonia Abdelhak<sup>1,5</sup>, Ilhem Ben Youssef-Turki<sup>5,6</sup>, Guy Lenaers<sup>3</sup>, Rym Kefi<sup>1,5\*</sup>

<sup>1</sup>Laboratory of Biomedical Genomics and Oncogenetics, Institut Pasteur de Tunis, BP 74, 13 Place Pasteur, Tunis 1002, Tunisia.

<sup>2</sup> University of Carthage, National Institute of Applied Science and Technology, Tunis, Tunisia.

<sup>3</sup>University of Angers, MitoLab Team, Unité MitoVasc, UMR CNRS 6015, INSERM U1083, SFR ICAT, Angers, France.

<sup>4</sup>Genetics, and immuno-cell therapy Team, Mohammed First University, Oujda, Morocco.

<sup>5</sup>University of Tunis El Manar, 2092 El Manar I Tunis, Tunisia.

<sup>6</sup>Research Laboratory LR18SP04, Department of Child and Adolescent Neurology, National Institute Mongi Ben Hmida of Neurology, Tunis, Tunisia.

<sup>7</sup>Department of Biochemistry and Genetics, University Hospital Angers, Angers, France.

<sup>8</sup>Department of Neuroradiology, National Institute Mongi Ben Hmida of Neurology, Tunis, Tunisia.

<sup>9</sup>Departement of clinical biology, Research LaboratoryLR18SP04, Department of Child and Adolescent Neurology, National Institute Mongi Ben Hmida of Neurology, Tunis, Tunisia.

<sup>10</sup>Laboratory of Proteins Engineering and Bioactive Molecules (LIP-MB), National Institute of Applied Sciences and Technology of Tunis (INSAT), The University of Carthage, Tunis, Tunisia.

\*Corresponding author: Dr Rym KEFI

E-mail [rym.kefi@pasteur.tn](mailto:rym.kefi@pasteur.tn); [rym.kefi@pasteur.utm.tn](mailto:rym.kefi@pasteur.utm.tn)

Tel.: +216 71843755 [ext. 566]; Fax: +216 71791833

## Abstract:

Mitochondrial cytopathies, among which the Leigh syndrome (LS), are caused by variants either in the mitochondrial or the nuclear genome, affecting the oxidative phosphorylation process. The aim of this study consisted in defining the molecular diagnosis of a group of Tunisian patients with LS.

Six children, belonging to five Tunisian families, with clinical and imaging presentations suggestive of LS were recruited. Whole mitochondrial DNA and targeted next generation sequencing of a panel of 281 nuclear genes involved in mitochondrial physiology were performed. Bio-informatic analyses were achieved in order to identify deleterious variations.

A single m.10197G>A (p.Ala47Thr) variant was found in the mitochondrial *MT-ND3* gene in one patient, while the others were related to autosomal homozygous variants: two c.1412delA (p.Gln471ArgfsTer42) and c.1264A>G (p.Thr422Ala) in *SLC19A3*, one c.454C>G (p.Pro152Ala) in *SLC25A19* and one c.122G>A (p.Gly41Asp) in *ETHE1*.

Our findings demonstrate the usefulness of genomic investigations to improve LS diagnosis in consanguineous populations, and further allow for treating the patients harboring variants in *SLC19A3* and *SLC25A19* that contribute to thiamine transport, by thiamine and biotin supplementation. Considering the Tunisian genetic background, the newly identified variants could be screened in patients with similar clinical presentation in related populations.

**Keywords:** Leigh syndrome, mitochondrial cytopathies, NGS, Tunisia, North Africa.

## Introduction:

Mitochondrial diseases (MD) are multisystemic, encompassing a wide phenotypic spectrum, and can be manifested at any age (1,2). MD affect approximately 1 in 5000, and are characterised by the alteration of the mitochondrial oxidative phosphorylation system (OXPHOS), composed of five complexes embedded in the mitochondrial inner membrane (3). They are caused either by variants in the mitochondrial DNA (mtDNA) and nuclear DNA (nDNA), with more than 300 nuclear genes involved in the composition of the OXPHOS complexes, in the biogenesis and structure of the mitochondria, the mtDNA maintenance and in metabolic pathways (4,5).

Leigh Syndrome (LS) also known as subacute necrotizing encephalo-myelopathy, was first described by Archibald Leigh in 1951, as a progressive psychomotor retardation or regression, induced by a symmetrical necrosis in the brain stem, thalamus and basal ganglia. Other LS associated symptoms are hypotonia, muscle weakness, cerebellar ataxia, spasticity, nystagmus, optic atrophy, dysarthria, failure to thrive due to dysphagia, and elevated lactate levels in blood and in the cerebrospinal fluids. The disease usually appears in the first year of life and death may occur after respiratory muscle failure (6,7).

LS inheritance is complex since it involves maternal, autosomal recessive and dominant, and X-link modes of transmission. MtDNA variations are found in around 20% of cases, affecting mainly the respiratory complexes I, IV and V, and among them, the m.8993T>G in *MT-ATP6* is the most frequent, altering the complex V efficiency. The other 80% of LS cases involve variations in nuclear genes, altering essentially the function or assembly of the OXPHOS complexes, mostly resulting in complex I deficiency (8,9).

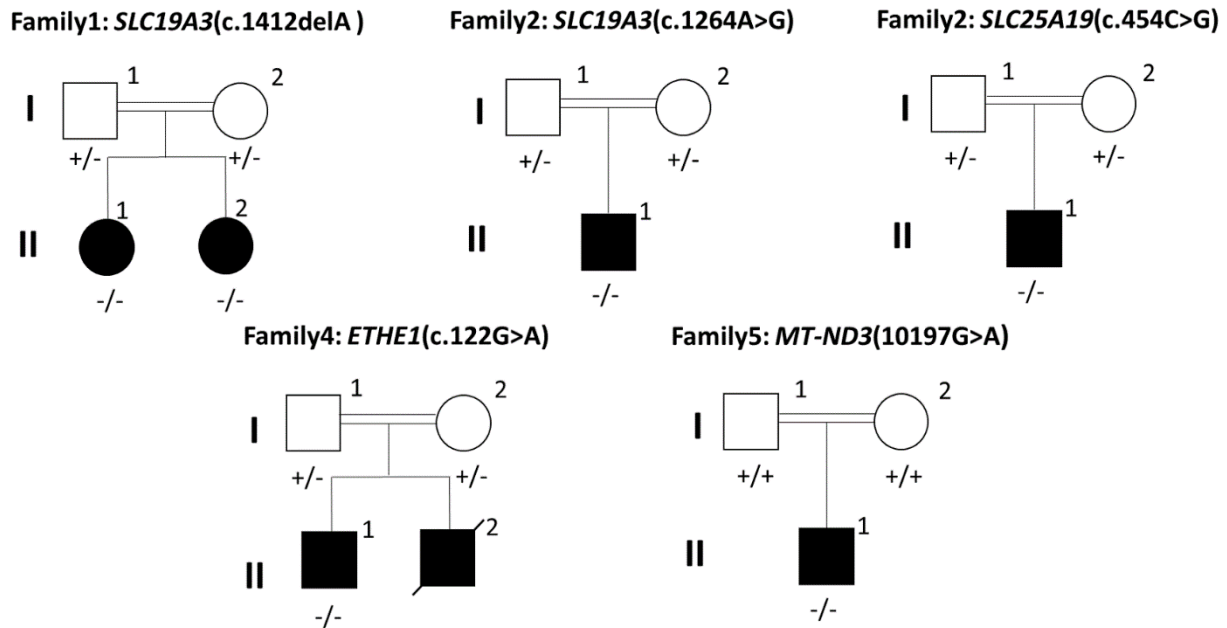
In Tunisia several genetic studies on LS patients were performed leading to the identification of variants in both mtDNA and nDNA. For example, the m.8993T>G variant in *MT-ATP6* was detected with variable heteroplasmic loads in all affected members of a single family (10). Two novel mitochondrial variants, m.5523T>G and m.5559A>G located in *MT-TW* affecting conserved regions of the *tRNA<sup>trp</sup>*, were also identified (11) as well as the m.9478T>C missense variant (V91A) in *COXIII* (12). Alternatively, variants in *SURF1* were identified, either as a homozygous splice site c.516-517delAG, or as compound heterozygous c.752-18A>C plus c.751+16G>A, most probably altering *SURF1* mRNA splicing and consequently the abundance of SURF1 protein (13).

The aim of this study was to further characterize genetic alterations in the mitochondrial and nuclear genomes in a cohort of Tunisian LS patients.

## **Patients and Methods:**

### ***Patient's descriptions***

This study was conducted according to the declaration of Helsinki and following the IRB recommendations was and approved by the Ethical Committee of The Institut Pasteur de Tunis Tunisia (Registration number IRB00005445, FWA00010074, Reference 2017/28/ILR16IPT). Written informed consent was obtained from parents for all the patients under the age of 18 years. Blood samples were obtained from five Tunisian families with six children having clinical, radiological and biochemical data suggestive of LS (figure 1). They were recruited from the Department of Pediatric Neurology (National Institute Mongi Ben Hmida of Neurology, Tunis).



**Figure 1: Pedigrees of the investigated families and segregation of their pathogenic variants.** Legend: Double lines indicates consanguineous parents; +/- indicates heterozygous for the variant; ++ homozygous for the normal allele and -/- homozygous for the deleterious variant. The position of each variation is in-between brackets.

#### ***Family 1 Patient 1:***

An 8-year-old girl, born from first-degree consanguineous parents. She had no perinatal asphyxia. She had a normal psychomotor development. Walking unaided was acquired at the age of 18 months. She was admitted to the department of pediatric neurology at the age of 5 years for acute gait disorder, dysarthria and abnormal postures. Examination revealed a right hemiparesis and generalized dystonia with dystonic dysarthria. Brain magnetic resonance imaging (MRI) revealed a bilateral necrosis of striatum, T2 weighted hyperintensity of the midbrain, with subcortical white matter and mammillary tubercles. The spectroscopy showed doublets of lactate. She had high levels of lactate in blood (2.82mmol/l; normal values 0.5-2.2 mmol/l), but normal in the cerebrospinal fluid (1.38mmol/l, normal values <2mmol/l). The lactate and pyruvate analysis revealed an elevated lactate to pyruvate ratio of 36.78, with a plasma lactate levels 2.06 mmol/l and pyruvate concentration of 0.056 mmol/l.

#### ***Family 1 Patient 2:***

She is a 6-year-old girl born from a twin pregnancy. She is the younger sister of patient 1. Her twin sister is healthy. She had no perinatal suffering and normal psychomotor development. The onset of the disease began at the age of 3 years and 8 months with acute abdominal pain followed by a gait instability, bilateral divergent strabismus and drowsiness without fever. Clinical examination revealed a drowsy patient spastic tetraparesis, walking aided with instability, axial hypotonia, pyramidal signs in four limbs, generalized dystonia, bilateral nystagmus, divergent strabismus and ptosis. Computerized tomography scan (CT-scan) showed a hypodensity of caudate nuclei and thalami. The MRI revealed T2 and FLAIR weighted hyper-intensity of thalami, striatum, vermis, peri-aqueducal region and fronto-

temporo-parietal cortex without enhancement and without restriction of diffusion. She had no lactate peak on spectroscopy. Her CSF lactate levels were normal (1.4 mmol/l). The lactate and pyruvate ratio appeared to be normal (18.16), with a plasma lactate level of 2.18mmol/l and pyruvate concentration of 0.12mmol/l.

***Family 2 Patient 1:***

He is a 7 years old boy born from first-degree consanguineous parents. He had a personal history of perinatal asphyxia. He had a normal psychomotor development. He presented at the age of 14 months abnormal postures of upper limbs and gait disorders that rapidly worsened until complete loss of the ability to walk. He had concomitant flu syndrome. Clinical examination showed that the patient was apyretic, drowsy and irritable. He had quadri-pyramidal syndrome and generalized dystonia. The first brain MRI performed at 7 days of evolution, showed abnormalities in subcortical white matter and in basal ganglia. The diagnosis of Acute Disseminated Encephalomyelopathy (ADEM) was evoked initially. He was hospitalized in the department of pediatric neurology. A second brain and spinal MRI was performed and revealed T2 and FLAIR weighted hyperintensity in basal ganglia with necrosis of the central area of the striatum suggestive of Leigh syndrome. Spectroscopy showed a lactate peak. CSF lactate was 1.47 mmol/l. Electromyoneurography (EMNG) was in favor of axonal sensory neuropathy of the lower limbs. He was treated as ADEM with corticoid and thiamin. The evolution was marked by improvement of consciousness and contact. However, he kept a severe generalized dystonia. The MRI performed 4 years later, showed a striatum atrophy with persistent hyperintensity. The lactate to pyruvate ratio was normal (17.2), with lactate plasma levels 1.38mmol/l and pyruvate concentration 0.08 mmol/l.

***Family 3 Patient 1:***

He is a 4 years old boy born from first-degree consanguineous parents. He had three aunts that died for an unknown reason between the ages of 4 and 5 years old. He had initially a normal psychomotor development. Walking was acquired at 14 months. He had a language delay. At the age of 14 months, he was hospitalized with 39°C fever, generalized epileptic seizures, sleep disturbance and psychomotor regression with loss of head control, sitting station, standing and walking. Examination showed generalized hypotonia and irritability. The diagnosis of encephalitis was evoked initially and the patient was treated by acyclovir and valproate of sodium. One month later, he presented dyspnea and dehydration. Biology showed cytolysis. Pyruvate blood levels before and after meal were 0.145mmol/L and 0.217mmol/L respectively. Brain MRI, showed thrombosis of the left lateral sinus and bilateral T2 and FLAIR weighted hyperintensity of striatum were observed. MRI spectroscopy showed a peak of lactate. He was switched to Phenobarbital and received heparinotherapy during 3 months. The evolution was marked by improvement on motor skills. However, he presented recurrent episodes of drowsiness. Brain MRI performed 3 years later, showed striatum necrosis with peak of lactate suggestive of Leigh syndrome. The lactate to pyruvate ratio was elevated 40.12, with lactate plasma levels 5.34mmol/l and pyruvate levels 0.133mmol/l.

***Family 4 Patient 1:***

A 5 years old boy born from second-degree consanguineous parents. He had a brother with similar illness who died at the age of 7 years. He was admitted to the hospital at the age of 5 months with chronic glairy diarrhea without fever. Examination showed axial hypotonia associated to spastic tetraparesis and generalized dystonia. He started walking at the age of 2 years and 2 months and his language skills were at monosyllable stage at the age of 2 years. MRI revealed lacunar lesion in the putamen and the anterior limb of the internal capsule. CSF lactate level was high (3.13 mmol/l). The lactate to pyruvate ratio was elevated 23.06, with lactate plasma levels 3.69mmol/l and pyruvate levels 0.16mmol/l.

#### ***Family 5 Patient 1:***

A 5-year-old boy born from third-degree consanguineous parents. He had a 7-year-old maternal cousin who had diabetes and developed psychomotor regression at 5-year-old. Pregnancy and delivery were uneventful. Psychomotor development was normal in the first year. His language was at babbling stage. The disease started at the age of one year with a motor regression followed by a complete loss of ambulation. He was unable to sit or stand independently. He was hospitalized at 15 months for investigation. Examination showed axial hypotonia, quadripyramidal syndrome and dystonia of the upper limbs. Brain MRI showed a T2 and FLAIR weighted hyperintensity of basal ganglia, of the periaqueductal region and the *substantia nigra* with a decrease of apparent diffusion coefficient (ADC). Spectroscopy revealed a doublet of lactate. Visual evoked potential, brain stem evoked response, cardiac and abdominal ultrasound were normal. EMNG was myogenic. CSF lactate levels were elevated (3.30 mmol/l). Evolution was marked by improvement of motor skills with appearance of generalized dystonia. He also developed epilepsy with tonic seizures treated by Lamotrigine with improvement.

#### ***Methods***

##### ***Targeted Next-Generation Sequencing:***

Total DNA was extracted from blood using the FlexiGene DNA kit (Qiagen). DNA quality was assessed using nano-drop spectrophotometer (ThermoFisher scientific) and Qubit 2.0 (ThermoFisher scientific). As previously described by (14), whole mitochondrial genome was amplified using two 8.5 kilo base (kb) over-lapping fragments. Ion Plus Fragment Library kit (Cat.no.4471269) was used in order to prepare the mtDNA library. mtDNA rearrangement and deletions were establish using eKLIPse software (15) .

A customized NGS panel of 281 nuclear genes involved in the maintenance of the mitochondrial genome, the assembly and function of the OXPHOS complexes, and the mitochondrial biogenesis was used to screen pathogenic variants for the six patients and their parents. Library preparation and sequencing and bioinformatics analysis were processed as described elsewhere (14).

##### ***Confirmation of variants by Sanger sequencing:***

Sanger sequencing was performed to confirm all the identified variants and to test the family segregation. Exons with candidate variants were amplified by PCR and sequenced on an ABI PRISM 3100- Avant automated DNA sequence using the BigDye Terminator Cycle

sequencing reaction kit v1.1. Sequences were compared with the updated Cambridge sequence of the mtDNA (GenBank accession number: NC\_012920). Sequence analyses were performed using SeqScape.

## **Results:**

### ***Mitochondrial DNA screening for variants and deletions:***

The mitochondrial genome from blood was screened for the 6 index patients. Results revealed in the index case of family 5, the m.10197G>A (p.Ala47Thr) variant in *MT-ND3* with a heteroplasmic rate of 87.7%. This variant is considered as probably damaging and deleterious according to Polyphen.

Analysis of mtDNA sequences of all patients using eKLIPse software did not reveal rearrangement or deletion (data not shown).

### ***Screening nuclear DNA for variations:***

Next generation sequencing of a panel of 281 genes involved in mitochondrial physiology was performed for the five patients devoid of mtDNA variant. Using a filtering step (14), four pathogenic variations in *SLC19A3*, *SLC25A19* and *ETHE1* genes (table 1) were identified. Both sisters from family 1 (patient 1 and 2) harbored the same homozygous frameshift deletion c.1412delA in *SLC19A3* exon 6. This novel variant was heterozygous in both parents and leads to a frameshift p.Gln471ArgfsTer42 classified as likely pathogenic (PVS1 and PM2) according to the ACMG classification (the American college of medical genetics). A second variation c.1264A>G in *SLC19A3* exon 5 was found in family 2 patient 1. This variation is predicted to be pathogenic (PP5, PM2 and PP2) by ACMG classification and was linked to biotin-thiamine responsive basal ganglia disease (BTRBGD). Both parents were heterozygous for this variant.



**Table 1: Variants identified in Tunisian patients with Leigh syndrome**

<i>Family and Patients</i>		<i>G</i>	<i>Age</i>	<i>Gene</i>	<i>ORF variant</i>	<i>Position</i>	<i>Protein change</i>	<i>Polyphen</i>	<i>Sift</i>	<i>Mutation Taster</i>
<i>Family 1</i>	Patient 1	F	6	<i>SLC19A3</i>	NM_025243.4 :c.1412delA	Chr2: 228552192	p.Gln471ArgfsTer42	-	-	-
	Patient 2	F	5	<i>SLC19A3</i>	NM_025243.4 :c.1412delA	Chr2: 228552192	p.Gln471ArgfsTer42	-	-	-
<i>Family 2</i>	Patient 1	M	5	<i>SLC19A3</i>	NM_025243:c.1264A>G	Chr2: 228552932	p.Thr422Ala	damaging	damaging	disease causing
<i>Family 3</i>	Patient 1	M	4	<i>SLC25A19</i>	NM_001126122.1:c.454C>G	Chr17: 73279509	p.Pro152Ala	possibly damaging	damaging	disease causing
<i>Family 4</i>	Patient 1	M	3	<i>ETHE1</i>	NM_014297: c.122G>A	Chr19: 44030771	p.Gly41Asp	probably damaging	damaging	disease causing
<i>Family 5</i>	Patient 1	M	3	<i>MT-ND3</i>	m. 10197G>A	mitochondria	p.Ala47Thr	-	-	-

G: gender; M: male; F: female.

Family 3 patient 1 carried a novel homozygous missense c.454C>G variation in *SLC25A19* exon 5, responsible for proline to alanine change in position 152. This variant was predicted to be deleterious according to Sift, Polyphen and Mutation Taster. This variant was also classified according to the ACMG classification criteria as likely pathogenic (PM2, PM5, PP2 and PP3). Both parents were heterozygous for this variant.

Finally, a novel homozygous missense variation c.122G>A variant in *ETHE1* was identified in patient 1 from family 4. This caused an amino acid substitution of glycine to aspartate at the protein position 41 (p.Gly41Asp). Sanger sequencing revealed that both parents were heterozygous for this variation, which is predicted to be damaging and disease causing by PolyPhen, Sift and Mutation Taster. And according to the ACMG classification criteria it was predicted as uncertain significance (PM2 and PP2). Biochemical investigation of the respiratory complexes' activities and cellular respiration of a patient biopsy showed normal values (data not shown).

## **Discussion:**

### **Impact of NGS/TGS on the diagnosis of Leigh syndrome patients**

In this study, we report five consanguineous Tunisian families with six children affected by Leigh syndrome. Mitochondrial genome sequencing revealed a novel m.10197G>A variation in family 5, with high heteroplasmic rate (87.7%), which has never been reported before in Tunisia, but well in patients affected by encephalo-myopathy (16), Leigh like syndrome (17), mitochondrial diseases with complex I deficiency (18), progressive generalized dystonia of childhood, Leber hereditary optic neuropathy with dystonia (19) and in another patient with stroke like episodes (20). In addition, three patients with LS or MELAS/LS overlapping syndromes harbored this m.10197G>A variant. High heteroplasmic rates of this variant can alter complex 1 activity and decrease cell respiration by 30% (21,22), and may explain the clinical features of our patient.

NGS sequencing of 281 genes implicated in mitochondrial diseases identified four variations, among them three novels in three different genes. These novel variants were checked in 100 unrelated Tunisian controls and were not found. The first variation c.1412delA (p.Gln471ArgfsTer42) in *SLC19A3* in the two sisters of family 1 was homozygous and led to a highly similar clinical phenotype. This variant created a new nonsense variant further downstream destroying the initial stop codon. This variant will lead to an abnormal protein with longer peptide chain altering the three-dimensional structure and subsequently its function. Added to that since the alteration occurred on the 3' untranslated region it will alter the regulatory function of this region (23). The variant c.1264A>G in *SLC19A3* found in family 2 results in a Threonine to Alanine change at position 422, altering a transmembrane domain. It was already reported in three families originated from Saudi Arabia (24) leading to decreased thiamine transporter 2 (hTHTR2) activity and down regulation of biotin accumulation (25). Furthermore, this c.1264A>G variation was identified as a founder variant in the Saudi population for BTRBGD (26). Similarly, a Turkish patient harbored the *SLC19A3* homozygous frameshift variant c.982del (p.Ala328Leufs\*10), resulting in a truncated protein (27).

*SLC19A3* encodes for hTHTR2, an ubiquitously expressed thiamine transporter, composed of 12 transmembrane domains (25). Additional *SLC19A3* variations were described in Leigh and Leigh like syndromes (28,29), in BTRBGD disease (30,31) and in Wernicke's Encephalopathy (32). The *SLC19A3* homozygous c.20C>A variant causing a premature stop codon, was found in two Moroccan siblings with LS, and then in 17 other LS patients (33). Pyruvate dehydrogenase activity from a muscle biopsy of one LS patient was virtually null, but the addition of thiamine pyrophosphate (TPP) did restore this activity (34). In addition, a novel homozygous missense variant c.958G>C (p.Glu320Gln) was found in four Japanese patients with a clinical presentation and radiological traits that were classified as LS. The p.Glu320Gln variant decreased of 63% the thiamine uptake (35).

The second thiamine transporter *SLC25A19* gene was found mutated in family 3, disclosing for the first time the c.454C>G (p.Pro152Ala) variant in a Tunisian patient. Alterations of *SLC25A19* gene have been linked to the bilateral striatal necrosis and neuropathy characterized by a truncal ataxia and hypotonia, episodes of encephalopathy, swallowing problems and recurrent episodes of flaccid paralysis and progressive polyneuropathy (36) and with the Amish lethal microencephalopathy. This latter disease is characterized by an apparent congenital microcephaly, high levels of  $\alpha$ -ketoglutarate in urine, brain malformations, psychomotor retardation with encephalopathy episodes (37). Li et al identified the same variant c.454C>A p.(Pro152Thr) but not the same amino acid change, in a Chinese LS patient, as compound heterozygous together with another variation c.194C>T (p.Ala65Val) in the same gene (38). Variants of *SLC25A19* play a major role on the etiology of Leigh syndrome, since neurological LS symptoms are convergent towards a pathomechanism of diseases related to thiamine transport. The members of thiamine transporters are expressed ubiquitously and thiamine plays a major role in the proper maintenance of the nervous, cardiovascular and motor systems (39,40).

Family 4 patient 1 presented a novel *ETHE1* homozygous variant c.122G>A,p.(Gly41Asp). *ETHE1* variants have been previously described as responsible for the development of ethylmalonic encephalopathy (EE), which is characterized by chronic diarrhea, recurrent petechiae, neurological degeneration, psychomotor delay, hypotonia, spastic tetraplegia, orthostatic acrocyanosis and Leigh-like syndrome (41,42). EE was mistakenly diagnosed as a Leigh syndrome, since both presentations have common clinical and radiological features, such as psychomotor regression, brain lesions, pyramidal and quadri-pyramidal syndromes, hypotonia and ataxia. According to the literature one patient was diagnosed as LS at the beginning, then after the apparition of petechia, orthostatic acrocyanosis, mild hepatomegaly and high ethylmalonate in blood and urine levels, the diagnosis was reconsidered to EE. Importantly, enzymatic activities of the mitochondrial respiration complexes from EE patient fibroblasts were normal (43), as we found in the case of family 4.

### **Founder mutations in LS**

With respect to founder effects in LS, previous studies have identified the *SLC19A3* c.20C>A variation in the Northern region of Morocco, in three unrelated families originated from the

Al Houceima province (33). Other founder variants were reported for LS patients in the literature. Variants with founder effect in *NDUFS4* gene was described in the Moroccan, Algerian and Ashkenazi Jewish population (44). Homozygous variant in *PET100* was reported in Lebanese patients (45). Variants in *LRPPRC* gene were found in patients originated from Northern Québec with LS French-Canadian type (46,47). Variant in *NDUFS4* gene present in five patients with LS is suggestive of a founder effect for the Hutterite population (48). A new founder variant in *USGM5* was identified for Ashkenazi Jewish patients affected with LS (49). These LS founder variants were not found in our Tunisian LS patients. Nevertheless, the *SLC19A3* variation c.1264A>G rs121917884 observed in our patient (family 2 patient 1), was identified as a founder variant for the Saudi Arabian population for BTRBGD. These latter variants could be screened as founder variants for LS Tunisian patients.

### Strategies for treatments

In the context of LS, for which no efficient treatment is available in most cases, patients harboring variants in the thiamine transporter genes, like *SLC19A3* and *SLC25A19* can be treated by thiamine and biotin supplementation, in order to increase thiamine intra cellular and mitochondrial concentrations (25). Thiamine enters the cytosol through the hTHTR2, then is converted to TPP, an active coenzyme, by the pyrophosphokinase 1 (TPK-1). Then TPP is transported across the mitochondrial membrane by the thiamine pyrophosphate carrier encoded by *SLC25A19*. TPP stimulates the production of acetyl-CoA through the conversion of pyruvate, to fuel the Krebs cycle (50,51). Thus, high doses of thiamine associated with biotin can be indicated as a treatment for LS patients with alteration of thiamine transporters in particular for those with variant in *SLC19A3* or *SLC25A19* (52). Taking into consideration these recommendations, our Tunisian patients with *SLC19A3* and *SLC25A19* variants affecting thiamine transport were supplemented with high doses of thiamine: 250 mg/day and biotin 5 to 10 mg/kg/day. This led to a notable improvement and stabilization of the course of the disease, which was reached for patient 1 harboring the *SLC19A3* c.1412delA variant after only 11 days of treatment. As regards to patient 2 family 1, we observed a total recovery after treatment for 12 days. After 3 months of treatment, the patient 1 from family 2 has partially recovered and did not present any novel episodes of encephalopathy. Lastly, patient 1 from family 3 started the treatment late, we observed a gradual improvement by the acquisition of walking and talking despite another encephalitic episode.

Regarding patients with *ETHE1* variants, it was reported that they can be treated with metronidazole and neomycine in alternance, in addition to N-acetylcysteine in order to decrease H<sub>2</sub>S levels. Alternatively, liver transplant can also expand the life span of children with EE (53,54).

### Conclusion:

The present study reports for the first time in Tunisia a NGS analysis of five families with children affected with LS. These patients were mutated in LS genes (*MT-ND3* and *SLC19A3*), and also in syndrome Leigh-like (*SLC25A19* and *ETHE1*). Taking into account common

genetic background and for the sake of cost-effectiveness, the newly identified variants should be screened in neighboring populations.

### **Author contributions**

MH, MC, GL, SO and RK conceived the project; MH, MC, GL, and RK designed the experiments; IC and IBYT, CD, SG performed the clinical analysis; MH, MC, MF, HD, VDD, CB, DG participated in the data acquisition, analysis and validation of the results. IC, VP, PAB reviewed the clinical data. SA, GL, SO and RK reviewed and edited the manuscript. All authors provided final approval of the manuscript.

### **Corresponding author**

Correspondence to Rym KEFI

### **Funding**

This work was funded by the Ministry of Higher Education and Scientific Research (LR16IPT05), the University of Carthage in Tunisia and by the Institut National de la Santé et de la Recherche Médicale (INSERM), Centre National de la Recherche Scientifique (CNRS), the Université d'Angers, the University Hospital (CHU) of Angers, the Région Pays de Loire and Angers Loire Métropole in France.

### **Acknowledgments**

We would like to thank the patients and their families.

### **Declaration of competing interest**

The authors declare that they have no known competing financial interests or personal relationships that could have appeared to influence the work reported in this paper.

### **Ethics approval**

This study was conducted according to the declaration of Helsinki and the approach was approved by the Ethical Committee of The Institut Pasteur de Tunis Tunisia (Registration number IRB00005445, FWA00010074, Reference 2017/28/ILR16IPT).

### **Consent for participation**

All subjects gave written informed consent.

### **Availability of data and material**

The article does not have additional data nor material.

### **References:**

1. Schaefer AM, McFarland R, Blakely EL, He L, Whittaker RG, Taylor RW, et al. Prevalence of mitochondrial DNA disease in adults. *Annals of Neurology*. 2008;63(1):35–9.
2. DiMauro S, Schon EA, Carelli V, Hirano M. The clinical maze of mitochondrial neurology. *Nature Reviews Neurology*. 2013;9(8):429–44.
3. Thorburn DR. Mitochondrial disorders: Prevalence, myths and advances. *Journal of Inherited Metabolic Disease*. 2004;27(3):349–62.

4. Dard L, Blanchard W, Hubert C, Lacombe D, Rossignol R. Molecular Aspects of Medicine Mitochondrial functions and rare diseases. *Molecular Aspects of Medicine*. 2020;71:1–28.
5. Russell OM, Gorman GS, Lightowlers RN, Turnbull DM. Review Mitochondrial Diseases : Hope for the Future. *Cell*. 2020;181(1):168–88.
6. Ruhoy IS, Saneto RP. The genetics of leigh syndrome and its implications for clinical practice and risk management. *Application of Clinical Genetics*. 2014;7:221–34.
7. Leigh D. Subacute Necrotizing Encephalomyelopathy in an Infant. *Journal of Neurology, Neurosurgery & Psychiatry*. 1951;14(3):216–21.
8. Chen L, Cui Y, Jiang D, Ma CY, Tse HF, Hwu WL, et al. Management of Leigh syndrome: Current status and new insights. *Clinical Genetics*. 2018;93(6):1131–40.
9. Schubert MB, Vilarinho L. Molecular basis of Leigh syndrome: A current look. *Orphanet Journal of Rare Diseases*. 2020;15(1):1–14.
10. Mkaouar-rebai E, Chaari W, Younes S. Maternally Inherited Leigh Syndrome : T8993G Mutation in a Tunisian Family. *Pediatric Neurology*. 2009;40(6):437–42.
11. Mkaouar-rebai E, Chamkha I, Kammoun F, Kammoun T, Aloulou H. Two new mutations in the MT-TW gene leading to the disruption of the secondary structure of the tRNA Trp in patients with Leigh syndrome. *Molecular Genetics and Metabolism*. 2009;97(3):179–84.
12. Mkaouar-Rebai E, Ellouze E, Chamkha I, Kammoun F, Triki C, Fakhfakh F. Molecular-clinical correlation in a family with a novel heteroplasmic leigh syndrome missense mutation in the mitochondrial cytochrome c oxidase III gene. *Journal of Child Neurology*. 2011;26(1):12–20.
13. Maalej M, Kammoun T, Alila-fersi O, Kharrat M, Hachicha M, Fakhfakh F. Biochemical and Biophysical Research Communications Cytochrome C oxydase de fi ciency : SURF1 gene investigation in patients with Leigh syndrome. *Biochemical and Biophysical Research Communications*. 2018;1–6.
14. Felhi R, Sfaihi L, Charif M, Desquiret-dumas V, Bris C, Goudenège D, et al. Next generation sequencing in family with MNGIE syndrome associated to optic atrophy : Novel homozygous POLG mutation in the C-terminal sub- domain leading to mtDNA depletion. *Clinica Chimica Acta*. 2019;488(October 2018):104–10.
15. Goudenège D, Bris C, Hoffmann V, Desquiret-dumas V, Jardel C, Rucheton B, et al. eKLIPse : a sensitive tool for the detection and quantification of mitochondrial DNA deletions from next-generation sequencing data. *Genetic in Medicine*. 2018;0(0).
16. Swalwell H, Kirby DM, Blakely EL, Mitchell A, Salemi R, Sugiana C, et al. Respiratory chain complex i deficiency caused by mitochondrial DNA mutations. *European Journal of Human Genetics*. 2011;19(7):769–75.
17. Kirby DM, Salemi R, Sugiana C, Ohtake A, Parry L, Bell KM, et al. NDUF56 mutations are a novel cause of lethal neonatal mitochondrial complex I deficiency. *Journal of Clinical Investigation*. 2004;114(6):837–45.

18. Lebre AS, Rio M, Faivre d'Arcier L, Vernerey D, Landrieu P, Slama A, et al. A common pattern of brain MRI imaging in mitochondrial diseases with complex I deficiency. *Journal of Medical Genetics*. 2011;48(1):16–23.
19. Wang K, Takahashi Y, Gao ZL, Wang GX, Chen XW, Goto J, et al. Mitochondrial ND3 as the novel causative gene for Leber hereditary optic neuropathy and dystonia. *Neurogenetics*. 2009;10(4):337–45.
20. Chae JH, Lee JS, Kim KJ, Hwang YS, Bonilla E, Tanji K, et al. A Novel ND3 Mitochondrial DNA Mutation in Three Korean Children With Basal Ganglia Lesions and Complex I Deficiency. *Pediatric Research*. 2007;61(5):622–4.
21. Tolomeo D, Rubegni A, Severino M, Pochiero F, Bruno C, Cassandrini D, et al. Clinical and neuroimaging features of the m.10197G>A mtDNA mutation: New case reports and expansion of the phenotype variability. *Journal of the Neurological Sciences*. 2019;
22. Galkin A, Wittig I, Karas M, Scha H, Vinogradov A, Brandt U, et al. Identification of the Mitochondrial ND3 Subunit as a Structural Component Involved in the Active / Deactive Enzyme Transition of Respiratory Complex I. *THE JOURNAL OF BIOLOGICAL CHEMISTRY*. 2008;283(30):20907–13.
23. Nussbaum RL, McInnes RR, Willard HF. *THOMPSON & THOMPSON GENETICS IN MEDICINE, EIGHTH EDITION*. 2016.
24. Zeng W, Al-yamani E, Acierno JS, Slaugenhaupt S, Gillis T, Macdonald ME, et al. Biotin-Responsive Basal Ganglia Disease Maps to 2q36 . 3 and Is Due to Mutations in SLC19A3. *the American Society of Human Genetics*. 2005;16–26.
25. Subramanian VS, Marchant JS, Said HM. Biotin-responsive basal ganglia disease-linked mutations inhibit thiamine transport via hTHTR2 : biotin is not a substrate for hTHTR2. *American journal of physiology Cell physiology*. 2006;291:851–9.
26. Alfadhel M, Almunashri M, Jadah RH, Bashiri FA, Talal M, Rifai A, et al. Biotin-responsive basal ganglia disease should be renamed biotin-thiamine-responsive basal ganglia disease : a retrospective review of the clinical , radiological and molecular findings of 18 new cases. *Orphanet Journal of Rare Diseases*. 2013;1–8.
27. Haack TB, Klee D, Strom TM, Mayatepek E, Meitinger T, Prokisch H, et al. Infantile Leigh-like syndrome caused by SLC19A3 mutations is a treatable disease. *Brain*. 2014;18–20.
28. Haack TB, Klee D, Strom TM, Mayatepek E, Meitinger T, Prokisch H, et al. Infantile Leigh-like syndrome caused by SLC19A3 mutations is a treatable disease. *Brain*. 2014;18–20.
29. Alfadhel M. Early Infantile Leigh-like SLC19A3 Gene Defects Have a Poor Prognosis : Report and Review. *journal of central nervous system disease*. 2017;9:1–4.
30. Alfadhel M, Tabarki B. SLC19A3 Gene Defects Sorting the Phenotype and Acronyms : Review. *Neuropediatrics*. 2017;1–17.
31. Savasta S, Bassanese F, Buschini C, Foadelli T, Trabatti C, Efthymiou S, et al. Biotin-Thiamine Responsive Encephalopathy : Report of an Egyptian Family with a Novel

- SLC19A3 Mutation and Review of the Literature. *journal of pediatric genetics*. 2018;1–9.
32. Kono S, Miyajima H, Yoshida K, Togawa A, Shirakawa K, Suzuki H. Mutations in a Thiamine-Transporter Gene and Wernicke ' s-like Encephalopathy. *the new england journal of medicine*. 2009;17(360):1792–4.
  33. Gerards M, Kamps R, Oevelen J Van, Boesten I, Jongen E, Koning B De, et al. Exome sequencing reveals a novel Moroccan founder mutation in SLC19A3 as a new cause of early-childhood fatal Leigh syndrome. *brain*. 2013;882–90.
  34. Gerards M, Kamps R, Oevelen J Van, Boesten I, Jongen E, Koning B De, et al. Exome sequencing reveals a novel Moroccan founder mutation in SLC19A3 as a new cause of early-childhood fatal Leigh syndrome. *brain*. 2013;882–90.
  35. Yamada K, Miura K, Hara K, Suzuki M, Nakanishi K, Kumagai T, et al. A wide spectrum of clinical and brain MRI findings in patients with SLC19A3 mutations. *BMC Medical Genetics*. 2010;11(1):171.
  36. Spiegel R, Shaag A, Stepensky P, Shalev SA, Case AI. SLC25A19 Mutation as a Cause of Neuropathy and Bilateral Striatal Necrosis. *Annals of Neurology*. 2009;1327–32.
  37. Kelley RI, Robinson D, Puffenberger EG, Strauss KA, Morton DH. Amish Lethal Microcephaly : A New Metabolic Disorder With Severe Congenital Microcephaly and 2-Ketoglutaric Aciduria. *American journal of medical genetics*. 2002;326(112):318–26.
  38. Li D, Song J, Li X, Liu Y, Dong H, Kang L, et al. Eleven novel mutations and clinical characteristics in seven Chinese patients with thiamine metabolism dysfunction syndrome. *European Journal of Medical Genetics*. 2020;63(10):104003.
  39. Ganapathy V, Smith SB, Prasad PD. SLC19: The folate/thiamine transporter family. Vol. 447, Pflugers Archiv European Journal of Physiology. 2004. p. 641–6.
  40. Tylicki A, Lotowski Z, Siemieniuk M, Ratkiewicz A. Thiamine and selected thiamine antivitamins — biological activity and methods of synthesis. *Bioscience Reports*. 2018;38(1):1–23.
  41. Tiranti V, Adamo PD, Briem E, Ferrari G, Mineri R, Lamantea E, et al. Ethylmalonic Encephalopathy Is Caused by Mutations in ETHE1 , a Gene Encoding a Mitochondrial Matrix Protein. *american society of human genetics*. 2004;239–52.
  42. TAVASOLI AR, ROSTAMI P, ASHRAFI MR, KARIMZADEH P. Neurological and Vascular Manifestations of Ethylmalonic Encephalopathy. *Iranian journal of child neurology*. 2017;11(2):57–60.
  43. Garcia-Silva T, Ribes A, Campos Y, Garavaglia B, Arenas J. Syndrome of encephalopathy,petechiae and Ethylmalonic Aciduria. *Pediatric Neurology*. 1997;8994(97):165–70.
  44. Assouline Z, Jambou M, Rio M, Bole-Feysot C, de Lonlay P, Barnerias C, et al. A constant and similar assembly defect of mitochondrial respiratory chain complex I allows rapid identification of NDUF54 mutations in patients with Leigh syndrome. *Biochimica et Biophysica Acta - Molecular Basis of Disease*. 2012;1822(6):1062–9.



45. Lim SC, Smith KR, Stroud DA, Compton AG, Tucker EJ, Dasvarma A, et al. A founder mutation in PET100 causes isolated complex IV deficiency in lebanese individuals with Leigh syndrome. *American Journal of Human Genetics*. 2014;94(2):209–22.
46. Debray FG, Morin C, Janvier A, Villeneuve J, Maranda B, Laframboise R, et al. LRPPRC mutations cause a phenotypically distinct form of Leigh syndrome with cytochrome c oxidase deficiency. *Journal of Medical Genetics*. 2011;48(3):183–9.
47. Morin C, Mitchell G, Larochelle J, Lambert M, Ogier H, Robinson BH, et al. Clinical, metabolic, and genetic aspects of cytochrome C oxidase deficiency in Saguenay-Lac-Saint-Jean. *American Journal of Human Genetics*. 1993;53(2):488–96.
48. Lamont RE, Beaulieu CL, Bernier FP, Sparkes R, Innes AM, Jackel-Cram C, et al. A novel NDUFS4 frameshift mutation causes Leigh disease in the Hutterite population. *American Journal of Medical Genetics, Part A*. 2016;173(3):596–600.
49. Barca E, Ganetzky RD, Potluri P, Juanola-Falgarona M, Gai X, Li D, et al. USMG5 Ashkenazi Jewish founder mutation impairs mitochondrial complex V dimerization and ATP synthesis. *Human Molecular Genetics*. 2018;27(19):3305–12.
50. Lindhurst MJ, Fiermonte G, Song S, Struys E, Leonardis F De, Schwartzberg PL, et al. Knockout of Slc25a19 causes mitochondrial thiamine pyrophosphate depletion , embryonic lethality , CNS malformations , and anemia. *Proceedings of the National Academy of Sciences of the United States of America*. 2006;103(43):15927–32.
51. Ganapathy V, Smith SB, Prasad PD. SLC19: The folate/thiamine transporter family. Vol. 447, *Pflugers Archiv European Journal of Physiology*. 2004. p. 641–6.
52. Whitford W, Hawkins I, Glamuzina E, Wilson F, Marshall A, Ashton F, et al. Compound heterozygous SLC19A3 mutations further refine the critical promoter region for biotin-thiamine- responsive basal ganglia disease. *Cold spring harbor: molecular case studies*. 2017;3:1–15.
53. Boyer M, Sowa M, Di Meo I, Eftekharian S, Steenari MR, Tiranti V, et al. Response to medical and a novel dietary treatment in newborn screen identified patients with ethylmalonic encephalopathy. *Molecular Genetics and Metabolism*. 2018;124(1):57–63.
54. Mc Kiernan PJ. Recent advances in liver transplantation for metabolic disease. *Journal of Inherited Metabolic Disease*. 2017;40(4):491–5.