



**HAL**  
open science

## Motion assessment of the thoracic aorta for flow numerical modeling

Marc Baudouard, Stanislas Rapacchi, Mariangela de Masi, Alexis Jacquier, Carine Guivier-Curien, Valerie Deplano

### ► To cite this version:

Marc Baudouard, Stanislas Rapacchi, Mariangela de Masi, Alexis Jacquier, Carine Guivier-Curien, et al.. Motion assessment of the thoracic aorta for flow numerical modeling. 47<sup>ème</sup> congrès de la Société de Biomécanique, Oct 2022, Monastir, Tunisia. hal-03859428

**HAL Id: hal-03859428**

**<https://hal.science/hal-03859428v1>**

Submitted on 18 Nov 2022

**HAL** is a multi-disciplinary open access archive for the deposit and dissemination of scientific research documents, whether they are published or not. The documents may come from teaching and research institutions in France or abroad, or from public or private research centers.

L'archive ouverte pluridisciplinaire **HAL**, est destinée au dépôt et à la diffusion de documents scientifiques de niveau recherche, publiés ou non, émanant des établissements d'enseignement et de recherche français ou étrangers, des laboratoires publics ou privés.

## Motion assessment of the thoracic aorta for flow numerical modeling

M. Baudouard<sup>a</sup>, S. Rapacchi<sup>b</sup>, M. De Masi<sup>c</sup>,  
C. Guivier-Curien<sup>a</sup>, A. Jacquier<sup>b,d</sup> and V. Deplano<sup>a</sup>

<sup>a</sup>Aix-Marseille Univ, CNRS, Ecole Centrale, IRPHÉ UMR 7342, Marseille, France; <sup>b</sup>Aix-Marseille Univ, CNRS, CRMBM UMR 7339, Marseille, France; <sup>c</sup>Aix-Marseille Univ, AP-HM, Service de chirurgie vasculaire de l'hôpital de la Timone, Marseille, France; <sup>d</sup>Aix-Marseille Univ, AP-HM, Service de radiologie de l'hôpital de la Timone, Marseille, France

### 1. Introduction

Numerical modeling of blood flow in pathologies of the thoracic aorta has been developed as an approach to anticipate their evolution. To be predictive, this modeling needs to be fully biomimetic. The few most advanced works consider unsteady flow, shear thinning fluid, patient-specific geometries as well as inlet and outlets boundary conditions derived from medical imaging. Few of them include fluid-structure interactions (FSI), that generate high computational times and generally consider the structures involved as hyperelastic solids with material parameters that are not patient specific. To overcome FSI limitations, it has been proposed in the literature to measure aortic wall motion, which is then prescribed as a boundary condition in the numerical simulations. On a numerical benchmark, we recently showed that 'prescribed displacement' modeling can substitute for complete FSI simulations (Baudouard et al. 2021). In the present study, the wall motion was obtained from MRI acquisitions and the objective is to improve the current methodologies used in the literature. Actually, our MRI acquisitions are not restricted to the ascending aorta (Capellini et al. 2021; Jin et al. 2003) and wall motion is assessed with appropriate spatio-temporal resolutions, in relation to motion magnitude and dynamics (Lantz et al. 2014).

### 2. Methods

The main steps of our methodology are the following: i) a reference centerline (CL) is obtained with 4DFlow MRI; ii) vessel contours are segmented at 5 imaging planes in the thoracic aorta with cine 2D-MRI, improving spatio-temporal resolution used in the literature; iii) for each phase of the cardiac cycle, specific CL and 3D geometry are reconstructed.

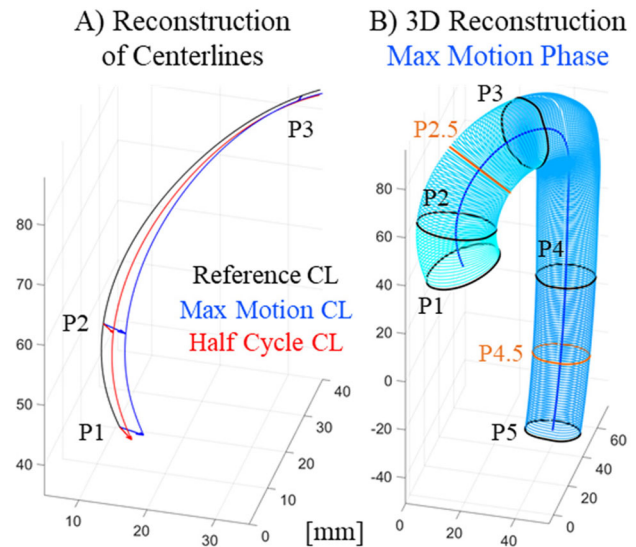


Figure 1. Centerlines and 3D reconstruction.

### 2.1. MRI acquisitions

Acquisitions on four volunteers were performed to develop the imaging protocol and only the final acquisition is presented. MRI scanner was a 3T Siemens Vida and heart rate was 81 bpm.

Parameters of the prototype free-breathing 4DFlow sequence were: respiratory motion tracking, retrospective ECG cardiac gating, TE/TR = 2.1/4.1ms, acquired temporal resolution = 32.6ms, reconstruction of 40 phases, acquired spatial resolution =  $2.1 \times 2.1 \times 2.1 \text{ mm}^3$ , velocity encoding in all directions (VENC = 150 cm/s). Acquisition in pseudo-sagittal view covered the entire thoracic aorta. Noise masking, correction for Maxwell terms and eddy currents were performed using GTFlow (GyroTools, Zürich).

Parameters of the free-breathing steady-state free precession cine 2D-MRI were: retrospective ECG cardiac gating, TE/TR = 3.8/6.0ms, acquired temporal resolution = 23.8ms, reconstruction of 40 phases, acquired spatial resolution =  $1.1 \times 1.1 \text{ mm}^2$ , interpolated 2-fold at reconstruction, slice thickness = 6mm. 5 planes perpendicular to the aorta main axis were acquired: ascending aorta (root (P1) and middle (P2)), aortic arch (P3), descending aorta (P4) and aorta at diaphragm (P5).

### 2.2. MRI segmentation

Using a velocity magnitude map computed from 4DFlow data, thoracic aorta at peak flow time is segmented in GTFlow with a region-growing method. Voxels not belonging to the vessel are manually removed. Finally, the reference CL is extracted from the 3D segmentation. All cine 2D-MRI images are

**Table 1.** Comparison aortic distension/CL motion.

Imaging Plane	P1	P2	P3	P4	P5
$D_{\text{dist}}$ [mm]	2.4	2.8	2.3	2.5	2.4
$CL_{\text{disp}}$ [mm]	6.9	6.4	2.6	1.9	2.7

segmented in MatLab using active contours. Manual corrections are performed on the noisiest images.

### 2.3. 4D reconstruction of the thoracic aorta

Firstly, the contours originating from cine 2D-MRI images are registered in the thoracic aortic volume.

Secondly, 3D transient motion of the CL is inferred from the displacements of the contours centroids (piecewise cubic hermite spline interpolation (PCHIP) between the imaging planes). Combining this motion with the reference CL gives CLs specific to each phase.


Then, each 3D geometry is reconstructed from the 5 contours and the CL, all phase specific. More precisely, the reconstruction shape evolves along the CL to ensure a smooth transition (PCHIP) between the known contours. Temporal pairing of reconstruction points between phases allows to determine 3D transient displacement of the whole thoracic aorta.

## 3. Results and discussion

Figure 1 illustrates the reconstruction method: A) displays the reference CL and two reconstructed CLs, as well as displacements of the contours centroids. B) shows the 3D geometry reconstructed at max motion phase (maximum displacement of the centroid at P1 and end of systole).

To compare distension of the thoracic aorta with CL motion, we computed maximum change in diameter ( $D_{\text{dist}}$ ) and maximum CL displacement in each imaging plane ( $CL_{\text{disp}}$ ). These values (Table 1) are consistent with published MRI results (Rengier et al. 2012). For example, distension was  $2.3 \pm 0.7$  mm in the aortic arch (P3) and CL displacement was  $6.7 \pm 1.8$  mm in the ascending aorta (P2).

CL motion is at least of the same order of magnitude as distension. Hence, CL reconstruction at each phase is mandatory. Some works (Capellini et al. 2021; Jin et al. 2003) only consider motion of the ascending aorta. However, distension and CL motion are not sub-millimetric in the descending aorta. Therefore, assessment of wall displacement should cover the entire thoracic aorta. Besides, a spatial resolution close to the maximum displacement amplitude cannot describe accurately the underlying motion. Thus, we chose 1.1mm-resolved cine 2D-MRI instead of cine 3D-MRI (Lantz et al. 2014).



**Figure 2.** Overlay of 4DFlow vessel (purple line) and reconstructed geometry (orange line) on the velocity magnitude map.

As CL motion and reconstruction shape are interpolated, deviations can appear, especially midway between imaging planes and far from reference CL phase. Flow deceleration is the last phase where 4DFlow velocity magnitude map can provide vessel wall location, albeit with low resolution (2.1 mm). At 2 planes (P2.5 and P4.5 on Figure 1), we compare our 4D reconstruction with the geometry derived from 4DFlow data (Figure 2).

Maximum difference in diameter and centroid location are, respectively, 1.1 and 1.3 mm, slightly above cine 2D-MRI spatial resolution. Consequently, interpolation induced inaccuracies do not impede correct wall displacement assessment.

## 4. Conclusions

The proposed method determines wall motion in the whole thoracic aorta with improved spatio-temporal accuracy compared with the literature. CL motion (2 to 7 mm) cannot be neglected compared to distension (2 to 3 mm). Implementing assessed motion in flow simulations is currently ongoing, with a fully patient-specific model as our long-term objective. In this clinical context, the routine CT-scan could be used to extract reference CL and geometry, enhancing the reconstruction. However, wall motion reduction due to aortic stiffening represents a potential limitation, as displacements may become sub-millimetric.

## Disclosure statement

No potential conflict of interest was reported by the authors.

## References

- Baudouard M, Rapacchi S, De Masi M, Guivier-Curien C, Jacquier A, Deplano V. 2021. Towards a prescribed wall displacement for fully patient-specific numerical modelling of pathological aorta. Accepted to 9th WC of Biomechanics 2022.
- Capellini K, Gasparotti E, Cella U, Costa E, Fanni BM, Groth C, Porziani S, Biancolini ME, Celi S. 2021. A novel

formulation for the study of the ascending aortic fluid dynamics with in vivo data. *Med. Eng. Phys.* 91:68–78.

Jin S, Oshinski J, Giddens DP. 2003. Effects of wall motion and compliance on flow patterns in the ascending aorta. *J. Biomech. Eng.* 125:347–354.

Lantz J, Dyverfeldt P, Ebbers T. 2014. Improving blood flow simulations by incorporating measured subject-specific wall motion. *Cardiovasc. Eng. Technol.* 5: 261–269.

Rengier F, Weber TF, Henninger V, Böckler D, Schumacher H, Kauczor HU, von Tengg-Kobligk H. 2012. Heartbeat-related distension and displacement of the thoracic aorta in healthy volunteers. *Eur. J. Radiol.* 81:158–164.

**KEYWORDS** Aortic wall motion; MRI; geometrical reconstruction; numerical modeling

 [valerie.deplano@univ-amu.fr](mailto:valerie.deplano@univ-amu.fr)