



HAL
open science

Anti-HMGCR antibody–related necrotizing zutoimmune myopathy mimicking muscular dystrophy

Céline Tard, Vincent Tiffreau, Emmanuelle Jaillette, Fabienne Jouen, Isabelle Nelson, Gisèle Bonne, Rabah Ben Yaou, Norma Romero, Louis Vallée, Patrick Vermersch, et al.

► To cite this version:

Céline Tard, Vincent Tiffreau, Emmanuelle Jaillette, Fabienne Jouen, Isabelle Nelson, et al.. Anti-HMGCR antibody–related necrotizing zutoimmune myopathy mimicking muscular dystrophy. *Neuropediatrics*, 2017, 48 (06), pp.473-476. 10.1055/s-0037-1604402 . hal-03855669

HAL Id: hal-03855669

<https://hal.science/hal-03855669>

Submitted on 3 Feb 2023

HAL is a multi-disciplinary open access archive for the deposit and dissemination of scientific research documents, whether they are published or not. The documents may come from teaching and research institutions in France or abroad, or from public or private research centers.

L'archive ouverte pluridisciplinaire **HAL**, est destinée au dépôt et à la diffusion de documents scientifiques de niveau recherche, publiés ou non, émanant des établissements d'enseignement et de recherche français ou étrangers, des laboratoires publics ou privés.

Misleading MD

Anti-HMGCR related necrotizing auto-immune myopathy mimicking muscular dystrophy.

Céline Tard^{1,2}, Vincent Tiffreau^{1,3}, Emmanuelle Jaillette^{1,4}, Fabienne Jouen⁵, Isabelle Nelson⁶, Gisèle Bonne⁶, Rabah Ben Yaou⁶, Norma Romero⁶, Louis Vallée^{1,7}, Patrick Vermersch^{1,2}, Sylvie Nguyen^{1,7}, Claude-Alain Maurage^{1,8}, Jean-Marie Cuisset^{1,7}

¹ Centre de référence des maladies rares, maladies neuromusculaires, Lille, France

² Service de neurologie et pathologie neuro-inflammatoire, CHRU de Lille, Lille, France

³ Service de médecine physique et réadaptation, CHRU de Lille, Lille, France

⁴ Service de réanimation médicale, CHRU de Lille, Lille, France

⁵ Immunology Department, Rouen University Hospital, Rouen, France

⁶ Sorbonne Universités, UPMC Univ Paris 06, INSERM UMRS974, CNRS FRE3617, Centre de Recherche en Myologie, Institut de Myologie, G.H. Pitié Salpêtrière, Paris, France.

⁷ Service de neuropédiatrie, CHRU de Lille, Lille, France

⁸ Service d'anatomopathologie, CHRU de Lille, Lille, France

Corresponding author: Céline Tard

Neurology Department

Salengro Hospital, Emile Laine Street

University Lille Hospital

59037 Lille cedex – France

Fax: +33 320444484

E-mail adress: celine.tard@chru-lille.fr

Abstract

Introduction: Necrotizing autoimmune myopathies are acquired myopathies with myofibrillar necrosis and weak or absent inflammatory component, sometimes associated with SRP or HMGCR antibodies.

Observation: The patient, a girl now aged 20, was first assessed at the age of 5 for abnormal gait revealing frank pelvic deficit. CK were as high as 7500 UI/L. Subsequent muscle biopsy showed some necrosis, fibre regeneration and fibrosis consistent with muscular dystrophy. Protein immunohistochemistry was normal. The disease course was progressive until wheelchair use at the age of 9. At 12, a second muscle biopsy found an advanced muscular dystrophy with some perivascular inflammatory mononuclear cells. All molecular analyses done through 14 years of follow up were negative till HMGCR antibodies were detected at a significant amount when she was 19.

Discussion: Necrotizing autoimmune myopathies may have a chronic course mimicking muscular dystrophies and begin at a pediatric age. Muscular biopsy can be misleading with a predominantly dystrophic pattern without inflammation.

Conclusion: this observation should prompt necrotizing autoimmune myopathy assessment in all muscular dystrophies, even pediatric, without molecular solution.

Keywords: acquired myopathy; idiopathic inflammatory myopathies; chronic myopathy; immune-mediated necrotizing myopathy

Abbreviations:

CK: creatine kinase

HMGCR: anti 3-hydroxy-3-methylglutaryl-coenzyme A reductase

SRP: anti Signal Recognition Particle

Misleading MD

NAM: necrotizing autoimmune myopathy

MD: muscular dystrophy

MHC: major histocompatibility complex

Introduction

Mammen et al.¹ were the first to discover that the molecular target of statins, 3-hydroxy-3-methylglutaryl coenzyme A reductase (HMGCR), is an autoantibody target in patients who develop an immune-mediated necrotizing myopathy or necrotizing autoimmune myopathy (NAM). The diagnosis of NAM include a subacute onset of proximally predominant muscle weakness, elevated CK levels, and abnormal EMG coupled with muscle biopsy showing necrotic muscle fibers with minimal or no inflammatory infiltrates^{2,3}. More than 15 different specific autoantibodies are now described in idiopathic inflammatory myopathies. Among them, the specific for signal recognition particle (SRP) or the 3-hydroxy-3-methylglutaryl-coenzyme A reductase (HMGCR) autoantibodies are specifically associated with NAM. In a large cohort study², common clinical features were a muscular weakness predominating at lower limbs (with a distal weakness), dysphagia and dyspnea. Facial weakness was more common in SRP-IgG-positive patients. Myotonic discharges were more common in statin-associated NAM. The median age of onset was usually over sixty. NAM often accompany statin therapy (35% of cases), connective tissue diseases and cancer^{2,4}. However, half of the patients have no identifiable risk factors constituting the idiopathic subgroup of NAM.

We report here a pediatric case, beginning at five years of age, with a rapidly progressive course until wheelchair use at 9. The clinical history and biopsy were highly suggestive of a dystrophic myopathy.

Case Report

A 5-year-old Caucasian girl with no previous medical history was referred to our neuropaediatric department because of muscular weakness and abnormal gait. She had 2 healthy brothers and unrelated parents. Familial history revealed a cardiomyopathy at 16 for her paternal grandfather, a breast neoplasia for her grandmothers, a rheumatoid arthritis for

her paternal grandmother and a dysthyroidism for her mother. Motor development was normal. Her first assessment revealed muscle weakness which was proximo-distal in lower limbs and proximal in upper limbs, and no facial involvement. Subsequent electromyography revealed myogenic pattern without spontaneous activity (Figure 1). The serum creatine kinase (CK) levels were as high as 7576. Hip retractions, then elbow - knee retractions and a rigid spine were also described around the age of 8, related to the muscle weakness. The disease course was rapidly progressive as she needed a wheelchair at 9. An unresolved attack of skin desquamation (palm of her hands) also occurred at 7. An artificial enteral feeding (through G tube) was initiated at 11 to maintain weight at 33 kg. A progressive scoliosis was surgically managed at 15 by a T3-S1 arthrodesis. Abdominal spasmodic pain, recurrent constipation with chronic intestinal pseudo-obstruction, pyrosis and dyspepsia (related to a mesenteric artery syndrome) also complicated the clinical presentation (around 16). In addition, she progressively developed a restrictive pulmonary syndrome with a vital capacity as low as 40% of the predicted value and a nocturnal hypercapnia when 11 years old. She thus required intermittent nocturnal non-invasive ventilation from the age of 12 onwards. Multiple cardiac assessments were done during follow-up and no cardiac involvement was found.

She also complained of nocturnal lower limb pain revealing osteoporosis and spontaneous femur and foot fractures. This required treatment by bisphosphonates from 12 onwards. At 16, type I diabetes was detected and required insulin pump.

Please insert about here Figure 1

The first quadriceps muscle biopsy, done at 6 years, revealed irregular muscular fibers, with some atrophic fibers (mainly type 2) and a major endomysial fibrosis suggestive of congenital muscular dystrophy (MD). Protein immunohistochemistry studies including dystrophin, sarcoglycans, merosin, alpha-dystroglycan and collagen 6 were normal. Normal levels of calpain, dysferlin, emerin, lamin A and lamin C were detected by muscle western blot

analysis. A second deltoid muscle biopsy done 2 years later was also considered as mainly dystrophic even though some particular non-specific findings were also observed (Figure 2). Those included type 2 fibre atrophy, type 1 fibre predominance and small inflammatory infiltrates, often perivascular. More recently, further analyses on this muscle biopsy were performed and showed a weak MHC1 overexpression and a weak C5b-9 deposit.

Please insert about here Figure 2

Several molecular analyses were performed from age 12 to 17 and included direct sequencing of successively *CAPN3*, *LMNA*, *FHL1*, *BAG3*, *CNTROB*, *FLNC*, *SUN1* and *Pax3* genes. No large rearrangement was found on two CGH arrays (CMD and LGMD_ NMD chip European project). Next Generation Sequencing was first performed on a designed DNA capture chip (NMD chip). Then whole exome sequencing was completed including DNA sequencing of her parents and two brothers. No candidate gene was identified.

More recently, HMGCRC antibodies were tested, using addressable laser bead immunoassay method ^{5,6}, due to the negativity of all molecular assessments and the association with an auto-immune environment. They were found positive (320 UI/L).

Based on clinical, laboratory, electrophysiological and pathologic findings, diagnosis of NAM was finally retained. Considering muscle atrophy, osteoporotic fracture history and diabetes, corticosteroids were not proposed. Polyvalent intravenous immunoglobulin therapy will be offered ⁷. Further investigations are planned, including pulmonary tomography to mainly look for an associated interstitial lung disease (that could lead to additional immunosuppressive treatment). A specific monitoring of neoplasia will be performed, including breast cancer.

Discussion

We report here on a patient with pediatric form of HMGCRA antibodies linked NAM for whom diagnosis was delayed mainly due to pathological findings mimicking MD and minimal inflammation, as recently reported in another child ⁶.

In the largest cohort of 63 adult patients ², no pediatric case was observed as the median age at symptom onset was 62 (ranging from 31 to 84) ². On the other hand, a French-cohort of 45 patients ⁴ included 8 pediatric cases (age range from 4 to 16) tested positive for anti-HMGCR (diagnosis performed in adulthood for 7/8): 4 girls were initially diagnosed as having an inflammatory myopathy because of rapidly progressive scapular and pelvic deficit with high CK level and the other 4 girls were initially diagnosed as having limb girdle MD because of a slowly progressive muscle deficit. Indeed, even if the subacute onset (<6 months) was noted for most of patients, 33% of patients had a slow progressive muscular deficit ranging from 10 months to several years (3 cases had been considered to be MD for more than 10 years prior to the detection of the anti-HMGCR antibodies) ⁴. The slow progression was also observed in a previous report of an anti-SRP antibodies related NAM ⁸.

The co-occurrence of other autoimmune disorders may be found in patients presenting a NAM and could suggest the NAM diagnosis. In fact, Allenbach *et al.* identified 8 autoimmune diseases in the past medical history of 5 patients among 45 (thyroiditis in 4, type 1 diabetes in 1) ⁴. In our case, the patient developed type 1 diabetes. In a recent cohort of juvenile myositis, 5/440 patients were HMGCRA-positive and have more frequent joint contractures and arthralgias, that may also suggest the diagnosis ⁹.

Muscle biopsies can be misleading when there is minimal inflammation and a pattern similar to that usually observed in MD ^{10,11}. Indeed, the predominant findings were fibre necrosis (100%) and regeneration (95%) with sometimes (22%) a mild inflammatory exudate that consisted of tiny perivascular collections of mononuclear cells in the perimysium ². Invasion of non-necrotic fibres and congophilic deposits was absent while non-rimmed vacuoles could

Misleading MD

be noted ². The same necrotizing myopathy pattern (necrosis and/or regeneration) with no or minor inflammatory infiltrates was observed in the other large cohort ⁴. C5b9 deposit was frequently (65%) observed on necrotic fibres but also on the membrane of a few normal ones, and on a few muscle capillaries (25%) though dramatically less than in the typical dermatomyositis ⁴. The differential diagnosis with MDs may thus be very complex ¹² ; immunohistochemical analysis (sometimes weak and focal MHC class I antigen sarcolemma expression) and cell phenotyping (showing that necrotic fibres can be invaded by macrophages which are the predominant mononuclear cell type, whereas T and B cells are virtually absent) may be helpful. In addition, inflammation, when present, was usually localized in perivascular areas. Overexpression of MHC class I was mainly observed on regenerative or necrotic fibres ² and sometimes in focal area in a few normal fibres. Diffuse and intense MHC class I overexpression (as observed in polymyositis or inclusion body myositis) was unusual ².

Pulmonary function tests in NAM revealed a restrictive pattern, consistent with neuromuscular respiratory weakness in 32% of the patients. Chest computed tomography revealed reticular interstitial lung abnormalities suggesting interstitial lung disease in very few patients ². Here, the severe restrictive pattern was supposed to be linked with muscular weakness but an interstitial lung infiltrate has to be ruled out.

In conclusion, to avoid overlooking this potentially treatable disorder, anti-HMGCR related should be rapidly considered as a possible diagnosis in children suffering from MD without definite genetic diagnosis. This should be ruled out in parallel to genetic workup.

Prednisone is often insufficient to control disease; the use of immunosuppressive agents such as rituximab is sometimes required. These may be beneficial when started within 3 months of onset ^{2,13}.

Misleading MD

Acknowledgements

NDM-chips (CMD and LGMD_ NMD chip European project), France Genomics, FMR

K. Claeys, M. Fardeau, L. Gueneau, F. Leturcq, P. Richard, J.A Urtizbera, T. Voit, G. Stoltenburgo for neuromuscular expertises for this case along time (clinic, genetic, pathology...)

Frederic London for English editing

References

1. Mammen AL. Autoimmune myopathies: autoantibodies, phenotypes and pathogenesis. *Nat Rev Neurol*. 2011;7(6):343-354. doi:10.1038/nrneurol.2011.63.
2. Kassardjian CD, Lennon VA, Alfugham NB, Mahler M, Milone M. Clinical Features and Treatment Outcomes of Necrotizing Autoimmune Myopathy. *JAMA Neurol*. 2015;72(9):996-1003. doi:10.1001/jamaneurol.2015.1207.
3. Hoogendijk JE, Amato AA, Lecky BR, et al. 119th ENMC international workshop: trial design in adult idiopathic inflammatory myopathies, with the exception of inclusion body myositis, 10-12 October 2003, Naarden, The Netherlands. *Neuromuscul Disord*. 2004;14(5):337-345. doi:10.1016/j.nmd.2004.02.006.
4. Allenbach Y, Drouot L, Rigolet A, et al. Anti-HMGCR autoantibodies in European patients with autoimmune necrotizing myopathies: inconstant exposure to statin. *Medicine (Baltimore)*. 2014;93(3):150-157. doi:10.1097/MD.0000000000000028.
5. Drouot L, Allenbach Y, Jouen F, et al. Exploring necrotizing autoimmune myopathies with a novel immunoassay for anti-3-hydroxy-3-methyl-glutaryl-CoA reductase autoantibodies. *Arthritis Res Ther*. 2014;16(1):R39. doi:10.1186/ar4468.
6. Musset L, Allenbach Y, Benveniste O, et al. Anti-HMGCR antibodies as a biomarker for immune-mediated necrotizing myopathies: A history of statins and experience from a large international multi-center study. *Autoimmun Rev*. 2016;15(10):983-993. doi:10.1016/j.autrev.2016.07.023.
7. Mohassel P, Foley AR, Donkervoort S, et al. Anti-HMGCR necrotizing myopathy masquerading as a muscular dystrophy in a child. *Muscle Nerve*. January 2017. doi:10.1002/mus.25567.
8. Suzuki S, Hayashi YK, Kuwana M, Tsuburaya R, Suzuki N, Nishino I. Myopathy associated with antibodies to signal recognition particle: disease progression and neurological outcome. *Arch Neurol*. 2012;69(6):728-732. doi:10.1001/archneurol.2011.1728.
9. Kishi T, Rider LG, Pak K, et al. Anti-3-Hydroxy-3-Methylglutaryl-Coenzyme A Reductase Autoantibodies are Associated with DRB1*07:01 and Severe Myositis in Pediatric Myositis Patients. *Arthritis Care Res (Hoboken)*. January 2017. doi:10.1002/acr.23113.
10. Ikeda K, Mori-Yoshimura M, Yamamoto T, et al. Chronic Myopathy Associated With Anti-Signal Recognition Particle Antibodies Can Be Misdiagnosed As Facioscapulohumeral Muscular Dystrophy. *J Clin Neuromuscul Dis*. 2016;17(4):197-206. doi:10.1097/CND.0000000000000115.
11. Liang W-C, Uruha A, Suzuki S, et al. Pediatric necrotizing myopathy associated with anti-3-hydroxy-3-methylglutaryl-coenzyme A reductase antibodies. *Rheumatology (Oxford)*. 2017;56(2):287-293. doi:10.1093/rheumatology/kew386.

12. Vattemi G, Mirabella M, Guglielmi V, et al. Muscle biopsy features of idiopathic inflammatory myopathies and differential diagnosis. *Auto Immun Highlights*. 2014;5(3):77-85. doi:10.1007/s13317-014-0062-2.
13. Dalakas MC. Inflammatory muscle diseases: a critical review on pathogenesis and therapies. *Curr Opin Pharmacol*. 2010;10(3):346-352. doi:10.1016/j.coph.2010.03.001.

Captions

Figure 1: electromyographic traces in 2002, in the *tibialis anterior* (channel, ch1) and in the *gluteus maximus* (channel, ch2). Spontaneous activities were not observed. Sensory and motor nerve conduction studies were normal.

Figure 2: pathology of *rectus femoris* muscle (HE x10). You can see atrophy with fibrous replacement and small foci of inflammatory cells.

Figure 1 EMG

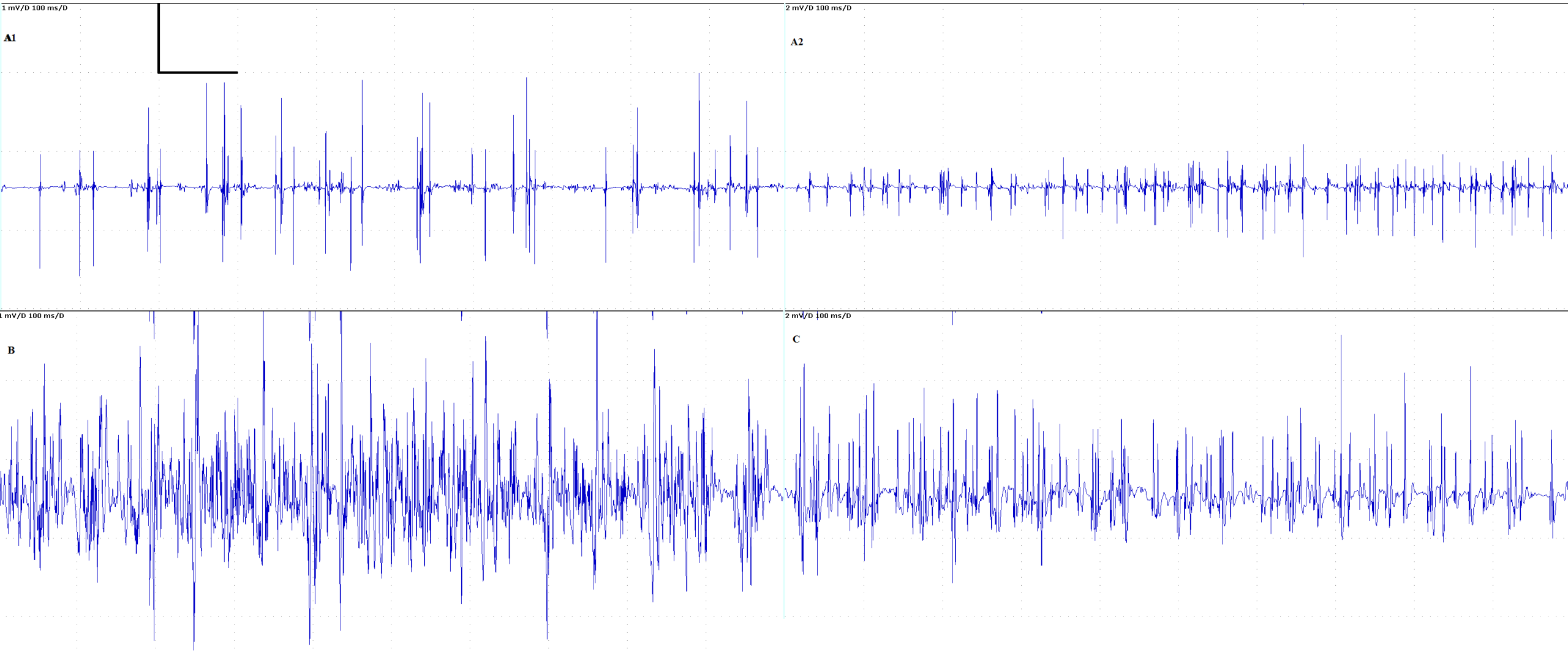


Figure 1

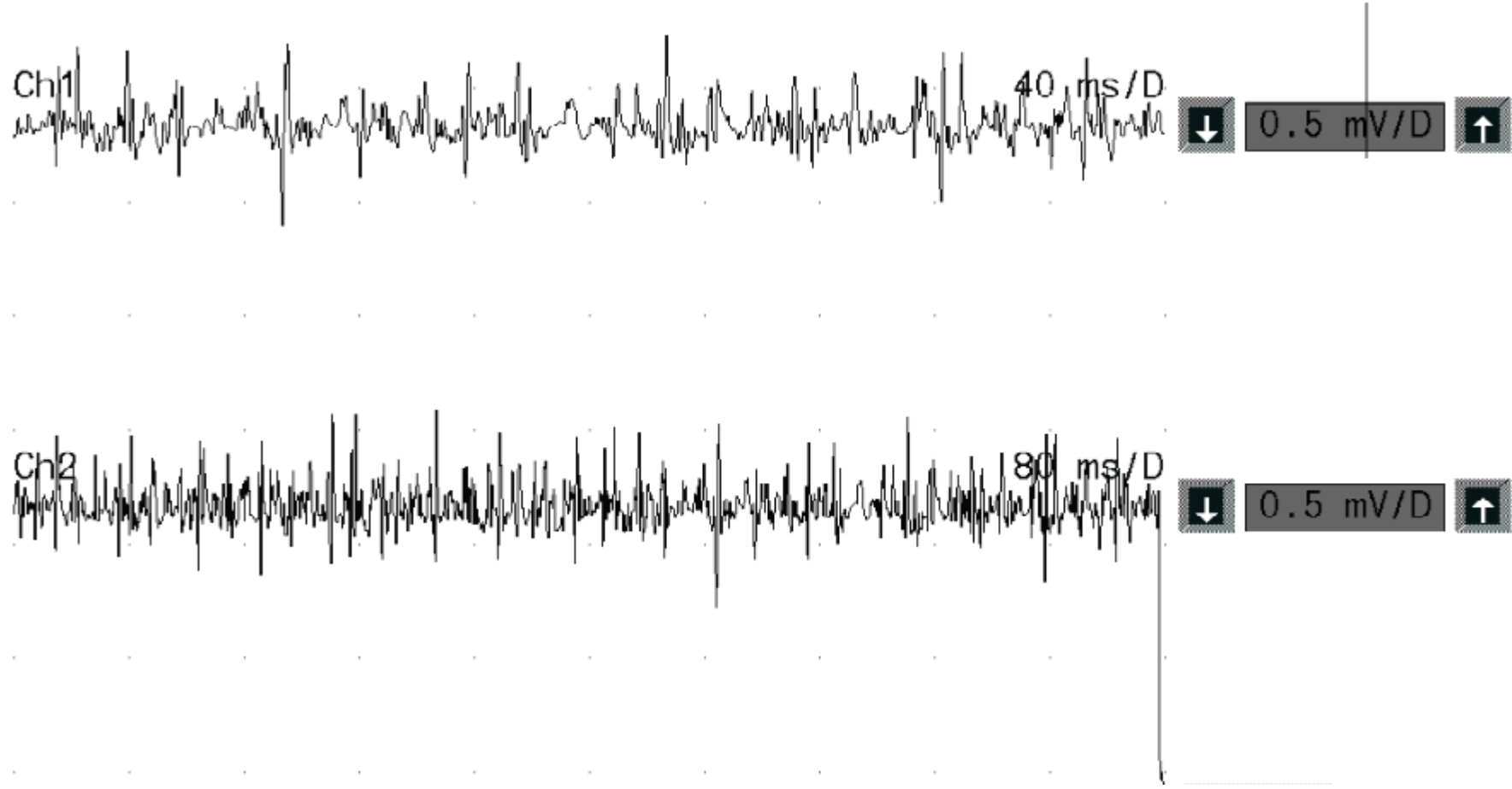


Figure 2

