



Acoustic and aerodynamic consequences of the nasal polyposis pathology

Amélie Elmerich, Angelique Amelot, Lise Crevier-Buchman, Shinji Maeda,
Jean-François Papon

► To cite this version:

Amélie Elmerich, Angelique Amelot, Lise Crevier-Buchman, Shinji Maeda, Jean-François Papon. Acoustic and aerodynamic consequences of the nasal polyposis pathology. 8th International Conference on Speech Motor Control, Aug 2022, Groningen, Netherlands. . hal-03850671

HAL Id: hal-03850671

<https://hal.science/hal-03850671>

Submitted on 14 Nov 2022

HAL is a multi-disciplinary open access archive for the deposit and dissemination of scientific research documents, whether they are published or not. The documents may come from teaching and research institutions in France or abroad, or from public or private research centers.

L'archive ouverte pluridisciplinaire **HAL**, est destinée au dépôt et à la diffusion de documents scientifiques de niveau recherche, publiés ou non, émanant des établissements d'enseignement et de recherche français ou étrangers, des laboratoires publics ou privés.

Background

Nasal cavities take part of the resonant system of speech. Nasal polyposis interferes with the configuration and airflow passage within the cavities, affecting not only the resonance but also the quality of nasal sounds (Hong et al., 1997). Depending on the degree of severity and in response to ineffective drug treatment, sinus surgery may be necessary.

Objectives

The goal of the current study is to evaluate the acoustic and aerodynamic effects of the nasal polyposis pathology from preoperative and postoperative data.


Methods



Four male patients with nasal polyposis recorded before and after surgery



Reading of a text with VNV and VCV sequences



Recordings of the nasal and oral airflow (l/s) with an acoustically transparent pneumotacograph mask

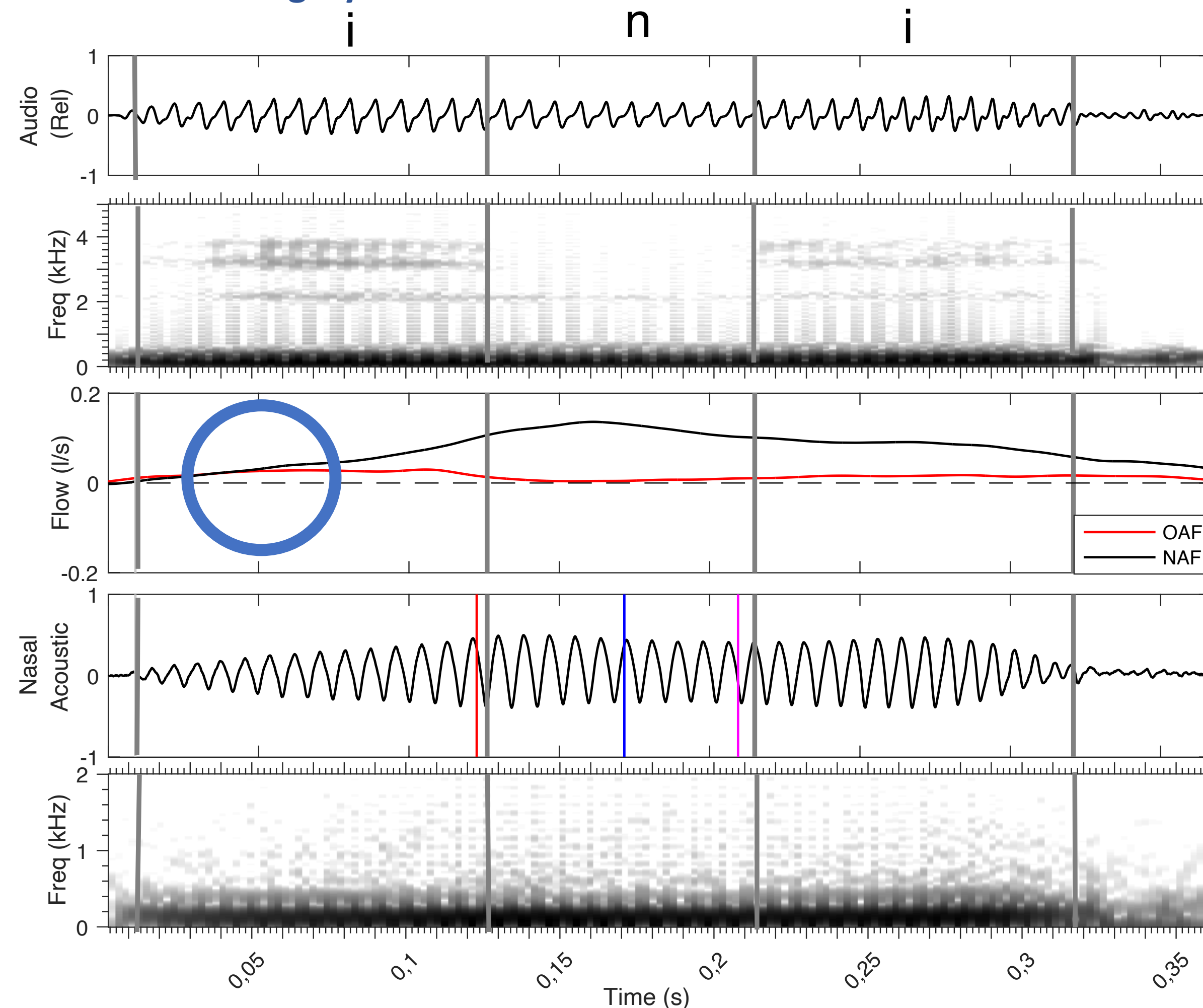
Audio signals were captured with a microphone.

Spectral slices were calculated in the nasal acoustic signal



Results

a. Before surgery



b. After surgery

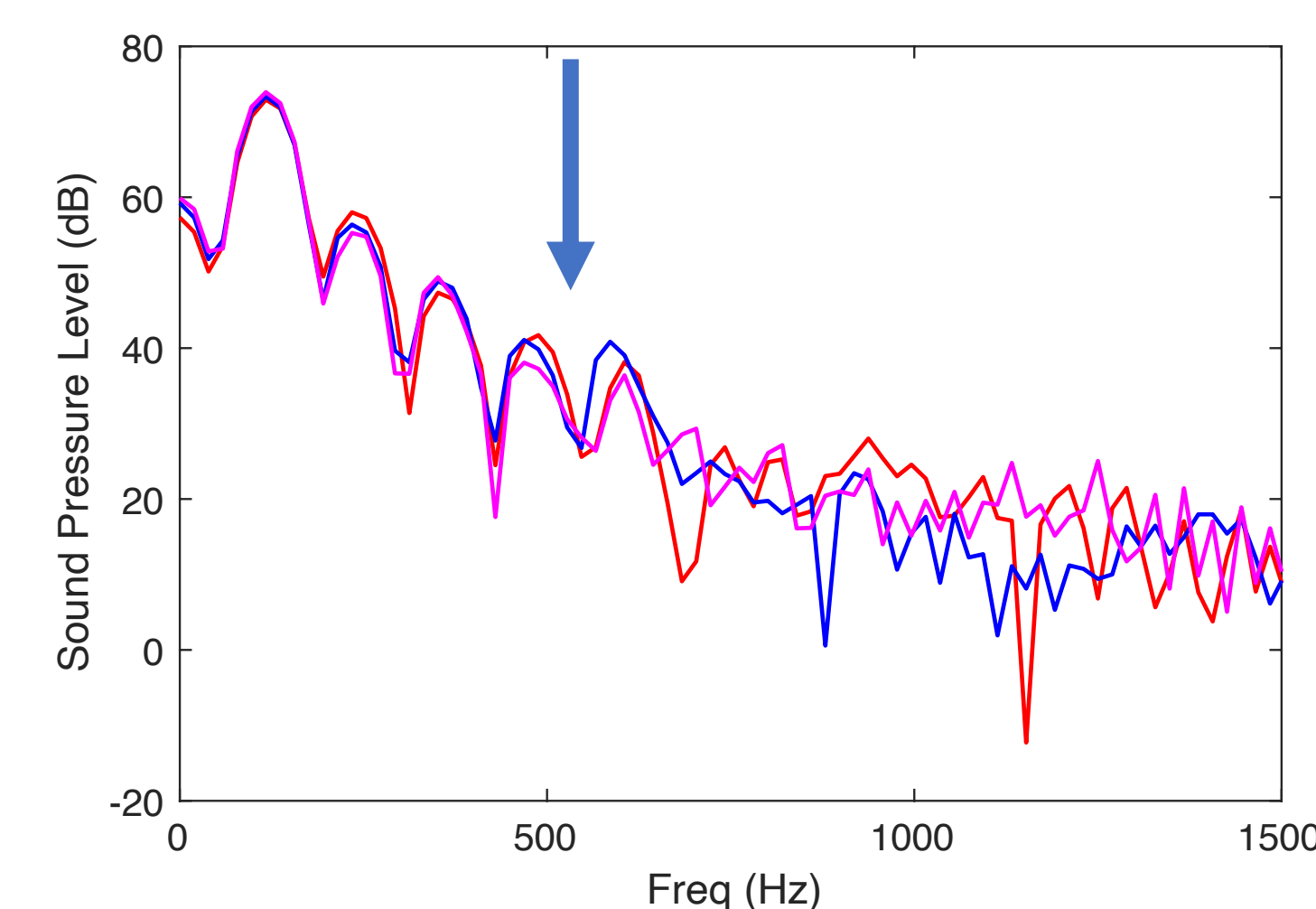
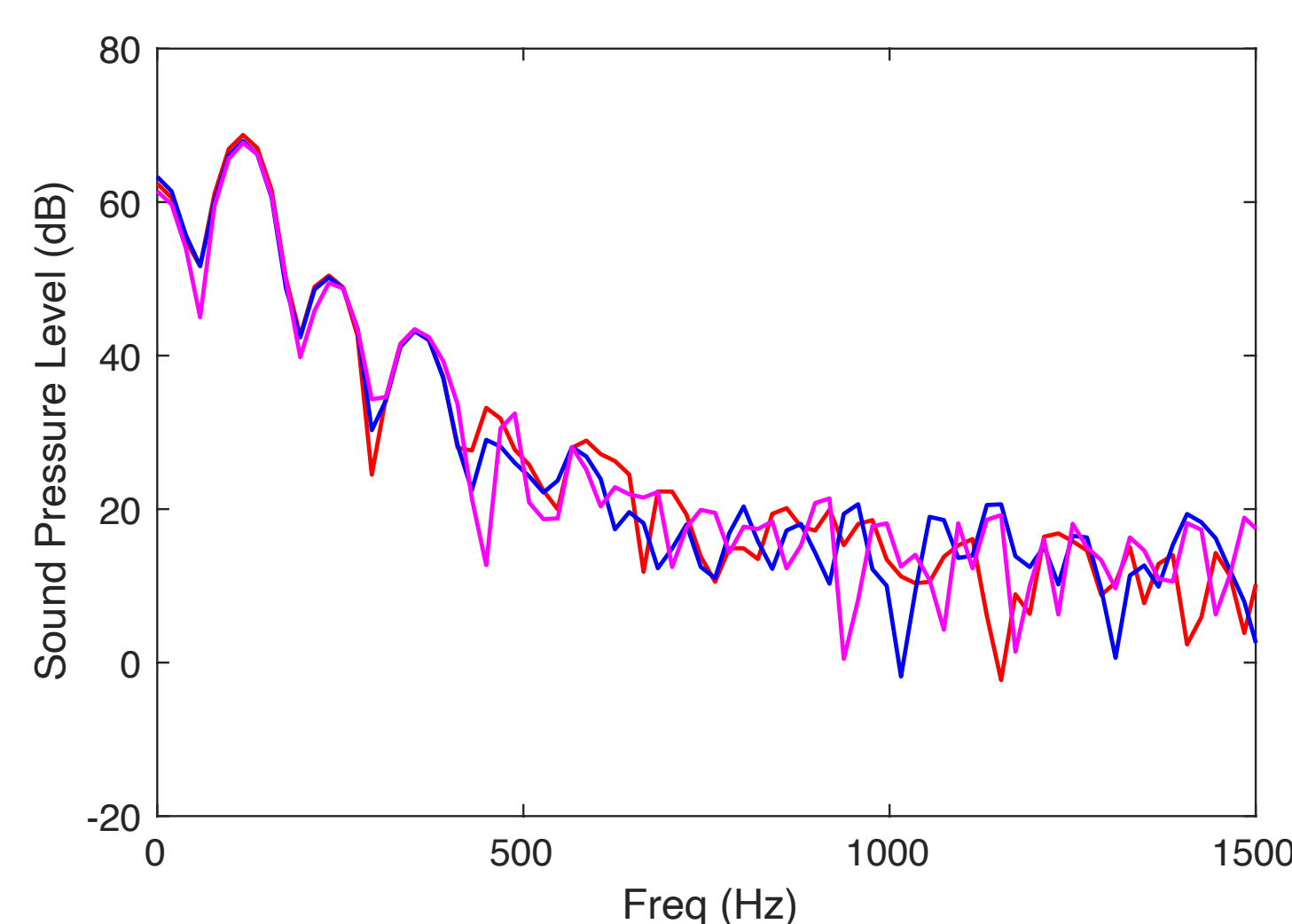
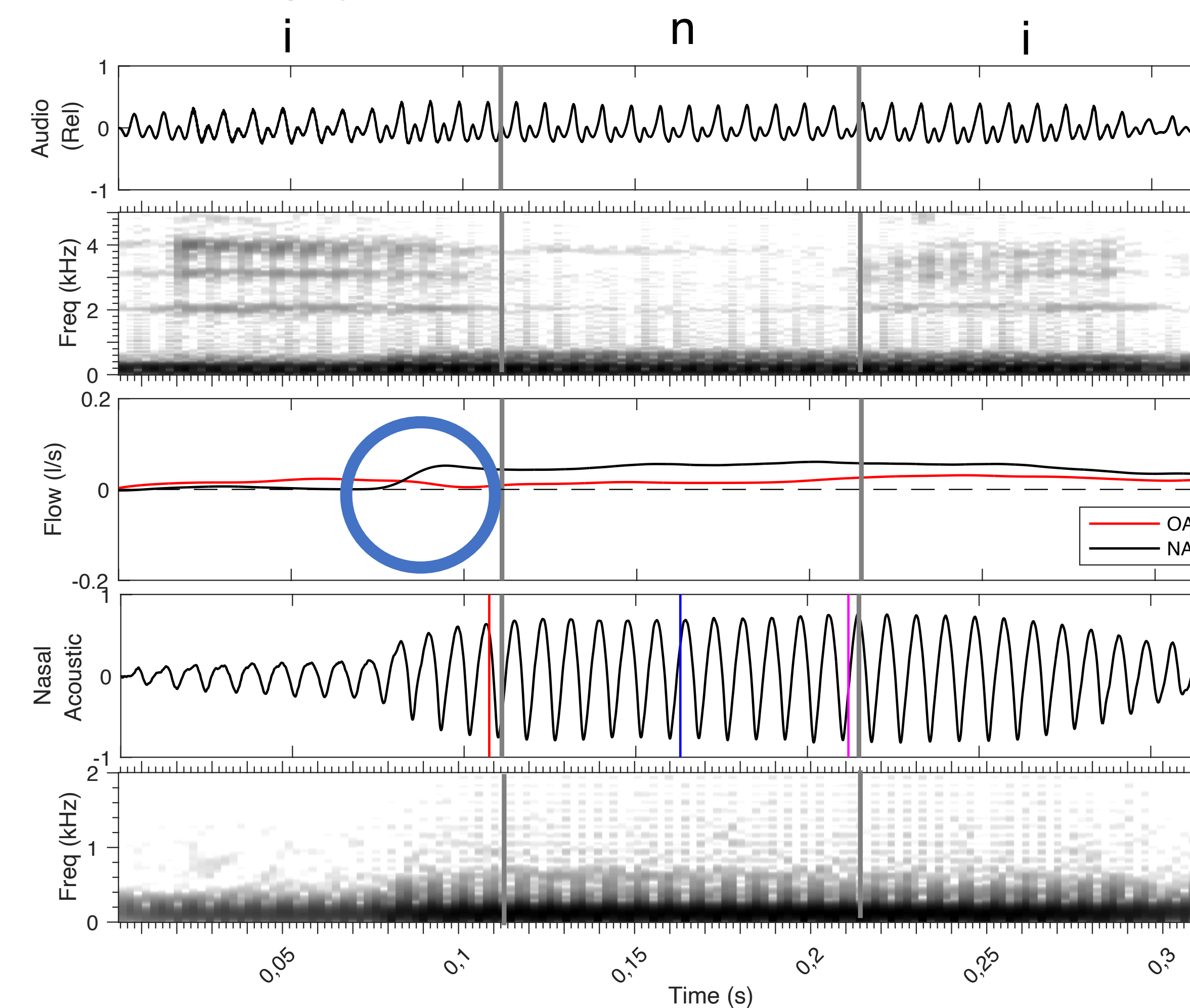


Figure: Acoustic and airflow records of [ini] utter by a patient before and after operation. From top to bottom row, (1) audio signal, (2) its spectrogram, (3) the nasal airflow (NAF in black) and oral airflow (OAF in red), (4) nasal acoustic signal, (5) its spectrogram, and (6) spectral slices sampled at the i-n boundary (red), n-center (blue), and n-release (n-i boundary, pink) in the nasal acoustic signal.

Aerodynamically :

- In preoperative, nasal airflow is present gradually and continuously, starting at the beginning of the first vowel.
- The amount of NAF decreases for the first vowel in postoperative. The opening of the velopharyngeal port is anticipated.
- The crossing point (○) between NAF and OAF in preoperative is gradual and less salient than in postoperative. This point comes at the end of the first vowel in postoperative; the opening of the velopharyngeal port seems to be punctually coordinated with the alveolar occlusion for /n/.

Acoustically :

- In the spectral slice, postoperatively : more intensity below 500 Hz and a double peak at 500 Hz (↓) probably due to the coupling between nasal cavities and sinuses (Maeda, 1982).
- Preoperative spectra appears to be highly damped, while the postoperative ones to be resonant.

Conclusion

The restoration of nasal permeability seems to restore aerodynamic and acoustic distinction for this patient.