



**HAL**  
open science

## Management of tinea capitis in children following the withdrawal of griseofulvin from the French market: A fast-track algorithm proposed by the Center of Evidence of the French Society of Dermatology

A Maruani, S Barbarot, J.P. Gangneux, M Caseris, C Moreau, A. S. Brun, F Botterel, J Menotti, J Toubiana, L Chouchana, et al.

### ► To cite this version:

A Maruani, S Barbarot, J.P. Gangneux, M Caseris, C Moreau, et al.. Management of tinea capitis in children following the withdrawal of griseofulvin from the French market: A fast-track algorithm proposed by the Center of Evidence of the French Society of Dermatology. *Annales de Dermatologie et de Vénérologie*, inPress, 10.1016/j.annder.2022.07.001 . hal-03837146

HAL Id: hal-03837146

<https://hal.science/hal-03837146v1>

Submitted on 4 Nov 2022

**HAL** is a multi-disciplinary open access archive for the deposit and dissemination of scientific research documents, whether they are published or not. The documents may come from teaching and research institutions in France or abroad, or from public or private research centers.

L'archive ouverte pluridisciplinaire **HAL**, est destinée au dépôt et à la diffusion de documents scientifiques de niveau recherche, publiés ou non, émanant des établissements d'enseignement et de recherche français ou étrangers, des laboratoires publics ou privés.

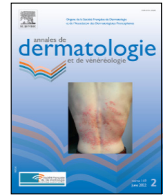


Distributed under a Creative Commons Attribution - NonCommercial - NoDerivatives 4.0 International License



Available online at  
**ScienceDirect**  
[www.sciencedirect.com](http://www.sciencedirect.com)

Elsevier Masson France  
**EM|consulte**  
[www.em-consulte.com/en](http://www.em-consulte.com/en)



## Perspective-opinion

# Management of *tinea capitis* in children following the withdrawal of griseofulvin from the French market: A fast-track algorithm proposed by the Center of Evidence of the French Society of Dermatology

A. Maruani <sup>a,b,1,\*</sup>, S. Barbarot <sup>b,c,1</sup>, J.P. Gangneux <sup>d,e,1</sup>, M. Caseris <sup>f,g</sup>, C. Moreau <sup>h</sup>, S. Brun <sup>i,e</sup>, F. Botterel <sup>j,e</sup>, J. Menotti <sup>k,e</sup>, J. Toubiana <sup>l</sup>, L. Chouchana <sup>m,n</sup>, M. Beylot-Barry <sup>o,p,1</sup>, N. Dupin <sup>p,q,1</sup>, B. Guillot <sup>n,o,1,1</sup>, O. Chosidow <sup>r,s,t,u,1</sup>

<sup>a</sup> Universités de Tours et Nantes, Inserm 1246-SPHERE, CHRU de Tours, service de dermatologie, unité de dermatologie pédiatrique, 37000 Tours, France

<sup>b</sup> Centre de Preuves en Dermatologie, Société Française de Dermatologie Pédiatrique, Société Française de Dermatologie, France

<sup>c</sup> Nantes Université, Service de Dermatologie, CHU Nantes, UMR 1280 PhAN, INRAE, F-44000 Nantes, France

<sup>d</sup> Service de Parasitologie-Mycologie, CHU de Rennes, Univ Rennes, Inserm, Irset (Institut de recherche en santé, environnement et travail) – UMR\_S 1085, F35000 Rennes, France

<sup>e</sup> Société Française de Mycologie Médicale, France

<sup>f</sup> Infectiologie mobile, Hôpital Robert Debré, AP-HP, 75019 Paris, France

<sup>g</sup> Groupe de Pathologie Infectieuse Pédiatrique de la Société Française de Pédiatrie, France

<sup>h</sup> Service Pharmacie, Hôpital Robert-Debré (AP-HP), 75019 Paris, France

<sup>i</sup> Service de Parasitologie-Mycologie, Hôpital Avicenne, AP-HP, Université Sorbonne Paris Nord, Bobigny, France

<sup>j</sup> Unité de Parasitologie – Mycologie, Département de Prévention, diagnostic et traitement des infections, CHU de Créteil, AP-HP, Université Paris Est Créteil, Créteil, France

<sup>k</sup> Service de Parasitologie et Mycologie Médicale, Institut des Agents Infectieux, Hospices Civils de Lyon / Université Lyon 1, Lyon, France

<sup>l</sup> Service de pédiatrie générale et maladies infectieuses, Hôpital Necker Enfants malades, AP-HP, Université de Paris, Paris, France

<sup>m</sup> Centre Régional de Pharmacovigilance, Service de Pharmacologie, EA 7323 Pharmacologie et Evaluation des Thérapeutiques chez l'enfant et la femme enceinte, Hôpital Cochin, AP-HP, Université de Paris, Paris, France

<sup>n</sup> Société Française de Pharmacologie et Thérapeutique, France

<sup>o</sup> Service de Dermatologie, CHU de Bordeaux, INSERM U1053, Bordeaux, France

<sup>p</sup> Centre de Preuves en Dermatologie, Société Française de Dermatologie, France

<sup>q</sup> Service de dermatologie Hôpital Cochin AP-HP, Paris, France

<sup>r</sup> Université de Montpellier, Montpellier, France

<sup>s</sup> Service de Dermatologie, Hôpitaux Universitaires Henri-Mondor, AP-HP, Créteil, France

<sup>t</sup> Universités de Tours et Nantes, Inserm 1246-SPHERE, France

<sup>u</sup> Centre de Preuves en Dermatologie, GrIDIST Groupe Infectiologie Dermatologique, ISD-SIDA, Société Française de Dermatologie, Paris, France

## ARTICLE INFO

### Article history:

Received 15 November 2021

Accepted 12 July 2022

Available online xxx

### Keywords:

Dermatophytes

*Tinea capitis*

Children

Treatment

Griseofulvin

Terbinafine

\* Corresponding author at: Department of Dermatology, Unit of Pediatric Dermatology, Center of Reference of Vascular Anomalies MAGEC-Tours, CHRU Tours, 37044 Tours Cedex 9, France.

E-mail address: [annabel.maruani@univ-tours.fr](mailto:annabel.maruani@univ-tours.fr) (A. Maruani).

<sup>1</sup> These authors equally contributed to the manuscript.

<https://doi.org/10.1016/j.annder.2022.07.001>

0151-9638/© 2022 The Authors. Published by Elsevier Masson SAS.

This is an open access article under the CC BY-NC-ND license (<http://creativecommons.org/licenses/by-nc-nd/4.0/>).

Please cite this article as: A. Maruani, S. Barbarot, J.P. Gangneux et al., Management of *tinea capitis* in children following the withdrawal of griseofulvin from the French market: A fast-track algorithm proposed by the Center of Evidence of the French Society of Dermatology, *Annales de Dermatologie et de Vénérologie*, <https://doi.org/10.1016/j.annder.2022.07.001>

## 1. Introduction

*Tinea capitis* is a common contagious dermatophyte infection of the scalp and hair predominantly seen in children. Although the diagnosis may be strongly suspected on physical examination, microscopic morphological examination and culture or molecular biology are recommended wherever possible to identify the species of dermatophyte involved and thus ensure the most suitable therapeutic choice. The prevalence of the causative fungi varies by geographic location throughout the world [1,2]. In Europe, *tinea capitis* is now mainly caused by anthropophilic *Trichophyton* species (*T. soudanense*, *T. tonsurans*) and less often by *Microsporum* species (*M. canis*, zoophilic; *M. audouinii*, anthropophilic) [3,4].

Treatment of *tinea capitis* consists of systemic antifungals and adjuvant topical antifungals. Indeed, topical drugs are not sufficient to cure the disease and prevent spreading [5].

Griseofulvin, a fungistatic drug, is the only systemic treatment with marketing authorization in France for pediatric *tinea capitis*. In September 2007, terbinafine hydrochloride (Lamisil® Oral Granules) was approved by the US Food and Drug Administration as an alternative to griseofulvin in this indication in children from the age of 4 years [6].

In early 2021, griseofulvin was withdrawn from the market in France. At that time the French national medicines agency (Agence Nationale de Sécurité des Médicaments -ANSM-) asked French medical societies involved in the management of pediatric *tinea capitis* to examine the currently available therapeutic options for children and to propose alternative options without delay. The purpose of this paper is to provide the French algorithm proposal for alternatives, based on expert consensus.

A multidisciplinary panel of French experts, coordinated by the Centre of Evidence of the French Society of Dermatology, met 5 times between April 23, 2021 and June 6, 2021. The panel consisted of members of the French Society of Dermatology (SFD), the French Society of Medical Mycology, the French Society of Pediatric Dermatology, the French Society of Pediatrics, the Society for Infectious Pathology of French Language, and the French Society of Pharmacology and Therapeutics. The experts decided to create an

easy-to-use tool (i.e., a “management” algorithm), available within 2 months for all physicians, based on the current state of knowledge about the fungi responsible for *tinea capitis*, a non-systematic review of the literature, previous European guidelines, and their own expert report [1–5,7–11]. The algorithm and the supplemental information were approved by the ANSM in July 9, 2021 (<https://ansm.sante.fr/actualites/traitement-de-la-teigne-de-lenfant-et-indisponibilite-de-la-griseofulvine-lansm-precise-la-conduite-a-tenir>), and are available at: <https://centredepreuves.sfdermato.org/#hot-topics-english-translation>.

The main points set out in the recommendations are as follows:

- High recommendation concerning taking of hair sample and skin scrapings for microscopic examination and culture in the case of clinical suspicion of *tinea capitis*. The aim is to identify the dermatophyte species in the event of further treatment failure, and to better target antifungal treatment if necessary.
- Probabilistic treatment: terbinafine is preferred for *tinea capitis* caused by *Trichophyton* spp. and itraconazole for *Microsporum* spp. infection. Thus for children weighing  $\geq 10$  kg, oral terbinafine (once a day taken during a meal) for 4 weeks should be the first-line probabilistic treatment because *Trichophyton* species are the most prevalent, with adaptation of the dose regimen to the child's weight (10 to 20 kg: 62.5 mg/d; 21 to 40 kg: 125 mg/d;  $> 40$  kg: 250 mg/d).
- Appropriate treatment based on microscopic examination: if a *Microsporum* sp. is identified, we recommend switching terbinafine to oral itraconazole (once a day outside meal-times) for 6 weeks (10 to 20 kg: 50 mg/d;  $> 20$  kg: 100 mg/d). If *Trichophyton* sp. infection is confirmed, we recommend maintaining terbinafine.
- The evidence is unclear regarding routine liver monitoring (gamma-glutamyl transferase, aspartate aminotransferase, alanine aminotransferase) prior to terbinafine or itraconazole treatment and 2 to 4 weeks after [8,10–12]. We recommend case-by-case decisions on such monitoring and

2021

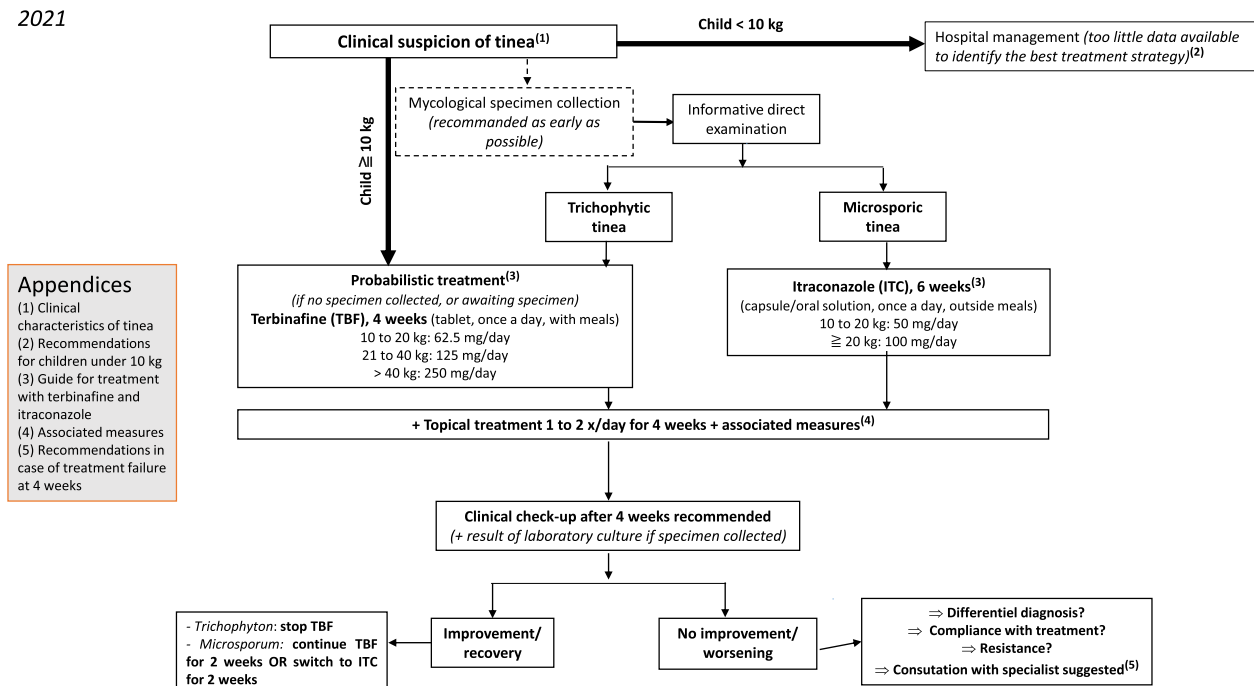


Fig. 1. Algorithm for management of *tinea capitis* in children following withdrawal of the MA for griseofulvin.

performance of lab monitoring in the case of risk factors for impaired liver function. In all cases, parents and children should be advised to discontinue treatment and consult a physician as soon as possible in the event of symptoms of acute liver damage (i.e., gastrointestinal symptoms, jaundice, asthenia, fever, rash, etc.)

- v) Topical antifungal drugs and additional measures (e.g. screening of parents, siblings and animals; washing at 60 °C of all towels, bedding etc., coming in contact with the child's head, etc.) are recommended in addition to systemic treatment.
- vi) Systematic clinical control is recommended after 4 weeks of treatment to assess treatment efficacy and correlate it with culture results. Clinical examination may reveal the following 5 possible situations, with potential solutions given:
  - 1) Completely healing of *tinea capitis*, leading to treatment withdrawal, unless *Microsporum sp.* is evidenced on culture, in which case treatment should be maintained for a further 2 weeks.
  - 2) Alleviation of *tinea capitis* but without complete resolution with evidence of *Trichophyton sp.* on culture, in which case terbinafine should be maintained for a further 2 weeks.
  - 3) Alleviation of *tinea capitis* but without complete resolution, with evidence of *Microsporum sp.*; in this case, terbinafine may be maintained for a further 2 weeks or switched to itraconazole for a further 2 weeks.
  - 4) No alleviation of *tinea capitis* or even worsening, with fungal culture showing positivity for *Microsporum sp.*; terbinafine should be switched to itraconazole for a complete 6-week course of treatment.
  - 5) No clinical improvement (or even worsening), and initial samples either not taken or negative: in the absence of therapeutic non-compliance, the child should be referred to a tertiary medical center to reassess the diagnosis and take samples for testing of antifungal drug resistance [13].
- vii) Infants <10 kg with *tinea capitis* should be referred to a tertiary medical center because of the lack of sufficient data on which to base recommendations [14,15]. Indeed pharmacokinetic and safety data are lacking in infants; terbinafine is not FDA-approved for infants, cutting the tablets into quarters is not optimal, and, although technically possible, reconstitution of the medication as an oral solution is not widespread; data regarding itraconazole at this age are scant, and an oral suspension of fluconazole may be used in newborns but is not indicated for *tinea capitis* due to inconstant efficacy [16]; topical drugs are usually not sufficiently efficacious, except for very limited fungal infections. Thus except for infections in a very limited area, treatment of *tinea capitis* in infants may include terbinafine 5 mg/kg/d, itraconazole 3–5 mg/kg/d or fluconazole 6–8 mg/kg/d for 4–6 weeks, with regular follow-up and lab monitoring.

In conclusion, the Center of Evidence of the SFD, in consultation with scientific societies, coordinated fast-track recommendations to deal with a public health situation of concern and rapidly provide therapeutic alternatives to the discontinued agent griseofulvin for *tinea capitis* in France. Because griseofulvin is becoming less and less readily available in countries throughout Europe, these recommendations may be useful beyond France. They are in line with previous British and German guidelines but are different in their presentation, since we created a pragmatic easy-to-use

algorithm (Fig. 1) [10,11]. Although the gold standard for guideline development is based on systematic reviews and meta-analyses of the literature, this is a long process that does not enable the rapid provision of answers. In addition, we were limited by the paucity of drug studies in children, especially in infants. This new situation highlights the value of creating registers to collect data for infants <10 kg presenting *tinea capitis* or for special cases such as resistance to antifungal drugs.

#### Declaration of Competing Interest

The authors declare that they have no known competing financial interests or personal relationships that could have appeared to influence the work reported in this paper.

#### Acknowledgements

We thank the other members of the Center of Evidence of the French Society of Dermatology, including: Antoine Bertolotti, Guillaume Chaby, Florence Corgibet, Laurence Fardet, Nicole Jouan, Denis Jullien, Sophie Leducq, Eve Pépin, Florence Poizeau, Jean-François Sei, and Delphine Staumont. We would also like to thank Mr Laurent Elgard for managing the website of the Center of Evidence of the SFD.

#### References

- [1] Nguyen CV, Collier S, Merten AH, Maguiness SM, Hook KP. *Tinea capitis*: A single-institution retrospective review from 2010 to 2015. *Pediatr Dermatol* 2020;37(2):305–10.
- [2] Zhi H, Shen H, Zhong Y, Sang Bo, Lv W, Li Q, et al. *Tinea capitis* in children: A single-institution retrospective review from 2011 to 2019. *Mycoses* 2021;64(5):550–4.
- [3] Ginter-Hanselmayer G, Weger W, Ilkit M, Smolle J. Epidemiology of *tinea capitis* in Europe: current state and changing patterns. *Mycoses* 2007;50(s2):6–13.
- [4] Gangneux J-P, Bougnoux M-E, Hennequin C, Godet C, Chandener J, Denning DW, et al. An estimation of burden of serious fungal infections in France. *J Mycol Med* 2016;26(4):385–90.
- [5] Greer DL. Successful treatment of *tinea capitis* with 2% ketoconazole shampoo. *Int J Dermatol* 2000;39(4):302–4.
- [6] Van Niel CW. Terbinafine granules approved by FDA for *tinea capitis*. *NEJM J Watch* 2007. <https://www.jwatch.org/pa200711210000001/2007/11/21/terbinafine-granules-approved-fda-tinea-capitis> [consulted on September 2021, 20].
- [7] Chen X, Jiang X, Yang M, González U, Lin X, Hua X, et al. Systemic antifungal therapy for *tinea capitis* in children (review). *Cochrane Database Syst Rev* 2016;2016(5).
- [8] Gupta AK, Mays RR, Versteeg SG, Piraccini BM, Shear NH, Piguet V, et al. *Tinea capitis* in children: a systematic review of management. *J Acad Dermatol Venereol* 2018;32(12):2264–74.
- [9] Foster KW, Friedlander SF, Panzer H, Ghannom MA, Elewski BE. A randomized controlled trial assessing the efficacy of fluconazole in the treatment of pediatric *tinea capitis*. *J Am Acad Dermatol* 2005;53(5):798–809.
- [10] Mays P, Nenoff P, Reinell D, Abeck D, Brasch J, Daeschlein G, et al. S1 guidelines: *Tinea capitis*. *J Dtsch Dermatol Ges* 2020;18(2):161–79.
- [11] Fuller LC, Barton RC, Mohd Mustapa MF, Proudfoot LE, Punjabi SP, Higgins EM. British Association of Dermatologists' guidelines for the management of *tinea capitis* 2014 Br. *J Dermatol* 2014;171:454–63.
- [12] Stolmeier DA, Stratman HB, McIntee TJ, Stratman EJ. Utility of laboratory test result monitoring in patients taking oral terbinafine or griseofulvin for dermatophyte infections. *JAMA Dermatol* 2018;154:1409–16.
- [13] Saunte DML, Pereiro-Ferreirós M, Rodríguez-Cerdeira C, Sergeev AY, Arabatzis M, Prohić A, et al. Emerging antifungal treatment failure of dermatophytosis in Europe: take care or it may become endemic. *J Eur Acad Dermatol Venereol* 2021;35(7):1582–6.
- [14] Binder B, Richtig E, Weger W, Ginter-Hanselmayer G. *Tinea capitis* in early infancy treated with itraconazole: a pilot study. *J Eur Acad Dermatol Venereol* 2009;23:1161–3.
- [15] Zaraq I, Hawilo A, Trojjet S, El Euch D, Mokni M, Ben OA. Letter: *Tinea capitis* in infants in their first 2 years of life: A 12-year study and a review of the literature. *Dermatol Online J* 2012;18:16.
- [16] Gupta AK, Bamimore MA, Renaud HJ, Shear NH, Piguet V. A network meta-analysis on the efficacy and safety of monotherapies for *tinea capitis*, and an assessment of evidence quality. *Pediatr Dermatol* 2020;37(6):1014–22.