



**HAL**  
open science

## Assessing the incidence of nerve injuries according to different mandibular osteotomies including Wing osteotomies

G. Cordier, N. Sigaux, J. Giai, B. Ibrahim, P. Cresseaux

► **To cite this version:**

G. Cordier, N. Sigaux, J. Giai, B. Ibrahim, P. Cresseaux. Assessing the incidence of nerve injuries according to different mandibular osteotomies including Wing osteotomies. *Journal of Stomatology, Oral and Maxillofacial Surgery*, 2021, 122 (5), pp.472-476. 10.1016/j.jormas.2020.09.006 . hal-03836863

**HAL Id: hal-03836863**

**<https://hal.science/hal-03836863>**

Submitted on 5 Jan 2024

**HAL** is a multi-disciplinary open access archive for the deposit and dissemination of scientific research documents, whether they are published or not. The documents may come from teaching and research institutions in France or abroad, or from public or private research centers.

L'archive ouverte pluridisciplinaire **HAL**, est destinée au dépôt et à la diffusion de documents scientifiques de niveau recherche, publiés ou non, émanant des établissements d'enseignement et de recherche français ou étrangers, des laboratoires publics ou privés.



Distributed under a Creative Commons Attribution - NonCommercial 4.0 International License

# **Assessing the incidence of nerve injuries according to different mandibular osteotomies including Wing osteotomies.**

## **Authors**

First author: G. Cordier<sup>1</sup>

Order of authors: G. Cordier<sup>1</sup>, N. Sigaux<sup>1</sup>, J. Giai<sup>1</sup>, B. Ibrahim<sup>1</sup>, P. Cresseaux<sup>2</sup>

Corresponding author:

G. Cordier<sup>1</sup>, mail: [cordier\\_guillaume@hotmail.fr](mailto:cordier_guillaume@hotmail.fr)

P. Cresseaux<sup>2</sup>, mail: [p.cresseaux@orange.fr](mailto:p.cresseaux@orange.fr)

<sup>1</sup>Department of Maxillofacial and Facial Plastic Surgery, Lyon Sud Hospital, Hospices Civils de Lyon, 165 chemin du grand Revoyet 69495 Pierre Benite; Claude Bernard Lyon 1 University

<sup>2</sup>Chirurgie Maxillo-Faciale, Hôpital Privé Jean Mermoz, 55 Avenue Jean Mermoz, 69008 Lyon

**Key words**

Bilateral Sagittal Split Osteotomy (BSSO), Chin Wing, Mini Wing, Orthognathic surgery, inferior alveolar nerve

## Abstract

We use currently 3 types of new mandibular osteotomies (a shortened bilateral sagittal split osteotomy (BSSO), associated or not with Chin Wing or Mini Wing). Chin osteotomy is a modified genioplasty extended along the basilar border and the angles of the mandible. These osteotomies are associated with a risk of inferior alveolar nerve (IAN) damage.

We prospectively studied 113 consecutive patients operated on by the same surgeon who underwent one of the following procedures: 1) isolated BSSO, 2) BSSO with a Chin Wing, 3) BSSO with a Mini Wing, 4) isolated Chin Wing. We analyzed rates of IAN damage and impact on the patients' life by using a subjective questionnaire administered at the patient's 1 year follow up appointment between June 2018 and August 2019.

Sixty-seven patients underwent isolated BSSO, 24 BSSO with Mini Wing, 13 BSSO with Chin Wing, and 9 Chin Wing only. Our analysis reveals that nerve damage is greater in the BSSO group associated with Chin Wing (50 % vs 21,6%;  $p= 0.006$ ). However, there is no significant difference between nerve damage in the Mini wing group and the isolated BSSO group (27,1% vs 21,6%;  $p= 0.432$ ). In the isolated Chin Wing group, the inferior alveolar nerve damage rate was 11 %. There is no significant difference between the groups with regard to the impact of the nerve damage on the patients' life.

In case of BSSO with concomitant Wing osteotomy, we conclude that Mini Wing osteotomies cause less nerve related morbidity than Chin Wing.

## Introduction

Two types of mandibular osteotomies are most commonly used: Bilateral Sagittal Split osteotomy (BSSO) and genioplasty. We have however chosen to develop another approach, for a couple of years, by using a shortened BSSO and two variants of genioplasty: the Chin Wing and the Mini Wing. The Chin Wing was first introduced by Dr. Triaca in 2009 (1–3). It is a modified genioplasty extending along the basilar border of the mandible up to the angles. Dr. Cresseaux has described a simplified version of the Chin Wing, known as the Mini Wing (4). The primary indication for Wing osteotomies is retrogenia. We perform a shortened bilateral sagittal split osteotomy (5) when a concomitant sagittal mandibular movement is required in order to incorporate Wing osteotomies in all our orthodontic-surgical protocols. The rate of inferior alveolar nerve (IAN) damage in classic BSSO ranges from 8 % to 40 % (6–13). There are practically no studies focusing on IAN damage specifically in Wing osteotomies. Only one study conducted by Tabrizi et al, found an IAN damage of 20 % one year post-operation, on 10 patients having had a Chin Wing surgery (14). There is a risk of IAN damage in Wing surgeries, due to the orientation of the osteotomy line. Our aim was to evaluate the incidence of IAN damage in the different mandibular osteotomies including Wing osteotomies that we performed.

## Materials and methods

We conducted a prospective case series study performed in a single center between June 2018 and August 2019. All patients were operated on 1 year earlier by the same surgeon (P. Cresseaux). The preoperative assessment included a cone beam computed tomography (CBCT) to control the position of the inferior alveolar nerve (IAN). The vertical position of the IAN, its distance from the basilar rim, and distance from buccal cortical plate of the mandible were assessed on coronal sections of the CBCT.

We use 3 different techniques and their combinations: modified BSSO/Chin Wing/Mini Wing (fig. 2). All surgeries were performed under general anesthesia with subperiosteal infiltration with 1% adrenaline solution. The BSSO line uses a shortened version (5) allowing for the association of the Chin Wing as described by Triaca (1,2), or Mini Wing (4).

The surgery was followed by systematic clinic visits at one week, one month. A clinical and radiologic assessment was performed at the one-year postoperative consultation (pictures of the patient, frontal and lateral cephalogram, panoramic radiograph and CBCT).

All patients were recruited in the study during their 1 post-operative follow up appointment. During this visit, patients were given a satisfaction questionnaire. This questionnaire evaluated the functional and aesthetic results as well as postoperative complications. The complications related domain of the questionnaire focused mainly on nerve disorders. Nerve damage was assessed via the following three questions:

Do you currently have:

- A loss of sensitivity of the lower right lip?
- A loss of sensitivity of the lower left lip?
- If that is the case, would you say that this loss of sensitivity has an impact on your everyday life?

Answer choices were:

- Absent (0);
- Low (1);
- Medium (2);
- Important (3);
- Complete (4).

The questionnaire was given with a consent form in accordance with our institution's ethical committee requirements.

Patients were separated in four based on the type of mandible surgery that they had undergone: 1) isolated BSSO 2) Mini Wing + BSSO 3) Chin Wing + BSSO 4) isolated Chin Wing. Some surgeries were combined with a maxillary surgery. We performed a comparative analysis of IAN damage within groups 1 to 3. Group 4 was not comparable to the others as BSSO itself increases nerve damage.

Data is presented using descriptive statistics. Fisher's exact test was used to determine whether significant differences in proportions of IAN damage and quality of life outcomes were observed amongst the first three groups. Alpha risk was set at 5%. R Software version 3.5.0 was used for all analyzes.

## Results

113 consecutive patients have answered our questionnaire. Sixty-seven had an isolated BSSO, 24 an BSSO with Mini Wing, 13 had an BSSO with classical Chin Wing, and 9 had an isolated Chin Wing. All patients agreed to answer the questionnaire. The first three group had comparable baseline characteristics. The fourth group had a younger median age and had had a shorter median time to evaluation. All of the patients' follow up appointments took place at least 6 months after their surgery (tab. 1).

Nerve damage was analyzed for each hemi-mandible separately without specifying the side. We therefore considered 134 osteotomies the isolated BSSO group, 48 in the Mini Wing + BSSO group, and 24 in the Chin Wing + BSSO group. Rates of IAN damage are shown in table 2. A higher rate of IAN damage was noted in BSSO with wing osteotomies. The Chin Wing + BSSO group shows a significant increase in nerve damage one year after surgery compared to the isolated BSSO control group (50% vs 21,6%;  $p=0.006$ ). However, there is no significant increase in nerve damage when comparing the Mini Wing + BSSO group to the control group (27,1% vs 21,6%;  $p=0,432$ ). With regard to the evaluation of nerve damage depending on different levels of severity, similar results were found: a significant increase in IAN damage in the Chin Wing + BSSO group in comparison with the control group ( $p<0,001$ ) as opposed to the Mini-Wing + BSSO group ( $p=0,14$ ) (tab. 3).

The fourth group shows an IAN nerve damage rate of 11 % (for 18 hemi-mandibles). This confirms that the Chin Wing osteotomy is in and of itself associated to a baseline rate of iatrogenic IAN damage.

Despite greater nerve damage in our BSSO group associated with Wing osteotomies, there was no significant difference in the impact on our patients' life (tab. 4).

## Discussion

Our study demonstrates an increased rate of IAN damage when performing a Wing osteotomy associated with a BSSO in comparison to isolated BSSO. However, this increase is not significant for the Mini Wing unlike in the Chin Wing group. The Mini Wing seems to be associated to less iatrogenic nerve damage than the Chin Wing. However, the Chin Wing increased IAN damage rate does not seem to have a significant negative impact on the patient's life, and therefore be considered acceptable by patient.

Very few studies specifically focus on nerve damage in isolated genioplasty and existing studies show nerve damage rates that are close to zero (15–17). Our study reveals that the isolated Chin Wing presents an IAN damage rate of 11 % for 9 patients (i.e. 18 hemi-mandibles). Chin Wing therefore increases the risk of nerve damage compared to a classic genioplasty.

As far as the isolated BSSO is concerned, we find an IAN nerve damage rate of 21,6 %. Our results are globally similar to the rates of nerve damage in the general orthognathic surgery literature, which range from 8 % to 40 % (6–13). This rate of nerve damage varies according to many parameters: the age of the patient, the experience of the surgeon and the type of BSSO. Our shortened BSSO consequently does not present an additional risk of nerve damage in comparison with classic BSSO.

McLeod et al's review of the literature confirms that nerve damage is greater when BSSO is associated with a genioplasty (6). Similarly, our results demonstrate an increased nerve damage rate in BSSO associated with a Wing osteotomy. But when a BSSO is part of the surgical plan, the Mini Wing should be favored. It is simpler, faster and is associated to less iatrogenic IAN damage than the Chin Wing. This is explained by the orientation of the osteotomy line which is different in the Mini Wing and the Chin Wing (fig. 1). The IAN has an elliptical trajectory within the mandible (18) and its lowest point is next to the first molar (19–22), which corresponds to the zone of highest risk for iatrogenic damage. In the Chin Wing, the osteotomy goes all the way to the angles and is therefore made higher on the mandible. This increases the risk of nerve damage. It is therefore necessary to preoperatively detect the lowest position of the IAN via a CBCT.

However, it is very difficult to compare the results of different nerve damage studies as there is no standardized test for the assessment of IAN damage. Indeed, some studies choose to conduct a subjective evaluation while others use objective testing (using criteria such as touch sensation, two-point discrimination, hot-cold, pain), or a combination of both. The subjective questionnaires have been reported both to over (23,24) and under (25,26) estimate nerve damage compared to objective testing. We have therefore chosen to conduct a purely subjective evaluation in view of the absence of standardization. Our rationale was to refocus the analysis on the patient's sensations and the repercussion of the surgery on their everyday life. We decided to limit the number of questions as much as possible in order to decrease the risk of inattentive responses and engage maximally the patient in the questionnaire. We prospectively included all patients presenting consecutively to their one-year post-operative appointment between June 2018 and August 2019. Our response rate to the questionnaire was of 100 %.

Taken together, the findings of the present paper allow us to suggest new indications for Wing osteotomies. We believe that the Mini Wing could replace the classic genioplasty in most cases, due to its relatively low rate of iatrogenic nerve damage and its improved functional and esthetic results versus genioplasty. The Mini Wing seems to be a better choice than Chin Wing when a BSSO is to be performed concomitantly. It can be associated with any classic osteotomy (Epker (27) or Obwegeser (28)), as long as it is done with short proximal segments.

On the other hand, it no longer seems advisable to associate a complete Chin Wing with a BSSO because of the high rate of nerve damage (50%), but also because we notice bone loss, in most cases, due to the remodeling of the posterior part of the wing (fig. 2). The isolated Chin Wing remains indicated in cases of hyperdivergent dental class I with important retrogenia and lip incompetence without need for mandibular advancement. The isolated Chin Wing seems to have less or no bone resorption at the mandibular angles when performed in a single procedure and a relatively low rate (11,1%) of IAN damage (fig. 2).

The authors declare they have no competing interest.



## Illustrations

|  | <b>Isolated<br/>BSSO<br/>n= 67</b> | <b>Mini Wing<br/>+ BSSO<br/>n = 24</b> | <b>Chin Wing<br/>+ BSSO<br/>n = 13</b> | <b>Isolated<br/>Chin Wing<br/>n= 9</b> |
|--|------------------------------------|--|--|--|
| Age                                    |                                    |  |  |  |
| Median                                 | 29.25                              | 26.17                                  | 28.85                                  | 21                                     |
| Range                                  | 15 - 58                            | 15 - 47                                | 15 - 48                                | 13 - 32                                |
| Sex                                    |                                    |  |  |  |
| Female                                 | 51 (76.1%)                         | 20 (83.3%)                             | 7 (53.8%)                              | 6 (66,7%)                              |
| Male                                   | 16 (23.9%)                         | 4 (16.7%)                              | 6 (46.2%)                              | 3 (33,3%)                              |
| Days between surgery<br>and evaluation |                                    |  |  |  |
| Median                                 | 390.88                             | 365.79                                 | 471.54                                 | 252,67                                 |
| Range                                  | 187 - 681                          | 214 - 709                              | 326 - 725                              | 205 - 452                              |

Table 1: Characteristics of the different groups (n: number of patient)

|   |         | <b>Isolated<br/>BSSO<br/>n=134</b> | <b>Mini Wing +<br/>BSSO<br/>n=48</b> | <b>Chin Wing +<br/>BSSO<br/>n=26</b> | <b>Isolated<br/>Chin Wing<br/>n=18</b> |
|---|---------|------------------------------------|--------------------------------------|--------------------------------------|--|
| Right and<br>left nerve<br>damage           | Absent  | 105<br>(78,4%)                     | 35<br>(72,9%)                        | 13<br>(50%)                          | 16<br>(88,9%)                          |
|   | Present | 29<br>(21,6%)                      | 13<br>(27,1%)                        | 13<br>(50%)                          | 2<br>(11,1%)                           |
| Fisher's test (comparison<br>to BSSO group) |         | NA                                 | p-value = 0,432                      | p-value = 0,006                      | NA                                     |

Table 2: Comparison of nerve damage (n: number of hemi-mandibule, NA: not applicable)

|   |           | <b>Isolated<br/>BSSO<br/>n=134</b> | <b>Mini Wing +<br/>BSSO<br/>n=48</b> | <b>Chin Wing +<br/>BSSO<br/>n=26</b> | <b>Isolated<br/>Chin Wing<br/>n=18</b> |
|---|-----------|------------------------------------|--------------------------------------|--------------------------------------|--|
| Right<br>and left<br>nerve<br>damage        | Absent    | 105<br>(78,4%)                     | 35<br>(72,9%)                        | 13<br>(50%)                          | 16<br>(88,9%)                          |
|   | Low       | 19<br>(14,2%)                      | 5<br>(10,4%)                         | 5<br>(19,2%)                         | (11,1%)                                |
|   | Medium    | 7<br>(5,2%)                        | 8<br>(16,7%)                         | 2<br>(7,7%)                          | 0                                      |
|   | Important | 2<br>(1,5%)                        | 0                                    | 6<br>(23,1%)                         | 0                                      |
|   | Complete  | 1<br>(0,7%)                        | 0                                    | 0                                    | 0                                      |
| Fisher's test (comparison<br>to BSSO group) |           | NA                                 | p-value = 0.141                      | p-value < 0,001                      | NA                                     |

Table 3: Comparison of nerve damage according to different levels of severity (n: number of hemi-mandibule, NA: not applicable)

|  |           | <b>Isolated BSSO<br/>n=67</b> | <b>Mini Wing + BSSO<br/>n=24</b> | <b>Chin Wing + BSSO<br/>n=13</b> | <b>Isolated Chin Wing<br/>n=9</b> |
|--|-----------|-------------------------------|----------------------------------|----------------------------------|-----------------------------------|
| Impact on quality of life                | Absent    | 55<br>(82,1%)                 | 20<br>(83,3%)                    | 9<br>(69,2%)                     | 8<br>(88,9%)                      |
|  | Low       | 8<br>(11,9%)                  | N=3<br>(12,5%)                   | N=2<br>(15,4%)                   | 1<br>(11,1%)                      |
|  | Medium    | 3<br>(4,5%)                   | 1<br>(4,2%)                      | 1<br>(7,7%)                      | 0                                 |
|  | Important | 1<br>(1,5%)                   | 0                                | 1<br>(7,7%)                      | 0                                 |
|  | Complete  | 0                             | 0                                | 0                                | 0                                 |
| Fisher's test (comparison to BSSO group) |           | NA                            | p-value = 1                      | p-value = 0,297                  | NA                                |

Table 4: Comparison of the impact on the quality of life (n: number of patients, NA: not applicable)

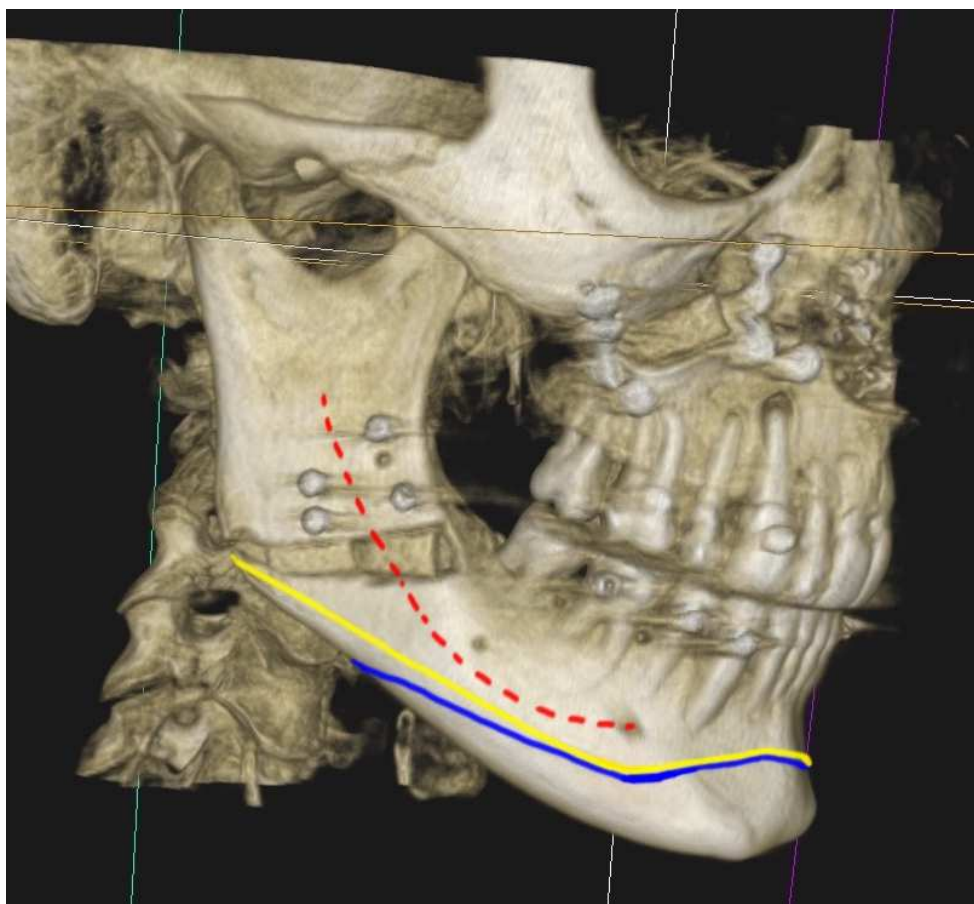


Figure 1: Postoperative CBCT of isolated BSSO case. Position of the Inferior Alveolar Nerve (red). Osteotomy line in the Chin Wing (yellow line) and in the Mini Wing osteotomy (blue line)

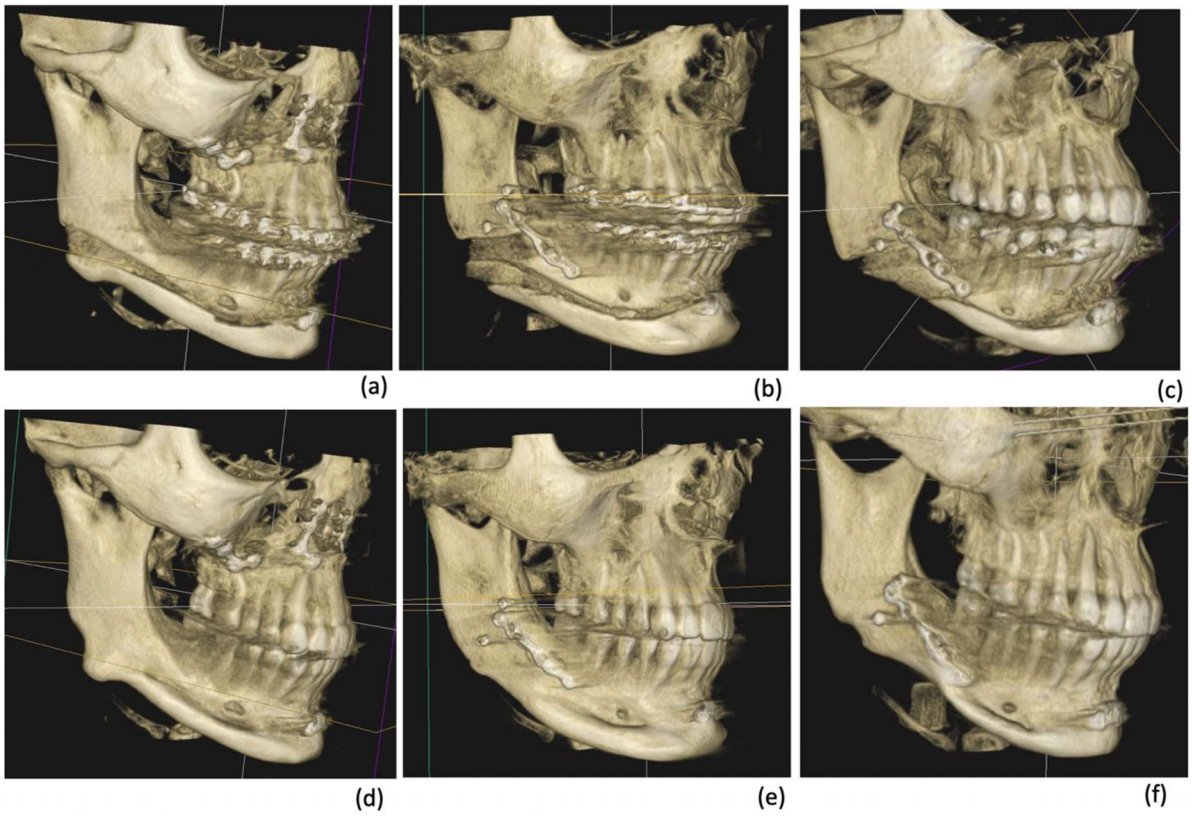


Figure 2: Immediate postoperative CBCT: a) isolated Chin Wing, b) BSSO with Chin Wing, c) BSSO with Mini Wing. One-year postoperative CBCT: d) isolated Chin Wing, e) BSSO with Chin Wing, f) BSSO with Mini Wing.

1. Triaca A, Brusco D, Guijarro-Martínez R. Chin wing osteotomy for the correction of hyper-divergent skeletal class III deformity: technical modification. *Br J Oral Maxillofac Surg.* 2015;53:775–7.
2. Triaca A, Minoretti R, Saulacic N. Mandibula wing osteotomy for correction of the mandibular plane: A case report. *Br J Oral Maxillofac Surg.* 2010;48:182–4.
3. Pouzoulet P, Cheynet F, Guyot L, Foletti JM, Chossegros C, Cresseaux P. Chin wing: Technical note. *J Stomatol Oral Maxillofac Surg.* 2018;119:315–8.
4. Cordier G, Sigaux N, Carlier A, Ibrahim B, Cresseaux P. Mini Wing osteotomy: a variant of Chin Wing osteotomy. *J Stomatol Oral Maxillofac Surg.* 2019 Oct 29;
5. Cordier G, Sigaux N, Ibrahim B, Cresseaux P. The intermediate length BSSO: Finding the balance between the classical and short designs. *J Stomatol Oral Maxillofac Surg.* 2019 Aug 31;
6. McLeod NMH, Bowe DC. Nerve injury associated with orthognathic surgery. Part 2: inferior alveolar nerve. *Br J Oral Maxillofac Surg.* 2016 May;54(4):366–71.
7. Iannetti G, Fadda TM, Riccardi E, Mitro V, Filiaci F. Our experience in complications of orthognathic surgery: a retrospective study on 3236 patients. *Eur Rev Med Pharmacol Sci.* 2013 Feb;17(3):379–84.
8. D’Agostino A, Trevisiol L, Gugole F, Bondí V, Nocini PF. Complications of orthognathic surgery: the inferior alveolar nerve. *J Craniofac Surg.* 2010;21:1189–95.
9. Mensink G, Zweers A, Wolterbeek R, Dicker GGJ, Groot RH, van Merkesteyn RJPR. Neurosensory disturbances one year after bilateral sagittal split osteotomy of the mandibula performed with separators: a multi-centre prospective study. *J Cranio-Maxillo-fac Surg Off Publ Eur Assoc Cranio-Maxillo-fac Surg.* 2012 Dec;40(8):763–7.
10. Westermarck A, Bystedt H, von Konow L. Inferior alveolar nerve function after sagittal split osteotomy of the mandible: correlation with degree of intraoperative nerve encounter and other variables in 496 operations. *Br J Oral Maxillofac Surg.* 1998 Dec;36(6):429–33.
11. Panula K, Finne K, Oikarinen K. Incidence of complications and problems related to orthognathic surgery: a review of 655 patients. *J Oral Maxillofac Surg Off J Am Assoc Oral Maxillofac Surg.* 2001 Oct;59(10):1128–36; discussion 1137.
12. Essick GK, Phillips C, Turvey TA, Tucker M. Facial altered sensation and sensory impairment after orthognathic surgery. *Int J Oral Maxillofac Surg.* 2007 Jul;36(7):577–82.
13. MacIntosh RB. Experience with the sagittal osteotomy of the mandibular ramus: a 13-year review. *J Maxillofac Surg.* 1981 Aug;9(3):151–65.
14. Tabrizi R, Pourdanesh F, Soleimanpour M, Shafie E. Evaluation of mandibular wing osteotomy in obstructive sleep apnea cases with retrognathia. *J Maxillofac Oral Surg.* 2015 Mar;14(1):46–50.
15. Troulis MJ, Kearns GJ, Perrott DH, Kaban LB. Extended genioplasty: long-term cephalometric, morphometric and sensory results. *Int J Oral Maxillofac Surg.* 2000 Jun;29(3):167–75.
16. Deshpande SN, Munoli AV. Osseous genioplasty: A case series. *Indian J Plast Surg Off Publ Assoc Plast Surg India.* 2011 Sep;44(3):414–21.
17. Hohl TH, Epker BN. Macrognathia: a study of treatment results, with surgical recommendations. *Oral Surg Oral Med Oral Pathol.* 1976;41:545–67.
18. Liu T, Xia B, Gu Z. Inferior alveolar canal course: a radiographic study. *Clin Oral Implants Res.* 2009 Nov;20(11):1212–8.
19. Hwang K, Lee WJ, Song YB, Chung IH. Vulnerability of the inferior alveolar nerve and mental nerve during genioplasty: an anatomic study. *J Craniofac Surg.* 2005 Jan;16(1):10–4; discussion 14.
20. de Oliveira-Santos C, Souza PHC, de Azambuja Berti-Couto S, Stinkens L, Moyaert

- K, Rubira-Bullen IRF, et al. Assessment of variations of the mandibular canal through cone beam computed tomography. *Clin Oral Investig*. 2012 Apr;16(2):387–93.
21. Sato I, Ueno R, Kawai T, Yosue T. Rare courses of the mandibular canal in the molar regions of the human mandible: a cadaveric study. *Okajimas Folia Anat Jpn*. 2005 Nov;82(3):95–101.
  22. Massey ND, Galil KA, Wilson TD. Determining position of the inferior alveolar nerve via anatomical dissection and micro-computed tomography in preparation for dental implants. *J Can Dent Assoc*. 2013;79:d39.
  23. Cunningham LL, Tiner BD, Clark GM, Bays RA, Keeling SD, Rugh JD. A comparison of questionnaire versus monofilament assessment of neurosensory deficit. *J Oral Maxillofac Surg Off J Am Assoc Oral Maxillofac Surg*. 1996 Apr;54(4):454–9; discussion 459-460.
  24. Pratt CA, Tippett H, Barnard JD, Birnie DJ. Labial sensory function following sagittal split osteotomy. *Br J Oral Maxillofac Surg*. 1996 Feb;34(1):75–81.
  25. Blomqvist JE, Alberius P, Isaksson S. Sensibility following sagittal split osteotomy in the mandible: a prospective clinical study. *Plast Reconstr Surg*. 1998 Aug;102(2):325–33.
  26. Coghlan KM, Irvine GH. Neurological damage after sagittal split osteotomy. *Int J Oral Maxillofac Surg*. 1986 Aug;15(4):369–71.
  27. Epker BN. Modifications in the sagittal osteotomy of the mandible. *J Oral Surg Am Dent Assoc* 1965. 1977;35:157–9.
  28. Trauner R, Obwegeser H. The surgical correction of mandibular prognathism and retrognathia with consideration of genioplasty. I. Surgical procedures to correct mandibular prognathism and reshaping of the chin. *Oral Surg Oral Med Oral Pathol*. 1957;10:677–89.