



In vivo evaluation of topical ascorbic acid application on skin aging by 50 MHz ultrasound

Mariane Massufero Vergilio, Laura Moretti Aiello, Andreza Sonogo Furlan, Amanda Costa Caritá, Jaqueline Rezende Azevedo, Marie-alexandrine Bolzinger, Yves Chevalier, Gislaine Ricci Leonardi

► To cite this version:

Mariane Massufero Vergilio, Laura Moretti Aiello, Andreza Sonogo Furlan, Amanda Costa Caritá, Jaqueline Rezende Azevedo, et al.. In vivo evaluation of topical ascorbic acid application on skin aging by 50 MHz ultrasound. *Journal of Cosmetic Dermatology*, 2022, 21 (10), pp.4921-4926. 10.1111/jocd.14892 . hal-03835488

HAL Id: hal-03835488

<https://hal.science/hal-03835488>

Submitted on 31 Oct 2022

HAL is a multi-disciplinary open access archive for the deposit and dissemination of scientific research documents, whether they are published or not. The documents may come from teaching and research institutions in France or abroad, or from public or private research centers.

L'archive ouverte pluridisciplinaire **HAL**, est destinée au dépôt et à la diffusion de documents scientifiques de niveau recherche, publiés ou non, émanant des établissements d'enseignement et de recherche français ou étrangers, des laboratoires publics ou privés.

***In vivo* evaluation of topical ascorbic acid application on skin aging by 50 MHz ultrasound**

Mariane Massufero Vergilio¹, Laura Moretti Aiello², Andreza Sonogo Furlan², Amanda Costa Caritá^{3,4}, Jaqueline Rezende Azevedo⁴, Marie-Alexandrine Bolzinger⁴, Yves Chevalier⁴, Gislaine Ricci Leonardi^{1,2,*}

¹ Graduate Program in Internal Medicine, School of Medical Sciences, University of Campinas (UNICAMP), Brazil.

² Graduate Program in Pharmaceutical Sciences, School of Pharmaceutical Sciences, University of Campinas (UNICAMP), Brazil.

³ Department of Translational Medicine, Federal University of São Paulo (UNIFESP), São Paulo, Brazil.

⁴ University of Lyon, Laboratoire d'Automatique, de Génie des Procédés et Génie Pharmaceutique (LAGEPP), CNRS UMR 5007, Université Claude Bernard Lyon 1, 43 bd 11 Novembre, 69622 Villeurbanne, France.

Abstract

Introduction: Ascorbic acid (AA) is a powerful antioxidant capable of acting significantly both in the prevention and treatment of the skin aging process. One way to assess the *in vivo* efficacy of anti-aging treatments is by using the high-frequency ultrasound (HFUS) skin image analysis technique, a non-invasive approach that allows for a new level of evaluating the effectiveness of dermatological and cosmetic products. The aim of the present study was to assess the performance of a topical emulsion of liquid crystalline structures containing AA using the 50 MHz HFUS skin image analysis method.

Methods: Twenty-five healthy female participants between 35 and 60 years old were included, all of whom randomly applied a placebo formulation and an AA-containing formulation to each forearm, once a day, for 30 days. HFUS measurements were performed before using the products (T0), two hours later (T2h), and after 30 days of use (T30d). The analyzed parameters included total skin, dermal, and epidermal echogenicity; variation and mean thickness of total skin, the epidermis and dermis; and surface roughness. Statistical analyses were performed using the Friedman test, followed by Dunn's test for comparisons of multiple means ($\alpha = 0.05$).

Results: A significant increase in total skin and dermal echogenicity was observed after topical AA application. Our findings suggest that collagen synthesis significantly increased after topical therapy with AA, which was responsible for the increment in dermal echogenicity. This study showed, through the HFUS technique, that the topical use of AA promoted dermal redensification after 30 days of application.

Keywords: ascorbic acid; high-frequency ultrasound; imaging analysis; skin aging.

1. INTRODUCTION

The skin corresponds to one of the largest organs in the human body and is of vital importance.¹ However, it is susceptible to numerous structural, biochemical, and functional changes triggered by the intrinsic and extrinsic aging process. Changes in the appearance of the skin are usually the first signs of aging and can affect the individual's social and psychological state. The identification of the mechanisms involved in this process, as well as the search for new strategies to prevent and combat skin aging, remain challenging.²

In the last decades, ascorbic acid (AA) has received widespread attention due to its anti-aging properties.^{3,4} AA is a powerful antioxidant capable of neutralizing oxidative stress triggered by several factors, including exposure to UV radiation. Studies show that sunscreens generally block only 55% of the free radicals produced by radiation; hence their use combined with antioxidants, such as AA, is highly recommended.⁴

The use of AA can also prevent immunosuppression induced by UV radiation (the expression of the CD1-a antigen by Langerhans cells decays with sun exposure) and promote a protective effect against photocarcinogenesis, decreasing the formation of thymine dimers in DNA.² This antioxidant is also known for its activity in collagen synthesis. In addition to inducing collagen gene transcription, AA is also an enzymatic cofactor for lysyl and prolyl hydroxylases, key enzymes in the stabilization and crosslinking of collagen fibers.^{5,6}

Another important use for AA is in the inhibition of melanogenesis by interfering in the active site of tyrosinase, an essential enzyme in the production of melanin. Laboratory and clinical studies have evidenced the effectiveness of this molecule in the treatment of melasma and hyperpigmentation.^{7,8}

Recent studies also show that, in addition to the well-documented regulatory genetic functions exerted by AA, this molecule can act as a cofactor for the TET (Ten-eleven translocation) enzyme family, which catalyze the removal of methylated cytosines in DNA. Thus, AA would act in the modulation of the epigenetic response and its decay would be involved with the early development of melanoma.⁹

Because of all these beneficial effects, AA has been used in personal care formulations for many years.^{10,11} However, it is important to highlight that, in order to maintain its biological activity, AA must be kept stable within the formulation.¹² In this sense, several strategies have been adopted, such as the addition of other antioxidants in the formula and the utilization of emulsified/encapsulated systems.^{13,14} In a previous study conducted by our group, AA was encapsulated in emulsions containing liquid crystals of mixed cetyl alcohol and Polysorbate 60. The emulsions were characterized by X-ray diffraction, polarized optical microscopy, and transmission electron microscopy. The stability of AA in the formulations was verified by high-performance liquid chromatography (HPLC) upon storage under different temperature conditions. Our results revealed that the developed emulsions contained a complex colloidal structure in the oil-water interface, consisting of the lamellar liquid crystalline ($L\alpha$) and lamellar gel crystalline ($L\beta$) phases. This structure was very efficient in preventing the oxidation of AA.¹⁵ Liquid crystals were first described in emulsions in 1969. Emulsions containing liquid crystals can provide numerous advantages, such as moisturizing power for the skin and improved rheological behavior of the formulation.¹⁶ They are able to promote the encapsulation of active ingredients, allowing for their sustained release, as well as providing protection to drugs, thus increasing formulation stability.¹⁷

On the contrary, effectiveness studies have been increasingly improved. Currently, skin image analysis by high-frequency ultrasound (HFUS) has received considerable attention.¹⁸ This approach

is based on the principle of transmitting short pulses of ultrasound energy to a specific tissue and receiving reflected waves arising from these ultrasound-tissue interactions, a process that takes place through the ultrasound transducer device, which contains thousands of piezoelectric crystals.^{18,19}

The application of HFUS is essential in complete skin evaluations since the high frequency enables the detailed, real-time visualization of the epidermis, dermis, and subcutaneous tissue, allowing for a meticulous characterization of skin parameters.¹⁸

In the ultrasound images, the dermis appears as a heterogeneous layer, with hyperechoic reflections of collagen fibers and hypoechoic spaces corresponding to the extracellular matrix that intersperse these fibers. The echo density of the skin can vary significantly with age and with the analyzed body region.²⁰ For this reason, several studies use this parameter to monitor the effects of anti-aging ingredients in the skin and underpins commercial claims, *e.g.*, the ability to redensify the dermis.^{2,21,22}

Despite being quite controversial, in practice, the thickness parameter has been used in studies to characterize skin aging, as well as to monitor the effects of anti-aging actives.^{2,23}

In the present study, we investigated the performance of our previously developed liquid crystal emulsion containing 5% AA using the HFUS (50 MHz) skin image analysis technique.

2. METHODS

An open, randomized, controlled clinical trial was carried out on twenty-five healthy female individuals, aged between 35 and 60 years old and with visible signs of facial aging. Exclusion criteria included cognitive and verbal limitations and allergic reactions to the cosmetic product. Each participant was informed about the nature and purpose of the study and signed a written consent form before enrolling in the trial. All participants randomly applied the base formulation - placebo (approximately 2 mg cm⁻²) to one forearm and the same amount of a formulation containing 5% AA on the other forearm once a day for 30 days.

The base formulation and the tested formulation containing AA were developed by Caritá et al. (2021)¹⁵ and are described in Table 1. Both were prepared by heating the oily phase (9% of cetyl alcohol and 6% of Polysorbate 60) and the water phase, separately, at 75 ± 5 °C. The water phase was incorporated into the oily phase by agitation at 10,000 rpm using an Ultra-Turrax T25 rotor-stator device equipped with an S25N-8G shaft (IKA) until cooling to below 40 °C. AA (5% w/w) was dissolved separately in water and added to the system when the temperature reached 40 °C.

The performance of the formulations was evaluated using high-frequency DUB® SkinScanner75 equipment (tpm taberna pro medicum GmbH), equipped with a 50 MHz transducer, with the aid of the equipment's integrated software.

The analyses were performed by applying the transducer to the test area on previously demarcated regions of the skin. Ultrasonographic gel (RMC®) was used at the interface between the transducer and the skin to obtain a better-quality images.¹⁸

High-frequency ultrasound measurements were carried out before (T0), 2 h later (T2h), and 30 days after of use of the products (T30d). The sonographic images were analyzed by an experienced and trained investigator. The following parameters were assessed according to Vergilio et al. (2021)¹⁸: echo density of total skin, the dermis, and epidermis; mean thickness of total skin, the dermis, and epidermis; and superficial skin roughness.

All statistical analyses were performed with the GraphPad Prism 9 software (GraphPad), using the ROUT outlier method and the Friedman test, and Dunn's test for multiple comparisons ($\alpha = 0.05$).

Table 1. Quantitative and qualitative composition of the emulsions.

INGREDIENTS	% (w/w)	
	Base emulsion - Control	Emulsion with AA
Cetyl alcohol	9.0	9.0
Polysorbate 60	6.0	6.0
Ascorbic acid (AA)	-	5.0
Propylene glycol	5.0	5.0
Phenoxyethanol + parabens	0.5	0.5
Sodium metabisulfite	0.3	0.3
Disodium EDTA	0.1	0.1
De-ionized water	q.s	q.s

3. RESULTS

The participants included in the present study had a mean age of 48.0 ± 8.08 years and were women with phototypes II, III, and IV. They underwent topical application of the AA emulsion and were monitored by 50 MHz HFUS for 30 days, as shown in Figure 1. The images revealed alterations in the structural pattern of the skin (Figure 1). After 2 hours of the study, no qualitative difference is observed between the images of the AA site and the placebo. However, after 30 days, an increment in dermal reflectivity/echogenicity (increase in the number of high echogenic pixels) was observed at the AA site. Such change was not evident at the placebo site. Also, variations related to the thickness and roughness parameters were not detected.

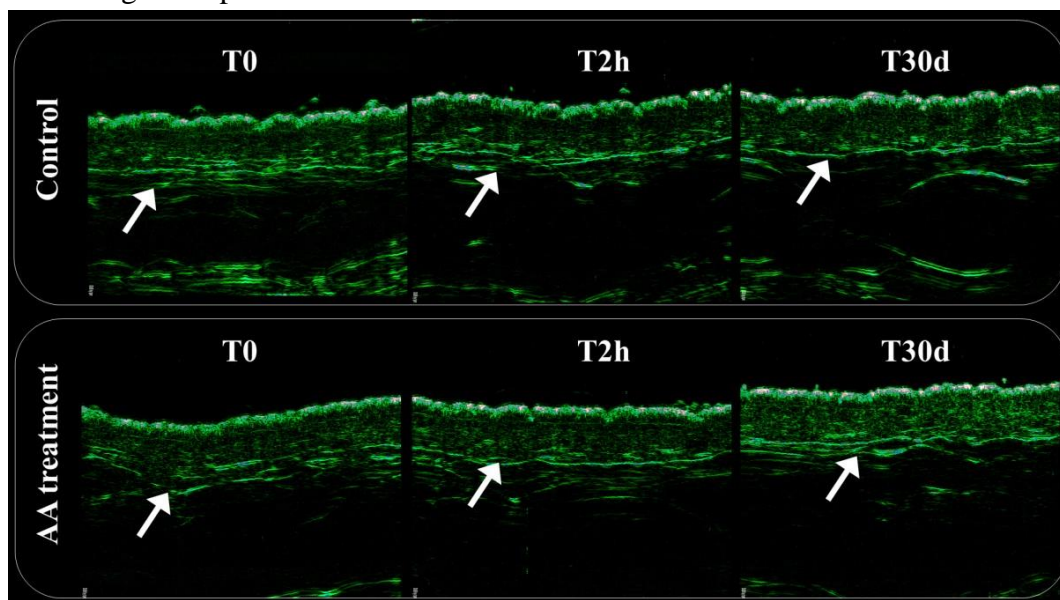


Figure 1. Anterior forearm images of participant P22 obtained through a 50 MHz HFUS probe before (T0), 2 hours (T2h), and 30 days (T30d) after the application of an emulsion containing or not 5% AA. The arrows indicate regions of the dermis that present changes caused by AA.

The results found in the comparative analysis between the AA site and placebo sites are represented in Figures 2 and 3 for all evaluated parameters. According to Figure 2, a significant increase in the echogenicity of the total skin, dermis, and epidermis was observed after topical AA application. On the other hand, Figure 3 shows that the superficial roughness parameter presented a considerable decrease at T30d when compared to T2h at the AA application site. Regarding the thickness of the total skin and its layers, there was no significant variation in this parameter concerning the time of use of the control and AA formulations (Figure 3).

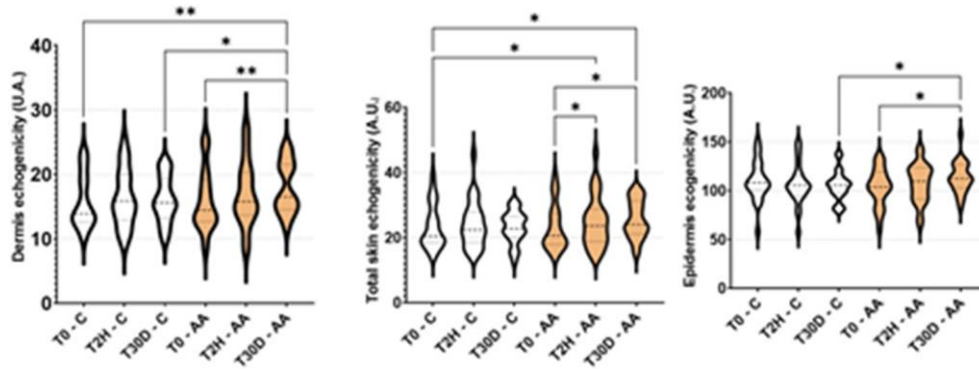


Figure 2. Graphical representation (violin plot) of the comparative analysis of the echogenicity parameters of the total skin, dermis, and epidermis for the test and control sites, at times T0, T2h and T30d. The test site is represented in orange. Values that were different are indicated with an asterisk p-value < 0.05 (*) and p-value < 0.005 (**) (Friedman analysis followed by Dunn's multiple comparison test).

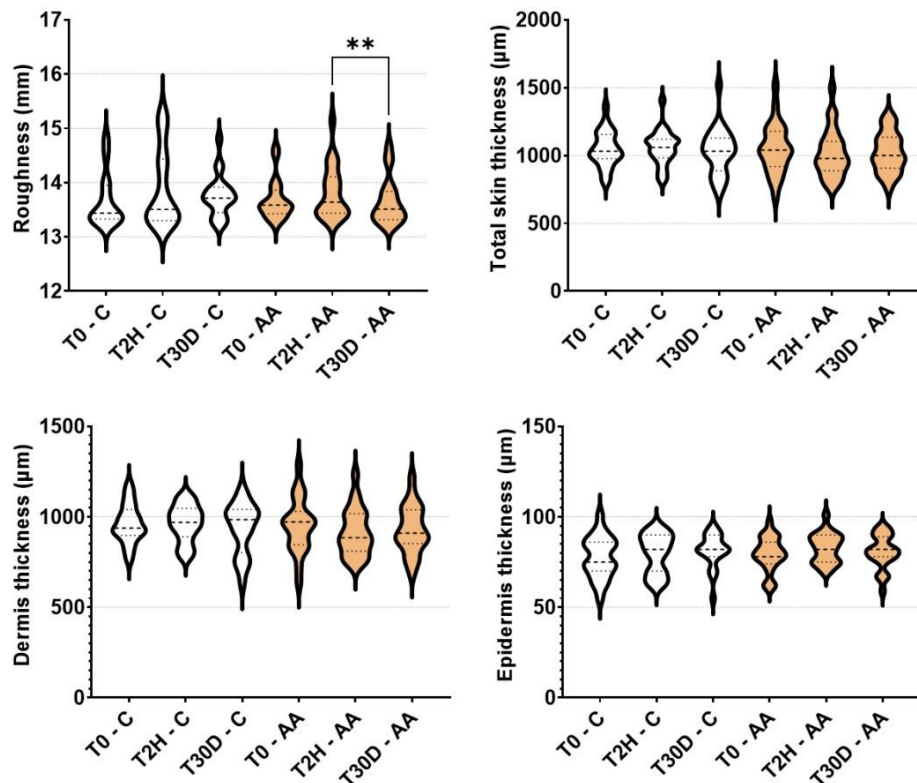


Figure 3. Graphical representation (violin plot) of the comparative analysis of the parameters of total skin, dermis and epidermis thickness, and superficial roughness, for the test and control sites, at times T0, T2h, and T30d. The test site is represented in orange. Values that were different are indicated with an asterisk p-value < 0.05 (*) and p-value < 0.005 (**) (Friedman analysis followed by Dunn's multiple comparison test).

4. DISCUSSION

With aging, the skin decreases its capacity for cell renewal, and the mechanisms of repair and protection are also compromised. This process leads to several molecular alterations, triggering modifications in the skin's elasticity and appearance.²⁴ These skin alterations can be observed through the analysis of high-frequency ultrasound images.²⁵ In a young and healthy HFUS skin image, the dermis appears as a less bright, hyperechoic band than the epidermis, with dermal echogenicity provided mainly by collagen. On the other hand, it seems brighter when compared to the subcutaneous tissue, which appears as a hypoechoic band due to fat lobes. The dermal collagen content, its type, orientation, and beam size affect dermal reflectivity/echogenicity.²⁶ Several experimental studies in animals and humans have reinforced the important role of AA in the synthesis, remodeling, and maintenance of the dermal extracellular matrix.^{2,27,28} This phenomenon is explained by the induction of local protein synthesis and leads to an increase in the level of dermal echogenicity.^{2,5,6} Following the opposite trend, unorganized collagen causes a reduction in ultrasound wave reflection.²⁹

According to our findings, the topical application of the emulsion containing AA increased the echogenicity in all skin layers. This property can be quantified by determining the number of pixels of a given brightness range in an area selected inside the HFUS image.³⁰ In other words, brightness increases with the improvement of echogenicity. The results obtained here suggest that the AA emulsion promoted dermal redensification after 30 days of application. This fact corroborates with histological studies that describe the action of AA in inducing local structural reorganization processes.²⁷

Ohshima *et al.* (2009)³¹ evaluated fourteen subjects with dark circles of the lower eyelid, and the use for 6 months of AA derivatives (10% sodium ascorbate or ascorbic acid glucoside lotion) in the facial region. When comparing the measurement of dermal thickness and echo density of the lower eyelids, no significant differences in changes in dermal thickness and echo density were seen between AA derivatives- and vehicle-treated sides during the clinical trial. Crisan *et al.* (2015) showed that topically applied AA is highly efficient as a rejuvenation therapy, inducing significant collagen synthesis in all age groups studied through the HFUS technique. Sixty women aged between 20 and 75 years were prospectively included in the study and divided into three age groups: 20-35, 35-50, and > 50 years. The study group topically applied 1 mL of AA-based solution to the face for 60 days. The following parameters were assessed for every subject: the thickness of the epidermis and the dermis (mm), and the number of lows (LEP), medium (MEP), high-echogenic pixels (HEP), and the number of LEP in the upper dermis/lower dermis (LEPs/LEPi). As result, there was an increase in MEP and HEP and a consequent decrease in LEP, but the thickness of the epidermis increased significantly only for the 20–35 age group. As far as the dermis thickness is concerned, did not observe any significant variation.¹⁶ Regarding the thickness parameters, in our study, no significant difference was observed after 30 days of AA use, indicating that the protocol did not cause an increase in thickness of the skin.

Studies show that age-related variations in skin thickness are less evident than those associated with location and gender.³² In addition, the photoexposure factor influences the thickness of the skin layers, which can be controversial in discussions on aging versus skin layer thickness.^{25,33} Reports in the literature also show that, after the age of 60, the thickness of the dermis tends to increase with sunlight exposure, whereas that of photoprotected areas tends to decrease.^{20,34} Some studies performed using confocal microscopy and biopsy indicate that there is a decrease in epidermal

thickness with increasing age. This can be explained by several keratinocyte-related modifications, such as the decrease in proliferative capacity, significant variability in shape, and mild nuclear atypia.^{35,36}

Superficial skin roughness measures the interfacial perimeter of the skin to assess skin aging.¹⁸ The aging process leads to changes in the elastic fibers of the skin, potentiating the wrinkling of its surface.³⁷ Skin roughness can thus be inferred, considering that a greater length implies high roughness. The improvement in the appearance of wrinkles related with topical AA application was identified in the literature.³⁸ In our study, the reduction in the superficial roughness of the skin associated with the use of AA highlights the role of this substance in repairing the network of elastic fibers.^{29,37}

5. CONCLUSION

The HFUS (50 MHz) skin image analysis technique is a promising tool to accurately evaluate the signs of skin aging. The quantitative data obtained through this analysis favor a better clinical understanding of the aging process and benefit a more detailed evaluation of the effectiveness of dermatological procedures and cosmetic products. Our study also showed that the liquid crystal emulsion containing 5% AA promoted dermal redensification after 30 days of application. These results reinforce the promising character of this formulation.

ACKNOWLEDGMENTS

This article was supported by grants from the São Paulo Research Foundation (FAPESP-2018/06973-4) and Coordenação de Aperfeiçoamento de Pessoal de Nivel Superior – Brasil (CAPES) – Finance Code 0001.

CONFLICTS OF INTEREST

None declared.

ETHICAL APPROVAL

The study was approved by the Research Ethics Committee of the Faculty of Medical Sciences at UNICAMP (CAAE: 13367219.5.0000.5404).

REFERENCES

1. Baroni A, Buommino E, De Gregorio V, Ruocco E, Ruocco V, Wolf R. Structure and function of the epidermis related to barrier properties. *Clin Dermatol*. 2012;30(3):257-262. doi:10.1016/j.clindermatol.2011.08.007
2. Crisan D, Roman I, Scharffetter-Kochanek K, Crisan M, Badea R. The role of vitamin C in pushing back the boundaries of skin aging: an ultrasonographic approach. *Clin Cosmet Investig Dermatol*. 2015;8:463-470. doi:10.2147/CCID.S84903
3. Gu C, Hu C, Ma C, Fang Q, Xing T, Xia Q. Development and characterization of solid lipid microparticles containing vitamin C for topical and cosmetic use. *Eur J Lipid Sci Technol*. 2016;118(7):1093-1103. doi:10.1002/ejlt.201500373
4. Telang P. Vitamin C in dermatology. *Indian Dermatol Online J*. 2013;4(2):143-146. doi:10.4103/2229-5178.110593
5. Kivirikko KI, Myllylä R. Post-translational processing of procollagens. *Ann N Y Acad Sci*. 1985;460:187-

201. doi:10.1111/j.1749-6632.1985.tb51167.x

6. Tajima S, Pinnell SR. Ascorbic acid preferentially enhances type I and III collagen gene transcription in human skin fibroblasts. *J Dermatol Sci*. 1996;11(3):250-253. doi:10.1016/0923-1811(95)00640-0
7. Stamford NPJ. Stability, transdermal penetration, and cutaneous effects of ascorbic acid and its derivatives. *J Cosmet Dermatol*. 2012;11(4):310-317. doi:10.1111/jocd.12006
8. Hsiao C-Y, Sung H-C, Hu S, Huang Y-L, Huang C-H. Fractional CO₂ laser pretreatment facilitates transdermal delivery of two vitamin C derivatives. *Molecules*. 2016;21(11):1-9. doi:10.3390/molecules21111547
9. Al-Niaimi F, Zhen Chiang NY. Topical Vitamin C and the skin: Mechanisms of action and clinical applications. *J Clin Aesthet Dermatol*. 2017;10(7):14-17.
10. Maia A, Baby A, Yasaka W, Suenaga E, Kaneko T, Velasco M. Validation of HPLC stability-indicating method for vitamin C in semisolid pharmaceutical/cosmetic preparations with glutathione and sodium metabisulfite, as antioxidants. *Talanta*. 2007;71(2):639-643. doi:10.1016/j.talanta.2006.05.006
11. Caritá AC, Fonseca-Santos B, Shultz JD, Michniak-Kohn B, Chorilli M, Leonardi GR. Vitamin C: One compound, several uses. Advances for delivery, efficiency and stability. *Nanomedicine Nanotechnology, Biol Med*. 2020;24:102-117. doi:10.1016/j.nano.2019.102117
12. Humbert PG, Haftek M, Creidi P, et al. Topical ascorbic acid on photoaged skin. Clinical, topographical and ultrastructural evaluation: double-blind study vs. placebo. *Exp Dermatol*. 2003;12(3):237-244. doi:10.1034/j.1600-0625.2003.00008.x
13. Sheraz MA, Khan MF, Ahmed S, Kazi SH, Khattak SR, Ahmad I. Factors affecting formulation characteristics and stability of ascorbic acid in water-in-oil creams. *Int J Cosmet Sci*. 2014;36(5):494-504. doi:10.1111/ics.12152
14. Sheraz M, Ahmad I, Vaid F., Ahmed S, Shaikh R, Iqbal K. Formulation and stability of ascorbic acid in topical preparations. *Syst Rev Pharm*. 2011;2(2):86-90. doi:10.4103/0975-8453.86296
15. Caritá AC, Resende de Azevedo J, Vinícius Buri M, et al. Stabilization of vitamin C in emulsions of liquid crystalline structures. *Int J Pharm*. 2021;592:1-7. doi:10.1016/j.ijpharm.2020.120092
16. e Silva SAM, Valarini MFC, Chorilli M, Friberg SE, Leonardi GR. Minimum evaporation model of dermatological delivery systems. Lamellar liquid crystal formulations containing Brazilian nut (*Bertholletia excelsa* HBK) vegetable oil and guarana glycolic extract. *J Dispers Sci Technol*. 2014;35(8):1191-1199. doi:10.1080/01932691.2013.826586
17. Oliveira MB, Prado AH Do, Bernegossi J, et al. Topical application of retinyl palmitate-loaded nanotechnology-based drug delivery systems for the treatment of skin aging. *Biomed Res Int*. 2014;2014:1-7. doi:10.1155/2014/632570
18. Vergilio MM, Monteiro e Silva SA, Jales RM, Leonardi GR. High-frequency ultrasound as a scientific tool for skin imaging analysis. *Exp Dermatol*. 2021;30(7):897-910. doi:10.1111/exd.14363
19. Hwang JH. Principles of ultrasound. In: Hawes R, Fockens P, Varadarajul S, eds. *Endosonography*. 4th ed. Elsevier; 2019:2-14. doi:10.1016/B978-0-323-54723-9.00001-4
20. Crisan M, Lupsor M, Crisan D, Boca A, Badea R. Ultrasonographic assessment of skin structure according to age. *Indian J Dermatology, Venereol Leprol*. 2012;78(4):519. doi:10.4103/0378-6323.98096
21. Tedeschi A, Lacarrubba F, Micali G. Mesotherapy with an intradermal hyaluronic acid formulation for skin rejuvenation: An inpatient, placebo-controlled, long-term trial using high-frequency ultrasound. *Aesthetic Plast Surg*. 2015;39(1):129-133. doi:10.1007/s00266-014-0432-1
22. Gniadecka M. Effects of ageing on dermal echogenicity. *Ski Res Technol*. 2001;7(3):204-207. doi:10.1034/j.1600-0846.2001.70310.x
23. Diridollou S, Vienne M-P, Alibert M, et al. Efficacy of topical 0.05% retinaldehyde in skin aging by ultrasound and rheological techniques. *Dermatology*. 1999;199(1):37-41. doi:10.1159/000051377
24. Nikolakis G, Makrantonaki E, Zouboulis C. Aging skin: A window to the body. In: Quan T, ed. *Molecular Mechanisms of Skin Aging and Age-Related Diseases*. CRC Press; 2016:200-228.

doi:10.1201/b21370-12

25. Vergilio MM, Monteiro e Silva SA, Vasques LI, Leonardi GR. Characterization of women's young and mature skin by the 50 MHz high-frequency ultrasound technique. *J Cosmet Dermatol*. 2021;20(11):3695-3697. doi:10.1111/jocd.13999
26. Wortsman X. *Atlas of Dermatologic Ultrasound*. Cham: Springer International Publishing; 2018. doi:10.1007/978-3-319-89614-4
27. Sauermann K, Jaspers S, Koop U, Wenck H. Topically applied vitamin C increases the density of dermal papillae in aged human skin. *BMC Dermatol*. 2004;4(1):13. doi:10.1186/1471-5945-4-13
28. Fisher GJ, Kang S, Varani J, et al. Mechanisms of photoaging and chronological skin aging. *Arch Dermatol*. 2002;138(11):1462-1470. doi:10.1001/archderm.138.11.1462
29. Sciolla B, Le Digabel J, Josse G, Dambry T, Guibert B, Delachartre P. Joint segmentation and characterization of the dermis in 50 MHz ultrasound 2D and 3D images of the skin. *Comput Biol Med*. 2018;103:277-286. doi:10.1016/j.combiomed.2018.10.029
30. Mlosek RK, Dębowska RM, Lewandowski M, Malinowska S, Nowicki A, Eris I. Imaging of the skin and subcutaneous tissue using classical and high-frequency ultrasonographies in anti-cellulite therapy. *Ski Res Technol*. 2011;17(4):461-468. doi:10.1111/j.1600-0846.2011.00519.x
31. Ohshima H, Mizukoshi K, Oyobikawa M, et al. Effects of vitamin C on dark circles of the lower eyelids: Quantitative evaluation using image analysis and echogram. *Skin Res Technol*. 2009;15(2):214-217. doi:10.1111/j.1600-0846.2009.00356.x
32. Lasagni C, Seidenari S. Echographic assessment of age-dependent variations of skin thickness. *Ski Res Technol*. 1995;1(2):81-85. doi:10.1111/j.1600-0846.1995.tb00022.x
33. Vergilio MM, Vasques LI, Leonardi GR. Characterization of skin aging through high-frequency ultrasound imaging as a technique for evaluating the effectiveness of anti-aging products and procedures: A review. *Skin Res Technol*. 2021;27(5):966-973. doi:10.1111/srt.13033
34. Carvalho PRS, Sumita JM, Soares JLM, Sanudo A, Bagatin E. Forearm skin aging: characterization by instrumental measurements. *Int J Cosmet Sci*. 2017;39(5):564-571. doi:10.1111/ics.12407
35. Branchet MC, Boisnic S, Frances C, Robert AM. Skin thickness changes in normal aging skin. *Gerontology*. 1990;36(1):28-35. doi:10.1159/000213172
36. Longo C, Casari A, Beretti F, Cesinaro AM, Pellacani G. Skin aging: In vivo microscopic assessment of epidermal and dermal changes by means of confocal microscopy. *J Am Acad Dermatol*. 2013;68(3):e73-e82. doi:10.1016/j.jaad.2011.08.021
37. Langton AK, Sherratt MJ, Griffiths CEM, Watson REB. A new wrinkle on old skin: the role of elastic fibres in skin ageing. *Int J Cosmet Sci*. 2010;32(5):330-339. doi:10.1111/j.1468-2494.2010.00574.x
38. Ehrlich M, Rao J, Pabby A, Goldman MP. Improvement in the appearance of wrinkles with topical transforming growth factor β 1 and L-ascorbic acid. *Dermatologic Surg*. 2006;32(5). doi:10.1111/j.1524-4725.2006.32132.x