



HAL
open science

Long-term follow-up of neurodegenerative phenomenon in severe traumatic brain injury using MRI

Pierre Simeone, Guillaume Auzias, Julien Lefevre, Sylvain Takerkart, Olivier Coulon, Blandine Lesimple, Grégory Torkomian, Valentine Battisti, Alice Jacquens, David Couret, et al.

► To cite this version:

Pierre Simeone, Guillaume Auzias, Julien Lefevre, Sylvain Takerkart, Olivier Coulon, et al.. Long-term follow-up of neurodegenerative phenomenon in severe traumatic brain injury using MRI. *Annals of Physical and Rehabilitation Medicine*, 2022, 65 (6), pp.101599. 10.1016/j.rehab.2021.101599 . hal-03832209

HAL Id: hal-03832209

<https://hal.science/hal-03832209>

Submitted on 27 Oct 2022

HAL is a multi-disciplinary open access archive for the deposit and dissemination of scientific research documents, whether they are published or not. The documents may come from teaching and research institutions in France or abroad, or from public or private research centers.

L'archive ouverte pluridisciplinaire **HAL**, est destinée au dépôt et à la diffusion de documents scientifiques de niveau recherche, publiés ou non, émanant des établissements d'enseignement et de recherche français ou étrangers, des laboratoires publics ou privés.

Long-term follow-up of neurodegenerative phenomenon in severe traumatic brain injury using MRI

P. Simeone^{1,2}, G. Auzias², J. Lefevre², S. Takerkart², O. Coulon², B. Lesimple³, G. Torkomian⁴,
V. Battisti⁴, A. Jacquens⁴, D. Couret⁵, L. Naccache⁶, E. Bayen⁷, N. Bruder¹, V. Perlberg⁸, L.
Puybasset^{3,4}, L. Velly^{1,2}

¹Aix-Marseille University, AP-HM, Dept of Anesthesiology and Critical Care Medicine, University Hospital La Timone, Marseille, France

²Aix-Marseille University, CNRS, UMR7289, Institut de Neurosciences de La Timone, Marseille, France

³Sorbonne Université, CNRS, INSERM, Laboratoire d'Imagerie Biomédicale, Paris, France

⁴Sorbonne Université, AP-HP, Dept of Anesthesiology and Critical Care Medicine, Hôpital Pitié Salpêtrière, Paris, France

⁵Réunion University, Neurocritical Care Unit, Hopital Saint-Pierre, Saint-Pierre, La Réunion, France

⁶Sorbonne Université, Institut du Cerveau et de la Moelle Epinière, PICNIC Lab, AP-HP, Hôpital Pitié Salpêtrière, Paris, France

⁷Service de Médecine Physique et Réadaptation, AP-HP, Hôpital Pitié Salpêtrière, Paris, France

⁸BrainTale SAS, paris, France

Abstract:

Background. Traumatic brain injury (TBI) lesions are known to evolve over time but duration and consequences of cerebral remodeling are unclear. Degenerative mechanisms occurring in chronic phase after TBI could constitute “tertiary” lesions related to the neurological outcome.

Objective. The objective of this prospective study in severe TBI was to longitudinally evaluate white and grey matter structures volumes and white matter integrity with two time points multimodal magnetic resonance imaging (MRI).

Methods. A longitudinal MRI follow-up was obtained for 11 healthy controls (HC) and 22 TBI (60 ± 15 months after injury) together with neuropsychological assessments. TBI patients were classified into “favorable” (GOSE6–8) and “unfavorable” (GOSE3–5) recovery groups based on the Glasgow Outcome Scale Extended at 5 years. Variation of brain volumes (3DT1-weighted image) and white matter integrity (diffusion tensor imaging; DTI) were quantitatively assess over time and used to predict neurological outcome.

Results. TBI patients demonstrated a dramatic decrease in whole white matter (-11.4% [IQR -5.8 to -14.6]; $p < 0.001$) and deep grey nuclear volumes (-17.1% [IQR -10.6 to -20.5]; $p < 0.001$). In contrast, HC did not present any significant change over the same time period. GOSE3–5 patients showed higher median volumetric loss than GOSE6–8 patients in several brain regions. These lesions were associated with lower fractional anisotropy (FA), and higher mean diffusivity (MD) at baseline. Volumetric variations showed a positive correlation with normalized FA and a negative correlation with normalized MD at baseline and follow-up. Computed predictive model with baseline DTI showed a good accuracy to predict atrophy and neurological outcome (area under the ROC curve 0.82 [95% CI, 0.81 to 0.83])

Conclusions. We characterized the dramatic atrophy of deep brain structures consecutive of severe TBI. DTI imaging in the subacute phase can predict occurrence and localization of these tertiary lesions as well as long-term neurological outcome.

Key words: traumatic brain injury, magnetic resonance imaging, prognosis, longitudinal, neurodegeneration, brain atrophy.

Abbreviations: **3DT1** = three-dimensional T1-weighted imaging; **AD** = axial diffusivity; **AUC** = area under the curve; **DTI** = diffusion tensor imaging; **eTIV** = estimating total intracranial volumes; **FA** = fractional anisotropy; **FDR** = false discovery rate; **FLAIR** = fluid-attenuated inversion recovery; **GOSE** = Glasgow outcome scale extended; **HC** = healthy controls; **ICU** = intensive care unit; **IQR** = interquartile range; **JHU** = Johns Hopkins University; **MRI** = magnetic resonance imaging; **MD** = mean diffusivity; **RD** = radial diffusivity; **ROC** = receiver-operating characteristic; **SD** = standard deviation; **SVM** = support vector machines ; **TBI** = traumatic brain injury; **VBM** = voxel-based morphometry.

Trial registration: ClinicalTrials.gov, NCT00577954. Registered on October 2006.

Introduction

Traumatic brain injury (TBI) have lifelong and dynamic effects on health and wellbeing. Evidence accumulated in the past decades has led to recognition that, for many patients, TBI to evolve after the acute period and initial recovery.[1] An increased risk of dementia after moderate to severe TBI has been observed on a large dataset.[2] This degenerative phenomenon, so-called “tertiary injury”, is now considered to play a major role in long-term functional prognosis.[3] Although, the mechanisms remain unclear although several hypothesis have been suggested such as microglial activation, phosphorylated tau protein, Wallerian degeneration and oxidative stress.[4] Several studies using magnetic resonance imaging (MRI) have produced some key data,[5–15] however the scale of the phenomenon remains unknown since most of studies had no morphometric data prior to the follow-up MRI. Diffuse Tensor Imaging provided by MRI assess the microstructural organization of tissues by diffusion of water molecules and has been already used to describe pathophysiological mechanisms in brain white matter following TBI.[16] Still, the relationship between brain anatomical change and neurological outcome remains unclear.

This prospective study was designed to longitudinally assess tertiary injuries in severe TBI in terms of white and grey matter structure volumes, and to measure white matter integrity with DTI from baseline to follow-up MRI. A secondary objective was to evaluate the prognostic performance of DTI at baseline MRI to predict neurological outcome.

Materials and methods

Study design

This was a prospective observational study conducted as part of a larger trial named MRI-COMA (assessing outcome with multimodal MRI of comatose patients of various origin; NCT00577954). Healthy controls (HC) and severe TBI patients were enrolled between October 2006 and April 2013, with an intended follow-up period of ~5 years, and were neuropsychological evaluated at the university hospital Pitié-Salpêtrière between April 2014 and September 2016.

Participants

TBI patients were eligible for inclusion if they were unconscious at day 7 after the initial injury (defined as the inability to obey verbal commands not attributed to sedation or aphasia). Inclusion criteria are summarized in the Supplementary material, page 3. Patients who had an interpretable MRI during their intensive care unit (ICU) stay were invited to participate in the follow-up phase. If patients were unable to respond, their relatives were contacted by phone to provide consent to patient participation. Patients were also required to have a Glasgow Outcome Scale Extended (GOSE)[17] score of at least 3.

Baseline data and follow-up neuropsychological evaluation

Demographic data before TBI (age, sex, handedness and education level) and score relating to injury severity were collected during ICU stay. Patients and relatives were contacted by telephone to obtain an appointment for the follow-up phase evaluation. They then underwent a structured interview (2–3 hours' duration) with a trained neuropsychologist masked to the clinical data. The primary clinical outcome was the GOSE assessed at the follow-up for the second time point evaluation, by which means

patients were dichotomized with "favorable" (ranging from *Upper Moderate Disability* (GOSE 6) to *Upper Good recovery* (GOSE 8)) and "unfavorable" (ranging from *Lower Severe Disability* (GOSE 3) to *Lower Moderate Disability* (GOSE 5)). Participants also underwent extensive neuropsychological evaluation using an expanded brief repeatable battery of neuropsychological tests assessing episodic memory, executive function, working memory and attentional abilities expressed as z-score (Supplementary material, appendix 1). The evaluation also assessed physical or psychological disabilities, and level of rehabilitation or required assistance.

MRI data acquisition

All included TBI patients underwent a minimum of two MRI acquisitions, including the baseline MRI performed at the subacute phase during ICU stay and a follow-up MRI on the day of the final neuropsychological assessment. HC also underwent a baseline and follow-up MRI. All participants were carefully placed in the same position on each occasion by the radiologists in order to obtain high reproducibility across participants and time points. The following four conventional MRI sequences were performed for each acquisition: A high-resolution T1-weighted structural image with an IR-FSPGR (inversion recovery fast spoiled gradient recalled echo) 3-dimensional protocol (3DT1; 1-mm isotropic voxel); an axial T2-weighted fluid-attenuated inversion recovery (FLAIR); an axial T2*-weighted gradient-recalled echo or weighted angiography; and a DTI sequence. The precise parameters of each sequence according to the scanner are listed in Supplementary Table 1. All the images underwent visual and standardized quality check (by the authors PS and LV) to ensure that they did not contain MRI artefacts or excessive movement before analysis.

Longitudinal volumetric MRI measurements

Post-processing and brain segmentation were performed on a computer cluster (a 64-bit Linux with 256 cores). All 3DT1 images from TBI patients and HC were denoised using the Spatially Adaptive Non-Local Means filter from the CAT12 toolbox of SPM software (<https://www.fil.ion.ucl.ac.uk/spm/software>; version 12.r7240) and were then processed with the longitudinal processing stream implemented in FreeSurfer software (<http://surfer.nmr.mgh.harvard.edu>; version 6.0).[18] Initially, all baseline and follow-up acquisitions were cross-sectionally processed using the "recon-all" processing stream with default parameters.[19,20] This includes motion correction, removal of nonbrain tissue, automated Talairach transformation, intensity correction, volumetric segmentation,[21] cortical surface reconstruction[19,20,22] and parcellation[23,24]. After the automated reconstruction of all participants, volumes were visually inspected for misclassifications during the reconstruction process. In order to extract reliable longitudinal cortical volume, thickness and area change estimates, the cross-sectional processed images were subsequently run through the longitudinal stream in FreeSurfer using an unbiased within-subject template volume computed using inverse consistent registration.[18,25] The within-subject template was used as initial guess of several segmentation and reconstruction steps (Talairach transforms, atlas registration and parcellations) for processing at each time point. The processing pipeline generated 68 cortical volumes (34 from each hemisphere) and 121 subcortical volumes for volumetric analysis. Cortical and subcortical volumetric measures from the right and left hemispheres were averaged.[26] Abnormal FLAIR-hyperintensity, i.e. contusions, were automatically segmented on the FLAIR images using k-nearest neighbors classification with tissue type priors.[27] Hematoma were manually drawn with Freeview ([https://surfer.nmr.mgh.harvard.edu/fswiki/UpdateFreeview;version 2.0](https://surfer.nmr.mgh.harvard.edu/fswiki/UpdateFreeview;version%202.0)). Hematoma and contusions were used to compute whole-brain MRI lesion volume. A deformation-based morphometry technique was also used in order to apply

longitudinal voxelwise analysis between baseline and follow-up MRI.[28] Details of post-processing steps are summarized in the Supplementary material, page 4.

Longitudinal DTI analysis

To assess white matter integrity, diffusion-weighted data from TBI patients and HC were processed by using the brainQuant software version 1.1 (<https://braintale.fr>), including motion and eddy current correction, tensor model fitting and coregistration to T1 volume. DTI parameters, Fractional Anisotropy (FA), Mean Diffusivity (MD), Radial Diffusivity (RD) and Axial Diffusivity (AD) within each of the 85 subcortical white matter volumes of FreeSurfer segmentation and within the 48 deep white matter tracts of the Johns Hopkins University (JHU) atlas.[29] A detailed list of the regions analyzed is provided in the Supplementary material, appendix 2. In order to reduce inter-scanner variability and allow direct comparison across scanners, DTI parameters for a given participants were finally calibrated with the mean of values acquired from HC on the same scanner and under the same DTI sequence,[30,31] leading to the following equations:

$$FA = \frac{FA}{\sum_{i=1}^{N_{HC}} (FA)_i} ; MD = \frac{MD}{\sum_{i=1}^{N_{HC}} (MD)_i} ; RD = \frac{RD}{\sum_{i=1}^{N_{HC}} (RD)_i} ; \text{ and } AD = \frac{AD}{\sum_{i=1}^{N_{HC}} (AD)_i}$$

where N_{HC} stands for the number of HC acquired with the same MR protocol, on the same scanner as the given patient (Supplementary Table 2). The results are expressed as a percentage of the value of HC.

Study endpoints

The main endpoint was the percentage brain volume change (ΔV) calculated as: $100 \times ((V_{\text{follow-up}} - V_{\text{baseline}}) \div V_{\text{baseline}})$. All volumes were corrected by the total intracranial volume (eTIV) that is estimated as the determinant of the transform matrix used to align the image

participant with the atlas[32] and has been used previously in several studies for normalization[26,33].

Cortical thickness estimates were calculated from FreeSurfer outputs by measuring surface distances between representations of the white-grey and pial-cerebrospinal fluid boundaries.

The correlation between normalized measures of FA, MD, RD, AD at baseline and follow-up with volumetric variations were also computed. A machine-learning approach with support vector machine (SVM) and a linear kernel was used to predict the neurological outcome of patients (GOSE 6–8 vs GOSE 3–5). Normalized FA and MD at baseline were implemented into the classifier to determine the prognostic performance of DTI carried out during the ICU stay at baseline MRI.

Statistical analysis

Data were tested for normality (Shapiro-Wilk test) and are presented as mean \pm standard deviation (SD) or median (interquartile range [IQR]) for continuous variables when appropriate. Categorical variables are presented as n (%). Comparisons between groups according to outcome at follow-up were performed using Fisher's exact test and non-parametric Wilcoxon–Mann–Whitney test when appropriate using JMP software (version 13.0, SAS Institute Inc., Cary, NC, USA). Significance was defined as a P -value <0.05 . P -values for region of interest analysis were corrected for multiple comparisons by a false discovery rate (FDR) method across 189 regions for volumetric analysis and 133 regions for DTI analysis using Scipy (version 0.19.0, <https://www.scipy.org/install.html>). Cortical thickness was expressed as z-score, defined as the deviation from the mean in SD, and a logistic regression was applied using the general linear model (GLM) to analyze cortical thickness differences between HC and TBI, integrating as covariates the age of the participants, time between the two acquisitions and type of MRI machine. Longitudinal

voxelwise analysis was carried out using FSL Randomize software.[34] Correlations were assessed using the square of Pearson's correlation coefficient (R^2). In order to compare the magnitude of differences among TBI patients and HC in terms of rates of atrophy, effect sizes were computed using Cohen's d for those regions of interest with greater rates of atrophy. SVM classification approach was conducted using open-source packages including Scikit-learn (version 0.16.1, <http://scikit-learn.org/stable/index.html>). These two last methodological points are detailed in the Supplementary material, page 6.

Standard protocol approvals, registrations, and patients consents

We obtained approval from the local Ethical committee (comité de protection des personnes, CPP XI; authorization number: 1934708). In accordance with French law, patients and their relatives were informed of their initial inclusion in the database, and informed consent of participants or their legal representatives was obtained prior to follow-up assessments. Written informed consent was obtained directly from the HC.

Results

Subject characteristics

Among severe TBI patients in whom an MRI was performed during the first study period, 182 patients were eligible for inclusion in the study (Figure 1). Overall, 22 severe TBI patients and 11 HC were included in the analysis. No difference between TBI patients and HC regarding sex (19 (86%) vs 8 (72%) males; $p = 0.18$), age (30 ± 13 vs 36 ± 7 yrs ; $p = 0.93$), and education status (6 [6–7] vs 6 [5–7]; $p = 0.84$) were observed. The follow-up for TBI patients was 60 ± 15 months after injury; 10 (45%) had a “favorable” outcome (GOSE 6–8) and 12 (55%) had a “unfavorable” recovery (GOSE 3–5). At admission in ICU, there was no significant difference between patients with “favorable” or “unfavorable” recovery in terms of demographic, clinical and radiological characteristics (Table 1). At follow-up, GOSE 3–5 had a higher occurrence of post-traumatic amnesia than GOSE 6–8 (66% vs 15%; $p = 0.046$), were more unable to work or only in sheltered workshop (100% vs 37%; $p = 0.009$), were more often undergoing a re-education process (43% vs 6%; $p = 0.008$) and were less able to drive (33% vs 86%; $p = 0.036$) (Table 2). Neuropsychological assessment (z-score) showed differences between GOSE 3–5 and GOSE 6–8 in episodic memory (-4.4 ± 2.2 vs -0.3 ± 1.3 ; $p < 0.001$) and executive functions (5.7 ± 3.2 vs -1.8 ± 2.3 ; $p = 0.018$), with no difference in attentional and work memory scores.

Volumetric MRI assessment

TBI patients underwent a minimum of two serial multimodal MRI. The first realized at baseline (21 [IQR 12 to 29] days after injury) assessed no difference in brain volume between HC and TBI (Table 3). The voxelwise distribution of abnormal hyperintensity on baseline FLAIR is presented in Supplementary Figure 1. At follow-up, the delay between MRI was not different between HC and TBI patients. (39 ± 39 vs 60 ± 15 months; $p = 0.06$). Unlike HC, who did not show any significant volumetric variation at follow-up, TBI

patients demonstrated a volume reduction after FDR correction in the whole white matter (-11.4% [IQR -5.8 to -14.6]; $p < 0.001$), in the whole JHU mask (-10.1% [IQR -4.3 to -18.4]; $p < 0.001$) and in the deep grey nuclear structures (-17.1% [IQR -10.6 to -20.5]; $p < 0.001$) (Table 3). Volumetric loss in TBI patients occurred especially in deep white matter tracts (corpus callosum, cingulum) and thalami (Figure 2AB). Voxelwise comparisons between the two MRI time points are presented in Supplementary Figure 2. There was no significant volumetric variation in the regions of interest of cortical grey matter (Figure 2C). There was also no statistically significant difference in the variation of cortical thickness at follow-up in HC and in TBI patients (Figure 2D). Compared to GOSE 6–8 patients, GOSE 3–5 patients had higher volume loss in several structures, e.g. in brainstem (-14.1% [IQR -8.2 to -24.5] vs -7.1% [IQR -1.2 to -11.9]; $p = 0.027$), right hippocampus (-13.4% [IQR -5.9 to -17.6] vs -4.8% [IQR 0.1 to -9.3]; $p = 0.044$) and left cerebral peduncle (-18.7% [IQR -5.0 to -41.8] vs -4.6% [IQR 9.1 to 5.2]; $p = 0.034$) (Supplementary Figure 3).

Diffusion MRI assessment

In HC, normalized FA, MD, RD, and AD in all regions of interest showed no significant change between the two MRI acquisitions (data not shown). In TBI patients, a significant decrease in normalized FA was associated with significant increase in normalized MD (Figure 3), RD and AD (Supplementary Figure 4) in deep white matter tracts at baseline and follow-up MRI. Volumetric variations were significantly correlated with normalized FA and normalized MD at baseline (Figure 4B) and follow-up (Figure 4D) in deep white matter structures.

Effect sizes and sample size calculations

Detailed effect size and power analyses for all regions and diffusion MRI assessments are presented in Supplementary Table 3.

Prognostic approach

ROC curves of the classifiers based on DTI measurements (FA, MD, FA–MD) that predict “unfavorable” recovery (GOSE 3–5) are shown on Supplementary Figure 5. The model combining FA and MD at baseline MRI shows the best prognostic performance for neurological outcomes. The ROC_{AUC} was 0.82 (95% CI, 0.81 – 0.83) with 86.3% positive predictive value (95% CI, 71.9 – 100) and 87.8% negative predictive value (95% CI, 74.1 – 100).

Discussion

Our study followed a cohort of TBI patients and HC over more than 5 years. We observed a dramatic brain volume loss in TBI patients over the study period. This brain atrophy predominates in the deep white matter and deep grey nuclear structures while sparing the cortical grey matter. Its intensity was more pronounced in patients with impaired recovery in specific regions of interest, namely brainstem, right hippocampus and left cerebral peduncle.

The first description of this neurodegenerative phenomenon was in the early days of MRI more than 30 years ago.[5] Studies at that time, often limited to the analysis of a single region of interest at a single time, reported the existence of neurodegenerative processes in the corpus callosum[35] and fornix[5].

Since then, image processing tools have improved significantly, and the study of tertiary injury has become a popular topic in recent literature. Thereafter, morphometric techniques based on voxelwise comparison between two acquisitions have better characterized the topography of neurodegenerative processes.[8,10,36]

Until now, assessment of tertiary brain injury has been a real challenge both for image processing and for integrating this method into a robust automated longitudinal approach for severe TBI patients with very injured brain.[13] Few works are closely related to our method.[8,28,37] Our results are in line with these previous reports but also have

the advantage of possessing a volumetric segmentation approach. Furthermore, in all these studies, the population was not focused on severe TBI patients, follow-up time was shorter than 60 months and morphometric analyses used were less accurate than the longitudinal regional segmentation process employed here. We also chose to use a dichotomized GOSE scale based on a functional approach used in other works,[38,39] as GOSE<3 patients were not relevant and included for this study. Moreover, the study reported by Cole *et al.* had no morphometric data prior to the baseline MRI acquired 1 year after TBI and did not include DTI analysis.[28]

Our results are consistent with previous reports on the occurrence of neurodegenerative phenomena in deep brain regions.[8–10,37] The volumetric loss we observed cannot be accounted for by normal physiological ageing. Unlike many studies without a control group,[40–42] we also followed HC longitudinally and showed no significant change in brain volume over the study period which is in line with the literature for this age group.[43] In contrast, we observed an average brain volume loss of 2% per year between the two acquisitions in TBI patients. When comparing this annual brain volume loss to those reported in the literature for other neurodegenerative diseases, it appears that the severity of the neurodegenerative processes we describe here in TBI is very similar to that of aggressive neurodegenerative conditions such as Alzheimer's disease³⁷ or multiple sclerosis³⁸.

We did not find any loss of brain volume in the cortical grey matter or significant variation in cortical thickness. We performed this complementary cortical thickness approach because it is not influenced by the use of anatomical atlases in volumetric analysis.[46] Another explanation for absence of loss in cortical grey matter compared to other studies is that some of these studies involved athletes with repeated traumas. However, this type of pathophysiology is characterized by the occurrence of a tau-type pathology that has a more frequent tropism in the cortical grey matter[3] with a clinical

presentation dominated by motor disorders and Parkinson's syndrome[47]. Our population of severe TBI patients with an acute injury seems to represent a different class of specific neurodegenerative mechanisms that occur mostly in white matter structures.

From a structural point of view, no volumetric difference existed between MRI at baseline in GOSE 3–5 and GOSE 6–8 patients. However, at follow-up, TBI patients with GOSE 3–5 had significantly more atrophy in the brainstem, right hippocampus and left cerebral peduncle. The link between atrophy and impairment of clinical scores is supported by the observation that patients with GOSE 3–5 had a poorer episodic memory score at clinical follow-up and greater post-traumatic amnesia. However, a causal anatomo-functional relationship has still to be confirmed by a larger prospective trial.

Besides the volumetric characterization assessed by MRI, DTI provides information on white matter integrity and longitudinal change between baseline and follow-up. In our study, quantitative normalized measures showed that, in the subacute phase, patients have a low FA with a high MD, AD and RD in the deep part of the brain in corpus callosum, basal nuclei, cingulum and brainstem. At follow-up MRI, the FA was even lower, together with higher MD, AD and RD and with a more pronounced pattern in GOSE 3–5 patients. These results are consistent with studies that focused on DTI in TBI.[37,48] Interestingly, these results could be explained by biomechanical models, which show that the corpus callosum, brainstem, midbrain, thalami and deep white matter are particularly sensitive to shearing forces due to the mechanical properties of the falx cerebri, the tentorium cerebelli and association fiber tracts.[49,50] This distribution of biomechanical forces results in greater acute damage in these areas and might be indirectly tracked by MRI at the subacute phase.[51] Our exploration provides additional pathophysiological arguments since DTI measures and the severity of atrophy were highly correlated (Figure 4) with presence of an alteration in DTI at baseline and the occurrence of atrophy in the same region on the follow-up MRI. From an anatomopathological point of view, this

phenomenon could be explained by demyelination and axonal degeneration lesions that would both occur in the long term, explaining the concomitant increase in AD and RD. However, it remains unclear whether the presence of these lesions and the loss of volume that occurs in the chronic phase is inevitable due to the primary lesion or if it is an active dynamic process that could be mitigated by treatments. Likewise, it is possible that the evolution of neuropsychological outcomes may not be linear, with an initial improvement and then a deterioration when lesions occur.

DTI MRI is used to characterize neurological lesions accurately and has proven to be a promising tool to predict outcome in patients with altered consciousness.[31] Our SVM classifier at baseline showed that DTI can predict “unfavorable” recovery with normalized FA and MD. The best prognostic model performance for neurological outcomes was obtained by combining FA and MD measured at baseline MRI. DTI measurements obtained at baseline appear to be more useful than anatomical images in predicting the neurological evolution in the long term after TBI. Our model shows better prognostic performance than others[14,52–55] but needs to be tested in a validation cohort.

TBI studies are more and more often carried out with the support of sports federations in order to prevent the cognitive dysfunctions presented by athletes following violent and repeated concussion. This model remains very far from the nosological framework of TBI patients admitted in the ICU. Investigations of new treatments to limit neurodegenerative phenomena related to TBI could build on examples from other neurodegenerative diseases (e.g. Alzheimer's and Huntington's disease), using neuroimaging as a biomarker to guide the choice of endpoints for clinical trials. Our findings should be interpreted in light of the following potential limitations. First, we cannot exclude the possibility of unmeasured confounding factors in this observational study. We assessed 22 patients in our follow-up period, which represents only 12% of the

patients initially eligible for inclusion. TBI patients are well known to be exposed to a loss of follow-up for this kind of study. Corrigan et al. reported a loss of follow-up to 60% at two years[56] as the PariS-TBI study reports a cumulative loss of follow-up to 87% at four years.[57,58] In addition, our study design required even more restrictive criteria to include our patients than these studies (longitudinal MRI and GOSE3-8 patients). The neuropsychological evaluation planned in our study was only possible if patients could communicate. We do not have data for patients in a vegetative state (also coined unresponsive wakefulness syndrome) or who died as a result of TBI. Third, the prognostic model we provide is based on this small derivation cohort and requires a validation cohort to truly assess the reliability of the prognosis provided by the DTI data. Fourth, the study of structural MRI and anatomo-clinical correlation in severe TBI represents a real challenge both for image processing and for the interpretation of the results. Manual correction when automated segmentation fails could be considered as a limitation in our work, but it is still the recommended method in case of failure and seems unavoidable for severe TBI with radiological lesions, such as bruising and contusion. In addition, longitudinal image processing in FreeSurfer reduces inter-individual variability and increases the accuracy of extracted structural measurements.[18] Fifth, there is minor discrepancies in the scanner acquisition modalities. However, scanners are calibrated from HC with DTI parameters expressed as normalized data which allow direct comparison between subjects and has been previously approved.[30];[57,58][31] Similarly, all the effects described were found at an individual level with no inconsistent results.

Conclusions

This prospective study evaluated longitudinally the tertiary injuries occurring following severe TBI and reports the occurrence of significant brain atrophy in these patients. This atrophy predominates in the white matter and central grey nuclei while sparing the cortical grey matter. It demonstrates brain alterations long after the initial

injury. Its variation is associated with neurological outcomes in certain deep brain structures (brainstem, peduncle and hippocampus). This phenomenon is associated with a change in white matter integrity assessed by DTI and a significant decrease in the FA, and an increase in MD related to an alteration in RD and AD that were correlated with atrophy. These DTI anomalies are more pronounced in TBI with GOSE 3–5 than GOSE 6–8, suggesting a relationship between anatomic and neurological outcomes. Multimodal MRI, mainly white matter FA and MD a few weeks after TBI, was predictive of long-term brain changes in our study. However, the utility of this biomarker of brain injury must be confirmed in further prospective clinical trials. In this way, MRI lesions could be considered as a surrogate marker of neurological outcome that could be used to evaluate neuroprotective strategies. These data provide a better understanding of the early and late pathophysiology related to the neurological changes in patients after severe TBI and could encourage new interest in investigating neuroprotective therapies in these patients.

Acknowledgements: We would like to thank the patients, relatives, and clinical and research staff.

Funding: There was no industry-sponsored funding. The MRI-COMA trial was funded by independent research grants from non-profit or governmental agencies: the French Ministry of Health, Paris, France (Programme Hospitalier de Recherche Clinique 2005 #051061), and the French National Agency for Research (ANR) for the program "Investissements d'avenir" ANR-10-IAIHU-06 (to the Brain and Spine Institute); Fondation des "gueules cassées".

Declaration of conflicting interests: VP is the CEO of BrainTale SAS. The other authors declare that there is no conflict of interest.

Legends.

Figure 1. Flow diagram of the long-term MRI follow-up study. GOSE denotes extended Glasgow outcome scale.

Figure 2. Longitudinal comparison of brain volume variations. (A) Atrophy in individual white matter and deep grey nuclear structures in healthy controls and traumatic brain injury patients. The results are expressed as percentage of volumetric variation between baseline MRI (subacute phase) and follow-up MRI (chronic phase) in each region of interest according to a colorimetric scale without false discovery rate (FDR) correction and with frequency occurrence expressed in scale of opacity overlaid on selected sagittal, coronal and axial slices of a brain T1-template. (B) Volume variation after FDR correction in the most relevant regions of interest for white matter and deep grey nuclear structures and in (C) cortical grey matter structures. HC do not show any statistically significant volumetric difference while TBI patients have a loss of intracranial volume (atrophy) up to twenty percent in some territories. Atrophy mainly affects deep grey nuclear structures and deep white matter tracts of the brain. No statistically significant volumetric difference was found in cortical grey matter structures. CC = corpus callosum, HC = healthy controls and TBI = traumatic brain injury. All images are in radiological convention (left side of the image is right side of the brain). (D) Longitudinal variation of cortical gray matter thickness between baseline and follow-up in traumatic brain injury patients. Z-score differences (upper part) and areas with a statistical test p of less than 0.05 (not corrected by FDR) reported in red (lower part) are presented for each group.

Figure 3. Brain maps of normalized DTI index. Fractional anisotropy (A and C) and mean diffusivity (B-D) in white matter of traumatic brain injury (TBI) patients measured at

baseline (subacute phase) (**A-B**) and at follow-up (chronic phase) MRI (**C-D**), overlaid on selected sagittal, axial, and of coronal slices of a brain T1-template. All images are in radiological convention (left side of the image is right side of the brain).

Figure 4. Pearson's correlation coefficient between % of volume variation and DTI index at baseline MRI and follow-up MRI. Pearson's correlation coefficient (R^2) in traumatic brain injury patients between rate of % volume variation and normalized fractional anisotropy (**A-C**) and normalized mean diffusivity (**B-D**) measured at baseline MRI (**A-B**) and follow-up MRI (**C-D**). All images are in radiological convention (left side of the image is right side of the brain).

References

- [1] Wilson L, Stewart W, Dams-O'Connor K, Diaz-Arrastia R, Horton L, Menon DK, et al. The chronic and evolving neurological consequences of traumatic brain injury. *Lancet Neurol* 2017;16:813–25. [https://doi.org/10.1016/S1474-4422\(17\)30279-X](https://doi.org/10.1016/S1474-4422(17)30279-X).
- [2] Gardner RC, Burke JF, Nettiksimmons J, Kaup A, Barnes DE, Yaffe K. Dementia Risk After Traumatic Brain Injury vs Nonbrain Trauma: The Role of Age and Severity. *JAMA Neurol* 2014;71:1490. <https://doi.org/10.1001/jamaneurol.2014.2668>.
- [3] McKee AC, Stern RA, Nowinski CJ, Stein TD, Alvarez VE, Daneshvar DH, et al. The spectrum of disease in chronic traumatic encephalopathy. *Brain J Neurol* 2013;136:43–64. <https://doi.org/10.1093/brain/aws307>.
- [4] Faden AI, Loane DJ. Chronic Neurodegeneration After Traumatic Brain Injury: Alzheimer Disease, Chronic Traumatic Encephalopathy, or Persistent Neuroinflammation? *Neurotherapeutics* 2015;12:143–50. <https://doi.org/10.1007/s13311-014-0319-5>.
- [5] Gale SD, Burr RB, Bigler ED, Blatter D. Fornix degeneration and memory in traumatic brain injury. *Brain Res Bull* 1993;32:345–9.
- [6] Bigler ED. The lesion(s) in traumatic brain injury: implications for clinical neuropsychology. *Arch Clin Neuropsychol* 2001;16:95–131. [https://doi.org/10.1016/S0887-6177\(00\)00095-0](https://doi.org/10.1016/S0887-6177(00)00095-0).
- [7] Trivedi MA, Ward MA, Hess TM, Gale SD, Dempsey RJ, Rowley HA, et al. Longitudinal changes in global brain volume between 79 and 409 days after traumatic brain injury: relationship with duration of coma. *J Neurotrauma* 2007;24:766–71. <https://doi.org/10.1089/neu.2006.0205>.
- [8] Bendlin BB, Ries ML, Lazar M, Alexander AL, Dempsey RJ, Rowley HA, et al. Longitudinal changes in patients with traumatic brain injury assessed with diffusion-

tensor and volumetric imaging. *NeuroImage* 2008;42:503–14.

<https://doi.org/10.1016/j.neuroimage.2008.04.254>.

[9] Kim J, Avants B, Patel S, Whyte J, Coslett BH, Pluta J, et al. Structural consequences of diffuse traumatic brain injury: a large deformation tensor-based morphometry study. *NeuroImage* 2008;39:1014–26.

<https://doi.org/10.1016/j.neuroimage.2007.10.005>.

[10] Sidaros A, Skimminge A, Liptrot M, Sidaros K, Engberg A, Herning M, et al. Long-term global and regional brain volume changes following severe traumatic brain injury: A longitudinal study with clinical correlates. *NeuroImage* 2009;44:1–8.

<https://doi.org/10.1016/j.neuroimage.2008.08.030>.

[11] Jorge RE, Acion L, White T, Tordesillas-Gutierrez D, Pierson R, Crespo-Facorro B, et al. White Matter Abnormalities in Veterans With Mild Traumatic Brain Injury. *Am J Psychiatry* 2012;169:1284–91.

<https://doi.org/10.1176/appi.ajp.2012.12050600>.

[12] Finnanger TG, Skandsen T, Andersson S, Lydersen S, Vik A, Indredavik M. Differentiated patterns of cognitive impairment 12 months after severe and moderate traumatic brain injury. *Brain Inj* 2013;27.

<https://doi.org/10.3109/02699052.2013.831127>.

[13] Irimia A, Goh S-YM, Torgerson CM, Vespa PM, Van Horn JD. Structural and connectomic neuroimaging for the personalized study of longitudinal alterations in cortical shape, thickness and connectivity after traumatic brain injury. *J Neurosurg Sci* 2014;58:129–44.

[14] Håberg AK, Olsen A, Moen KG, Schirmer-Mikalsen K, Visser E, Finnanger TG, et al. White matter microstructure in chronic moderate-to-severe traumatic brain injury: Impact of acute-phase injury-related variables and associations with outcome measures. *J Neurosci Res* 2015;93:1109–26. <https://doi.org/10.1002/jnr.23534>.

- [15] Dall'Acqua P, Johannes S, Mica L, Simmen H-P, Glaab R, Fandino J, et al. Connectomic and Surface-Based Morphometric Correlates of Acute Mild Traumatic Brain Injury. *Front Hum Neurosci* 2016;127.
<https://doi.org/10.3389/fnhum.2016.00127>.
- [16] Asken BM, DeKosky ST, Clugston JR, Jaffee MS, Bauer RM. Diffusion tensor imaging (DTI) findings in adult civilian, military, and sport-related mild traumatic brain injury (mTBI): a systematic critical review. *Brain Imaging Behav* 2017;1–28.
<https://doi.org/10.1007/s11682-017-9708-9>.
- [17] Jennett B, Snoek J, Bond MR, Brooks N. Disability after severe head injury: observations on the use of the Glasgow Outcome Scale. *J Neurol Neurosurg Psychiatry* 1981;44:285–93.
- [18] Reuter M, Schmansky NJ, Rosas HD, Fischl B. Within-subject template estimation for unbiased longitudinal image analysis. *Neuroimage* 2012;61:1402.
<https://doi.org/10.1016/j.neuroimage.2012.02.084>.
- [19] Dale AM, Fischl B, Sereno MI. Cortical surface-based analysis. I. Segmentation and surface reconstruction. *NeuroImage* 1999;9:179–94.
<https://doi.org/10.1006/nimg.1998.0395>.
- [20] Fischl B, Sereno MI, Dale AM. Cortical Surface-Based Analysis: II: Inflation, Flattening, and a Surface-Based Coordinate System. *NeuroImage* 1999;9:195–207.
<https://doi.org/10.1006/nimg.1998.0396>.
- [21] Fischl B, Salat DH, Busa E, Albert M, Dieterich M, Haselgrove C, et al. Whole brain segmentation: automated labeling of neuroanatomical structures in the human brain. *Neuron* 2002;33:341–55.
- [22] Fischl B, Dale AM. Measuring the thickness of the human cerebral cortex from magnetic resonance images. *Proc Natl Acad Sci* 2000;97:11050–5.
<https://doi.org/10.1073/pnas.200033797>.

- [23] Fischl B, Salat DH, van der Kouwe AJW, Makris N, Ségonne F, Quinn BT, et al. Sequence-independent segmentation of magnetic resonance images. *NeuroImage* 2004;23:S69–84. <https://doi.org/10.1016/j.neuroimage.2004.07.016>.
- [24] Desikan RS, Ségonne F, Fischl B, Quinn BT, Dickerson BC, Blacker D, et al. An automated labeling system for subdividing the human cerebral cortex on MRI scans into gyral based regions of interest. *NeuroImage* 2006;31:968–80. <https://doi.org/10.1016/j.neuroimage.2006.01.021>.
- [25] Reuter M, Rosas HD, Fischl B. Highly accurate inverse consistent registration: a robust approach. *NeuroImage* 2010;53:1181–96. <https://doi.org/10.1016/j.neuroimage.2010.07.020>.
- [26] Westman E, Aguilar C, Muehlboeck J-S, Simmons A. Regional magnetic resonance imaging measures for multivariate analysis in Alzheimer’s disease and mild cognitive impairment. *Brain Topogr* 2013;26:9–23. <https://doi.org/10.1007/s10548-012-0246-x>.
- [27] Iorio M, Spalletta G, Chiapponi C, Luccichenti G, Cacciari C, Orfei MD, et al. White matter hyperintensities segmentation: a new semi-automated method. *Front Aging Neurosci* 2013;5:76.
- [28] Cole JH, Jolly A, de Simoni S, Bourke N, Patel MC, Scott G, et al. Spatial patterns of progressive brain volume loss after moderate-severe traumatic brain injury. *Brain* 2018;141:822–36.
- [29] Woolrich MW, Jbabdi S, Patenaude B, Chappell M, Makni S, Behrens T, et al. Bayesian analysis of neuroimaging data in FSL. *NeuroImage* 2009;45:S173-186. <https://doi.org/10.1016/j.neuroimage.2008.10.055>.
- [30] Galanaud D, Perlberg V, Gupta R, Stevens RD, Sanchez P, Tollard E, et al. Assessment of White Matter Injury and Outcome in Severe Brain Trauma: A Prospective Multicenter Cohort. *Anesthesiology* 2012;117:1300–10.

<https://doi.org/10.1097/ALN.0b013e3182755558>.

[31] Velly L, Perlberg V, Boulier T, Adam N, Delphine S, Luyt C-E, et al. Use of brain diffusion tensor imaging for the prediction of long-term neurological outcomes in patients after cardiac arrest: a multicentre, international, prospective, observational, cohort study. *Lancet Neurol* 2018;17:317–26. [https://doi.org/10.1016/S1474-4422\(18\)30027-9](https://doi.org/10.1016/S1474-4422(18)30027-9).

[32] Malone IB, Leung KK, Clegg S, Barnes J, Whitwell JL, Ashburner J, et al. Accurate automatic estimation of total intracranial volume: A nuisance variable with less nuisance. *Neuroimage* 2015;104:366–72.

<https://doi.org/10.1016/j.neuroimage.2014.09.034>.

[33] Westman E, Simmons A, Muehlboeck J-S, Mecocci P, Vellas B, Tsolaki M, et al. AddNeuroMed and ADNI: similar patterns of Alzheimer’s atrophy and automated MRI classification accuracy in Europe and North America. *NeuroImage* 2011;58:818–28. <https://doi.org/10.1016/j.neuroimage.2011.06.065>.

[34] Winkler AM, Ridgway GR, Webster MA, Smith SM, Nichols TE. Permutation inference for the general linear model. *Neuroimage* 2014;92:381–97.

<https://doi.org/10.1016/j.neuroimage.2014.01.060>.

[35] Yeo RA, BIGLER E. CALLOSAL MORPHOLOGY IN CLOSED-HEAD-INJURY PATIENTS. *J. Clin. Exp. Neuropsychol.*, vol. 13, SWETS ZEITLINGER PUBLISHERS PO BOX 825, 2160 SZ LISSE, NETHERLANDS; 1991, p. 63–63.

[36] Gale SD, Baxter L, Roundy N, Johnson SC. Traumatic brain injury and grey matter concentration: a preliminary voxel based morphometry study. *J Neurol Neurosurg Psychiatry* 2005;76:984–8.

[37] Newcombe VFJ, Correia MM, Ledig C, Abate MG, Outtrim JG, Chatfield D, et al. Dynamic Changes in White Matter Abnormalities Correlate With Late Improvement and Deterioration Following TBI: A Diffusion Tensor Imaging Study.

Neurorehabil Neural Repair 2016;30:49–62.

<https://doi.org/10.1177/1545968315584004>.

[38] Kesinger MR, Kumar RG, Wagner AK, Puyana JC, Peitzman AP, Billiar TR, et al. Hospital Acquired Pneumonia is an Independent Predictor of Poor Global Outcome in Severe Traumatic Brain Injury up to 5 Years after Discharge. *J Trauma Acute Care Surg* 2015;78:396–402. <https://doi.org/10.1097/TA.0000000000000526>.

[39] Kumar RG, Kesinger MR, Juengst SB, Brooks MM, Fabio A, Dams-O'Connor K, et al. Effects of Hospital-Acquired Pneumonia on Long-Term Recovery and Hospital Resource Utilization Following Moderate to Severe Traumatic Brain Injury. *J Trauma Acute Care Surg* 2020;88:491–500.

<https://doi.org/10.1097/TA.0000000000002562>.

[40] Ross DE, Ochs AL, Seabaugh JM, DeMark MF, Shrader CR, Marwitz JH, et al. Progressive brain atrophy in patients with chronic neuropsychiatric symptoms after mild traumatic brain injury: a preliminary study. *Brain Inj* 2012;26:1500–9.

[41] Tomaiuolo F, Bivona U, Lerch JP, Di Paola M, Carlesimo GA, Ciurli P, et al. Memory and anatomical change in severe non missile traumatic brain injury: ~ 1 vs. ~ 8 years follow-up. *Brain Res Bull* 2012;87:373–82.

[42] Brezova V, Moen KG, Skandsen T, Vik A, Brewer JB, Salvesen Ø, et al. Prospective longitudinal MRI study of brain volumes and diffusion changes during the first year after moderate to severe traumatic brain injury. *NeuroImage Clin* 2014;5:128–40.

[43] Hedman AM, van Haren NE, Schnack HG, Kahn RS, Hulshoff Pol HE. Human brain changes across the life span: a review of 56 longitudinal magnetic resonance imaging studies. *Hum Brain Mapp* 2012;33:1987–2002.

[44] Smeets D, Ribbens A, Sima DM, Cambron M, Horakova D, Jain S, et al. Reliable measurements of brain atrophy in individual patients with multiple sclerosis.

Brain Behav 2016;6. <https://doi.org/10.1002/brb3.518>.

[45] Chan D, Janssen JC, Whitwell JL, Watt HC, Jenkins R, Frost C, et al. Change in rates of cerebral atrophy over time in early-onset Alzheimer's disease: longitudinal MRI study. *The Lancet* 2003;362:1121–2. [https://doi.org/10.1016/S0140-6736\(03\)14469-8](https://doi.org/10.1016/S0140-6736(03)14469-8).

[46] Kong L, Herold CJ, Zöllner F, Salat DH, Lässer MM, Schmid LA, et al. Comparison of grey matter volume and thickness for analysing cortical changes in chronic schizophrenia: a matter of surface area, grey/white matter intensity contrast, and curvature. *Psychiatry Res* 2015;231:176–83. <https://doi.org/10.1016/j.psychresns.2014.12.004>.

[47] Zhang X, Gao F, Wang D, Li C, Fu Y, He W, et al. Tau Pathology in Parkinson's Disease. *Front Neurol* 2018;9. <https://doi.org/10.3389/fneur.2018.00809>.

[48] Roberts RM, Mathias JL, Rose SE. Diffusion Tensor Imaging (DTI) Findings Following Pediatric Non-Penetrating TBI: A Meta-Analysis. *Dev Neuropsychol* 2014;39:600–37. <https://doi.org/10.1080/87565641.2014.973958>.

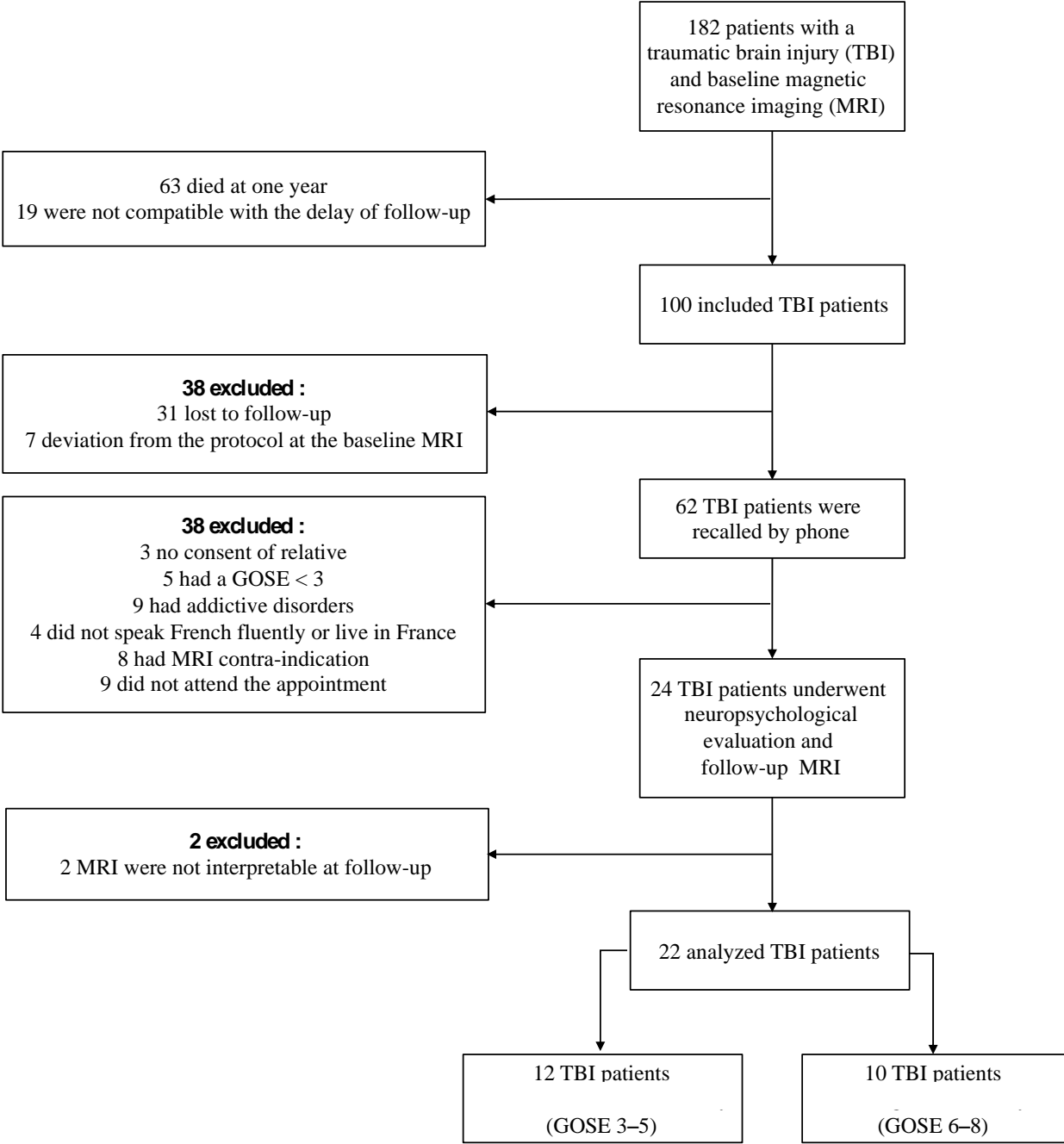
[49] Ho J, Zhou Z, Li X, Kleiven S. The peculiar properties of the falx and tentorium in brain injury biomechanics. *J Biomech* 2017;60. <https://doi.org/10.1016/j.jbiomech.2017.06.023>.

[50] Giordano C, Zappalà S, Kleiven S. Anisotropic finite element models for brain injury prediction: the sensitivity of axonal strain to white matter tract inter-subject variability. *Biomech Model Mechanobiol* 2017;16:1269–93. <https://doi.org/10.1007/s10237-017-0887-5>.

[51] Harris JL, Yeh H-W, Choi I-Y, Lee P, Berman NE, Swerdlow RH, et al. Altered neurochemical profile after traumatic brain injury: 1H-MRS biomarkers of pathological mechanisms. *J Cereb Blood Flow Metab* 2012;32:2122–34. <https://doi.org/10.1038/jcbfm.2012.114>.

- [52] Moen KG, Vik A, Olsen A, Skandsen T, Håberg AK, Evensen KAI, et al. Traumatic axonal injury: Relationships between lesions in the early phase and diffusion tensor imaging parameters in the chronic phase of traumatic brain injury. *J Neurosci Res* 2016;94:623–35. <https://doi.org/10.1002/jnr.23728>.
- [53] Edlow BL, Copen WA, Izzy S, Bakhadirov K, van der Kouwe A, Glenn MB, et al. Diffusion tensor imaging in acute-to-subacute traumatic brain injury: a longitudinal analysis. *BMC Neurol* 2016;16. <https://doi.org/10.1186/s12883-015-0525-8>.
- [54] Rutgers DR, Fillard P, Paradot G, Tadié M, Lasjaunias P, Ducreux D. Diffusion tensor imaging characteristics of the corpus callosum in mild, moderate, and severe traumatic brain injury. *AJNR Am J Neuroradiol* 2008;29:1730–5. <https://doi.org/10.3174/ajnr.A1213>.
- [55] Shakir A, Aksoy D, Mlynash M, Harris OA, Albers GW, Hirsch KG. Prognostic Value of Quantitative Diffusion-Weighted MRI in Patients with Traumatic Brain Injury. *J Neuroimaging* 2016;26:103–8. <https://doi.org/10.1111/jon.12286>.
- [56] Corrigan JD, Harrison-Felix C, Bogner J, Dijkers M, Terrill MS, Whiteneck G. Systematic bias in traumatic brain injury outcome studies because of loss to follow-up. *Arch Phys Med Rehabil* 2003;84:153–60. <https://doi.org/10.1053/apmr.2003.50093>.
- [57] Jourdan C, Bayen E, Bahrami S, Ghout I, Darnoux E, Azerad S, et al. Loss to Follow-Up and Social Background in an Inception Cohort of Patients With Severe Traumatic Brain Injury: Results From the PariS-TBI Study. *J Head Trauma Rehabil* 2016;31:E42-48. <https://doi.org/10.1097/HTR.000000000000147>.
- [58] Ruet A, Bayen E, Jourdan C, Ghout I, Meaude L, Lalanne A, et al. A Detailed Overview of Long-Term Outcomes in Severe Traumatic Brain Injury Eight Years Post-injury. *Front Neurol* 2019;10. <https://doi.org/10.3389/fneur.2019.00120>.

Figure 1.



GOSE = extended Glasgow outcome scale.

Figure 2.

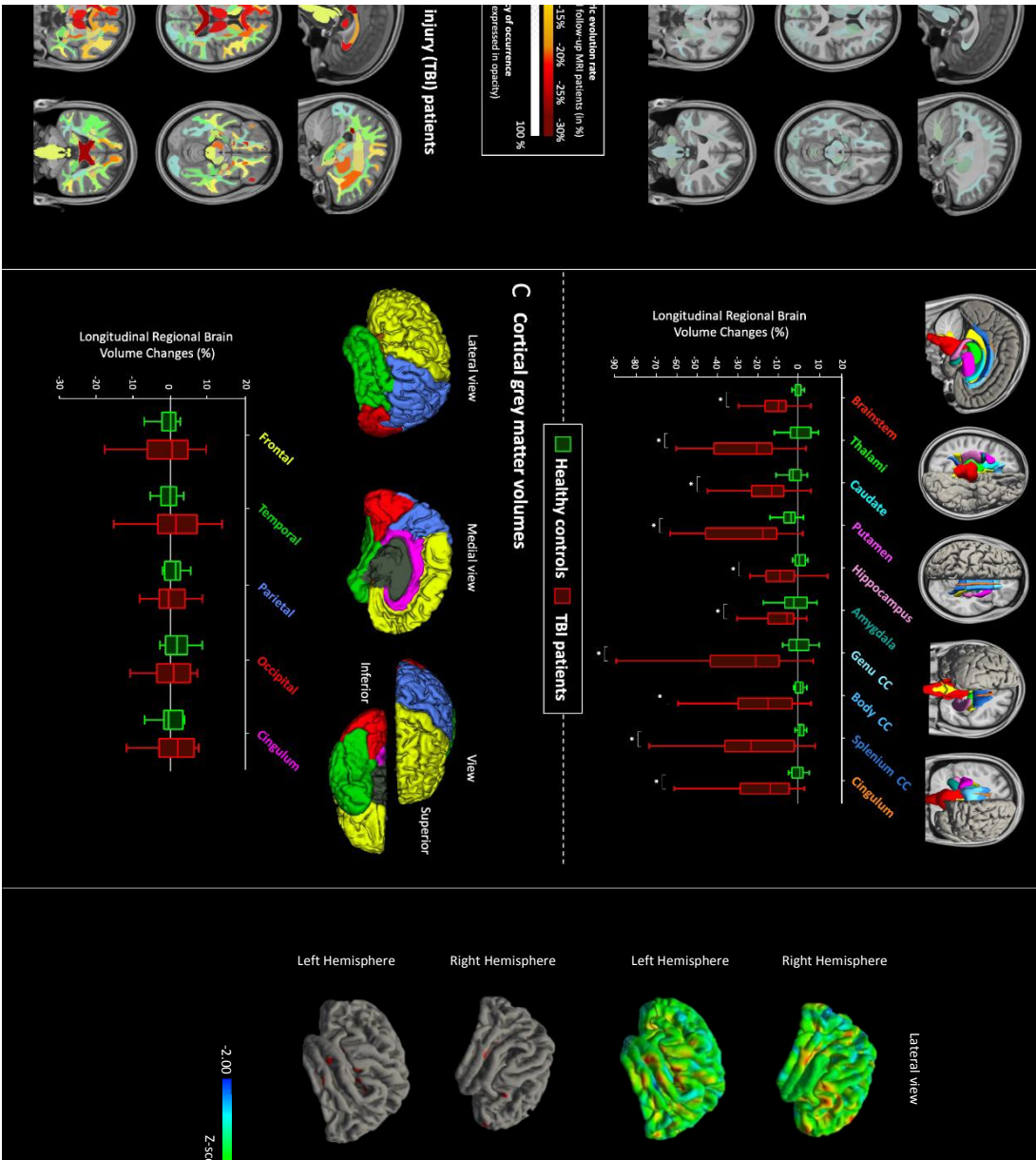


Figure 3.

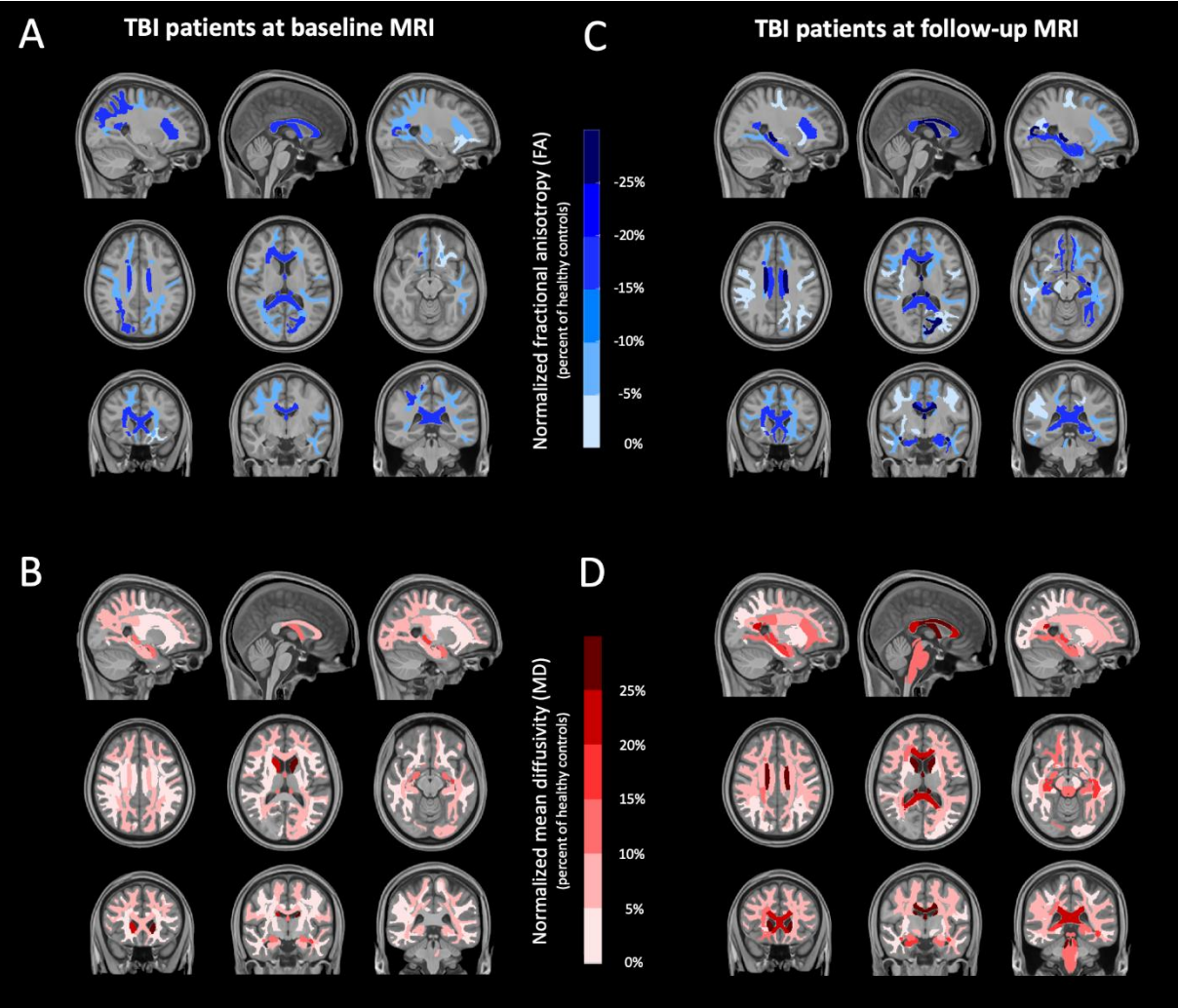


Figure 4.

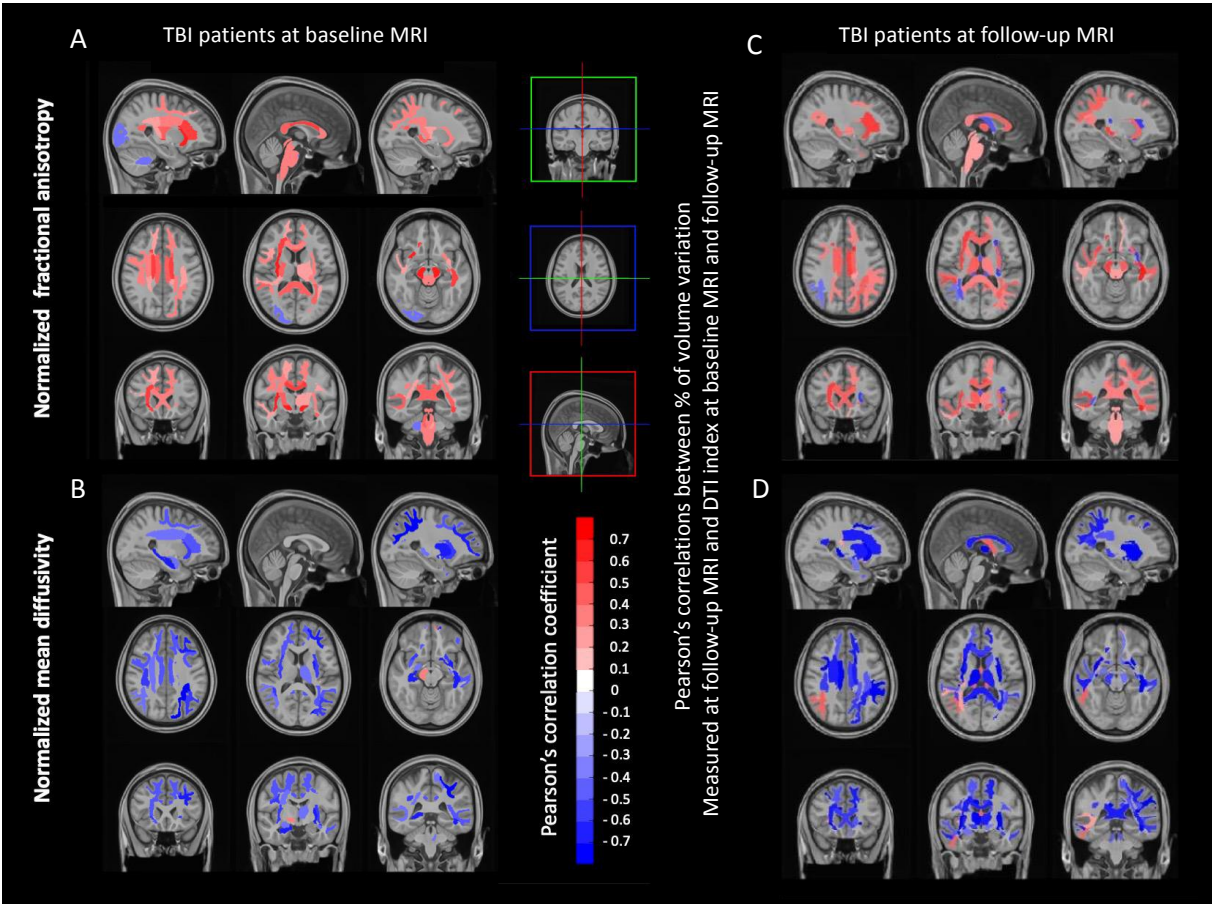


Table 1. Cohort demographic, clinical and radiographic characteristics during intensive care unit stay.

Parameters	All patients (<i>n</i> = 22)	“Unfavorable” recovery (GOSE 3–5) (<i>n</i> = 12)	“Favorable” recovery (GOSE 6–8) (<i>n</i> = 10)	<i>P</i> -values ⁱ
<i>Demographic and clinical presentation</i>				
Sex (males), <i>n</i> (%)	19 (86)	10 (83)	9 (90)	0.650
Age (yr)	30 ± 13	32 ± 15	28 ± 10	0.442
Right-handed, <i>n</i> (%)	16 (73)	10 (84)	6 (60)	0.840
Education status ^b	6 [5–7]	5 [4–7]	6 [5–7]	0.509
Cause of TBI, <i>n</i> (%)				
Assault	2 (9)	1 (8)	1 (10)	1
Motor vehicle accidents	15 (69)	8 (66)	7 (70)	1
Fall	5 (22)	3 (25)	2 (20)	1
Glasgow Coma Score ^c at admission	6 [3–10]	5 [3–7]	7 [3–12]	0.297
Worst Glasgow Coma Score during hospital stay	5 [3–7]	5 [3–6]	4 [3–8]	0.307
Glasgow Coma Score at the first MRI	7 [5–10]	7 [5–10]	8 [3–10]	0.699
Day with sedation	13 ± 6	12 ± 6	14 ± 6	0.521
Duration of coma (in days)	25 [14–33]	31 [15–36]	16 [14–25]	0.105
Seizures during hospital stay	2 (11)	2 (20)	0 (0)	0.179
<i>Initial CT scan</i>				
Marshall grade ^d initial CT scan	2 [2–3]	2 [2–5]	2 [2–2]	0.162
<i>Location of injury, n (%)</i>				
Left hemisphere	4 (28)	3 (25)	1 (10)	0.593
Right hemisphere	3 (13)	1 (8)	2 (20)	0.380
Bilateral	15 (68)	8 (66)	7 (70)	0.863
Cerebellum lesion	2 (11)	1 (10)	1 (12.5)	0.866

Category of injury, n (%)

Intracerebral hematoma	9 (50)	7 (70)	2 (25)	0.057
Extradural hematoma	5 (27)	3 (30)	2 (25)	0.813
Subdural hematoma	3 (16)	1 (10)	2 (25)	0.396
Sub-arachnoid hemorrhage	11 (61)	8 (80)	3 (37.5)	0.066
Petechial lesion	8 (44)	4 (40)	4 (50)	0.671

Injury classification on basis of MRI at baseline

Whole-brain MRI lesion volume (mm ³)	797 [42–5903]	1367 [41–11475]	347 [38–9384]	0.890
Diffuse axonal injury ^e (grading)	2 [1–3]	2 [1–3]	1 [1–2]	0.297
Firsching Score ^f (grading)	1 [1–2]	1 [1–2]	1 [1–1]	0.280

Data are expressed as mean \pm SD, median [IQR] or counts (%) when appropriate.

CT denotes computed tomography; GOSE, extended Glasgow outcome scale and MRI, magnetic resonance imaging.

^a *P*-value for patients with a “favorable” recovery (GOSE 6–8) versus those with “unfavorable” recovery (GOSE 3–5).

^b Education status is expressed as follow: 2: No diploma but able to read and write, 3: Middle school for at least two years; 4: Middle school until 9th grade; 5: High School; 6: High-School Diploma; 7: three-year university or technical degree.

^c Scores on the Glasgow Coma Scale range from 3 to 15, with lower scores indicating reduced levels of consciousness.

^d Marshall grade presented in the Supplementary material, page 22.

^e Diffuse axonal injury (grading) presented in the Supplementary material, page 23.

^f Firsching Score (grading) presented in the Supplementary material, page 24.

Table 2. Cohort clinical presentation at follow-up (chronic phase).

	All TBI patients (<i>n</i> = 22)	-“Unfavorable” recovery (GOSE 3-5) (<i>n</i> = 12)	“Favorable” recovery (GOSE 6-8) (<i>n</i> = 10)	<i>P</i> -value ^a
Clinical presentation at follow-up, <i>n</i> (%)				
Re-education process	8 (50)	7 (43)	1 (6)	0.008
Unable to work or only in sheltered workshop	12 (70)	9 (100)	3 (37)	0.009
Driving	9 (52)	3 (33)	6 (86)	0.036
Post-traumatic amnesia ^b	7 (46)	6 (66)	1 (15)	0.046
Seizures	5 (28)	2 (20)	3 (38)	0.410
Motor disabilities	9 (52)	6 (66)	6 (75)	0.186
Clinical and neuropsychological scores at follow-up^c				
Episodic memory score (z-score)	-2.6 ± 2.7	-4.4 ± 2.2	-0.3 ± 1.3	<0.001
Executive function score (z-score)	-4.0 ± 3.4	-5.7 ± 3.2	-1.8 ± 2.3	0.018
Work memory Score (z-score)	-1.7 ± 2.6	-2.7 ± 2.9	-0.5 ± 1.7	0.075
Attentional Score (z-score)	-4.4 ± 4.1	-5.7 ± 4.9	-2.7 ± 2.3	0.080

Data are expressed as mean ± SD or counts (%) when appropriate.

^a *P*-value for patients with a “favorable” recovery (GOSE 6–8) vs those with “unfavorable” recovery (GOSE 3–5).

^b Presence of a post-traumatic amnesia longer than 60 days after traumatic brain injury.

^c All neuropsychological scores are detailed in the Supplementary material, Appendix 2.

Table 3. Brain volume measurement at baseline (subacute phase) and follow-up (chronic phase).

Intracranial volume	Healthy controls (<i>n</i> = 11)	All TBI patients (<i>n</i> = 22)	-“Favorable” recovery (GOSE 6-8) (<i>n</i> = 10)	-“Unfavorable” recovery (GOSE 3-5) (<i>n</i> = 12)
Estimated total intracranial volume (cm ³)	1440 [1270–1704]	1626 [1546–1676]	1647 [1531–1699]	1610 [1556–1677]
<i>At baseline^c</i>				
Whole grey matter	0.33 [0.30–0.35]	0.31 [0.29–0.32]	0.32 [0.30–0.33]	0.31 [0.28–0.32]
Whole white matter	0.31 [0.29–0.33]	0.29 [0.28–0.32]	0.29 [0.28–0.32]	0.29 [0.27–0.31]
Deep white matter tracts from JHU-ICBM Atlas ^d	0.09 [0.09–0.10]	0.09 [0.08–0.09]	0.10 [0.10–0.11]	0.10 [0.10–0.11]
Deep grey nuclear structures ^e	0.03 [0.02–0.03]	0.03 [0.02–0.03]	0.02 [0.03–0.03]	0.03 [0.02–0.03]
<i>At follow-up^c</i>				
Whole grey matter	0.33 [0.29–0.35]	0.30 [0.29–0.32]	0.31 [0.30–0.33]	0.30 [0.28–0.32]
Whole white matter	0.31 [0.29–0.33]	0.26 [0.25–0.28] ^{ab}	0.27 [0.26–0.29] ^{ab}	0.25 [0.25–0.27] ^{ab}
Deep white matter tracts from JHU-ICBM Atlas ^d	0.11 [0.10–0.12]	0.09 [0.09–0.10] ^{ab}	0.09 [0.09–0.10] ^{ab}	0.09 [0.09–0.10] ^{ab}
Deep grey nuclear structures ^e	0.03 [0.02–0.03]	0.02 [0.02–0.02] ^{ab}	0.02 [0.02–0.02] ^{ab}	0.02 [0.02–0.02] ^{ab}

Data are expressed as median (IQR).

^a *P*-value <0.05 versus healthy controls; ^b *P*-value <0.05 versus baseline and follow-up.

^c Intracranial volume data are divided by estimated total intracranial volume generated by FreeSurfer in order to consider head-size inter-subject variability.

^d Deep white matter tracts from Johns Hopkins University Atlas (Woolrich *et al.*, 2009).

^e Deep grey nuclear structures included left and right thalamus, caudate, putamen, pallidum and accumbens area.