



HAL
open science

Physician modified stent-graft for blunt thoracic aortic injuries: do the benefits worth the trouble?

Youcef Lounes, Amin Belarbi, Kheira Hireche, Lucien Chassin-Trubert, Baris Ata Ozdemir, Mariama Akodad, Pierre Alric, Ludovic Canaud

► To cite this version:

Youcef Lounes, Amin Belarbi, Kheira Hireche, Lucien Chassin-Trubert, Baris Ata Ozdemir, et al.. Physician modified stent-graft for blunt thoracic aortic injuries: do the benefits worth the trouble?. *Annals of Vascular Surgery*, 2022, 90, pp.100-108. 10.1016/j.avsg.2022.09.054 . hal-03825247

HAL Id: hal-03825247

<https://hal.science/hal-03825247>

Submitted on 6 Jul 2023

HAL is a multi-disciplinary open access archive for the deposit and dissemination of scientific research documents, whether they are published or not. The documents may come from teaching and research institutions in France or abroad, or from public or private research centers.

L'archive ouverte pluridisciplinaire **HAL**, est destinée au dépôt et à la diffusion de documents scientifiques de niveau recherche, publiés ou non, émanant des établissements d'enseignement et de recherche français ou étrangers, des laboratoires publics ou privés.

Physician-Modified Stent Graft for Blunt Thoracic Aortic Injuries: Do the Benefits Worth the Trouble?

Youcef Lounes, 1,2 Amin Belarbi, 1 Kheira Hireche, 1 Lucien Chassin-Trubert, 1

Baris Ata Ozdemir, 1,3,4 Mariama Akodad, 2,3 Pierre Alric, 1,2 and Ludovic Canaud, 1,2

Montpellier, France; Bristol, UK

1 Department of Vascular and Thoracic Surgery, University of Montpellier, CHU Montpellier, Montpellier, France.

2 PhyMedExp, Univ Montpellier, CNRS, INSERM, CHU Montpellier, Montpellier, France.

3 Department of Cardiology, University of Montpellier, CHU Montpellier, Montpellier, France.

4 University of Bristol, Bristol, UK.

Correspondence to:

Dr Lounes Youcef, Vascular Surgery Department, Montpellier University Hospital, 371 Avenue Doyen Gaston Giraud 34090, Montpellier, France;

E-mail: youceflounes@gmail.com

Background:

Obtaining a suitable proximal landing zone in blunt thoracic aortic injuries (BTAI) often necessitates coverage of the left subclavian artery (LSA). This study aimed to evaluate the outcomes of physician-modified endovascular grafts (PMEGs) in this indication.

Methods:

We performed a retrospective analysis of a prospective registry including all patients who had undergone a thoracic endovascular aortic repair (TEVAR) for BTAI from October 2008 to October 2020. Starting in 2015, patients requiring coverage of the LSA were either treated using a physician-modified proximal scalloped or single-fenestrated stent graft. After an early postoperative computed tomography scan, follow-up was performed at 3 months, 6-months, and yearly.

Results:

Among 58 patients treated with TEVAR for BTAI, 23 (39.6%) patients required a zone 2 landing zone of which 10 (17.2%) patients were treated with PMEGs. The median age was 48 [31e64.5] years, and 78.2% (n ¼ 18) patients were male. The median Injury Severity Score was 38 [27e55.5]. Coverage of the LSA was performed in 25.8% (n ¼ 15) of the total population in which 5 patients had an LSA transposition. The median modification time was 18 [14e27] minutes. Technical success of PMEGs was 90.0% overall and 100% for fenestrated stent grafts. No stroke, paraplegia, or retrograde dissection was observed. The primary patency of the LSA in the PMEGs group was 90 % at 1 year and 28.8 % in the LSA coverage group (P < 0.01).

Conclusions:

The use of PMEGs is feasible and effective in the management of BTAI with a short proximal

--

INTRODUCTION

Although of low prevalence, transection of the thoracic aorta because of blunt injury frequently results in death.¹ Treatment of blunt thoracic aortic injuries (BTAI) has dramatically evolved over the past 20 years. Thoracic endovascular aortic repair (TEVAR) has been adopted as standard of care largely replacing open surgery.^{2e4} BTAI commonly occurs at the aortic isthmus, therefore, in more than 30% of cases, deliberate coverage of the left subclavian artery (LSA) becomes necessary.² Mohapatra et al. demonstrated, in a series of 633 TEVARs for BTAI, a significant association between LSA involvement and mortality.⁵ The management of the LSA has always been a source of controversy in this context and may include systematic, delayed, or selective revascularization. However, optimal management of the LSA remains unclear.^{6,7} Covering the LSA can occasionally lead to complications such as stroke, left arm ischemia, and paraplegia.⁸ In emergency situations, the European Society for Vascular Surgery recommends revascularization of the LSA in case of left mammary coronary bypass or dominant cerebral blood supply from the left vertebral.⁹

Physician-modified endovascular grafts (PMEGs) can be an elegant solution to preserve patency of the supra aortic trunk. Our team has already published the early outcomes of PMEGs in zone 2^{10,11} for all type of aortic lesions. The evaluation of this technique specifically in traumatic thoracic aortic rupture is missing in the literature.

The purpose of this study was to evaluate the outcomes of traumatic thoracic aortic rupture who required a zone 2 or above landing zone and compare outcomes between groups with and without PMEGs.

METHOD

Study Population and Data Collection

A review of a prospective database of patients undergoing TEVAR for traumatic rupture of the descending thoracic aorta in our center was performed. All patients from October 2008 (implanted with the second generation of TEVAR) to October 2020 were included. Among the patients who required a zone 2 landing zone or above, we compared those who had a PEMG performed (PEMG group) with those who had an LSA coverage (LSA coverage group). Diagnosis of aortic disruption was achieved by a total body contrast-enhanced computed tomography (CT) scan of all patients.

Demographic data, early and mid-term outcomes were evaluated. Patients were prospectively monitored by a control CT scan before hospital discharge, at 3, 6, and 12 months and then annually. Symptoms of vertigo or left arm claudication were recorded. The study was approved by the authors' institutional review and ethics committees. Informed consent was provided for the database.

Therapeutic Strategy

Patients underwent TEVAR urgently unless they required other more urgent procedures (damage control surgery or orthopedic pelvic stabilization). Grades I and II were treated if an early pathological evolution was detected on the repeat CT scan. All procedures were achieved under general anesthesia and cerebrospinal fluid drainage was never performed. Depending on the presence or absence of other injuries and the coagulation status, half dose or no heparin was utilized. Trans-femoral access with a surgical cut down was preferred until 2017 whereupon percutaneous approach was also utilized using Perclose ProGlide® devices (Abbott Vascular, Santa Clara, CA). Sizing for the repair was performed from the CT scan using the EndoSize 3D vascular imaging workstation with centerline luminal reconstruction (Therenva, v.3.1.25, Nanjing, France). A proximal landing zone of 20 mm without dissection or lesions was defined as suitable for the procedure. As per instructions for use, oversizing of 10e20% was the norm, but may have been greater for patients with very small aortas under 20 mm, who were usually in shock and young with a tolerance up to 40%. When a surgical revascularization was used for the LSA, a transposition to the left common carotid artery was performed. Technical success was defined by successful completion of the planned procedure, which may include intentional coverage of the LSA. Accidental coverage of supra-aortic trunks, type I endoleak in the final angiogram, or a crossing failure were considered failures.

LSA Management Strategy

In case of critical hemodynamic situations and a short neck, intentional coverage of the LSA was realized. Otherwise, a surgical revascularization was used for the LSA. A transposition to the left common carotid artery was performed through a cervical access. After 2015, revascularizations were realized with a scallop or a fenestrated physician modified stent graft. Distribution of the cases over the study period are described in [Figure 1](#).

Device Preparation

In 2015, our team started utilizing PMEG. Initially this was with a proximal scallop planned for landing in zone 2. This technique has previously been described.¹⁰ The approach shifted quickly to a single fenestration, then, with the use of a preloaded wire in 2017. All PMEGs utilized the Valiant Captivia stent graft (Medtronic, Minneapolis, MN, USA).

The 2 proximal stents are unsheathed on a back table without releasing the tip capture mechanism ([Fig. 2A](#)). The site of the LSA fenestrations is chosen in accordance with the CT scan measurements and avoiding stent strut crossing. At least 5 mm of fabric stent graft is left untouched between the proximal edge of the stent graft and the fenestration, to avoid compromising the integrity and stability of grafts. A cautery device is used to carefully burn the Dacron fabric to fashion the 8e10 mm fenestration depending on the LSA diameter. Thereafter, to mark the position of the LSA fenestration and to reinforce seal around the fenestration, a radiopaque nitinol wire (loop of a snare, EV3 Amplatz Goose Neck Snare, Medtronic, Santa Rosa, Calif, USA) is sutured onto the margin of the fenestration ([Fig. 2A](#)). More recently, a preloaded wire has been added to the technique to ensure the catheterization of the fenestration, as previously published.¹²

PMEGs Procedural Details

The procedure was performed in a hybrid room (Artis, Zeego, Siemens Healthcare GmbH Erlangen, Germany) when available or with classic C-arm fluoroscopy. Left subclavian access was performed through open brachial or percutaneous distal radial access depending on the choice of the stent used. In case of misalignment of the modified graft, a second graft with coverage of the LSA would be placed. Modifications of the endoprosthesis were performed while the patient was prepared for surgery and are not included in the operative time reported. The procedure for PMEGs has already been described ^{10e13} and is summarized in [Figure 3](#). For standard TEVAR (i.e. no physician modification) both the Medtronic Valiant Captivia_ (Medtronic, Minneapolis, MN, USA) and Gore ^{C-TAG®} (W.L. Gore& Associates, Flagstaff, AZ, USA) were used.

Statistical Analysis

Statistical analysis was performed using SPSS IBM software, 25 version (IBM, Armonk, NY). Categorical variables were expressed as numbers and percentages of patients, and continuous variables as means and standard deviation or median and interquartile depending on the distribution. Comparisons were with the chi-squared test or Fisher's exact test for categorical variables and with Manne Whitney for continuous variables. The Kaplan Meier method was employed to calculate the primary patency rates. All tests were 2-sided using an alpha <0.05 considered statistically significant.

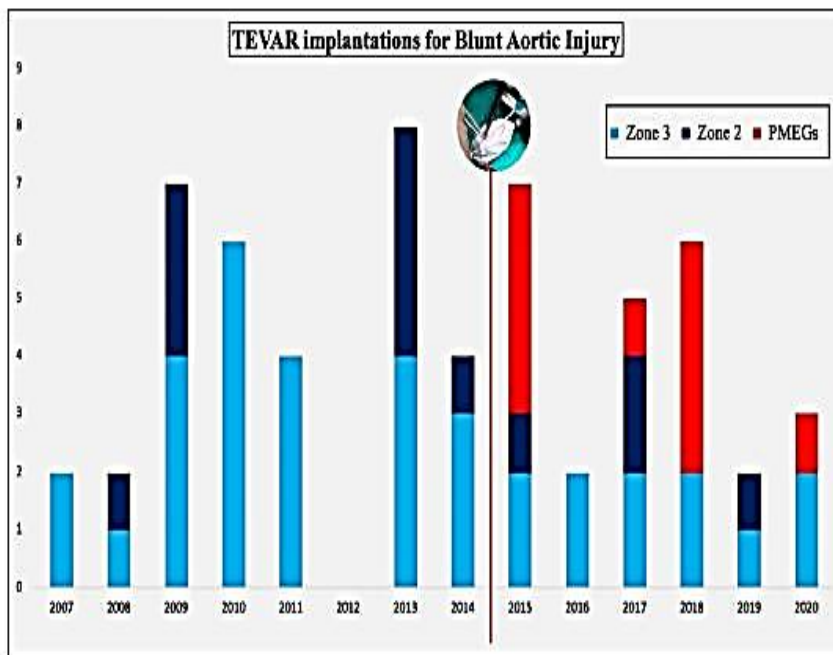


Fig. 1. Distribution of cases over the years and evolution of the implantation's zone of TEVAR during the study period. The red line represents the beginning of the PMEGs activity.

RESULTS

Population Baseline Characteristics

Within the study period, 58 patients were treated by TEVAR for BTAI, and 23 patients were placed in or above zone 2. The median age was 48 [31-64.5] years with 78.2% of men (n ¼ 18) (Table I). The principal mechanism of trauma was road traffic accidents (86.9%; n ¼ 20), one patient had a penetrating injury (4.4%), and 2 patients (8.7%) had falling accidents. In 3 patients (13.0%), the treatment was delayed and performed after 24 hr. The baseline characteristics of both groups are detailed and compared in Table I. The median Injury Severity Score was 38 [27-55.5] in total with no statistical differences between the 2 groups.

Population Procedural Characteristics

The mean aortic diameter was 24.7 ± 4.9 mm in the total population, the anatomical details are described for each group in Table II. The Medtronic Valiant® stent graft was used in 86.7% (n ¼ 20) of cases, and the Gore C-Tag in 3 patients. For 4 patients (17.4%) a second endoprosthesis was necessary, in 2 cases because of a distal migration, one patient had a type I endoleak and one because of a crossing failure.

One patient had a rupture in zone 1 which required a triple transposition and a TEVAR in zone 0. Two patients had a TEVAR in zone 1 because of a proximal migration of the stent grafts. The first one was managed with a chimney technique for the left common carotid artery and the second by a carotid-carotid bypass. The mean operative time was 75.7 ± 35.1

min with no significant differences between the 2 groups. Overall technical success was 86.9%, with 90% for the PMEGs group, and 84.6% for the LSA coverage group.

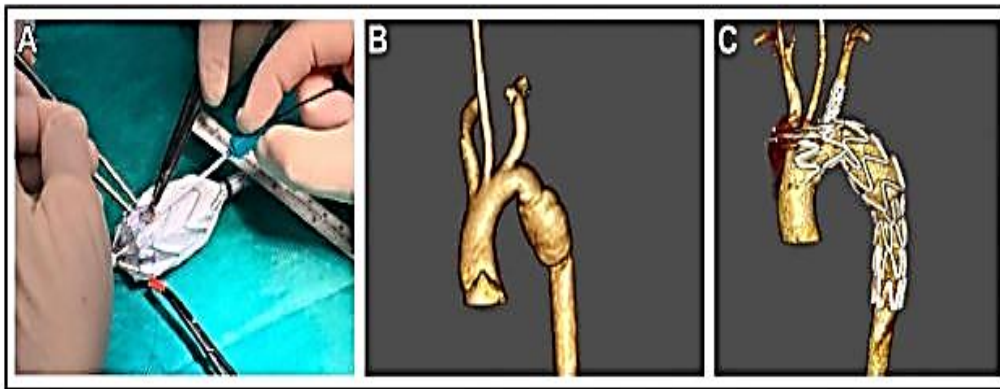


Fig. 2. Example of BTAI treated with PMEG. (A) Physician modified stent graft with customized fenestration, note the implementation of a radio opaque nitinol wire around the fenestration acting as a marker; (B) Blunt

aortic trauma in a 34 year old male with a distance LSA-rupture inferior to 20 mm; (C) Control CT showing an exclusion of the rupture and a perfect patency of the LSA.

LSA Management

A partial or total coverage of the LSA was realized in 25.8% (n ¼ 15) of the total population (n ¼ 58). Between the 2 groups, no statistical differences were found in terms of LSA transpositions (Table II). However, after 2017, no surgical transposition (n ¼ 0) and only one intentional coverage of the LSA (n ¼ 1) were observed (Fig. 1).

Clinical Outcomes

The 30-day mortality including in-hospital mortality rate was 4.3% (n ¼ 1), Table III. One patient had died after multiorgan dysfunction secondary to hemorrhagic shock due to grade IV kidney injury. Access site complication consisted of one patient with external iliac artery rupture that required open surgical repair. No early reintervention was needed.

PMEGs

The mean time for stent graft modification was 18 [14-27] minutes. Technical success was 80%, one patient had a type I endoleak requiring another endograft covering the LSA and a surgical transposition. Another patient presented a partial coverage of the LSA probably due to a rotation of the scallop. After 2017 and the realization of a fenestration instead of a scallop, the technical success was 100%. The rate of LSA stenting was 30% (n ¼ 3). No statistical difference was identified with regards to the operative time in the PMEGs group versus other procedures (P ¼ 0.1) (Table II). LSA occlusion was more frequent in the LSA coverage group (P < 0.01).

Follow-up

The median radiologic follow-up was 28 [10.5- 48.5] months for the total population and 12 [2.25-18.75] months for the PMEGs group. Among the PMEGs group, 70 % (n ¼ 7) had more than 1-year follow-up. No secondary endoleaks, migrations, dissections or other complications involving the aorta, the stent graft or the subclavian artery were observed. For 2 patients, no follow-up scan beyond 3 months was available. The primary patency of the LSA in the PMEGs group was 90% at 1 year and 28.8% in the LSA coverage group (P < 0.01) (Fig. 4).

One patient had a reintervention due to a late infection of the prosthetic carotid-carotid bypass which was managed by a saphenous replacement. Two patients presented with left arm symptoms secondary to the coverage of the LSA (n ¼ 2 [8.6%]) and declined a surgical intervention.

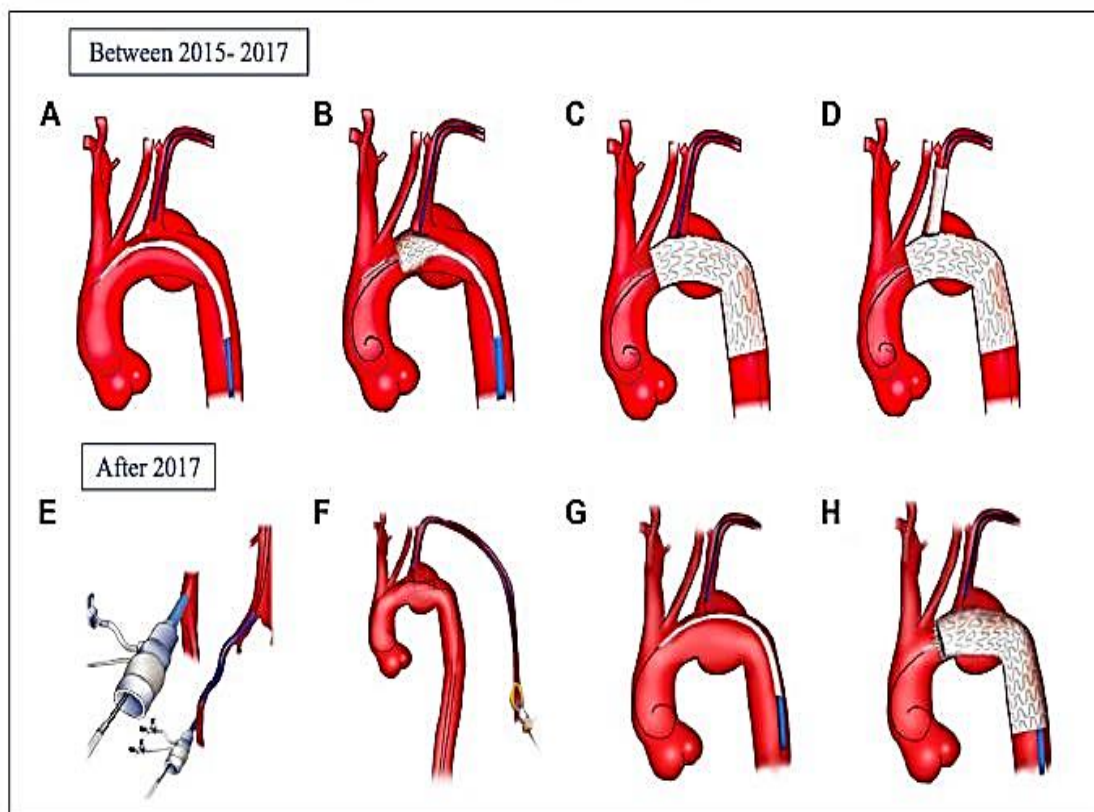


Fig. 3. Techniques of LSA catheterization with and without a preloaded wire. (A) Physician-modified stent graft with customized fenestration is positioned in zone 2 as well as a 7 Fr sheath in the LSA; (B) The stent graft is partially deployed and the fenestration catheterized; (C) The graft is completely deployed and the sheath is advanced into the ascending aorta allowing the placement of a covered stent; (D) Final result after balloon-

expandable covered stent deployment; (E) The preloaded wire is placed through the sheath, then the stent graft is advanced over a stiff wire; (F) A snare is placed through a brachial access to capture the preloaded guide wire; (G) The stent graft is advanced over the LSA ostium; (H) The stent graft is deployed and the sheath is advanced through the fenestration to deploy the covered stent with the same result as (D).

DISCUSSION

In this study comparing PMEGs to LSA coverage, there was no difference in mortality (P $\frac{1}{4}$ 0.4) and no significant differences in operative time (70 [60-112] minutes vs. 54.5 [48-68.5] minutes respectively, P $\frac{1}{4}$ 0.1). This demonstrates safety of this approach in these urgent situations. Despite the high Injury Severity Score of our population, this study reports no aortic-related death (n $\frac{1}{4}$ 0) and only 4.3% (n/41) of all-cause mortality. The demographic characteristic of the study population as well as the mortality rate were similar to the literature. [2,4,8](#) Furthermore, no paraplegia, stroke, or retrograde dissection occurred. These findings will re-affirm the interest in minimally invasive treatment for this condition.

This report compared in a specific emergent situation, where no “off the shelf” devices are available. Patients who required a zone 2 deployment were studied in order to have the most comparable groups of patients. Principal demographic characteristics were not significantly different, except for hypertension which could be explained by the older population of the PMEGs group or by a type 2 statistical error. Operative time was lower in the PMEGs group due to the lower rate of subclavian artery transposition and the higher rate of percutaneous access.

Studies have shown that intentional coverage of the LSA is safe and feasible.[14-17](#) They reported more than 94% freedom from revascularization at 2 years.[17](#) In the present study, one patient presented with vertigo without left arm symptoms and the other one left arm claudication but declined a surgical revascularization due to the limited impact on his quality of life. Other studies[2,4,16,17](#) have reported severe left arm claudication as a result of coverage with 68% having moderate to severe claudication immediately postoperation, and 4% acute ischemia. Coverage of the LSA may also preclude the possibility of coronary bypass with the left internal mammary artery. In addition, data reporting the long-term impact of the LSA coverage are lacking.[17](#)

Surgical revascularizations have inherent risks such as injury to the brachial plexus, the phrenic and the recurrent nerve as well as the thoracic duct. Moreover, this surgery is often compromised by cervical lesions and neck immobilization. In our study, direct transpositions of the LSA to the left common carotid through a longitudinal cervicotomy were performed with no complications observed.

Potential benefits of LSA revascularization are debated, but we believe that a revascularization should always be preferred. Even though an emergent TEVAR with coverage of the LSA is without question recommended for critically ill patient, these situations remain fortunately rare. Using the PMEGs technic or landing in zone 3 when possible, may avoid unnecessary LSA occlusion that may be critical for patients with traumatic brain injuries or spinal cord injuries. Moreover, the 2 technics are minimally invasive with a low rate of complications and can be performed under local anesthesia. When a revascularization is required, time to realize this procedure is reduced compared to a surgical transposition.

Table 1. Baseline characteristics of the total population

Baseline characteristics	Total <i>n</i> = 23	LSA coverage <i>n</i> = 13	PMEG <i>n</i> = 10	<i>P</i>
Age, median (IQR 25–75)	48 [31–64.5]	47 [29–55]	56.5 [44.5–69]	0.1
Male sex, <i>n</i> (%)	18 (78.2)	10 (76.8)	8 (80.0)	0.8
BTAI grade, <i>n</i> (%)				
Grade 2	6 (26)	2 (15.4)	4 (40.0)	0.2
Grade 3	15 (65.2)	9 (69.2)	6 (60.0)	
Grade 4	2 (8.6)	2 (15.4)	0 (0.0)	
Injury Severity score, median (IQR 25–75)	38 [27–55.5]	42 [30–54]	28 [26.2–51.2]	0.3
Hypertension, <i>n</i> (%)	5 (21.7)	0 (0.0)	5 (50.0)	<0.01
Dyslipidemia, <i>n</i> (%)	1 (4.3)	1 (7.7)	0 (0.0)	0.4
Diabetes, <i>n</i> (%)	0 (0.0)	0 (0.0)	0 (0.0)	-
COPD, <i>n</i> (%)	0 (0.0)	0 (0.0)	0 (0.0)	-
Renal insufficiency, <i>n</i> (%)	2 (8.6)	1 (7.7)	1 (10.0)	0.8
CAD, <i>n</i> (%)	2 (8.6)	0 (0.0)	2 (20.0)	0.2
Smoking, <i>n</i> (%)	7 (30.4)	3 (23.1)	4 (40.0)	0.4
ASA, median (IQR 25–75)	2 [2–3]	3 [2–3]	2 [2–3]	0.4
Mechanism of injury, <i>n</i> (%)				
Road accident	20 (86.9)	12 (92.3)	8 (80.0)	0.2
Fall	2 (8.6)	0 (0.0)	2 (20.0)	
Penetrating	1 (4.3)	1 (7.7)	0 (0.0)	
Delay < 24 hr (hr), <i>n</i> (%)	20 (86.9)	10 (76.9)	10 (100)	0.2
Hemodynamic shock, <i>n</i> (%)	9 (39.1)	6 (46.2)	3 (30.0)	0.4
Associated trauma, <i>n</i> (%)				
Head injuries	5 (21.7)	2 (15.4)	3 (30.0)	0.6
Bones fractures	18 (78.2)	11 (84.6)	7 (70.0)	0.6
Visceral injuries	14 (60.8)	7 (53.8)	7 (70.0)	0.7

ASA, American Society of Anesthesiologists; COPD, chronic obstructive pulmonary diseases; CAD, coronary artery diseases; IQR, interquartile range.

Our experience with PMEGs was progressive, and after using scallop a shift to fenestrated PMEGs was made. We preferred this technique due to its reproducibility for other urgent indications as well as its accuracy. Indeed, the stenting of the LSA ensures the position of the graft, increases the sealing, and avoids future migration. Catheterization of the fenestrated target was 100% in this series of patients, but we observed 3 failures of cannulation in the rest of our experience.¹³ Those events led us to add a preloaded guide wire through the LSA fenestration, first in a benchtop model,¹² then in clinical practice.¹³ This technique ensures the catheterization of the fenestration, increases the speed of the procedure, and decreases the stress of the surgeon, in these particularly stressful situations. No systematic stenting was realized at the beginning of our fenestrated experience. However, an angioplasty was systematically realized to ensure the positioning of the fenestration, in order to avoid any unnecessary stenting in this young population. The authors believe that late endoleaks are rare after the healing process of the aorta especially if no doubt exists in the postoperative CT scan. One patient had a stenting through a percutaneous radial access which realized a true total percutaneous fenestrated TEVAR and may offer an even less invasive procedure to the patient.

Table II. Perioperative characteristic of the total population

Perioperative characteristic	LSA coverage <i>n</i> = 13	PMEG <i>n</i> = 10	<i>P</i>
Proximal aortic diameter (mm), median (IQR 25–75)	23 [20–25]	24 [20–26.7]	0.03
Distal aortic diameter (mm), median (IQR 25–75)	20 [18–24]	22 [18–24]	0.2
Endograft			
Diameter (mm), median (IQR 25–75)	26 [26–31]	30 [30–30]	0.03
Length (mm), median (IQR 25–75)	110 [100–132]	150 [100–156]	0.4
Proximal oversizing (%), median (IQR 25–75)	14.8 [8.3–23.7]	16.3 [8.4–22.8]	0.04
LSA coverage			
Complete, <i>n</i> (%)	11 (84.6)	1 (10.0)	0.01
Partial, <i>n</i> (%)	2 (15.4)	1 (10.0)	1
LSA Transposition, <i>n</i> (%)	4 (30.8)	1 (10.0)	0.2
Operative time (min), median (IQR 25–75)	70 [60–112]	54.5 [48.5–68.5]	0.1
Contrast (mL), median (IQR 25–75)	60 [45–60]	60 [40–60]	0.6

Table III. General outcomes of the total population

Outcomes	LSA coverage <i>n</i> = 13	PMEG <i>n</i> = 10	<i>P</i>
Other type of surgery <i>n</i> (%)	8 (61.5)	3 (30)	0.2
Length of stay (days), median (IQR 25–75)			
ICU	16 [7–30]	11 [5–28]	0.8
Total	20 [11–34]	14 [7–35.5]	0.7
Stroke, <i>n</i> (%)	0 (0)	0 (0)	-
Paraplegia, <i>n</i> (%)	0 (0)	0 (0)	-
Retrograde dissection, <i>n</i> (%)	0 (0)	0 (0)	-
Pneumopathy, <i>n</i> (%)	3 (23.1)	0 (0)	0.8
Tracheotomy, <i>n</i> (%)	0 (0)	0 (0)	0.3
Pulmonary embolism, <i>n</i> (%)	0 (0)	0 (0)	-
Myocardial infarction, <i>n</i> (%)	0 (0)	0 (0)	-
Access complications, <i>n</i> (%)	1 (7.7)	0 (0)	0.3
30 days mortality, <i>n</i> (%)	0 (0)	1 (10)	0.4
Follow-up (months), median (IQR 25–75)	37 [21–42]	12 [2.25–18.75]	0.04
Left arm ischemia, <i>n</i> (%)	2 (15.3)	0 (0)	0.5
Reinterventions, <i>n</i> (%)	0 (0)	0 (0)	-

Laser fenestrations are also an attractive solution in this indication.^{18,19} This technique allows a rapid access through the target vessel. However, some concerns have been made about the long-term results.²⁰ The cost and the availability of the laser device may be taken into consideration.

The use of “off-the-shelf” branch devices-Valiant Mona LSA (Medtronic, Santa Rosa, Calif) and the Gore single-side branch (W.L. Gore & Associates, Inc.; Flagstaff, Ariz) consists of a main stent graft with one side branch designed to maintain patency of one of the supra-aortic trunks. Besho et al. described the successful management of 2 cases with the Gore single-side branch devices.²¹ This approach allows preservation of LSA patency during emergent TEVAR. However, these devices are not currently available on the market; moreover, a distance of 2 centimeter is required between the LSA and the left common carotid artery.

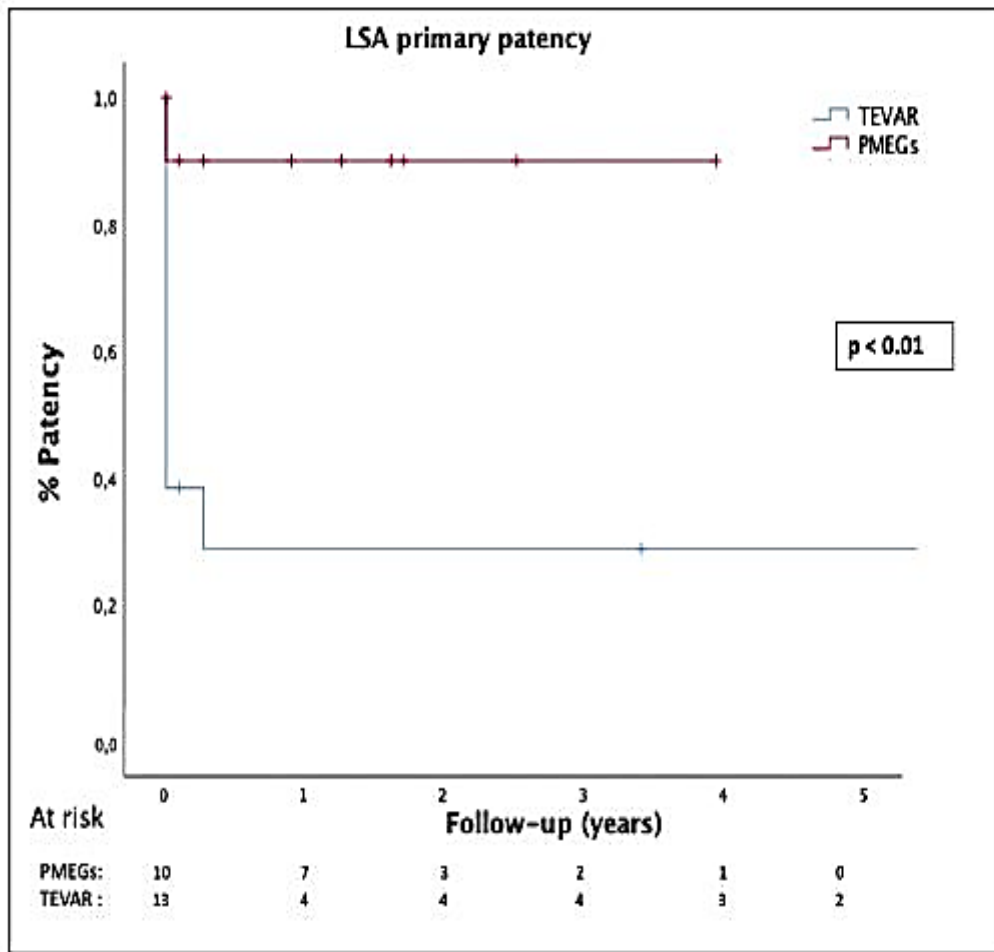


Fig. 4. Kaplan–Meier curve of primary patency of the LSA in case of zone 2 landing.

Limitations

This study is limited by the retrospective analysis as well as the low number of patients. This low number may induce statistical type II errors as well as a lack of statistical power. However, this study is the first in the literature to assess the performance of PMEGs in BTAI. The durability of physician modified stent grafts remains a concern, especially in this young population. Fatigability testing is ongoing. Although the modification of the stent graft by the physician requires some time, the PMEGs can be prepared on a back table as the patient is being readied for the procedure. Modification of commercially available devices by physicians may void any guarantee of safety by the manufacturer, and the systematic evaluation of such devices is better done within a protocol approved at the institutional and/or regulatory level. In the long-term, more data are required to confirm the applicability of this approach and to establish durability because of the potential for stent collapse or stent breakage.

CONCLUSIONS

The use of PMEGs in zone 2 is feasible and effective for the management of a short proximal landing zone in BTAI. This technique can ensure the permeability of the LSA without lengthening the operative time and avoids an additional surgical procedure. Further evaluations concerning the long-term results in this specific young population are still pending.

REFERENCES

1. Clancy TV, Gary Maxwell J, Covington DL, et al. A statewide analysis of level I and II trauma centers for patients with major injuries. *J Trauma* 2001;51:346-51.
2. Murad MH, Rizvi AZ, Malgor R, et al. Comparative effectiveness of the treatments for thoracic aortic transection [corrected]. *J Vasc Surg* 2011;53:193-199.-1-21.
3. Canaud L, Alric P, Branchereau P, et al. Open versus endovascular repair for patients with acute traumatic rupture of the thoracic aorta. *J Thorac Cardiovasc Surg* 2011;142: 1032-7.
4. Lee WA, Matsumura JS, Mitchell RS, et al. Endovascular repair of traumatic thoracic aortic injury: clinical practice guidelines of the Society for Vascular Surgery. *J Vasc Surg* 2011;53:187-92.
5. Mohapatra A, Liang NL, Makaroun MS, et al. Risk factors for mortality after endovascular repair for blunt thoracic aortic injury. *J Vasc Surg* 2020;71:768-73.
6. Martinelli O, Malaj A, Gossetti B, et al. Outcomes in the emergency endovascular repair of blunt thoracic aortic injuries. *J Vasc Surg* 2013;58:832-5.
7. Canaud L, Joyeux F, Berthet J-P, et al. Impact of stent-graft development on outcome of endovascular repair of acute traumatic transection of the thoracic aorta. *J Endovasc Ther* 2011;18:485-90.
8. Rizvi AZ, Murad MH, Fairman RM, et al. The effect of left subclavian artery coverage on morbidity and mortality in patients undergoing endovascular thoracic aortic interventions: a systematic review and meta-analysis. *J Vasc Surg* 2009;50:1159-69.
9. Riambau V, B€ockler D, Brunkwall J, et al. Editor's choice e management of descending thoracic aorta diseases: clinical practice guidelines of the European society for vascular surgery (ESVS). *Eur J Vasc Endovasc Surg* 2017;53:4-52.
10. Canaud L, Gandet T, Khantaline I, et al. Homemade proximal scalloped stent graft for thoracic endovascular aortic repair of zone 2 acute aortic syndrome. *J Thorac Cardiovasc Surg* 2016;152:1301-6.

11. Chassin-Trubert L, Mandelli M, Ozdemir BA, et al. Midterm follow-up of fenestrated and scalloped physician-modified endovascular grafts for zone 2 TEVAR. *J Endovasc Ther* 2020;27:377-84.
12. Lounes Y, Chassin-Trubert L, Gandet T, et al. Endovascular aortic arch repair with a pre-cannulated double-fenestrated physician-modified stent graft: a benchtop experiment. *Interact Cardiovasc Thorac Surg* 2021;32:942-9.
13. Chassin-Trubert L, Gandet T, Lounes Y, et al. Double fenestrated physician-modified stent-grafts for total aortic arch repair in 50 patients. *J Vasc Surg* 2020;73: 1898e1905.-1.
14. Romagnoli AN, Zeeshan M, Joseph B, et al. Utilization of endovascular and open surgical repair in the United States: a 10-year analysis of the National Trauma Databank (NTDB). *Am J Surg* 2019;218:1128-33.
15. Canaud L, Marty-An_e C, Ziza V, et al. Minimum 10-year follow-up of endovascular repair for acute traumatic transection of the thoracic aorta. *J Thorac Cardiovasc Surg* 2015;149:825-9.
16. McBride CL, Dubose JJ, Miller CC, et al. Intentional left subclavian artery coverage during thoracic endovascular aortic repair for traumatic aortic injury. *J Vasc Surg* 2015;61:73-9.
17. Antonello M, Menegolo M, Maturi C, et al. Intentional coverage of the left subclavian artery during endovascular repair of traumatic descending thoracic aortic transection. *J Vasc Surg* 2013;57:684e690.-1.
18. Redlinger RE, Ahanchi SS, Panneton JM. In situ laser fenestration during emergent thoracic endovascular aortic repair is an effective method for left subclavian artery revascularization. *J Vasc Surg* 2013;58:1171-7.
19. Li C, Xu P, Hua Z, et al. Early and midterm outcomes of in situ laser fenestration during thoracic endovascular aortic repair for acute and subacute aortic arch diseases and analysis of its complications. *J Vasc Surg* 2020;72:1524-33.
20. Jayet J, Heim F, Coggia M, et al. An experimental study of laser in situ fenestration of current aortic endografts. *Eur J Vasc Endovasc Surg* 2018;56:68-77.
21. Besho JM, Tanaka A, Al-Rstum Z, et al. Thoracic branched endograft for traumatic aortic pseudoaneurysm. *J Vasc Surg Cases Innov Tech* 2019;5:540-3.

Conflict of interest:

Professor Canaud is proctor for Medtronic. The other authors do not have any relevant disclosures.

Funding sources:

This research did not receive any specific grant from funding agencies in the public, commercial, or not-for-profit sectors.