



HAL
open science

Percutaneous surgery with balloon for tibial plateau fractures, results with a minimum of 5 years of follow-up

Tanguy Vendevre, Victor Ferrière, Pierre Bouget, Maxime Billot, Arnaud Germaneau, Mathieu Severyns, Manuel Roulaud, Philippe Rigoard, Pierre Pries

► To cite this version:

Tanguy Vendevre, Victor Ferrière, Pierre Bouget, Maxime Billot, Arnaud Germaneau, et al.. Percutaneous surgery with balloon for tibial plateau fractures, results with a minimum of 5 years of follow-up. *Injury*, 2022, 53 (7), pp.2650-2656. 10.1016/j.injury.2022.05.033 . hal-03820556

HAL Id: hal-03820556

<https://hal.science/hal-03820556v1>

Submitted on 22 Jul 2024

HAL is a multi-disciplinary open access archive for the deposit and dissemination of scientific research documents, whether they are published or not. The documents may come from teaching and research institutions in France or abroad, or from public or private research centers.

L'archive ouverte pluridisciplinaire **HAL**, est destinée au dépôt et à la diffusion de documents scientifiques de niveau recherche, publiés ou non, émanant des établissements d'enseignement et de recherche français ou étrangers, des laboratoires publics ou privés.



Distributed under a Creative Commons Attribution - NonCommercial 4.0 International License

Percutaneous surgery with balloon for tibial plateau fractures, results with a minimum of 5 years of follow-up.

Author names and affiliations: Tanguy Vendevre^{*a,c}, Victor Ferrière^{*a}, Pierre Bouget^a, Maxime Billot^b, Arnaud Germaneau^b, Mathieu Severyns^c, Manuel Roulaud^b, Philippe Rigoard^b, Pierre Pries^a

^a : CHU de Poitiers, 2 rue de la Milétrie, Service d'Orthopédie-Traumatologie, 86021 Poitiers, France

^b : CHU de Poitiers, 2 rue de la Milétrie, PRISMATICS (Predictive Research in Spine/Neuromodulation Management and Thoracic Innovation/Cardiac Surgery), 86021 Poitiers, France

^c : Institut Pprime UPR 3346, CNRS – Université de Poitiers – ISAE-ENSMA, France

Corresponding author : Victor Ferrière (victor.ferriere@outlook.fr)

Contact : tanguy.vendevre@chu-poitiers.fr, victor.ferriere@outlook.fr, pierre.bouget@chu-poitiers.fr, maxime.billot@chu-poitiers.fr, arnaud.germaneau@univ-poitiers.fr, mathieu.severyns@hotmail.fr, manuel.roulaud@chu-poitiers.fr, philippe.rigoard@chu-poitiers.fr, pierre.pries@chu-poitiers.fr

Abstract

Tibial plateau fracture is a frequent entity for which surgical management is difficult both surgically and postoperatively, with multiple complications and often delayed recovery. The challenge lies in the anatomical reduction of the joint, the limitation of complications and the rapid functional recovery. Tuberoplasty appears to be an innovative technique that meets current expectations.

The objective is to evaluate the reliability of tuberoplasty in reducing surgical risks and improving postoperative clinical results.

This single-centre retrospective study included 30 patients with depressed tibial plateau fractures who underwent tuberoplasty from September 2011 to March 2014. Reduction analysis was performed by comparing pre-operative and post-operative depression from computed tomography (CT) data. Clinical outcomes were assessed by measuring flexion joint ranges, time to weight-bearing, KOOS questionnaire and a pangonogram.

The mean depression was 7.4mm pre-operatively and 2.6mm [0;9] post-operatively, with 47% (14/30) having a residual depression of 2mm or less. Mean flexion at 6 weeks was 103° [30; 130]. Partial and total weight-bearing were allowed on day 47 [3; 150] and day 58 [20; 150], respectively. The mean KOOS score was 25.43 [1.15; 62.30] at a minimum of 5 years after surgery and the mean axis was 176.54° [172; 180]. There was one case of thrombophlebitis and one sensory-motor deficit in the common fibular nerve territory.

The reduction of the tibial plateau observed in our study from tuberoplasty is in line with the literature results obtained from a conventional approach. Our results indicate that tuberoplasty is stable in the long term, has good functional results and early recovery with few complications. This preliminary study presents results that need to be investigated in a prospective randomised double-blind study.

Keywords

Tuberoplasty, tibial plateau fracture, tibial plateau depression, Schatzker, arthroscopy.

Highlights

Tuberoplasty allows percutaneous reduction of tibial plateau depressions.

Filling with PMMA with osteosynthesis allows early rehabilitation and weight-bearing recovery.

Arthroscopy allows control of the reduction and treatment of associated lesions.

Introduction

External tibial plateau surgeries of fractures with pure depression or associated with a separation represent 50% of tibial plateau fractures (1,2). This type of fracture is relatively frequent with 11212 fractures in 2019 in France, of which 5129 were treated surgically (PMSI data). In addition to reducing the fracture, the post-intervention objective is to regain at least partial weight-bearing as soon as possible and thereby allow a return to activity, limiting early arthritic degeneration and the associated high socio-economic cost (3,4). The clinical results depend on, the reduction, which must be as anatomical as possible (residual depression < 2mm) (5-7), and the stability of the osteosynthesis. Conventional open reduction or with bone impactor is associated with risks of bone devascularisation, infection, or skin necrosis (8) and delayed functional recovery with a return to weight-bearing in 6-8 weeks.

Tuberoplasty has recently been developed based on experimental simulations (9,10). This minimally invasive percutaneous surgery, inspired by kyphoplasty, consists of balloon-assisted elevation of the tibial plateau combined with filling and osteosynthesis (11). While this approach appears promising as a means of improving access to posterior depressions, achieving primary stability through cementing, possibly enabling arthroscopy and reducing skin risk (12), no clinical data are currently available in the literature.

The aim of our study is to determine the quality of reduction and stability of the osteosynthesis following tuberoplasty with a minimum follow-up of 5 years. Joint range of motion, time to partial and full weight-bearing, possible complications, and operating time (with and without arthroscopic time) were considered as secondary endpoints.

Patients et methods

Design

Single-arm retrospective study conducted at Poitiers University Hospital in patients with a tibial plateau fracture between September 2011 and March 2014 (CHU86-RECH-R2020-03-02).

Patients

The inclusion criteria were tibial plateau fracture with a depressed component diagnosed by CT scan. Fractures older than 10 days or with skin wound and pregnant women were excluded.

Surgical technique

The patients were placed on an orthopaedic table with traction in the axis, and the one-centimetre incision was guided under scopic control in front of the anterolateral part of the tibial metaphysis below the depression.

The anterior cortex was trepanned above the incision using a Jamshidi trocar, through which a tap and then a balloon (Kyphon, Medtronic, Dublin, Ireland) were successively introduced under fluoroscopic control from the face and profile below the depression. The balloon was inflated progressively until the fracture was reduced.

Regarding osteosynthesis, 23 patients had only 1 to 3 Asnis screws diameter 4, 6.5 and 8mm (Stryker, Kalamazoo, Michigan, USA), 5 patients had a percutaneous NCB plate (Zimmer Biomet, Warsaw, Indiana, USA) with polyaxial locked screws.

The cement was then placed in place of the removed balloon , in 28 patients with PMMA and 2 patients (aged 17 and 23 years) with phosphocalcic cement (Kyphose FS Kyphon Inc,

Medtronic, Dublin, Ireland, Biomet PMA and Calcibon, Zimmer Biomet, Warsaw, Indiana, USA).

Monitoring and evaluation

Primary endpoint

Pre- and post-operative tibial depression were compared using a computed tomography (CT) scan (McKesson Radiology, McKesson, Irving, Texas, USA). Measurements were taken at maximum depression.

Secondary endpoints

The secondary endpoints were (i) measurement of joint range of motion by the surgeon at 6 weeks post-op with a goniometer, (ii) time to partial and total weight-bearing resumption authorised by the surgeon after analysis of frontal and lateral knee radiographs, and (iii) radiographic (HKA angle) and clinical evaluation of the patient in the long term (5-8 years post-op) by EOS® imaging and the KOOS questionnaire.

Statistical analysis

The data were integrated and then analysed using an Excel spreadsheet and the Wilcoxon test (BiostaTGV, iPLesp, Paris, France). Calculations were made for each KOOS sub-chapter and then on the overall score. They are presented as a mean with extremes and standard deviation. The significance level used is $p < 0.05$.

Results

Thirty patients (14 women, 48.6 years [17; 78]) were included in the study. According to the Schatzker classification, there were 15 type II, 7 type III, 3 type IV, 3 type V and 2 type VI.

Nine patients had an arthroscopic procedure, two had an external meniscal lesion.

Measurements of depression, operative times, flexion range of motion, weight-bearing recovery, KOOS score, HKA and complications are presented in Tables 1 and 2.

Our results indicate a significant reduction in preoperative depression $7.4\text{mm} \pm 4.6$ [3; 18] vs. postoperative depression $2.6\text{mm} \pm 2.5$ [0; 9] ($p < 0.001$).

The material was removed in 10 patients due to discomfort, 2 patients underwent arthroscopy for meniscal lesions at the same time, and one patient underwent knee mobilisation under general anaesthesia.

There were no cases of infection, compartment syndrome, skin necrosis, pseudoarthrosis or revision surgery.

Discussion

The development of osteoarthritis is conditioned by the residual depression, type of fracture, the stability of the fixation and post-operative complications, including infection (13). This study suggests that tuberoasty is a reliable technique that allows good reduction of the depression while preserving metaphyseal vascularity with few intra- and post-operative complications (figures 1 and 2). The approach to posterior depressions could be performed by anterior approach without difficulty (figures 3, 4 and 5), and arthroscopy can be associated during the reduction phase or afterwards to check both the reduction and the associated meniscal injuries.

From a mean depression of 7.4mm, our CT results indicate that tuberoasty resulted in a mean tibial plateau reduction of 4.8mm ($p < 0.001$). Out of the 30 patients, 21 had a residual depression of less than or equal to 5mm, which is considered acceptable (14), 14 were less than or equal to 2mm, and 7 had an anatomical reduction. It is currently accepted that a depression of more than 2mm is a source of early osteoarthritis (5-7,13,15). In the literature, using plain radiographs at two angles of view, Simpson and Keating (16) achieved reduction with depression of less than 2mm in 13/26 patients with open osteosynthesis and phosphocalcic cement filling. In contrast, using the conventional technique, Mardian et al (17) achieved 84/96 of less than 1mm depression.

The 9 arthroscopies performed revealed 2 external meniscus injuries, one of which was successfully corrected. Arthroscopy also allowed the reduction and intra-articular cement leakage to be checked. In their arthroscopic study of 36 patients, Vangness et al (18) diagnosed 47% (17/36) of associated meniscal lesions in all fracture types. Intraoperative arthroscopic monitoring allows treatment of associated meniscal lesions and assists in reduction by releasing soft tissue from the fracture site.

Operating times are short, from 25 to 89 minutes with an average of 53 minutes without arthroscopic time; arthroscopy adds an average 20 minutes of operating time. Short operating times favour post-anaesthetic effects (19) and make spinal and locoregional anaesthesia easier.

Regarding complications, we noted intra-articular cement leakage in 3 patients, one of which was seen during the arthroscopic procedure. These leaks had no clinical repercussions except in one patient, who required removal of the intra-articular fragment under arthroscopy.

Thrombophlebitis also occurred in a patient with no risk factors. He was treated with effective anticoagulation for 3 months with complete resorption of the clot. A deficit of the common fibular nerve was diagnosed postoperatively in a patient already showing signs of distal neuropathy due to hepato-cellular insufficiency. One year after the operation, we observed two secondary displacements (6%), one in a patient with a posterior recess osteosynthesised by a screw and one in a patient with a fracture in the frontal plane stabilised by two screws, one of which was anteroposterior. Simpson and Keating (16) found 42% (11/26) of patients with secondary compression at 1 year, while Jansen et al. reported 22.7% (5/22) (20). Ten patients required removal of the osteosynthesis material, 8 complained of discomfort with the screw heads and 2 were routinely performed during arthroscopy for meniscal injuries. In the study by Dreumel et al (21), 41.6% (40/96) of patients had the material removed. No mounting instability was recorded. Only one patient underwent knee mobilisation under general anaesthesia 2 months after surgery to accelerate rehabilitation, active and passive flexion mobilisation was limited to 80°. Compared to the literature on conventional surgery, we had fewer complications. No infections or skin necrosis were noted, in comparison Mardian found 6% (6/101) of infections (17), Van Dreumel found 2% (2/96) (21) and Jansen reported 17% (4/22) (20). No compartment syndrome, no cases of pseudoarthrosis or revision surgery with arthroplasty. In the literature, Van Dreumel found 2% (2/96) compartment

syndrome, 7.3% (7/96) revision surgery for arthroplasty (21), Jansen found 4.5% compartment syndrome (1/22) and 17% (4/22) of pseudoarthrosis (20).

Twenty-eight patients were treated with PMMA to fill the bone defect. PMMA offers satisfactory strength for osteosynthesis of tibial plateau fractures (22). It is preferred over phosphocalcic in the latest spinal surgery study for its greater compressive strength (23). A post operative radiography of an osteosynthesis with two screws and cement is presented in figures 6 and 7 (face and profile), the result at 6 years in figure 8 (face). Wardlaw's randomised study shows the safety of cement in the short and long term in the consolidation of fractured bone (24). Its presence does not influence the stress distribution of the metaphyseal bone, integrating biomechanically in a transparent manner (25). Ideally, a resorbable cement should be used, which, together with the removal of screws, would leave no foreign material after consolidation.

Mean flexion at 6 weeks was 103° [30;130]. Eleven patients had flexion greater than 90°.

These results are compatible with an early return to activity, and subsequent rehabilitation has an important role to play in the recovery of flexion and the prevention of osteoarthritis in the long term (5). In the literature, Jansen obtained a mean flexion of 124.9° at a minimum of 3 years follow-up (20).

Partial and full weight-bearing are allowed on average at day 47 [3;150] and day 58 [20;150].

Other studies have shown prolonged discharge, 130 days for Sun in Schatzker II fractures with posterior column involvement (26), 84 days for Vasanad (27). These short times allowed early return to activity for a majority of patients.

The mean KOOS score is 25.43 [1.15 ;62.30] at least 5 years after the intervention. The choice of the KOOS questionnaire in this study was made due to its validity, universality and robustness (28-31). The heterogeneity observed by high standard deviation can be explained by the inclusion of elderly patients over 60 years of age who already had joint disease with

disabling pain. Our average of 25.43 is comparable to the literature. Van Dreumel found an average of 17.01 in his study at 6 years of open osteosynthesis in a population with an equivalent average age (21,32). When analysing the subgroups, we note a greater impact on sports and recreational activities, while the others are closer to the overall average. This trend is found in the literature (21,33). A difference of 10 points between several questionnaires is not significant according to Roos who suggested that older people tend to increase the differences in score for an equivalent clinical impact (34).

The average HKA axis was 176.54° [$172 ; 180$]. We did not find any angulation of more than 10° with an average of 3.5° . Few studies have investigated the change in this angle following a tibial plateau fracture. Siegler showed similar long-term axes varying from 0° to 6° in their reduction under arthroscopy with filling by allo- or autograft (32). Parkkinsen showed an unfavourable evolution as soon as the axial deviation exceeds 5° (14). There was no major axis difference except in 2 patients with axis inversion who were those with the highest KOOS scores, one of whom had a secondary displacement.

The main bias of this study is a lack of comparison with conventional surgery. The size of the cohort is explained by the low monocentric recruitment and the need for in vivo validation of this technique (35). The lack of data (joint range and measurement of residual depression) is related to the retrospective nature of the study. This preliminary study is a basis for defining the parameters and the feasibility of a randomised control study.

Conclusion

Tubero-plasty is an innovative technique giving results comparable to the literature and to other traditional techniques in the long term, and better results in the short and medium term, considerably reducing complications.

References

1. Kfuri M, Schatzker J. Revisiting the Schatzker classification of tibial plateau fractures. *Injury*. 2018 Dec;49(12):2252–63.
2. Gicquel T, Najihi N, Vendevre T, Teyssedou S, Gayet L-E, Hutten D. Tibial plateau fractures: reproducibility of three classifications (Schatzker, AO, Duparc) and a revised Duparc classification. *Orthop Traumatol Surg Res*. 2013 Nov;99(7):805–16.
3. Hohl M. Managing the challenges of tibial plateau fractures. *J Musculoskel Med*. 1991;
4. Volpin G, Dowd GS, Stein H, Bentley G. Degenerative arthritis after intra-articular fractures of the knee. Long-term results. *J Bone Joint Surg Br*. 1990 Jul;72(4):634–8.
5. Honkonen SE. Degenerative arthritis after tibial plateau fractures. *J Orthop Trauma*. 1995;9(4):273–7.
6. Giannoudis PV, Tzioupis C, Papathanassopoulos A, Obakponovwe O, Roberts C. Articular step-off and risk of post-traumatic osteoarthritis. Evidence today. *Injury*. 2010 Oct;41(10):986–95.
7. Prat-Fabregat S, Camacho-Carrasco P. Treatment strategy for tibial plateau fractures: an update. *EFORT Open Rev*. 2016 May;1(5):225–32.
8. Young MJ, Barrack RL. Complications of internal fixation of tibial plateau fractures. *Orthop Rev*. 1994 Feb;23(2):149–54.
9. Vendevre T, Babusiaux D, Brèque C, Khiami F, Steiger V, Merienne J-F, et al. Tubero-plasty: minimally invasive osteosynthesis technique for tibial plateau fractures. *Orthop Traumatol Surg Res*. 2013 Jun;99(4 Suppl):S267-272.
10. Vendevre T, Grunberg M, Germaneau A, Maloubier F, Faure J-P, Gayet L-E, et al. Contribution of minimally invasive bone augmentation to primary stabilization of the osteosynthesis of Schatzker type II tibial plateau fractures: Balloon vs bone tamp. *Clin Biomech (Bristol, Avon)*. 2018;59:27–33.
11. Belaid D, Germaneau A, Bouchoucha A, Brémand F, Brèque C, Rigoard P, et al. Finite element analysis of mechanical behavior of stabilization techniques for tibial plateau fractures. *Comput Methods Biomech Biomed Engin*. 2017 Oct;20(sup1):13–4.
12. Medium-term results of percutaneous, arthroscopically-assisted osteosynthesis of fractures of the tibial plateau. - PubMed - NCBI [Internet]. [cited 2020 Jan 23]. Available from: <https://www.ncbi.nlm.nih.gov/pubmed/9853485>
13. Manidakis N, Dosani A, Dimitriou R, Stengel D, Matthews S, Giannoudis P. Tibial plateau fractures: functional outcome and incidence of osteoarthritis in 125 cases. *Int Orthop*. 2010 Apr;34(4):565–70.
14. Parkkinen M, Madanat R, Mustonen A, Koskinen SK, Paavola M, Lindahl J. Factors predicting the development of early osteoarthritis following lateral tibial plateau

- fractures: mid-term clinical and radiographic outcomes of 73 operatively treated patients. *Scand J Surg*. 2014 Dec;103(4):256–62.
15. Lansinger O, Bergman B, Körner L, Andersson GB. Tibial condylar fractures. A twenty-year follow-up. *J Bone Joint Surg Am*. 1986 Jan;68(1):13–9.
 16. Simpson D, Keating JF. Outcome of tibial plateau fractures managed with calcium phosphate cement. *Injury*. 2004 Sep 1;35(9):913–8.
 17. Mardian S, Landmann F, Wichlas F, Haas NP, Schaser K-D, Schwabe P. Angular-stable locking plate fixation of tibial plateau fractures-clinical and radiological midterm results in 101 patients. *Indian Journal of Orthopaedics*. 2015 Jan 11;49(6):620.
 18. Vangsnæs CT, Ghaderi B, Hohl M, Moore TM. Arthroscopy of meniscal injuries with tibial plateau fractures. *J Bone Joint Surg Br*. 1994 May;76(3):488–90.
 19. Masson E. Risque et conséquences à court et à long terme de l’anesthésie [Internet]. EM-Consulte. [cited 2021 Feb 9]. Available from: <https://www.em-consulte.com/article/231232/risque-et-consequences-a-court-et-a-long-terme-de>
 20. Jansen H, Frey SP, Doht S, Fehske K, Meffert RH. Medium-term results after complex intra-articular fractures of the tibial plateau. *J Orthop Sci*. 2013 Jul;18(4):569–77.
 21. van Dreumel RLM, van Wunnik BPW, Janssen L, Simons PCG, Janzing HMJ. Mid- to long-term functional outcome after open reduction and internal fixation of tibial plateau fractures. *Injury*. 2015 Aug;46(8):1608–12.
 22. Belaid D, Vendevre T, Bouchoucha A, Brémand F, Brèque C, Rigoard P, et al. Utility of cement injection to stabilize split-depression tibial plateau fracture by minimally invasive methods: A finite element analysis. *Clin Biomech (Bristol, Avon)*. 2018;56:27–35.
 23. Teyssédou S, Saget M, Prébet R, Leclercq N, Vendevre T, Pries P. Evaluation of percutaneous surgery in the treatment of thoracolumbar fractures. Preliminary results of a prospective study on 65 patients. *Orthopaedics & Traumatology: Surgery & Research*. 2012 Feb 1;98(1):39–47.
 24. Wardlaw D, Cummings SR, Van Meirhaeghe J, Bastian L, Tillman JB, Ranstam J, et al. Efficacy and safety of balloon kyphoplasty compared with non-surgical care for vertebral compression fracture (FREE): a randomised controlled trial. *Lancet*. 2009 Mar 21;373(9668):1016–24.
 25. Aubert K, Germaneau A, Rochette M, Ye W, Severyns M, Billot M, et al. Development of Digital Twins to Optimize Trauma Surgery and Postoperative Management. A Case Study Focusing on Tibial Plateau Fracture. *Frontiers in Bioengineering and Biotechnology* [Internet]. 2021 [cited 2022 Mar 8];9. Available from: <https://www.frontiersin.org/article/10.3389/fbioe.2021.722275>
 26. Sun H, Zhai Q-L, Xu Y-F, Wang Y-K, Luo C-F, Zhang C-Q. Combined approaches for fixation of Schatzker type II tibial plateau fractures involving the posterolateral column: a prospective observational cohort study. *Arch Orthop Trauma Surg*. 2015 Feb;135(2):209–21.

27. Vasanad GH, Antin SM, Akkimaradi RC, Policepatil P, Naikawadi G. Surgical management of tibial plateau fractures - a clinical study. *J Clin Diagn Res.* 2013 Dec;7(12):3128–30.
28. Roos EM, Roos HP, Lohmander LS, Ekdahl C, Beynnon BD. Knee Injury and Osteoarthritis Outcome Score (KOOS)--development of a self-administered outcome measure. *J Orthop Sports Phys Ther.* 1998 Aug;28(2):88–96.
29. Roos EM, Toksvig-Larsen S. Knee injury and Osteoarthritis Outcome Score (KOOS) - validation and comparison to the WOMAC in total knee replacement. *Health Qual Life Outcomes.* 2003 May 25;1:17.
30. Ornetti P, Parratte S, Gossec L, Tavernier C, Argenson J-N, Roos EM, et al. Cross-cultural adaptation and validation of the French version of the Knee injury and Osteoarthritis Outcome Score (KOOS) in knee osteoarthritis patients. *Osteoarthr Cartil.* 2008 Apr;16(4):423–8.
31. Roos EM, Roos HP, Ekdahl C, Lohmander LS. Knee injury and Osteoarthritis Outcome Score (KOOS) - validation of a Swedish version. *Scandinavian Journal of Medicine & Science in Sports.* 1998;8(6):439–48.
32. Siegler J, Galissier B, Marcheix P-S, Charissoux J-L, Mabit C, Arnaud J-P. Percutaneous fixation of tibial plateau fractures under arthroscopy: a medium term perspective. *Orthop Traumatol Surg Res.* 2011 Feb;97(1):44–50.
33. Singleton N, Sahakian V, Muir D. Outcome After Tibial Plateau Fracture: How Important Is Restoration of Articular Congruity? *J Orthop Trauma.* 2017 Mar;31(3):158–63.
34. Roos EM, Lohmander LS. The Knee injury and Osteoarthritis Outcome Score (KOOS): from joint injury to osteoarthritis. *Health Qual Life Outcomes.* 2003 Nov 3;1:64.
35. Vendeuvre T, Monlezun O, Brandet C, Ingrand P, Durand-Zaleski I, Gayet L-E, et al. Comparative evaluation of minimally invasive ‘tibial tubero-plasty’ surgical technique versus conventional open surgery for Schatzker II–III tibial plateau fractures: design of a multicentre, randomised, controlled and blinded trial (TUBERIMPACT study). *BMJ Open* [Internet]. 2019 Sep 3 [cited 2020 Jan 23];9(8). Available from: <https://www.ncbi.nlm.nih.gov/pmc/articles/PMC6731842/>

Figures 1 and 2: pre and post operative (5 days) CT scans in a 22-year-old patient with a Schatzker VI fracture and lateral depression

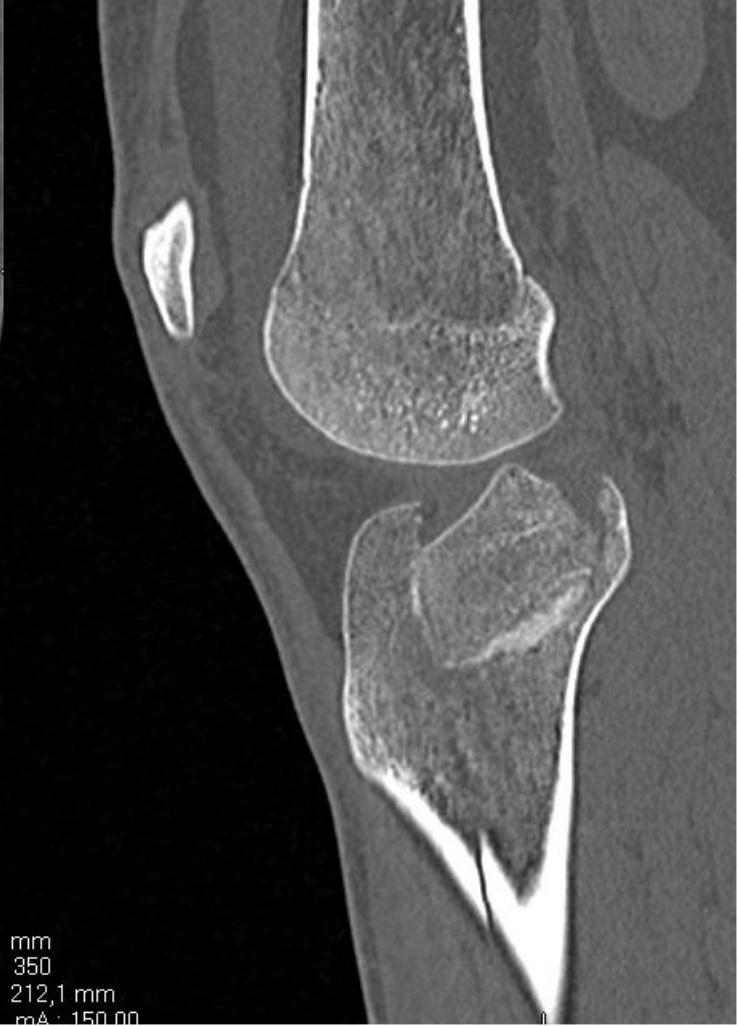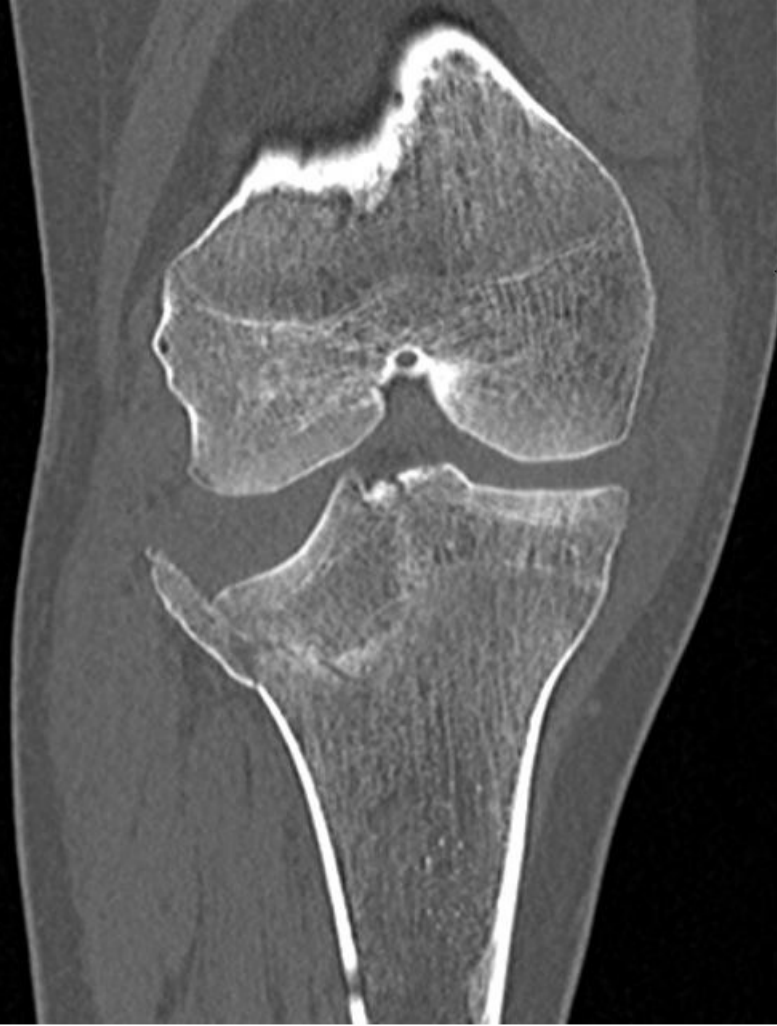Figures 3 and 4: pre and post operative (7 month) CT scans in a 64-year-old patient with a Schatzker VI fracture and posterior depression

Figure 5: post operative pangonogram at 5 years in the patient presented in figures 6 and 7. The HKA axis is 179° (varus)

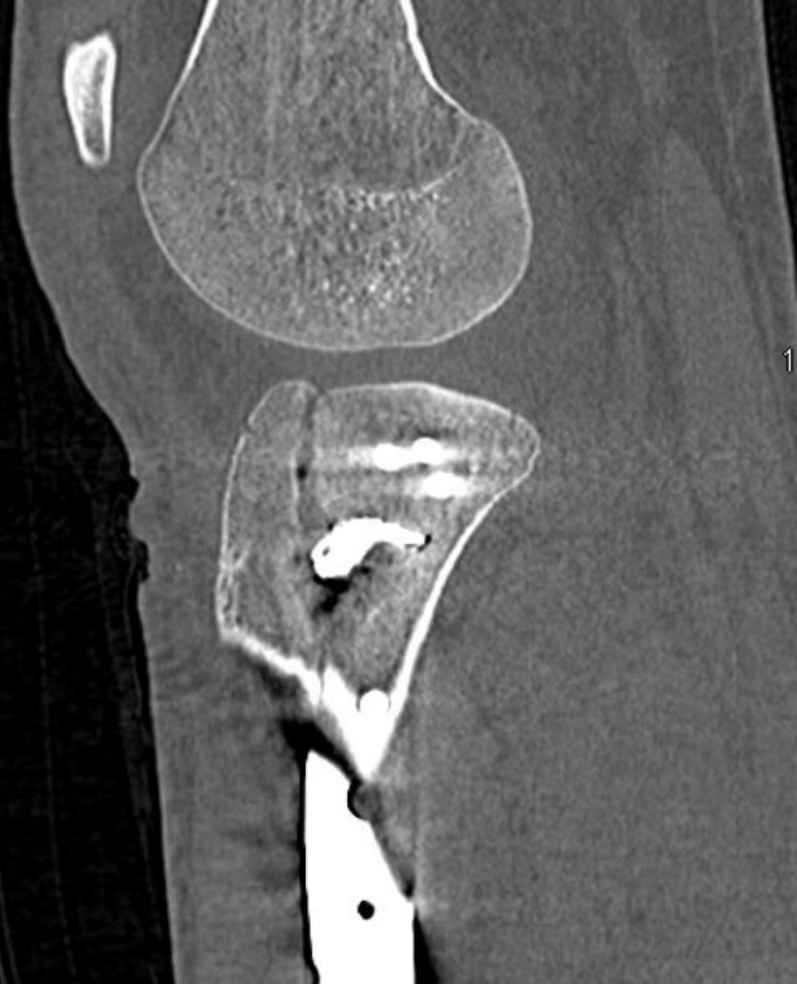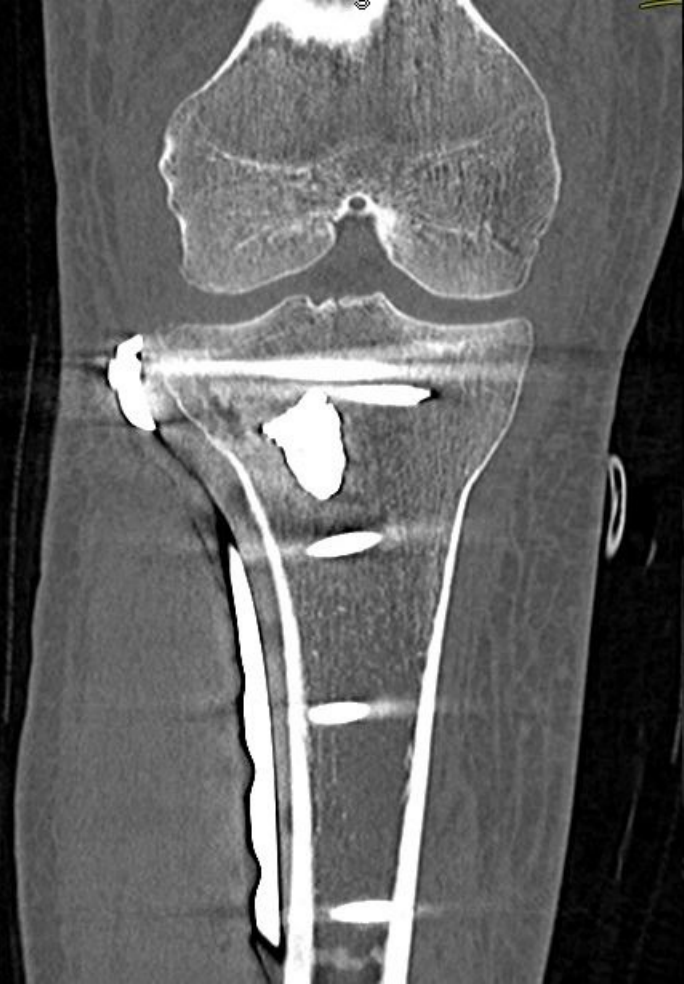Figure 6: immediate postoperative frontal radiograph

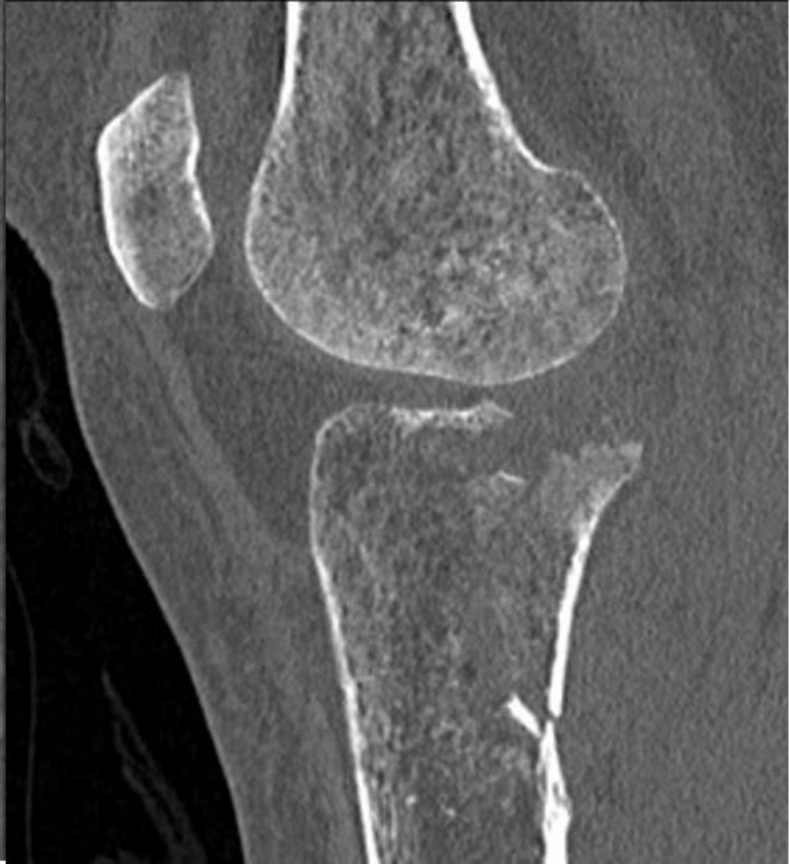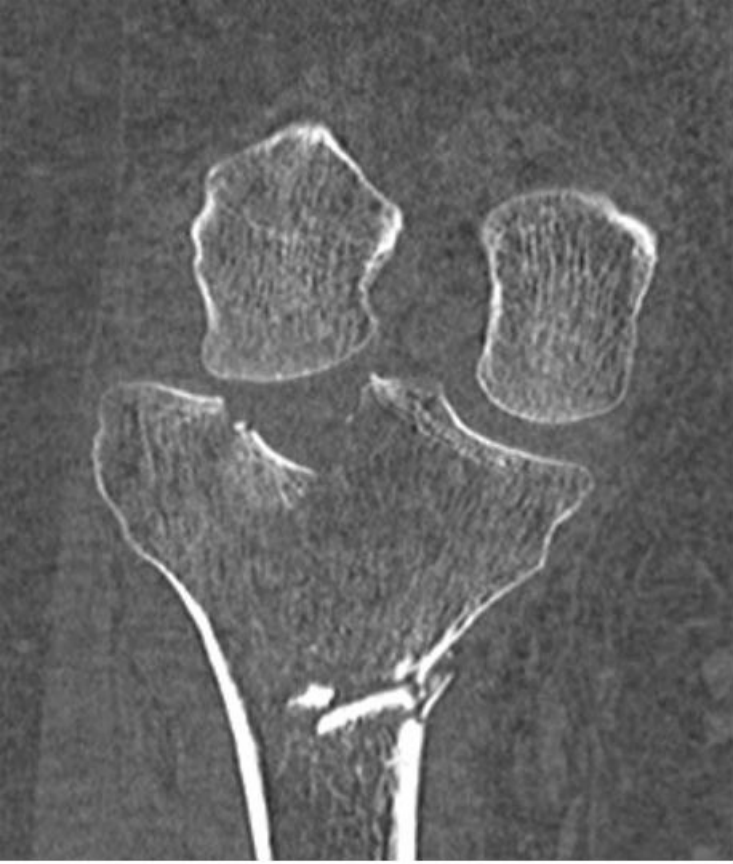Figure 7: immediate postoperative lateral radiograph

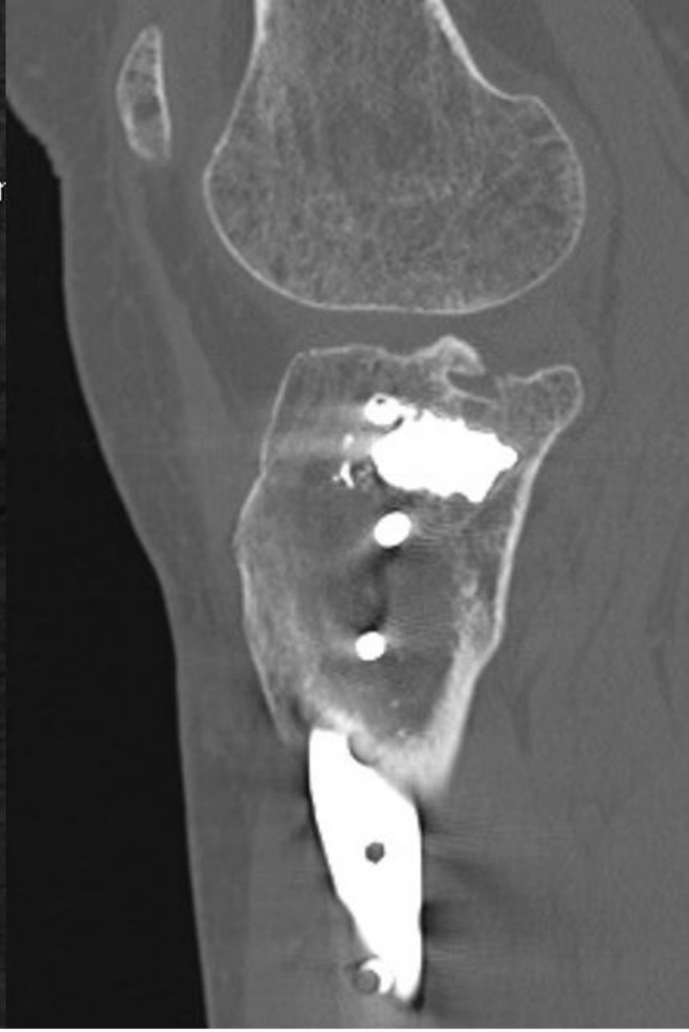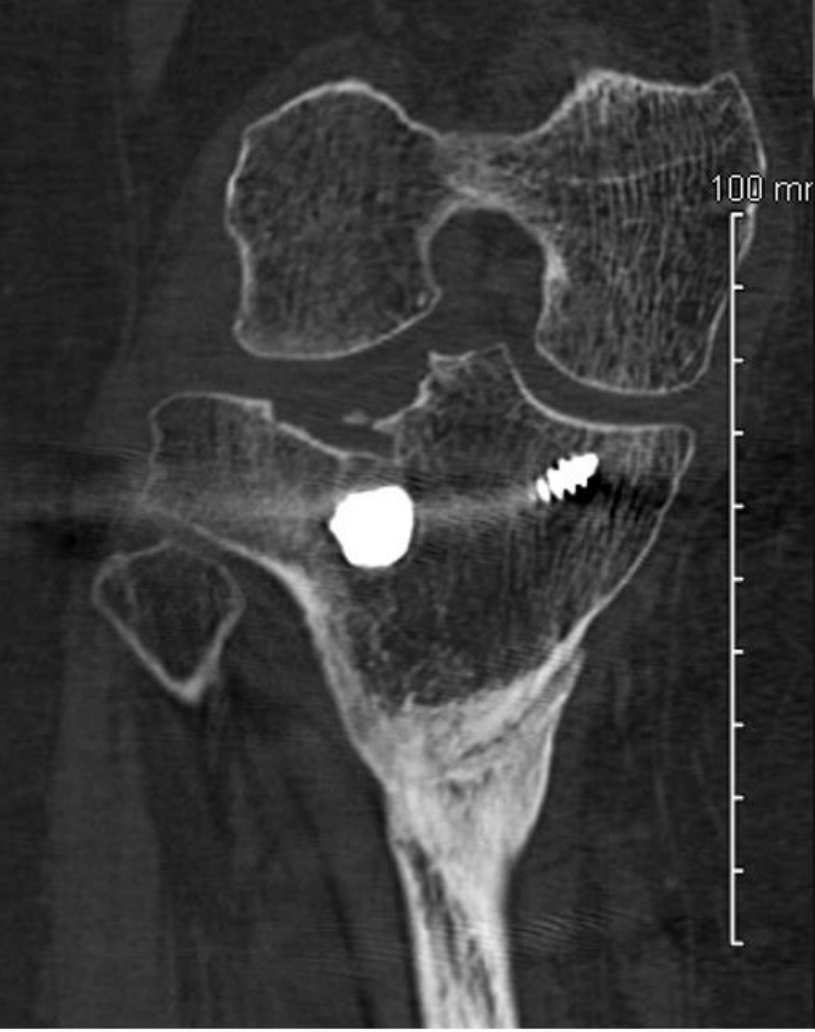Figure 8: 6 years old post operative frontal radiograph

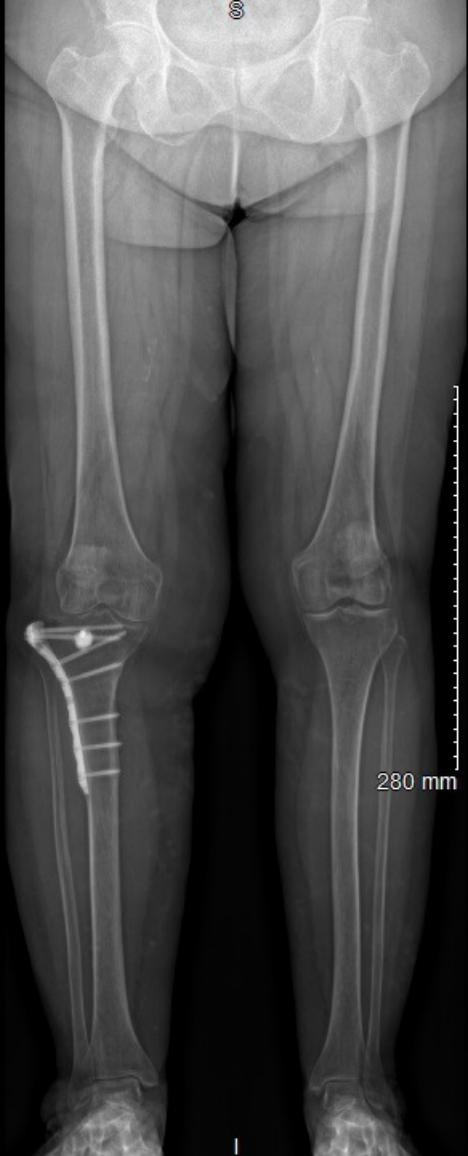

mm
350
212,1 mm
mA: 150.00



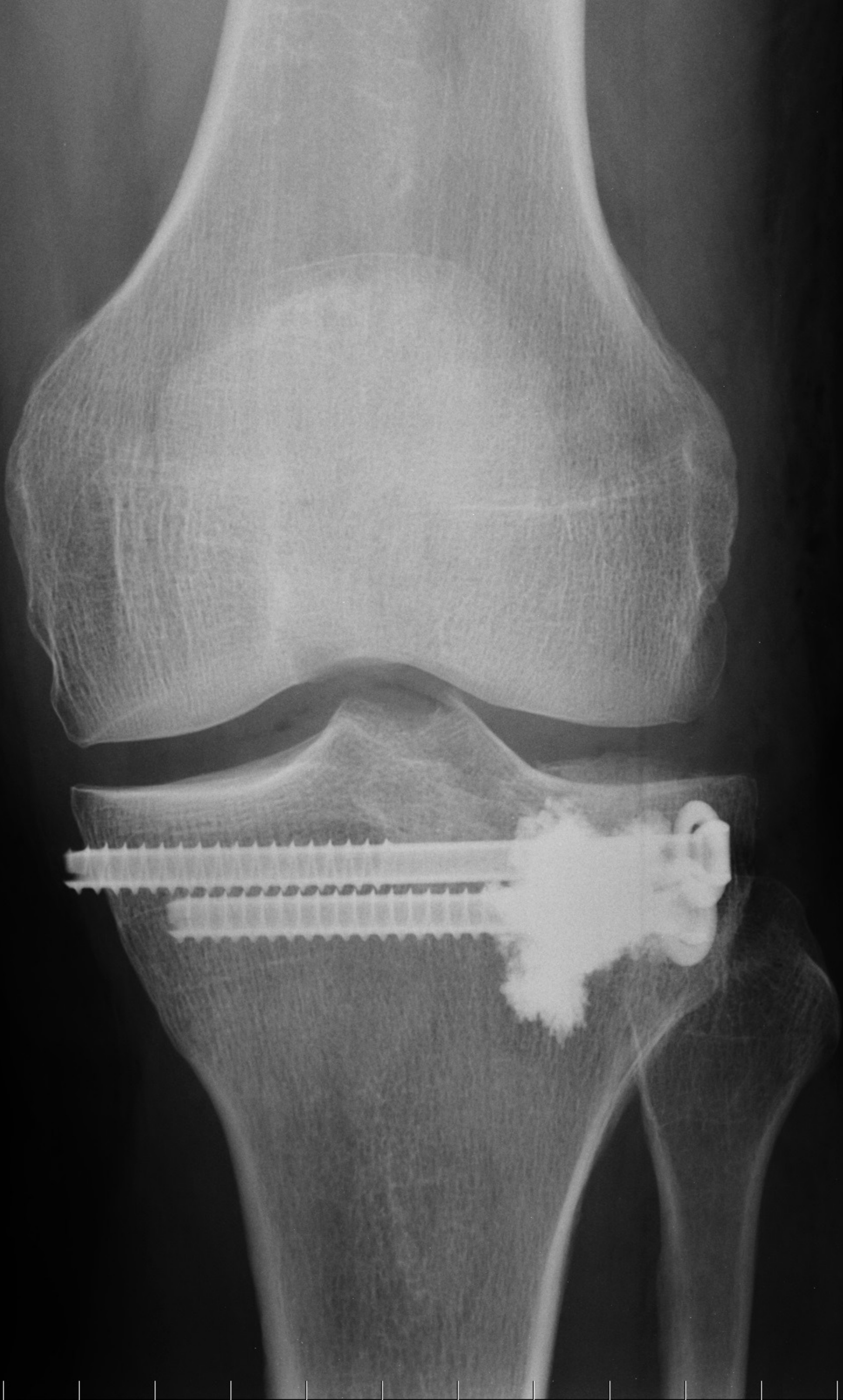




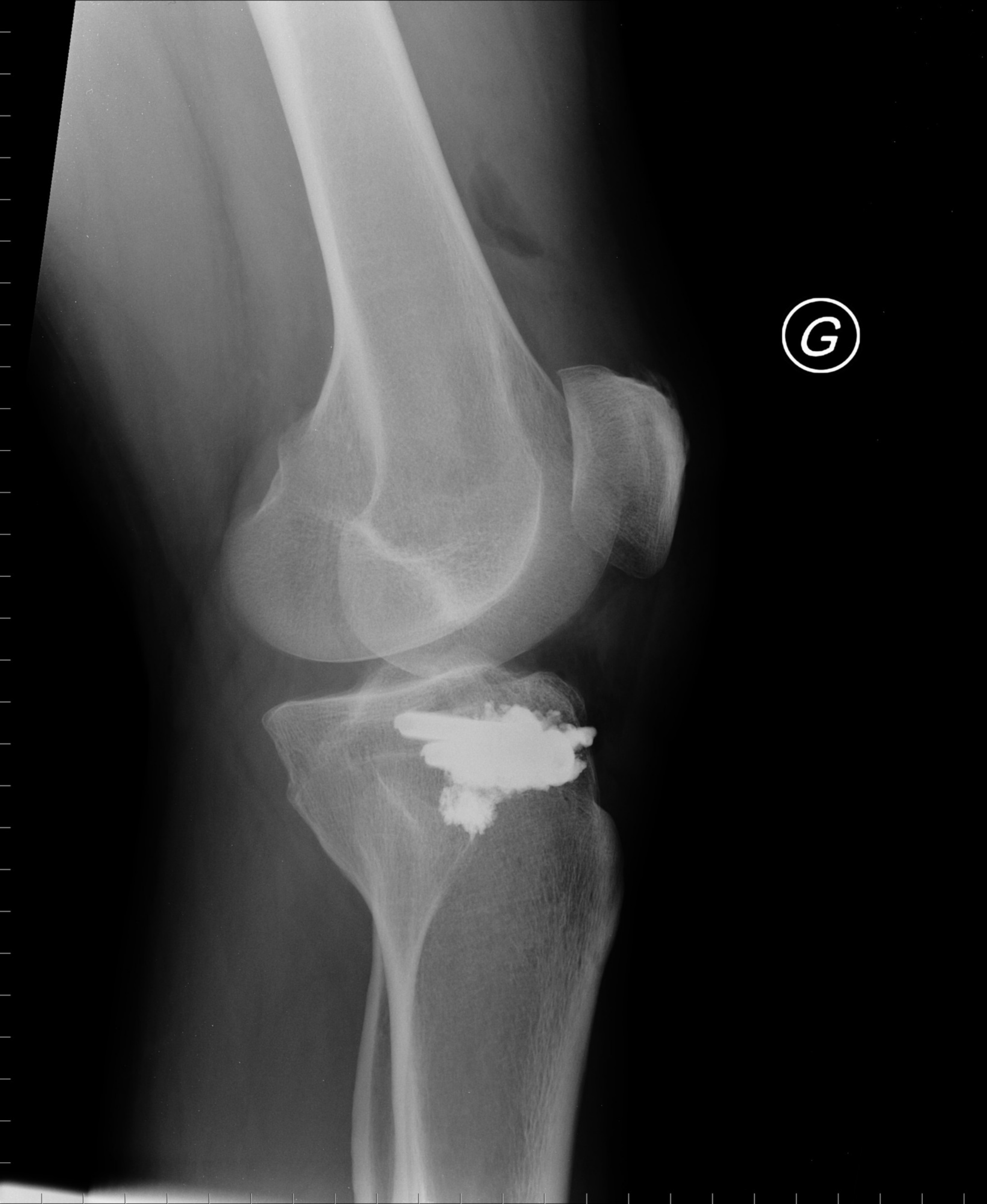

280 mm

©G



©G



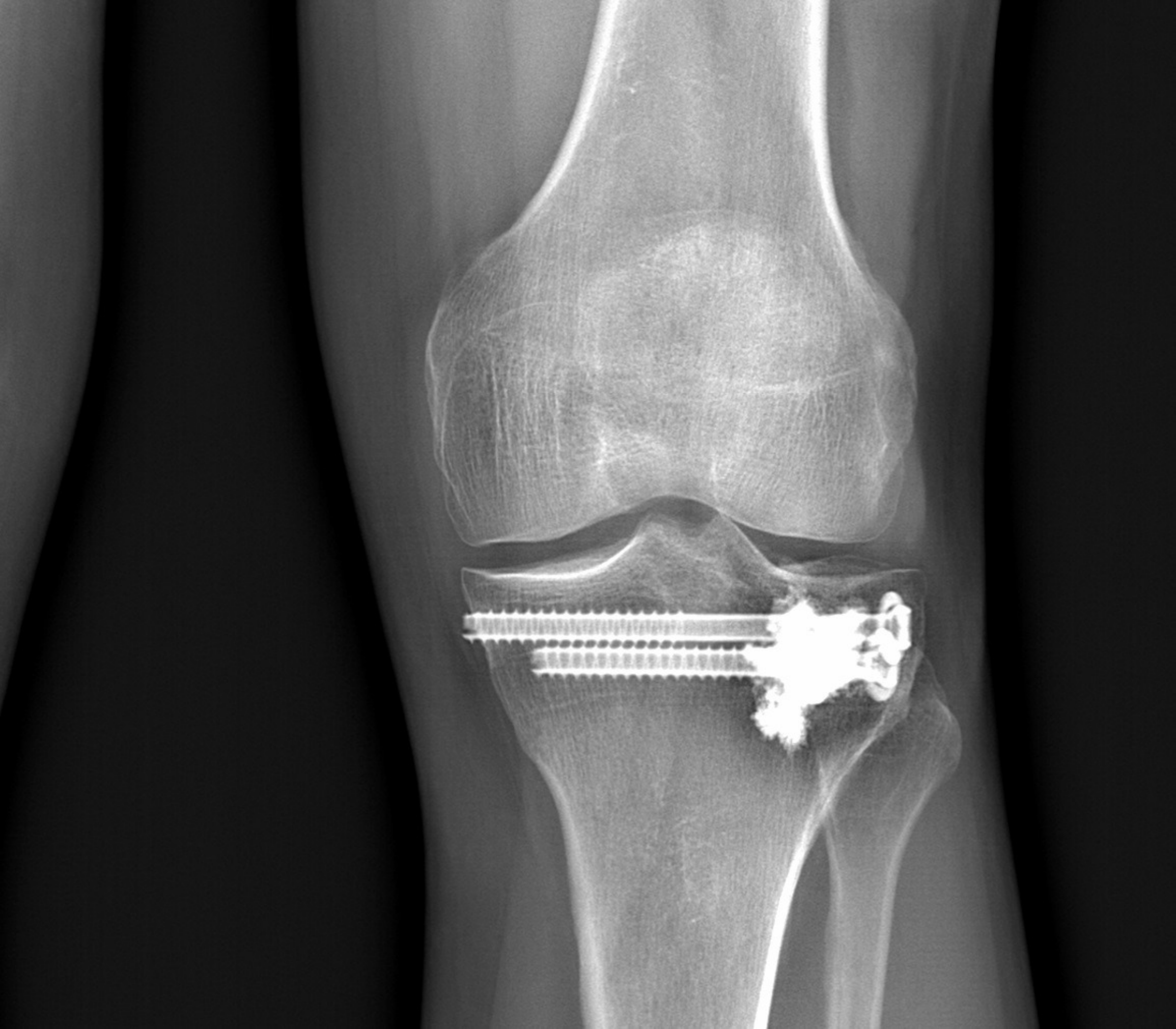


Table 1: Measurements of depression, operative times, flexion range of motion, weight-bearing recovery, KOOS score, HKA and complications

	Average \pm SD [min ; max]	Number of patients
Depression measurement		
Pre-operative (mm)	7,4 \pm 4,6 [3 ; 18]	26
Post-operative (mm)	2,6 \pm 2,5 [0 ; 9]	25
Operating time (min)		
Tuberoplasty only	53 \pm 21 [25 ; 89]	18
Tuberoplasty with arthroscopy	113 \pm 26 [83 ; 163]	9
Range of motion at 6 weeks		
Flexion (degrees)	103 \pm 32 [30 ; 130]	14
Weight-bearing		
Partial (days)	47 \pm 37 [3 ; 150]	24
Full (days)	58 \pm 33 [20 ; 150]	24
KOOS score		
Decline (years)	6,2 \pm 0,8s [5,2 ; 7,8]	16
Global	25,4 \pm 23,2 [1,3 ; 62,3]	16
Symptoms	19,0 \pm 19,9 [0 ; 64,3]	16
Pain	18,2 \pm 23,7 [0 ; 66,7]	16
Function, daily living	16,7 \pm 23,4 [0 ; 61,8]	16
Function, sports and recreational activities	40,3 \pm 33,4 [0 ; 100]	16
Quality of life	32,9 \pm 23,2 [0 ; 68,8]	16
HKA		
Decline (years)	6,1 \pm 0,8 [5,2 ; 7,8]	13
Axis	176,5 \pm 2,4 [172 ; 180]	13
Valgus	182,9 \pm 1,9 [181 ; 187]	8
Varus	175,8 \pm 2,9 [172 ; 179]	4
Null	180,0 \pm 0,0 [180 ; 180]	1
Difference on both sides	4,2 \pm 4,0 [1 ; 15]	13
Complications		
Intra-articular leaks		3
Venous thromboembolism		1
Comon fibular nerve deficit		1
Secondary displacement		2
Secondary depression		1

Table 2: Measures of depression, flexion amplitude, weight-bearing time, time to reload and KOOS score by class

Residual depression (mm)	0	1-2	3-5	> 5
Number of patients (25)	7	7	7	4
Range of motion at 6 weeks (degrees)	0-45	46-90	91-135	>135
Number of patients (14)	2	1	11	0
Weight-bearing (days)	<21	22-30	31-45	>45
Number of patients (24)	7	4	4	9
Time to full load (days)	<21	22-30	31-45	>45
Number of patients (24)	0	3	11	10
KOOS score	<25	26-50	51-75	76-100
Number of patients (16)	8	5	3	0