



HAL
open science

Dual-source dual-energy CT-scan confirms the diagnosis of ancient hydatid cysts recovered from a Late Roman burial in Amiens, France

Gholamreza Mowlavi, Shapour Shirani, Zeynab Askari, Jean Dupouy-Camet, Sacha Kacki, Majid Fasihi Harandi, Faranak Kargar, Negar Bizhani, Saeid Reza, Saeid Reza

► To cite this version:

Gholamreza Mowlavi, Shapour Shirani, Zeynab Askari, Jean Dupouy-Camet, Sacha Kacki, et al.. Dual-source dual-energy CT-scan confirms the diagnosis of ancient hydatid cysts recovered from a Late Roman burial in Amiens, France. *Iranian Journal of Parasitology*, 2022, 17 (2), pp.194-201. 10.18502/ijpa.v17i2.9536 . hal-03819789

HAL Id: hal-03819789

<https://hal.science/hal-03819789>

Submitted on 18 Oct 2022

HAL is a multi-disciplinary open access archive for the deposit and dissemination of scientific research documents, whether they are published or not. The documents may come from teaching and research institutions in France or abroad, or from public or private research centers.

L'archive ouverte pluridisciplinaire **HAL**, est destinée au dépôt et à la diffusion de documents scientifiques de niveau recherche, publiés ou non, émanant des établissements d'enseignement et de recherche français ou étrangers, des laboratoires publics ou privés.



Distributed under a Creative Commons Attribution - NonCommercial 4.0 International License



Tehran University of Medical
Sciences Publication
<http://tums.ac.ir>

Iran J Parasitol

Open access Journal at
<http://ijpa.tums.ac.ir>



Iranian Society of Parasitology
<http://isp.tums.ac.ir>

Original Article

Dual-Source Dual-Energy CT-Scan Confirms the Diagnosis of Ancient Hydatid Cysts Recovered from a Late Roman Burial in Amiens, France

*Gholamreza Mowlavi^{1,2}, Shapour Shirani³, Zeynab Askari¹, Jean Dupouy-Camet⁴, Sacha Kacki⁵, Majid Fasihi Harandi⁶, Faranak Kargar⁷, Negar Bizhani¹, Saeid Reza Naddaf⁸

1. Department of Parasitology and Mycology, School of Public Health, Tehran University of Medical Sciences, Tehran, Iran
2. Center for Research of Endemic Parasites of Iran (CREPI), Tehran University of Medical Sciences, Tehran, Iran
3. Department of Radiology, Tebran Heart Center, Teberan University of Medical Sciences, Tehran, Iran
4. Parasitology-Mycology Department, Cochbin Public Assistance Hospital Paris Hospitals, Paris Cité University, Paris, France
5. CNRS, PACEA, UMR 5199, University of Bordeaux, Pessac Cedex, France
6. Research Center for Hydatid Disease in Iran, School of Medicine, Kerman University of Medical Sciences, Kerman, Iran
7. Shahid Rajaei Heart Hospital, Faculty of Medicine, Tebran University of Medical Sciences, Tehran, Iran
8. Department of Parasitology, Pasteur Institute of Iran, Tehran, Iran

Received 15 Jan 2022
Accepted 13 Mar 2022

Keywords:
Echinococcus granulosus;
Hydatid cysts;
Dual-source dual-
energy CT-scan;
Amiens

***Correspondence**
Email:
molavig@yahoo.com

Abstract

Background: Two calcified objects recovered from an adolescent in a burial site in Amiens, France, have been previously identified as hydatid cysts using thin-section petrography. The importance of ancient hydatidosis besides the value of these unique archeological excavated materials encouraged the authors to look at this attractive subject more interdisciplinary by implementing medical radiology.

Methods: In the current experiment, which has been carried out in the Radiology Department, Tehran Heart Center (THC), Tehran, Iran, the conventional and dual-energy dual-source CT-scan was used in studying the remaining structures of the two calcified masses. The imaging procedure was carried out based on X-Ray attenuation by two different tube voltages.

Results: A high concentration of calcium sediment in the cyst walls was revealed in Hounsfield units, the measuring of the elements in CT. Taking advantage of implementing this imaging technique the oxalate calcium was also shown as the dominant component of the samples. The results were all in favor of diagnosing hydatid cysts.

Conclusion: The achieved pictorial results in the present paper have highlighted the important role of CT scan as a noninvasive confirming technique in paleopathological investigations. Using Dual-source dual-energy CT-scan in reconfirming these previously identified hydatid cysts, is an encouraging message towards the necessity of sequential studies on invaluable biological excavated pieces.



Copyright © 2022 Mowlavi et al. Published by Tehran University of Medical Sciences.

This work is licensed under a Creative Commons Attribution-NonCommercial 4.0 International license.

(<https://creativecommons.org/licenses/by-nc/4.0/>). Non-commercial uses of the work are permitted, provided the original work is properly cited

Introduction

H ydatidosis is a chronic and slowly growing cystic parasitic infection that leads to surgery in complicated cases.

It is prevalent in developing countries and is known as a re-emerging disease in some regions with a history of previous occurrences (1). The origin of the term "Hydatid" in Greek as "watery vesicles" refers well to its common clinical description" (2). Since humans acquire hydatidosis through the ingestion of the *Echinococcus granulosus* eggs dispersing by the feces of infected dogs and other canids feeding on parasitized viscera of herbivores, the disease could have happened worldwide over time (3).

Given the prevalence of this zoonotic disease at the present modern time, the human cases in millenniums ago could have been more than it appears (4). Events like domestication and settlement (5), parallel to public neglect in health measures amongst primitive populations, could have played an essential role in the diffusion of CE since the Neolithic revolution. Meanwhile, it should be taken into account that parasitological objects for the cystic echinococcosis in archeological sites are limited compared to most other helminthic infections identified based on eggs structures.

We previously identified hydatid cysts in an adolescent in a burial site in Amiens, France, by observing typical laminated layers using thin-section petrography (6). Regarding the WHO expert committee in using medical imaging techniques for diagnosing human CE, we decided to re-describe the hydatid cysts of Amiens (7). Based on the artifacts associated with the skeletons, which included a glass pitcher, metallic objects, and coins this grave

of a small Late Roman necropolis, dated from the 3rd-4th century AD.

CT scan can be a practical technique to detect unusual hydatid cysts, e.g., applying contrast-enhanced dynamic CT to detect intracardiac echinococcosis (8). Due to the high risk of x-ray radiation for the live body, these dual techniques are limited in patients concerning radiation exposures that should be as low as a possible rule (ALAP). So this is promising that Dual-source dual-energy computed tomography can be used without restriction for archeological remains.

Materials and Methods

The two objects under study were initially recovered during a rescue excavation conducted in 2009 by the Institut National de Recherches Archéologiques Préventives (Inrap) at 'Avenue Charles de Gaulle', in the city center of Amiens (northern France). Conventional and dual-energy dual-source CT-scan (Kv140 and Kv100) with Maximum Intensity Projection (MIP) and Volume Rendering (VR) reconstruction were performed on the remaining structures of the two calcified masses (Fig. 1) in the Radiology Department, Tehran Heart Center (THC), using a SOMATOM Definition Flash (Dual-Source) Siemens 2009, for dual-energy study and 16 slice spiral scanner for conventional CT. The inner powder was similarly scanned. Diagnostic imaging was carried out based on X-Ray attenuation by two different tube voltages for chemical composition definition.



Fig. 1: The calcified object identified as hydatid cyst (A, one of the recovered cysts, B, Represents the inner concave surface and the outer convex surface of that cyst)

Ethical approve

The samples used in this study were provided by Inrap in accordance with national legislation.

Results

Dual-energy CT revealed the dimensions of two imaged concavo-convex particles as 35x31x4 mm and 34x29x2 mm. The concave inner side of the calcified objects was relatively smooth, while the convex outer surface of the samples was irregular. The average thickness of the samples was 2.3 mm, and by changing the window level, the characteristic laminated layers became visible (Fig. 2).

Concerning the Hounsfield unit, (measuring of the elements in CT) the HU in 100 and 140 KV were 1420 and 780 HU respectively, which might be attributed to a high concentration of calcium sediment in the cyst walls (Fig. 3). Oxalate calcium was also shown here as the dominant component of the samples by the dual-energy plot. Performing single source CT-Scan did not show enough descriptive evidence other than showing a primitive calcified cystic appearance (Fig. 2 B). Since the procedure was programed to detect the calcium-based objects, the internal cyst powder was not observed in the CT image, indicating the absence of calcium.

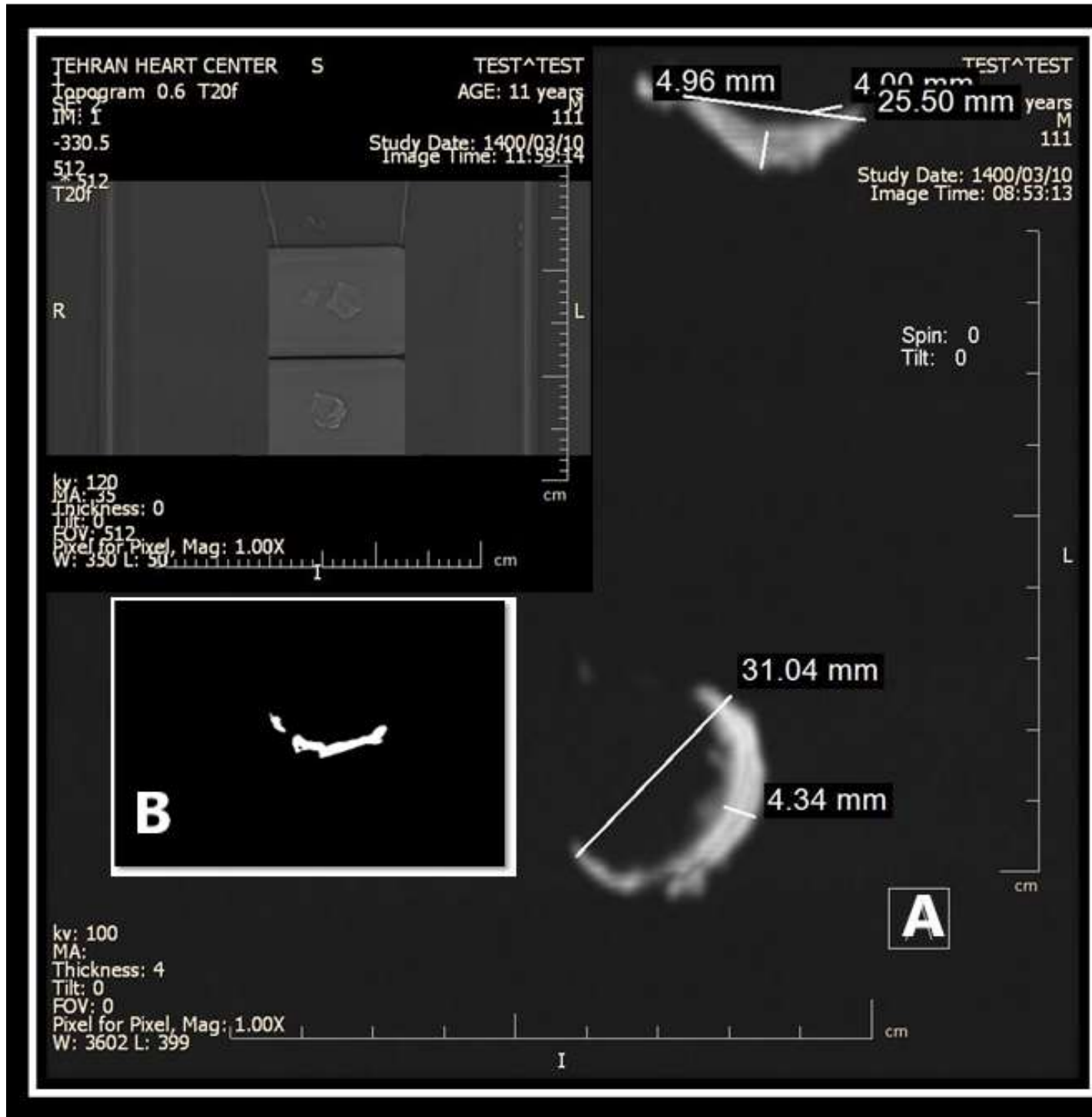


Fig. 2: A: Dual energy dual source CT using SOMATOM Definition Flash (Dual-Source) Siemens 2009 shows the presence of laminated layer B: Low-resolution regular 16 slice single source spiral CT shows the calcified cyst wall

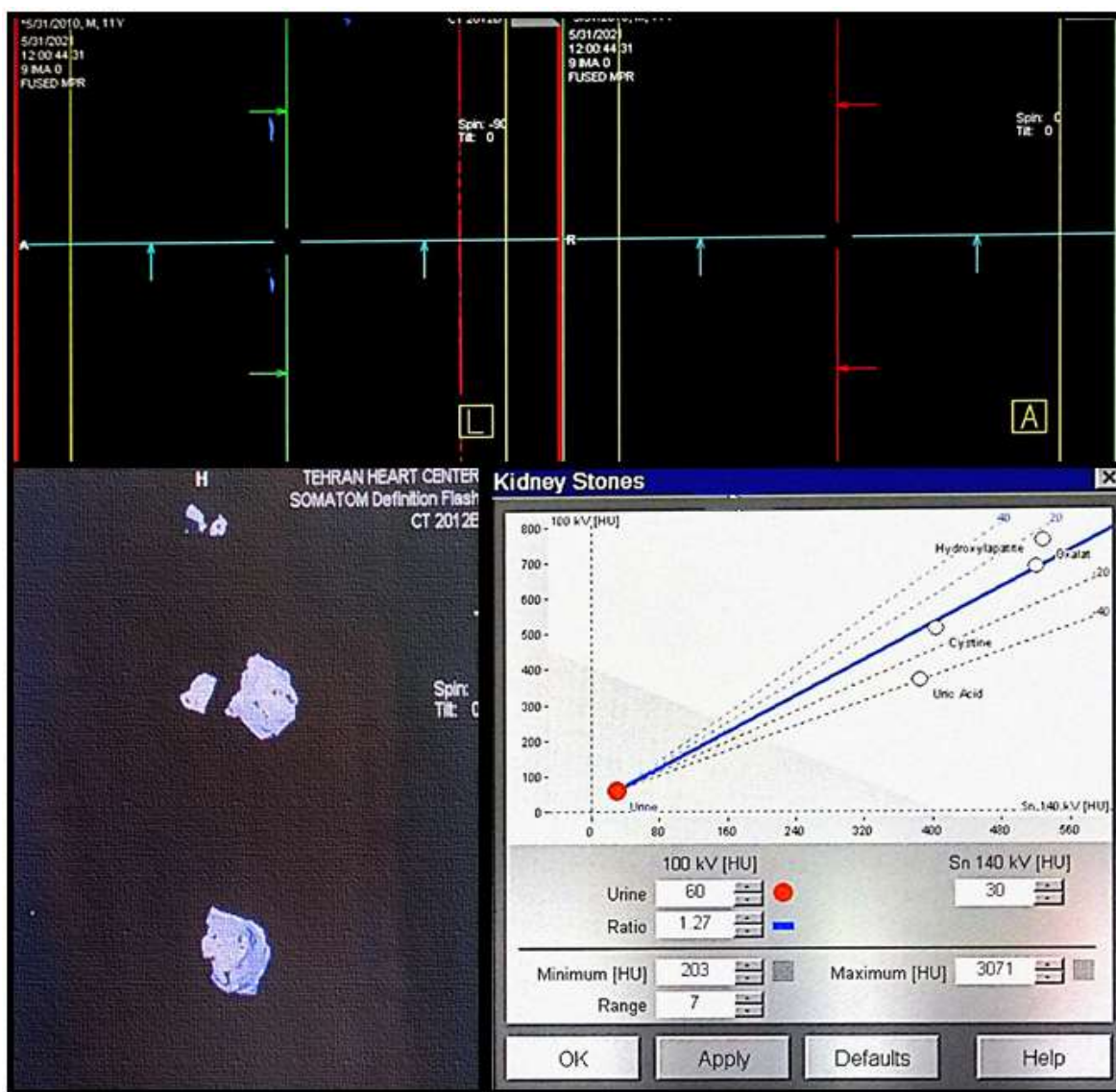


Fig. 3: Dual-energy study curve, for evaluation of the chemical composition of cyst wall, shows blue encoding compatible with highly calcified structure. The curve was depicted on Leonardo work station, medical Siemens Somatom definition CT

Discussion

Human cystic echinococcosis, caused by the metacestodes of *E. granulosus*, has been occasionally reported from archeological sites worldwide (9). By looking at this zoonotic helminthes life cycle (3), hydatid cyst might have circulated on the Earth since the *Homo sapiens* time, and its occurrence may have increased significantly since the Neolithic revo-

lution. Supporting the claim can be justified in occasional contacts between humans and canines in pre domestication periods.

Despite expecting a higher number of hydatidosis in ancient times, the scarcity of these findings in archeological sites can be undoubtedly attributed to neglect in collecting the biological samples besides the similarities of calcified hydatid cysts to pebbles obtained in ancient cemeteries (10). Nevertheless, mention-

ing the number of cystic echinococcosis confirmed in the brain and lung of the Egyptian mummies by tissue sections is an impressive example (11). To avoid any neglect in exceptional opportunities during the archeological excavations, archeologists should be more cautious in dealing with possible biological remains in the burials and those near the skeletons in excavating sites as they intensively do with the everyday unearthed archeological objects. In addition, the available diagnostic tools that have been already utilized successfully in similar exceptional items should also be carefully regarded. The Saltmen of Chehrabad salt mine (12), Ötzi, also called the Iceman (13), and the other invaluable findings like the artificial eye found in Shahr-i Sokhta of Bronze Age of Iran (14), are of these priceless instances which are not usually attainable everywhere.

Confronting such unique findings in archeological studies leads the researchers in finding innovative means of identification. During the paleopathological investigations as interdisciplinary research, creating applied techniques will be more possible through exchanging experiences amongst the team members. As we look at this burial more clinically now, providing a more detailed description of this medieval patient seems valuable. As the exact position of these calcified objects was not recorded during the fieldwork it is assumed that they were initially located in the thoracoabdominal as they have been isolated together with commingled bones from this anatomical region (i.e., costal and vertebral fragments).

Moreover, a glance at the literature indicates that approximately 75% of hydatid cysts may form in the liver and rarely in other internal organs (15). However, our presented medieval case might have suffered from hepatic hydatidosis. According to pathogenesis and the progression of hydatidosis, which the infection could be mostly acquired in childhood and its symptoms will gradually appear in adulthood (ADULT), the presented case might be described in the same scenario. Meanwhile, the

Roman case with incomplete mineralization of the roots of the third molar (16) and the degree of bone maturation (17) is determined as an adolescent individual whose age-at-death was comprised between 16 and 19-year-old. The sex also did not determine due to the ossa coxae's destruction.

Furthermore, concerning the laminated layers observed in the present case of Amiens and the fact that the intact laminated layers are not typically visible in fully calcified hydatid cysts (18,19), observing these characteristic structures could be attributed to partially calcified chronic hydatid cysts. Since the skeleton does not display any obvious bone lesion, the presence of those calcified cysts suggests that the individual may have suffered from a pathological disorder. Since the cause of death was not directly emphasized in the previously published paper for the individual of 3rd-4th century AD, the threatening consequences of cystic hydatidosis and its possible reinfections should not be possibly overlooked.

However, the obstructive effects, the cirrhotic process of the disease, as well as coinfection with capillarioris demonstrated in the mentioned article must be also regarded as the possible cause of death in this file of the Roman individual. Now that the importance of recognizing these biological remains is well cleared it is also important to mention that despite five decades of the advent of CT scan in the world medical sciences, the use of this technique on excavated skeletons is widely used in projects. In patients, CT is capable to detect cyst wall or septal calcification in a frequent postcontrast enhancement with high sensitivity and specificity for HD (20) along with most clearly depicting the levels of gas or air within the cyst (21). Although some severe large pathological signs have been occasionally described from anthropological views using CT-Scan, however, the more available capabilities of these technical facilities have been neglected. Of course, to some extent, taking advantage of this technology has been practically used in Thirteen Natural Mummies from Italy,

through which the history of diseases and living conditions in ancient populations can be described (22). Applying of CT-scan imaging technique for calcified hydatid cysts exhumed from one of the graves from the 'Avenue Charles de Gaulle' burial ground is re-emphasizing this previously reported finding in 2014. Therefore, following our previous X-ray microanalysis detecting calcium and phosphorus oxides, calcite, and apatite components, through XRD and XRF techniques (6), to attain a complete illustration of the same cystic objects, performing of dual-energy dual-source CT-Scan was carried out.

The capability of dual-energy in detecting the chemical composition of the material re-confirmed the texture of the Hydatid cysts. At the same time, with this new spectral imaging method that determines the essential elements according to their atomic numbers, image contrast optimization and metal artifacts reduction can also be attainable (23). On the other hand, the interested parasitologists working along with the archeologists on the field should also think to apply CT prior to any destructive procedure as well. In this case, radiologists are fortunately enough openhanded to maneuver a wide range of radiation for archeological objects regardless of recommended ALAP in the clinics.

Conclusion

Investigating valuable biological remains excavated from the archeological sites in Paleoparasitology is promising, shedding light on hidden realities upon the diseases and the health over time.

Acknowledgements

The authors would like to express their sincere appreciation to the technical staff in Tehran Heart Centre Hospital in facilitating of official steps for conducting CT- scans.

Conflict of interest

The authors declare that there is no conflict of interests.

References

1. Siracusano A, Teggi A, Ortona E. Human cystic echinococcosis: old problems and new perspectives. *Interdiscip Perspect Infect Dis*. 2009; 2009: 474368.
2. Garg MK, Sharma M, Gulati A, et al. Imaging in pulmonary hydatid cysts. *World J Radiol*. 2016. 8(6): p. 581-87.
3. Beaver PC, Jung RC, Cupp EW. *Clinical Parasitology*. Pennsylvania: Lea & Febiger; 1984.
4. Bouchet F, Harter S, Le Bailly M. The state of the art of paleoparasitological research in the Old World. *Mem Inst Oswaldo Cruz*. 2003; 98: p. 95-101.
5. Paknezhad N, Mazdarani FH, Hessari M, et al. Retrieving ascarid and taeniid eggs from the biological remains of a Neolithic dog from the late 9th millennium BC in Western Iran. *Mem Inst Oswaldo Cruz*. 2017; 112: p. 593-595.
6. Mowlavi G, Kacki S, Dupouy-Camet J, et al. Probable hepatic capillariosis and hydatidosis in an adolescent from the late Roman period buried in Amiens (France). *Parasite*, 2014. 21:9.
7. Organization, W.H. Echinococcosis 2021; Available from: <https://www.who.int/news-room/fact-sheets/detail/echinococcosis>
8. Omrani GR, Kargar F, Aazami MH. Intra-pericardial hydatid cyst seen by dynamic computed tomography. *E J Cardio Surg*, 2006. 30(5): p. 805-805.
9. Gonçalves ML, Araújo A, Ferreira LF. Human intestinal parasites in the past: new findings and a review. *Mem Inst Oswaldo Cruz*. 2003. 98: p. 103-118.
10. Ferreira LF, Reinhard K J, Araújo A. *Foundations of paleoparasitology*. Editora Fiocruz; 2014.
11. Sandison A, Tapp A. *Disease in ancient Egypt*. 1998: Cambridge: Cam Uni Press.
12. Aali A, Abar A, Boenke N, et al. Ancient salt mining and salt men: the interdisciplinary Chehrabad Douzlakh project in north-western Iran. *Antiquity*, 2012. 86(333).

13. Kutschera W, Rom W. Ötzi, the prehistoric Iceman. NIM-B, 2000. 164: p. 12-22.
14. Moghadasi AN. Artificial eye in burnt city and theoretical understanding of how vision works. Iran J Public Health. 2014. 43(11): p. 1595-96.
15. Engin G, Acunaş B, Rozanes I, Acunaş G. Hydatid disease with unusual localization. Eur Radiol, 2000. 10(12): p. 1904-1912.
16. Moorrees CF, Fanning EA, , Hunt EE Jr. Age variation of formation stages for ten permanent teeth. J Dent Res, 1963. 42(6): p. 1490-1502.
17. Cunningham C, Scheuer L, Black S. Developmental juvenile osteology. Academic press. 2016.
18. Pawlowski ZS, Eckert J, Vuitton D, et al. Echinococcosis in humans: clinical aspects, diagnosis and treatment. In: Eckert J, Gemmell MA, Meslin et al. editors WHO/OIE manual on echinococcosis in humans and animals: a public health problem of global concern. 2001: p. 20-66.
19. Eckert J, Gemmell MA, Meslin FX, et al. WHO/OIE manual on echinococcosis in humans and animals: a public health problem of global concern. Paris, France: World Organisation for Animal Health, 2001.
20. Mehta P, Prakash M, Khandelwal N. Radiological manifestations of hydatid disease and its complications. Trop Parasitol, 2016. 6(2): p. 103.
21. Pedrosa I, Gemmell MA, Meslin F, et al. Hydatid Disease: Radiologic and Pathologic Features and Complications 1: (CME available in print version and on RSNA Link). Radiographics, 2000. 20(3): p. 795-817.
22. Petrella E, Piciocchi S, Feletti F, et al. CT scan of thirteen natural mummies dating back to the XVI-XVIII centuries: an emerging tool to investigate living conditions and diseases in history. PLoS One, 2016. 11(6): p. e0154349.
23. Omoumi P, Becce F, Racine D, et al. Dual-energy CT: basic principles, technical approaches, and applications in musculoskeletal imaging (Part 1). in Seminars in musculoskeletal radiology. 2015. Thieme Medical Publishers.