



**HAL**  
open science

## Identification and Quantification of Myofascial Taut Bands With Magnetic Resonance Elastography

Qingshan Chen, Sabine F Bensamoun, Jeffrey Basford, Jeffrey Thompson,  
Kai-Nan An

► **To cite this version:**

Qingshan Chen, Sabine F Bensamoun, Jeffrey Basford, Jeffrey Thompson, Kai-Nan An. Identification and Quantification of Myofascial Taut Bands With Magnetic Resonance Elastography. Archives of Physical Medicine and Rehabilitation, 2007, 88 (12), pp.1658-1661. 10.1016/j.apmr.2007.07.020 . hal-03812635

**HAL Id: hal-03812635**

**<https://hal.science/hal-03812635>**

Submitted on 16 Oct 2022

**HAL** is a multi-disciplinary open access archive for the deposit and dissemination of scientific research documents, whether they are published or not. The documents may come from teaching and research institutions in France or abroad, or from public or private research centers.

L'archive ouverte pluridisciplinaire **HAL**, est destinée au dépôt et à la diffusion de documents scientifiques de niveau recherche, publiés ou non, émanant des établissements d'enseignement et de recherche français ou étrangers, des laboratoires publics ou privés.

# Identification and Quantification of Myofascial Taut Bands With Magnetic Resonance Elastography

Qingshan Chen, M.S.<sup>1</sup>

Sabine F. Bensamoun, Ph.D.<sup>1</sup>

Jeffrey R. Basford, M.D, PhD.<sup>2</sup>

Jeffrey M. Thompson, M.D.<sup>2</sup>

Kai-Nan An, Ph.D.<sup>2</sup>

<sup>1</sup>Biomechanics Laboratory, Division of Orthopedic Research, Mayo Clinic, College of Medicine, Rochester, MN.

<sup>2</sup>Department of Physical Medicine and Rehabilitation, Mayo Clinic, College of Medicine, Rochester, MN.

## **Corresponding Author:**

Jeffrey R. Basford, MD, PhD

Dept of Physical Medicine and Rehabilitation,

Mayo Clinic, 200 First St SW,

Rochester, MN 55905,

e-mail: basford.jeffrey@mayo.edu

**Grant Support:** Supported by the National Institute of Health (grant no. EB00812).

## **ABSTRACT**

**Objective:** To explore the feasibility of using a new magnetic resonance imaging (MRI) technique - magnetic resonance elastography (MRE) - to identify and quantitate the nature of myofascial taut bands.

**Design:** This investigation consisted of 3 steps. The first involved proof of concept on gel phantoms, the second involved numeric modeling, and the third involved a pilot trial on 2 subjects. Imaging was performed with a 1.5T MRI machine. Shear waves were produced with a custom-developed acoustically driven pneumatic transducer with gradient-echo image collection gated to the transducer's motion. Shear wave propagation were imaged by MRE.

**Setting:** An MRI research laboratory.

**Participants:** Two women, one with a 3-year history of myofascial pain and the other serving as the control.

**Interventions:** Not applicable.

**Main Outcome Measures:** MRE images, finite element analysis calculations, and tissue and phantom stiffness determinations.

**Results:** Results of the phantom measurements, finite element calculations, and study patients were all consistent with the concept that taut bands are detectable and quantifiable with MRE imaging. The findings in the subjects suggest that the stiffness of the taut bands ( $9.0\pm 0.9\text{KPa}$ ) in patients with myofascial pain may be 50% greater than that of the surrounding muscle tissue.

**Conclusions:** Our findings suggest that MRE can quantitate asymmetries in muscle tone that could previously only be identified subjectively by examination.

**Key Words:** Magnetic resonance imaging; Myofascial pain; Rehabilitation.

## 1. INTRODUCTION

Medical Advances depend on improvements in our ability to objectively diagnose disease and quantify the effects of treatment. Much progress has been made. Nevertheless, many conditions remain obscure in origin and dependent on the clinician's skills for identification and treatment. This situation is particularly true for the musculoskeletal system, for which a number of disabling and painful syndromes remain poorly defined, controversial in nature, and dependent on qualitative criteria for diagnosis. This subjectivity is not a trivial issue, because the lack of quantification can result in an inability to generate an accepted diagnosis, isolate a mechanism of action, or accurately assess the benefits of treatment. Two conditions, myofascial pain and fibromyalgia, epitomize this situation in that their existence (much less treatment) remains controversial despite a high prevalence (3-6 million in the United States for fibromyalgia and perhaps 9 million for myofascial pain)<sup>1</sup> and the development of diagnostic criteria. The root of the difficulty, despite the presence of criteria, lies in their difficult-to-quantitate symptoms (eg, pain and fatigue) and problematic and semi-qualitative physical findings. In the case of myofascial pain, the main findings are localized bands of increased tone (taut bands), which contain even more circumscribed points of tenderness that when compressed produce stereotypical patterns of referred pain (trigger points).<sup>2</sup> In fibromyalgia, a major component of the diagnosis is dependent on the detection of a set of tender points that are distributed in a specific pattern, but which unlike trigger points typically do not produce referred pain when pressed.

Several attempts have been made over the years to quantify the nature of taut bands and trigger points and thereby gain the tools necessary for a more objective study of the condition and effects of treatment.<sup>3,4</sup> Several handheld mechanical devices that use pressure to quantitate the sensitivity of pressure points (pressure algometers) have been developed to

measure tissue stiffness over the years,<sup>5</sup> but have not gained wide acceptance in clinical use, perhaps due to concerns about reliability.<sup>6</sup> It may be that a modification of widely available magnetic resonance imaging (MRI) techniques can offer a solution.

Magnetic resonance elastography (MRE) is a relatively recent advancement in MRI imaging that uses phase contrast imaging<sup>7</sup> to detect tissue stiffness. The process is, in theory, quite simple. An external source is used to introduce cyclic shear waves into the tissue to be studied and phase contrast imaging is used to image tissue distortions as the waves pass through the region of interest. Wavelengths ( $\lambda$ ) are then determined from the images and used to calculate the speed of the waves. The final step consists of recognizing that shear waves travel more rapidly in stiffer than in less rigid materials and that once a wave's speed has been determined inversion algorithms<sup>7,8</sup> can be used to reconstruct the shear modulus of the tissue.

Initial MRE investigations were devoted to the analysis of a variety of soft tissues such as cancer of the breast.<sup>7,8</sup> More recent work, in part by this group, has begun to assess the usefulness of this approach in the study of the musculoskeletal sequelae of conditions such as immobilization, stroke, and spinal cord injury. This study, however, focuses specifically on myofascial pain, given the high prevalence of the condition, its controversial nature, and the importance of taut bands to its diagnosis. The latter are particularly intriguing in view of the fact that these bands do, in actuality, feel taut (ie, stiff) on examination and of the acceptance by many that, if they exist, they are the product of localized increases in muscle tone. Our hypothesis was that taut bands are the result of increased muscle tension and that MRE imaging would be able to detect and begin to quantitate their presence on the basis of differences between the velocities of shear waves in the bands and the softer surrounding muscle.<sup>9-13</sup> Our investigation consisted of 3 steps. The first involved a proof of concept imaging in gel phantoms, the second involved numeric modeling, and the third involved patients.

## 2. METHODS

### **Bovine Gel Phantom**

Phantoms representing muscles with taut bands were fabricated using bovine gels of 2 weight/volume (% w/v) consistencies. The stiffer (18% w/v) gel occupied a 4cm wide central channel in a 30cm long by 7cm deep acrylic mold that was sandwiched between two 5cm wide bands of the less rigid 8% w/v gel. The bar-like applicator of an adjustable electromechanical vibrator was placed on the surface of the gel at the mold's distal end such that the induced shear waves traveled parallel to the central channel's long axis. MRI techniques and parameters were those reported in previous in vitro studies.<sup>14-16</sup> A shear wave driving frequency of 250Hz was used and 8 vertical offset 2-dimensional MRE phase images were collected for each cycle.

### **Finite Element Simulation**

Finite element analysis was performed with ABAQUS.<sup>17,a</sup> Eight-node linear brick elements (C3D8) were used throughout a model of the same dimensions as used in the bovine phantom above and its bottom surface was vertically constrained. The shear modulus of the central channel was defined as twice that of its lateral softer regions. Material damping was assumed to be zero. Cyclic sinusoidal shear waves at 250Hz were applied to the distal end of the model in order to mimic the gel phantom studies of the first experiment.

A previously described direct integration transient dynamic analysis procedure<sup>14,15</sup> was used to characterize shear wave propagation and the time increment in the analysis was set as  $4 \times 10^{-4}$  seconds.<sup>14,18</sup> Nodal displacements in vertical direction at the topical surface were extracted, reformatted, and displayed with an in-house-developed image analysis program.<sup>14,15</sup>

## **Participants**

Two women participated in this portion of the study. One (age, 23y; weight, 57kg; height, 165cm) had no history or findings of myofascial pain and served as a control subject. The other (age, 28y; weight, 59kg; height, 170cm) had a 3-year history of myofascial pain and underwent an examination and diagnosis confirmation by a physician experienced in its diagnosis and treatment. This physician also marked the location of a right upper-trapezial taut band with an indelible marker prior to the patient's undergoing imaging. This study was approved by our institutional review board and informed consent was obtained.

The imaging techniques used in this report share many features with those previously reported.<sup>19</sup> They do differ, however, in that shear waves were introduced with a custom-made acoustically driven pneumatic transducer (fig 1) rather than the electromechanical devices reported in the earlier investigations. More specifically, the driver was composed of a remotely located loudspeaker that was connected by 2.5cm internal diameter flexible plastic tubing to a 2.0cm deep, 6.7cm diameter plexiglas pressure chamber (see fig 1I). The inferior surface of the chamber in turn consisted of a .25mm-thick polycarbonate resin thermoplastic (Lexan) film<sup>b</sup> to which an 83-mm long, 6×22mm acrylic bar was attached (see fig 1II). The chamber assembly was in turn positioned by adjusting the arms of the positioning jig (see fig 1III) so that the vibrator bar was firmly pressed to the subject's skin just medial to the mid-portion of their scapular spine in a manner that was perpendicular to the direction of the trapezial muscle fibers. A 17.8-cm diameter MRI surface coil was placed over the right upper trapezius and 8 offsets of MRE phase image data were collected in the vertical (z) motion sensitization direction.

### **3. RESULTS**

#### **Taut Band Phantom**

MRE phase images of the taut band phantom revealed a chevron-shaped wave pattern (fig 2A), that differed from the planar wave fronts found in homogeneous gel phantoms (fig 2B)<sup>16</sup> and suggested a higher wave velocity in the central than in the lateral sections. Linear profiles were drawn longitudinally in both the stiffer (18% w/v) central channel and the lateral softer 8% regions. We calculated stiffness values<sup>19-21</sup> that indicated a  $48.6 \pm 10.8$  kPa stiffness in the central band and lesser stiffness of  $13.5 \pm 2.0$  and  $13.4 \pm 2.1$  kPa in the lateral regions. Wave reflection was observed in the distal region and was only partially eliminated by directional filtering.<sup>22</sup>

#### **Finite Element Simulation**

Simulated wave fronts in the finite element model also displayed a chevron pattern (fig 2C) that was consistent with that observed in the phantoms and compatible with a higher wave velocity within the central band. In contrast, a homogeneous finite element model showed planar wave fronts (fig 2D). Additional modeling (not shown) with central band of varying widths showed similar findings.

#### **Participants**

Wave fronts in typical MRE wave images of the control and myofascial pain patient are displayed in figures 2E and 2F. Images from the patient with myofascial pain revealed a longer wavelength (ie, faster velocity) and chevron-like pattern with the leading edge of the chevron coincident with the physician-identified taut band. Stiffness calculations performed as described above indicated that the modulus in the taut band was  $9.0 \pm 0.9$  kPa, whereas that



of the adjacent muscle tissue was  $6.2 \pm 0.8 \text{ kPa}$ .

The MRE phase image of the myofascial pain-free control subject on the other hand (see fig 2E) revealed a picture of planar wave fronts similar to those of the homogeneous phantom and finite element calculations (see figs 2A, 2C). We drew profiles along the wave propagation direction and a tissue stiffness of  $4.1 \pm 0.6 \text{ kPa}$  was calculated in the manner noted above.<sup>19-21</sup>

#### 4. DISCUSSION

The goal of this study was to investigate the potential of MRE imaging in the quantification of muscular pathophysiology. We believe that the findings provide a consistent pattern of support to our belief that, at least in the case of myofascial pain, we have succeeded in doing so.

More specifically, the taut band gel phantom studies revealed the presence of chevron-like wave patterns and higher shear wave velocities in their stiffer central channel as expected. Finite element analyses, as well as the subject imaging, confirmed these findings.

It is also supportive that the location of the taut band as identified by the physician in his examination was the same as that identified in the MRE images. Finally, it is reassuring that the  $9.0\pm 0.9\text{kPa}$  stiffness of the taut band in the subject with myofascial pain was not only above that of her surrounding musculature ( $6.2\pm 0.8\text{kPa}$ ), but also above the  $4.1\pm 0.6\text{kPa}$  value found in the control subject. This latter observation offers some support for the intuitively reasonable idea that even the resting tone of the uninvolved muscle of people with myofascial pain may be affected by the condition.

Comparisons between the previous experiments of MRE and numeric simulations in the upper extremity revealed that shaped shear waves were induced if the bicep's tendon was vibrated.<sup>8</sup> This led to some debate at the time within our group but the finding was thought to be primarily due to muscle anisotropy and the fact that the shear modulus along a muscle fiber's axis is significantly higher than that found across it.<sup>8</sup> The present study suggests that differential tone of muscle tissue may also play a role. This issue might benefit from further evaluation that considers the effects of point (eg, tendon) versus the broader vibratory source used in this study.

## **Study Limitations**

This study was exploratory in nature and its findings, although intriguing, have a number of obvious limitations. The most obvious is that we evaluated only 2 people; future investigations aimed at confirming the value of MRE in this application will clearly need to involve significantly larger numbers.

It should also be noted that the gel phantom and finite element analyses were performed simply to validate the concept that shear waves might display differential velocities as they traverse tissues modeled to have a taut band. They were not done in an attempt to produce a realistic model of the mechanical properties of skeletal muscles. It may be that these approaches will have some use in this role. We, however, did not pursue this issue.<sup>8</sup>

## **CONCLUSION**

The findings of this study have significance in that they support the idea that MRE imaging is capable of quantifying muscular pathophysiology whose existence was previously only apparent on physical examination. Further research might be directed toward improving the clinical usefulness of the technique as well as the identification of the more difficult to isolate trigger points and their relationship to taut bands.

## REFERENCES

1. Gerwin RD. Classification, epidemiology, and natural history of myofascial pain syndrome. *Curr Pain Headache Rep* 2001;5:412-20.
2. Travell J. Identification of myofascial trigger point syndromes: a case of atypical facial neuralgia. *Arch Phys Med Rehabil* 1981;62:100-6.
3. Tunks E, McCain GA, Hart LE, et al. The reliability of examination for tenderness in patients with myofascial pain, chronic fibromyalgia and controls. *J Rheumatol* 1995;22:944-52.
4. Wolfe F, Simons DG, Friction J, et al. The fibromyalgia and myofascial pain syndromes: a preliminary study of tender points and trigger points in persons with fibromyalgia, myofascial pain syndrome and no disease. *J Rheumatol* 1992;19:944-51.
5. Fischer AA. Tissue compliance meter for objective, quantitative documentation of soft tissue consistency and pathology. *Arch Phys Med Rehabil* 1987;68:122-5.
6. Kawchuk G, Herzog W. The reliability and accuracy of a standard method of tissue compliance assessment. *J Manipulative Physiol Ther* 1995;18:298-301.
7. Muthupillai R, Lomas D, Rossman P, Greenleaf JF, Manduca A, Ehman RL. Magnetic resonance elastography by direct visualization of propagating acoustic strain waves. *Science* 1995; 269:1854-7.
8. Sack I, Bernarding J, Braun J. Analysis of wave patterns in MR elastography of skeletal muscle using coupled harmonic oscillator simulations. *Magn Reson Imaging* 2002;20:95-104.
9. Alvarez DJ, Rockwell PG. Trigger points: diagnosis and management. *Am Fam Physician* 2002;65:653-60.
10. Simons DG. Examining for myofascial trigger points. *Arch Phys Med Rehabil* 1993;74:676-7.
11. Simons DG. Review of enigmatic MTrPs as a common cause of enigmatic

- musculoskeletal pain and dysfunction. *J Electromyogr Kinesiol* 2004;14:95-107.
12. Hong CZ. Treatment of myofascial pain syndrome. *Curr Pain Headache Rep* 2006;10:345-9.
  13. Hong CZ, Simons DG. Pathophysiologic and electrophysiologic mechanisms of myofascial trigger points. *Arch Phys Med Rehabil* 1998;79:863-72.
  14. Chen Q, Ringleb SI, Manduca A, Ehman RL, An KN. Differential effects of pre-tension on shear wave propagation in elastic media with different boundary conditions as measured by magnetic resonance elastography and finite element modeling. *J Biomech* 2006;39:1428-34.
  15. Chen Q, Ringleb SI, Manduca A, Ehman RL, An KN. A finite element model for analyzing shear wave propagation observed in magnetic resonance elastography. *J Biomech* 2005;38:2198-203.
  16. Ringleb SI, Chen Q, Lake DS, Manduca A, Ehman RL, An KN. Quantitative shear wave magnetic resonance elastography: comparison to a dynamic shear material test. *Magn Reson Med* 2005; 53:1197-201.
  17. ABAQUS/standard user's manual. Pawtucket: Hibbitt, Karlsson & Sorensen Inc; 2002.
  18. Chen Q, Ringleb SI, Manduca A, Ehman RL, An KN. Differential effects of pre-tension on shear wave propagation in elastic media with different boundary conditions as measured by magnetic resonance elastography and finite element modeling. *J Biomech* 2006;39:1428-34.
  19. Bensamoun SF, Ringleb SI, Littrell L, et al. Determination of thigh muscle stiffness using magnetic resonance elastography. *J Magn Reson Imaging* 2005;23:242-7.
  20. Heers G, Jenkyn T, Dresner MA, et al. Measurement of muscle activity with magnetic resonance elastography. *Clin Biomech (Bristol, Avon)* 2003 Jul;18:537-42.
  21. Uffmann K, Maderwald S, Ajaj W, et al. In vivo elasticity measurements of extremity

skeletal muscle with MR elastography. *NMR Biomed* 2004;17:181-90.


22. Manduca A, Lake DS, Kruse SA, Ehman RL. Spatio-temporal directional filtering for improved inversion of MR elastography images. *Med Image Anal* 2003;7:465-73.

### **Suppliers**

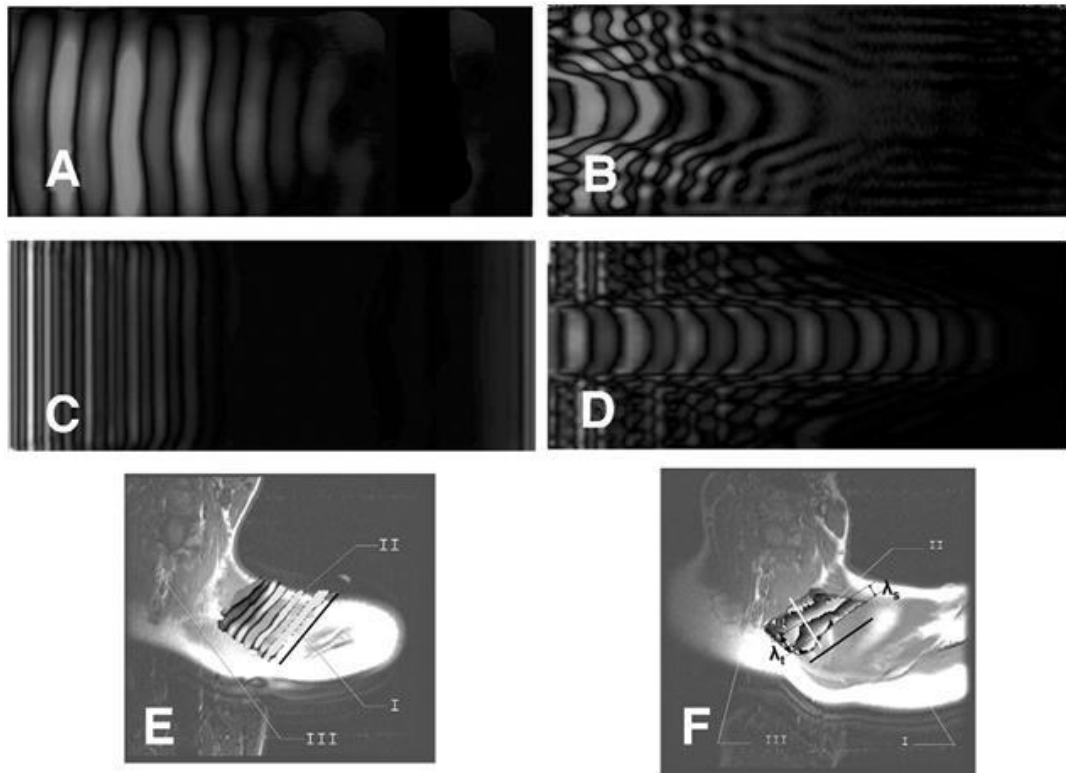
a. Version Standard 6.4-1; Simulia, Rising Sun Mills, 166 Valley St, Providence, RI 02909-2499.

b. GE Plastics, One Plastics Ave, Pittsfield, MA 01201.

## FIGURES



**Fig 1.** Experimental setup of MRE on subjects. (I) Pressure chamber connected to a remote loudspeaker. (II) Acrylic bar vibrator. (III) Positioning jig. (IV) Radiologic marker.



**Fig 2.** Wave propagation patterns. (A) MRE phase image of a homogeneous bovine gel phantom. The vibratory source located at the left border produces a planar waveform. (B) MRE phase image of the bovine gel taut band phantom. Note the chevron-like pattern of the waves as they travel away from the source located at the left border. (C, D) Finite element simulation of the homogeneous and taut band phantom models. Note the reoccurrence of the chevron-shaped waveform in the taut band simulation. (E) MRE phase image of upper trapezius of the control subject superimposed to an MR image of the same region. Note the uniform, planar nature of the waves produced by the vibratory source located on the spine of the scapula - (I) spine of scapula; (II) planar wave fronts in upper trapezius; and (III) cervical spine. (F) MRE phase image of upper trapezius of the patient with myofascial pain superimposed to an MR image of the same region. The line appearing in the figure's center indicates the physician's localization of the taut band. Although more difficult to distinguish than in the phantoms, the V-shaped wave fronts are again apparent.  $\lambda_t$  indicates the wavelength in the chevron-shaped wave fronts region, and  $\lambda_s$  indicates the wavelength in the



surrounding muscle - (I) spine of scapula; (II) chevron-shaped wave fronts observed in the region of taut band palpated by the physician; and (III) cervical spine.