



HAL
open science

Prospective and multicentre study of radiofrequency treatment in anal fistula

Marie Sautereau, Dominique Bouchard, Charlène Brochard, François Pigot, Laurent Siproudhis, Jean Marie Fayette, Cecile Train, Anne Laurain, Charlotte Favreau, Laurent Abramowitz

► To cite this version:

Marie Sautereau, Dominique Bouchard, Charlène Brochard, François Pigot, Laurent Siproudhis, et al.. Prospective and multicentre study of radiofrequency treatment in anal fistula. *Colorectal Disease*, 2023, 25 (2), pp.289-297. 10.1111/codi.16344 . hal-03800924

HAL Id: hal-03800924

<https://hal.science/hal-03800924v1>

Submitted on 21 Feb 2023

HAL is a multi-disciplinary open access archive for the deposit and dissemination of scientific research documents, whether they are published or not. The documents may come from teaching and research institutions in France or abroad, or from public or private research centers.

L'archive ouverte pluridisciplinaire **HAL**, est destinée au dépôt et à la diffusion de documents scientifiques de niveau recherche, publiés ou non, émanant des établissements d'enseignement et de recherche français ou étrangers, des laboratoires publics ou privés.



Distributed under a Creative Commons Attribution - NonCommercial 4.0 International License

Prospective and multicentre study of radiofrequency treatment in anal fistula

Authors: Marie Sautereau^(a), Dominique Bouchard^(b), Charlène Brochard^(c), François Pigot^(b), Laurent Siproudhis^(c), Jean Marie Fayette, Cécile Train^(d), Anne Laurain^(e), Charlotte Favreau^(b), Laurent Abramowitz^(e)

Affiliations:

- a) APHP, Department of Gastroenterology and Proctology, CHU Bichat, Paris.
- b) Department of Proctology, Bagatelle Hospital, Talence.
- c) Digestive Physiology Unit, Rennes Pontchaillou University Hospital, University of Rennes 1, Rennes.
- d) CRO ClinSearch, Malakoff.
- e) Ramsay GDS Blomet Clinic, Paris.

Abstract

Background: The most effective treatment for anal fistula is fistulotomy, but it involves a risk of anal incontinence. To reduce this morbidity, sphincter-sparing treatments have been developed, but their success in real life is often less than 50%. The aim is to determine clinical healing rate 6 months after radiofrequency treatment.

Patients and methods: We planned to evaluate 50 patients from 3 French proctology centres. Treatment efficacy was evaluated at 6 and 12 months by means of clinical and magnetic resonance imaging examination. We evaluated morbidity and healing prognostic factors.

Results: Fifty patients with a mean age of 51years [22-82] were included. Eleven patients had a low transsphincteric fistula(LTS), 21 high transsphincteric fistula(HTS), 8 complex fistula and 9 Crohn's disease fistula.

After 6 months, 17 patients (34.7%) had a clinically healed fistula, including 5 (45.5%) with LTS fistula, 7 (33.3%) with HTS fistula, 1 (12.5%) with complex fistula, 4 (44.4%) with Crohn's disease, with no significant difference between these fistula types ($p:0.142$). At 12 months, the healing rate was identical. MRI in 15 out of 17 clinically healed patients showed a deep remission of 73.3% at 12 months. Energy power was associated with the success of the treatment.

There was an 8.2% incidence of post-surgical complications with 4.1% being abscesses (one required surgical management). Postoperative pain was minor. No new cases or deterioration of continence have been shown.

Conclusion: Radiofrequency is effective in less than 50% of the cases as an anal fistula treatment in this first prospective study, with low morbidity and no effect on continence. Clinical healing was deep (MRI) in $\frac{3}{4}$ at 1 year. The increase in energy power during the procedure seems to be a key point to be analysed to optimise results.

Keywords: fistula-in-ano, sphincter-sparing, Crohn's disease, radiofrequency, anal incontinence

Introduction

The treatment of anal fistula remains a major challenge in proctological surgery. The objective is two fold: to heal the suppurative process and preserve anal continence. Currently, the reference treatment is the opening of the fistula tract by means of fistulotomy, with an effectiveness of 71% to 100%⁽¹⁻⁴⁾. According to the type of fistula (height, complexity), it is carried out in one or several steps with periods of drainage after seton placement⁽⁵⁻⁷⁾.

However, fistulotomy is associated with the risk of altering continence, in part related to the extent of sphincter muscle resection, with a significant impact on quality of life⁽⁸⁾. This risk is mainly for high, recurrent, complex and anterior fistulas in women. It is increased in Crohn's disease or in patients with a history of obstetrical and perineal surgery^(9–11). It varies from 2% to 82% after fistulotomy^(12–14), depending on centres but also on validated continence scales used and follow-up.

To reduce anal incontinence risk, sphincter-sparing surgery has been developed for decades⁽¹⁵⁾ without any other technique demonstrating superiority in terms of efficacy. There are those that obliterate the fistula tract (rectal advancement flap⁽¹⁶⁾, glue⁽³⁷⁾, PLUG⁽¹⁹⁾, LIFT⁽²⁰⁾) and those that destroy the walls of the fistula tract (laser⁽³⁵⁾, VAAFT⁽⁴⁷⁾). Overall, closure of the fistula without recurrence is obtained in about 50% of the cases. The studies evaluating the success of these treatments are very heterogeneous but it is lower than fistulotomy in most cases (5,25). Many of them were not evaluated with MRI examinations, now well recognised as only deep target (26).

Radiofrequency is a new tool used in several conditions (varicose veins, endobrachyoesophagus with dysplasia, pancreatic tumours, non-operable hepatocellular carcinomas and, more recently, haemorrhoids) (27–29). It provides a very localised tissue thermocoagulation by means of a high frequency signal transmitted through a catheter (Figure 1). Its precision reduces the risk of damage to adjacent tissues and, in the treatment of anal fistulas, it reduces, in theory, the risk of sphincter injury. In 2003, it was applied for the treatment of lower anal fistulas by means of fistulotomy compared to traditional fistulotomy (with diathermy) in two small series. The outcome was comparable, with less postoperative pain and earlier healing with radiofrequency (30,31). Recently, a new technique of endoscopic radiofrequency combining the VAAFT and the radiofrequency probe is being evaluated⁽³²⁾. Treatment of anal fistulas directly by radiofrequency probe, with destruction of the fistula wall without sphincter section, has never been prospectively studied. For this reason, we conducted this first prospective, multicentre, open therapeutic study to evaluate the efficacy and the safety of radiofrequency treatment in anal fistulas by means of clinical and MRI evaluation with one-year follow-up.

Patients and methods

Patients and investigating centres

With the Agence Nationale de Sécurité du Médicament (ANSM), we planned to include prospectively 50 patients for a period of 2 years (1 year of inclusion and 1 year of follow-up), from 3 French referral centres for proctology.

Eligibility criteria

Adult patients were required to have an anal fistula previously drained by means of seton placement. All of them had an MRI done before the procedure, in order to verify the absence of a non-drained tract. All fistulas which could be treated with sphincter-sparing therapy were proposed for inclusion (patient with complex, high trans-sphincteric fistula and "low trans-sphincteric fistula with risk of anal incontinence": pre-existing, Crohn's disease, obstetric and perineal surgical history, recurrent or anterior fistulas in women or patient's request because of the risk of incontinence). Secondary extensions and diverticula of complex fistulas were treated during the first phase of the operation by drainage of the extension.

The exclusion criteria were: linguistic or psychic inability to understand the information in order to give an informed consent and to complete the self-administered questionnaires, no sufficient drainage for seton removal (non-inflammatory orifices, no undrained tract on clinical examination and/or MRI), radiofrequency contraindication (residual clips from previous treatment, such as Longo haemorrhoidopexy), or MRI contraindication. Women had to guarantee absence of

pregnancy and the use of an effective contraception method. Patients could not participate in any other clinical study during this period.

Primary and secondary outcomes

The primary outcome was the clinical healing rate 6 months after radiofrequency treatment (defined as internal and external orifices obliteration without inflammation or discharge). Patients with an abscess during the follow-up period or requiring a new surgical procedure or antibiotic therapy (more than 15 days after surgery) were considered as failures.

The secondary outcome was the clinical healing rate at 12 months, rate and nature of immediate and late postoperative complications, assessment of pre- and post-treatment continence and patient satisfaction, identification of prognostic factors (type of fistula, patient, etc.), estimation of optimal radiofrequency settings and MRI for deep healing of clinically healed fistulas.

Follow-up and evaluation

The fistulas were divided into 4 strata:

- Single low tract trans-sphincteric (crossing the lower third of the anal sphincter) (LTS).
- Single high tract trans-sphincteric (crossing the upper two-thirds of the anal sphincter) (HTS).
- Complex with multiple tracts defined as high trans-sphincteric fistula with more than one external opening. These were high trans-sphincteric fistulas with multiple tracts, supralelevator or horseshoe fistulas) (C).
- Crohn's disease anal fistulas (CD).

If a patient had multiple fistulas, they were classified under the most severe stratum (LTS < HTS < C < CD).

The follow-up period was 1 year with 5 proctological clinical evaluations (pre-operative and post-operative after 1, 3, 6 and 12 months) and patient self-administered questionnaires. We used visual analogue scales and validated scores, the Vaizey score (33). Patients with clinical healing had a systematic MRI at 6 and 12 months to assess deep healing (absence of T1 injected hypersignal and T2 hypersignal). Data collection included demographic information, medical, surgical, and gynaecological history.

Material and procedure

Radiofrequency ablation treatment was by means of cauterisation with sterilisation of the fistula walls. We used a F Care Systems probe already validated for the treatment of venous and haemorrhoidal diseases. The length of the probe was of 35 cm. Different diameters were available to match the fistula diameter: 4F (1.33 mm), 5F (1.66 mm), 6F (2 mm), 7F (2.33 mm) and 9F (3 mm). The probe generated high frequency pulses of 4MHz. The generator produced a temperature of 120°C (25 watts). The energy locally delivered to the distal end was 150 joules/0.5cm.

The procedure was performed under general anaesthesia or spinal anaesthesia after the first operation 2 to 12 months earlier (drainage of the fistula with seton placement). The fistula was first cleaned with a brush. The internal opening was obliterated with an X-point. The radiofrequency probe was introduced through the external to the internal opening. The radiofrequency was then initiated, causing a localised destruction of the tissues by vibration and heating. The probe was slowly withdrawn from the internal to the external opening by 0.5 cm/6 seconds (Figure 2). The wall destruction was of an expected thickness of 2-3 mm (as previously observed on ex vivo fistulas) in order not to damage the anal sphincters. There was no postoperative antibiotic prophylaxis. Post-operative care consisted of cleaning the skin with soft soap.

Statistical methods

In agreement with the Agence Nationale de Sécurité du Médicament (ANSM) and as this was a first exploratory study, no sample size calculation was performed. The objective was to accurately assess the results on the first 50 patients of a technique that had never been used to treat anal fistulas.

After consultation with the ANSM, by including 50 patients, we will be able to demonstrate a healing rate of 85% with a precision of 10%, corresponding to the range of the healing rate of fistulotomies, the gold standard. Statistical significance was set at 0.05. The risk of 1st order error alpha was set at 0.05. The analysis of associated factors was performed only in a univariate level because of the small population.

For numerical variables, the mean, standard deviation, median, minimum and maximum values were calculated. Student t test or the nonparametric Wilcoxon (2 groups) or Kruskal-Wallis (more than 2 groups) tests were used to compare the means between different groups. The Chi2 test or Fisher's exact test was used to compare the similarity of distributions between groups. Data entry was performed on computer, descriptive and analytical statistical analysis was performed by ClinSearch.

Ethical and legal aspects

This study received an authorisation from the ANSM on 11/01/2017. The Île-de-France IV Committee for the Protection of Individuals issued a favourable opinion on 10/28/16, according to articles L. 1123-6 and R. 1123-20 of the Public Health Code (N°ID-RCB 2016-A01107-44). At the request of the ANSM, an independent committee – in charge of analysing adverse events and device deficiencies – was set up, consisting of 3 proctology experts – not participating in the study – who could recommend stopping the study if necessary. An initial analysis was performed on the first 20 patients, which was included in the study to verify the absence of serious adverse events contraindicating the continuation of the clinical trial. The results were submitted to this committee and then to the ANSM, before continuing the inclusions of 50 patients in total. All patients gave written consent, and the study was approved by the Commission Nationale de l'Informatique et des Libertés (CNIL).

Results

Demographics and description of fistulas

From 7 March 2017 to 5 October 2018, 50 patients – of whom 17 were women – were included. One patient with a high trans-sphincteric fistula was excluded because of the discovery of non-drained tracts during the operation.

Overall, 49 patients were analysed, including 11 patients (22.4%) with low trans-sphincteric fistulas, 21 (42.9%) with high trans-sphincteric fistulas, 8 (16.3%) with complex fistulas and 9 (18.4%) with Crohn's fistulas. In addition, 10% of the patients had multiple fistulas and were classified under the most severe stratum (LTS< HTS< C < CD). The demographic characteristics of the patients were comparable between the different types of fistulas (Table 1). The median length of the fistula was of 35 mm (15-85 mm), increasing with the complexity of the fistula. Most of the patients had a single external opening (90%). An abscess had been previously drained for 22 patients and a diverticulum > 5 mm had been drained for 17 patients. A previous sphincter-sparing treatment had been performed for 12 patients with 2 associated techniques in 6 of them. Overall, 10 patients had a history of anal surgery and 5 women had a vaginal delivery.

Healing at 6 and 12 months

At 6 months, 17 patients (34.7%) had a healed fistula, with clinical symptoms disappearing after 67 days [14-239]. Of those, 5 (45.5%) had LTS fistulas, 7 (33.3%) HTS fistulas, 1 (12.5%) complex fistula, 4 (44.4%) with CD without significant difference between these different strata ($p:0.142$). Unhealed patients were 32 (65.3%), of which 16 (32.7%) presented the narrowing of one or both orifices without complete closure.

At 12 months, the result was maintained with 17 healed patients (34.7%), one recurrence after healing at 6 months and one late healing at 12 months.

MRI results

MRI was performed in clinically healed patients to determine deep healing. At 6 months, 13 clinically healed patients had an MRI which showed deep healing in 7 patients (53.8%), without significant difference between fistula stratum. A new MRI was performed at 12 months in 15 out of the 17 clinically healed patients: 11 (73.3%) of them were confirmed deeply healed (Figure 3).

Adverse effects and complications

Complications after radiofrequency treatment were observed in 4 (8.2%) patients. However, in immediate postoperative period, 2 patients developed a local infection, one required antibiotic treatment (HTS fistula) and the other one required a second surgery (complex fistula). No bleeding or acute urinary retention was reported in postoperative period. At 6 months, there were 3 (6.8%) recurrences with abscesses and at 12 months, 2 additional abscesses were reported. These patients were considered failures.

Postoperative pain was low with a median pain of 1/10 [0-10] during the first week. By the 2nd postoperative week, the median was 0/10 [0-10]. Analgesic use was next to nothing (median use of level one analgesic pills in the first week was 0[0-8]).

Anal incontinence

Anal continence scores were decreasing after radiofrequency treatment. The median Vaizey score was 5 at M0, 1.5 at M6 and 0 at M12. At 12 months, no patient described anal incontinence.

Predictive factors of success

The first factor associated with success was energy. The median energy used during the procedure was 1500 joules (J) [425-8775], with no significant difference according to the type of fistula (1537.5 J for TSI, 1375 J for TSS, 1475J for MC, 2250J for complex fistulas (p: 0.365)).

The energy power delivered during the procedure was higher among healed patients at 12 months, with a median of 2725 J (825-8775) versus 1325 J (425-7225) among unhealed patients (p: 0.049) (Table 2).

There was no correlation between the energy delivered and the size of the fistula. More energy was used in healed patients independently of the length and width of the fistula. This power was significantly higher in the centre with the best healing rate (median joule/patient at 3137.5J [975.0 - 8775] versus 1325.0 J [425-5800] and 1275 J [575-7825] for the other two (p: 0.032)).

A centre effect was clearly observed for success rate at 6 and 12 months follow-up. At 6 months, fistula closure occurred in 50% (16 patients) of the patients in centre B, 33% (21 patients) in centre A and 16.7% (2 patients) in centre C (p: 0.016), with the same differences results at 12 months.

Age at surgery, gender, previous fistula treatment and fistula size did not influence the prognosis.

Patient's satisfaction after surgery

The self-evaluation at 6 months revealed an overall comfort level with a median of 2 [0-9] (0: no discomfort and 10: maximum discomfort), with no significant difference between healed and unhealed patients (p: 0.74).

The level of post-surgical anal discomfort was low with a median of 1/10 [0-10], with no difference between healed and unhealed patients (p: 0.403). Overall, 64.5% of the patients were satisfied with the procedure and 96.8% would repeat the procedure if necessary. At 12 months, 67.8% of the patients (scarred or not) were satisfied with the surgery and 92.9% would repeat the technique if necessary.

Discussion

This first prospective multicentre study evaluating radiofrequency in the treatment of anal fistulas included fistulas that could benefit from sphincter-sparing treatment. Results have shown lower success than expected: fistula healing was effective in 34.7% of the patients at 6 and 12 months. Our

criteria were strict to evaluate success and potential morbidity. They included regular follow-up with 2 assessments at 6 and 12 months to evaluate relapses, MRI analysis of all healed fistulas to evaluate deep healing and continence evaluation by validated scores (Wexner and Vaizey scores). Few side effects were reported (8.2%) and recurrences in the form of abscesses were rare (3 [6,1%] at 6 months). Post-operative pain was low, allowing a rapid return to activities, which may be an advantage compared to progressive fistulotomy, which requires repeated post-operative care and time off work.

These results are superior to a previous case-control retrospective study comparing radiofrequency treatment and advancement flap (34) which showed healing in 25.8% of the cases, with a median follow-up of 5 months. Post-operative complications were higher (three abscesses, a haematoma and a thermal ulceration with a recto-vaginal fistula). Complex fistulas were mainly included after failure of other treatments, which could explain the difference with our study. Recurrence after radiofrequency was early and occurred in the first month, while in our study after healing at 6 months, only one relapse was observed.

Also, the presence of Crohn's disease was a criterion of good response. In our study, healing rate in this subgroup was slightly higher, although not significant: 4 healed of 9 patients with Crohn's disease (44.4%) vs 13 healed on 40 (32,5%) in no Crohn. The laser, the other techniques that use this same process of fistula wall destruction, seem to reveal the same tendency (35). In many studies, Crohn's disease is a negative factor of the effectiveness of the obstruction treatments (36,37). These new types of treatment could be interesting for this progressive and recurrent disease where a non-aggressive treatment is preferable.

Regarding recent tract destruction techniques, laser, for example, was very promising in first studies with initial healing rates between 71.4% and 90% (38,39). But the success rate was between 33% and 64.1% in subsequent studies (40,41). A recent French study showed healing in 45.6% of the 69 patients, with a median follow-up of 6.3 months (42). Unfortunately, these studies did not evaluate deep healing by MRI. Laser and radiofrequency could have a very close efficacy with the same strategy but it is possible that radiofrequency would have the advantage of a more localised destruction and an easier passage of some complex curves because of its flexibility.

One advantage of our study was the evaluation of deep efficacy by MRI at 6 and 12 months in clinically healed patients. Indeed, a fistula can close clinically but remain active in depth; an extinct fistula on MRI has been shown to have long term healing. It is a marker of deep remission in Crohn's disease (43). MRI evaluation is rarely performed in other studies as shown by these meta-analysis on the laser technique (21). Our study shows an evolution of complete healing: 53.8% of patients clinically healed at 6 months and 73.3% at 12 months. This could suggest a slow healing process.

The other advantages are the multicentric design, rarely done in the evaluation of other destruction techniques (44). We assessed continence by the usual scores. Incontinence covers a wide variety of symptoms and the use of reproducible scores is recommended. We observed an improvement of the Wexner score from 2 preoperatively to 0.5 at 6 months. This improvement is probably related to the decrease in leakage from the fistula itself after treatment. No new cases or worsening of pre-existing anal incontinence were reported during the follow-up. This new sphincter-sparing technique destroying the walls of the fistula does not seem to involve a risk of anal incontinence.

Most importantly, the number of joules used during the procedure was identified as a predictive factor of success, regardless of fistula size. For future studies, the objective will be to optimise cauterisation by increasing this parameter. Radiofrequency permits the disintegration of cells by transforming them into dense connective tissue in a very localised way. Therefore, increasing the power will probably allow low heat diffusion in the surrounding tissue and decrease risk for underlying sphincters. Large, multi-operated fistulas and the number of previous repair attempts

were not significantly associated with a less favourable outcome in contrast to other techniques, such as biological glue (18).

The limitation of this preliminary study was the small size of our population with a small sample size for each of the subgroups, which did not allow for a multivariate analysis (factors predicting response to treatment) and possibly a lack of statistical power. Future studies may analyse more specifically results in one type of fistula, such as Crohn disease. In addition, a centre effect was found. The treatment achieved healing in only 8.3% in one of the centres compared with 50% and 38% at 12 months in the other two (p: 0.049). We cannot explain this difference because the technique was identical in all centres, except for the absence of bottom scraping in the centre with 50% healing and the injection of iced saline before the procedure in the centre with 8.3% healing. In the centre with the lowest rate of healing, the population had a – not statistically different – higher rate of complex fistulas (41.7% versus 4.8% and 12.5%) and more previous sphincter-sparing treatment.

Conclusion

This first prospective study evaluating radiofrequency treatment in anal fistulas shows clinical healing in 17 of 49 patients (34.7%) at one year with a centre effect. The clinical healing was confirmed by MRI in 11 patients out of 15 (73,3%) at one year. This technique is minimally invasive, simple, inexpensive and easy to learn. With a low morbidity, radiofrequency seems to be a new tool for fistula treatment. In the future, optimisation of this technique is necessary. The increase in energy during the procedure seems to be an essential point to be analysed.

Acknowledgements

We are grateful for GREP (Groupe de Recherche En Proctologie de la SNFCP), Clinsearch and the independent committee (Philippe Godeberge, Thierry Higuero and Ghislain Staumont).

Abbreviation

ANSM: National Agency for the Safety of Medicines

C: complex

CD: Crohn's disease

HH: Horseshoe

HTS: High Trans-sphincter

IA: Anal incontinence

J: joule(s)

LTS: Low Trans-sphincteric

MRI: Magnetic Resonance Imaging

SL: Supralelevator

VAAFT: Video-assisted anal fistula treatment

Declaration

Availability of data and materials

The datasets during and/or analysed during the current study are available from the corresponding author on reasonable request.

Competing interests

The authors declare that they have no potential or actual conflicts of interest.

Funding

None

Authors' contributions

Conceptualisation: LA, DB, CF, FP, LS, Data curation: LA, DB, CF, FP, LS, CB, AL Formal analysis: JMF, MS, LA, CT. Investigation: MS, LA, DB, CF, FP, LS, CB, AL Resources: MS, LA, DB, CF, FP, LS, CB, CT, AL; Supervision: LA; Validation: MS, LA, DB, CF, FP, LS, CB, CT, AL; Visualisation: MS, LA, DB, CF, FP, LS, CB, CT, AL Manuscript writing: MS, LA

Tables and figures

Figure 1: Radiofrequency probe



Figure 2: Radiofrequency treatment procedure

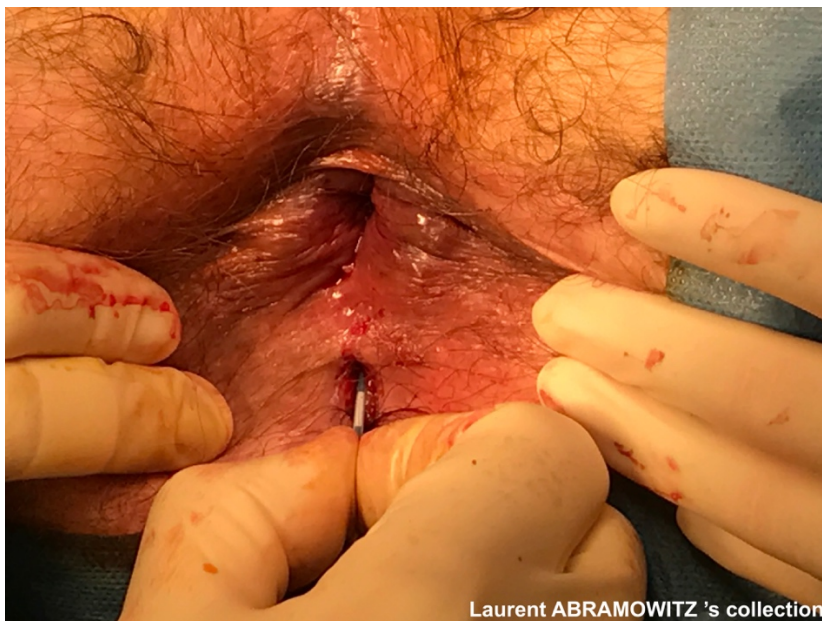

Figure 3 : Flow chart of clinical and MRI findings

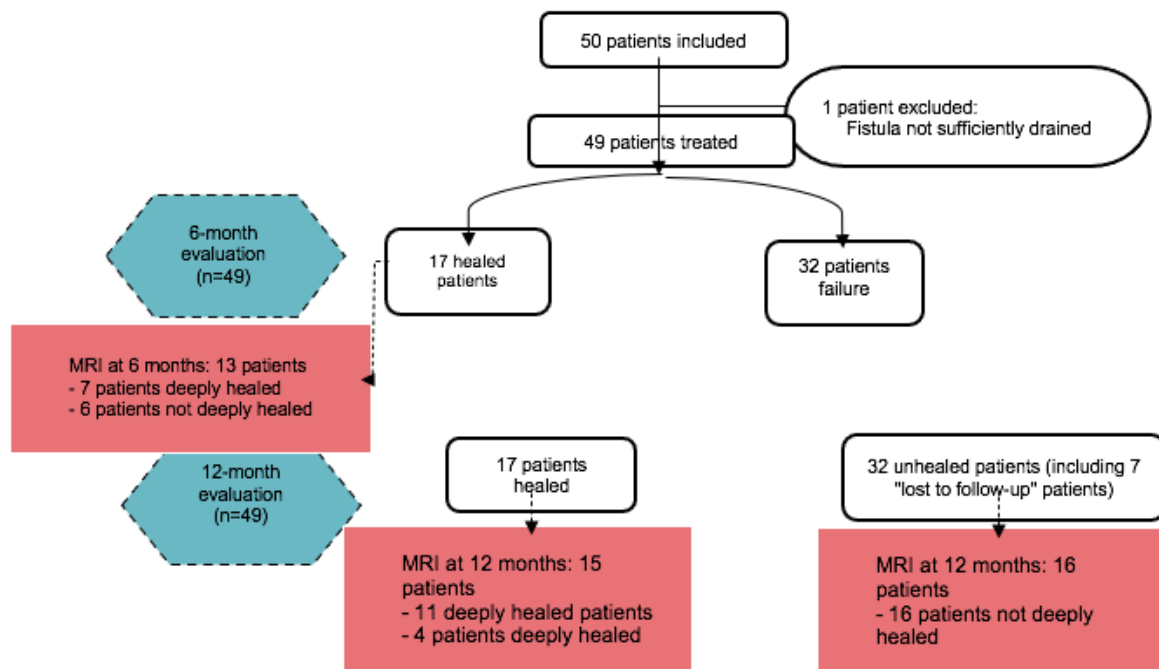


Table 1 - Demographic characteristics and description of fistulas

Gender	32 men (66%) 17 women (34%)
Age	22-82.6 (median: 51 years)
Classification by most severe stratum (n=49 patients)	11 LTS fistulas (22.4%) 21 HTS fistulas (42.9%) 8 C fistulas (16.3%) 9 CD fistulas (18.4%)
Classification by fistula type (n=58 fistulas)	14 LTS fistulas (24.1%) 35 HTS fistulas (60.3%) 3 supralelevator fistulas (5.2%) 3 horseshoe fistulas (5.2%) 3 Y fistulas (5.2%)
Median length (mm) by fistula type (n= 58 fistulas)	LTS fistulas: 30 mm (17-50) HTS fistulas: 38 mm (15-80) SL fistulas: 55 mm (18-85) HH fistulas: 45 mm (30-60) Y fistulas: 40 mm (40-40) Total: 35 mm (15-85)
Largest median diameter (mm) by fistula type (n= 58 fistulas)	Fistulas LTS: 5 mm (2-8) Fistulas HTS: 4 mm (2-8) Fistulas SL: 6 mm (2-7) Fistulas HH: 3 mm (2-4) Y fistulas: 3.5 mm (3-4) Total: 4 mm (2-8)
Description Crohn's disease (n=11 fistulas*)	Fistulas LTS: 3 (27.3%) Fistulas HTS: 7 (63.6%) Fistulas HH: 1 (9.1%)
Previous sphincter-sparing treatments (n= 58 fistulas)	No treatment: 42 (72.4%) Biological glue: 5 (8.6%) Biological glue + other: 1 (1.7%) Biological glue + advancement flap: 5 (8.6%) Rectal advancement flap: 1 (1.7%) LIFT: 2 (3.4%) Other: 2 (3.4%)
Preoperative anal continence (N=49 patients)	Absence of solid urgency: 93% Absence of liquid urgency: 71.4%. Absence of gas leakage: 46.9%. No need for protection: 69.4%. Presence of oozing 55.1%.

LSI: low trans-sphincteric, HTS: high trans-sphincteric, CD: Crohn's disease, HH: horseshoe, SL: supralelevator.
 *9 patients : 8 patients with a single fistula and one patient with 3 fistulas.

Table 2 - Predictive factors of success and failure of treatment at 12 months

	Healed fistulas at 12 months (n =17)	Unhealed fistulas at 12 months (n=32)	Total (N=49)	p
Type of fistula				0.142
LTS fistulas	5 (45,5%)	6 (54,5%)	11 (22.4%)	
HTS fistulas	7 (33,3)	14(66,7)	21 (42.9%)	
C fistulas	1 (12,5)	7 (87,5)	8 (16.3%)	
CD fistulas	4 (44,4)	5 (55,6)	9 (18.4%)	
Median of joule (J)	2725,0 J (825-8775)	1325,0 J (425 – 7225)	1500 J (425 – 8775)	p: 0,049
Number of previous treatments				p: 0,396
0	15 (88,2%)	22 (68,8%)	37 (75,5%)	
1	1 (5,9%)	7 (21,9%)	8 (16,3%)	
2	1 (5,9%)	3 (9,4%)	4 (8,2%)	
Drained abscess?	N: 17	N: 31	N: 48	p: 0,181
No	7 (41,2%)	19 (61,3%)	16 (54,2%)	
Yes	10 (58,8%)	12 (38,7%)	22 (45,8%)	
Diverticula > 5 mm drained?	N=17	N: 30	N: 47	p: 0,925
No	11 (64,7%)	19 (63,3%)	30 (63,8%)	
Yes	6 (35,3%)	11 (36,7%)	17 (36,2%)	
Median of the maximum length (mm)	N: 16 40 mm (30-60)	N = 26 32,5 (15-85)	N = 41 36,5 (15-85)	p: 0,638
Median of the maximum diameter (mm)	N = 15 5,0 (2-8)	N = 26 4 (2-8)	N = 41 4,0 (2-8)	p: 0,070
Gender				p: 0, 774
Male	11 (33,3%)	22 (66,6%)	33 (100%)	
Female	6 (37,5%)	10 (62,5%)	16 (100%)	
Median age at time of procedure	45,9 (22 – 82,6)	53 (24 – 79,0)	51,0 (22,0-82,6)	p: 0,181

LSI: low trans-sphincteric, HTS: high trans-sphincteric, C: complex, CD: Crohn's disease,

References

- Hyman N, O'Brien S, Osler T. Outcomes after fistulotomy: results of a prospective, multicenter regional study. *Dis Colon Rectum*. déc 2009;52(12):2022-7.
- Steele SR, Kumar R, Feingold DL, Rafferty JL, Buie WD, Standards Practice Task Force of the American Society of Colon and Rectal Surgeons. Practice parameters for the management of perianal abscess and fistula-in-ano. *Dis Colon Rectum*. déc 2011;54(12):1465-74.
- Jordán J, Roig JV, García-Armengol J, García-Granero E, Solana A, Lledó S. Risk factors for recurrence and incontinence after anal fistula surgery. *Colorectal Dis*. mars 2010;12(3):254-60.
- Abramowitz L, Soudan D, Souffran M, Bouchard D, Castinel A, Suduca JM, et al. The outcome of fistulotomy for anal fistula at 1 year: a prospective multicentre French study. *Colorectal Dis*. mars 2016;18(3):279-85.
- Pearl RK, Andrews JR, Orsay CP, Weisman RI, Prasad ML, Nelson RL, et al. Role of the seton in the management of anorectal fistulas. *Dis Colon Rectum*. juin 1993;36(6):573-7; discussion 577-579.
- Blumetti J, Abcarian A, Quinteros F, Chaudhry V, Prasad L, Abcarian H. Evolution of treatment of fistula in ano. *World J Surg*. mai 2012;36(5):1162-7.
- Abramowitz L, Allez M, Devulder F, Faucheron JL, Ganansia R, Soudan D, Tarrerias AL. Guide pratique d'utilisation des colles de fibrines dans les fistules anales. Springer. 2010. (Collection SNFCP, en partenariat avec le GETAID et le CREGG).
- Damon H, Guye O, Seigneurin A, Long F, Sonko A, Faucheron JL, et al. Prevalence of anal incontinence in adults and impact on quality-of-life. *Gastroenterol Clin Biol*. janv 2006;30(1):37-43.
- Amato A, Bottini C, De Nardi P, Giamundo P, Lauretta A, Realis Luc A, et al. Evaluation and management of perianal abscess and anal fistula: SICCR position statement. *Tech Coloproctol*. févr 2020;24(2):127-43.

10. Garcia-Aguilar J, Belmonte C, Wong WD, Goldberg SM, Madoff RD. Anal fistula surgery. Factors associated with recurrence and incontinence. *Dis Colon Rectum*. juill 1996;39(7):723-9.
11. Lunniss PJ, Kamm MA, Phillips RK. Factors affecting continence after surgery for anal fistula. *Br J Surg*. sept 1994;81(9):1382-5.
12. Emile SH, Elfeki H, Thabet W, Sakr A, Magdy A, El-Hamed TMA, et al. Predictive factors for recurrence of high transsphincteric anal fistula after placement of seton. *J Surg Res*. 1 juin 2017;213:261-8.
13. Cirocchi R, Santoro A, Trastulli S, Farinella E, Di Rocco G, Vendettuali D, et al. Meta-analysis of fibrin glue versus surgery for treatment of fistula-in-ano. *Ann Ital Chir*. oct 2010;81(5):349-56.
14. Williams JG, MacLeod CA, Rothenberger DA, Goldberg SM. Seton treatment of high anal fistulae. *Br J Surg*. oct 1991;78(10):1159-61.
15. Ommer A, Herold A, Berg E, Fürst A, Post S, Ruppert R, et al. German S3 guidelines: anal abscess and fistula (second revised version). *Langenbecks Arch Surg*. mars 2017;402(2):191-201.
16. Stellingwerf ME, van Praag EM, Tozer PJ, Bemelman WA, Buskens CJ. Systematic review and meta-analysis of endorectal advancement flap and ligation of the intersphincteric fistula tract for cryptoglandular and Crohn's high perianal fistulas. *BJS Open*. 21 janv 2019;3(3):231-41.
17. de Parades V, Far HS, Etienney I, Zeitoun JD, Atienza P, Bauer P. Seton drainage and fibrin glue injection for complex anal fistulas. *Colorectal Dis*. mai 2010;12(5):459-63.
18. Witte ME, Klaase JM, Gerritsen JJGM, Kummer EW. Fibrin glue treatment for simple and complex anal fistulas. *Hepatogastroenterology*. juin 2007;54(76):1071-3.
19. Bubbers E, Cologne K. Management of Complex Anal Fistulas. *Clinics in Colon and Rectal Surgery*. 16 févr 2016;29(01):043-9.
20. Bleier JIS, Moloo H, Goldberg SM. Ligation of the intersphincteric fistula tract: an effective new technique for complex fistulas. *Dis Colon Rectum*. janv 2010;53(1):43-6.
21. Frountzas M, Stergios K, Nikolaou C, Bellos I, Schizas D, Linardoutsos D, et al. Could FiLaC™ be effective in the treatment of anal fistulas? A systematic review of observational studies and proportional meta-analysis. *Colorectal Disease*. 2020;22(12):1874-84.
22. Terzi MC, Agalar C, Habip S, Canda AE, Arslan NC, Obuz F. Closing Perianal Fistulas Using a Laser: Long-Term Results in 103 Patients. *Dis Colon Rectum*. mai 2018;61(5):599-603.
23. Meinero P, Mori L. Video-assisted anal fistula treatment (VAAFT): a novel sphincter-saving procedure for treating complex anal fistulas. *Tech Coloproctol*. déc 2011;15(4):417-22.
24. Garg P, Singh P. Video-Assisted Anal Fistula Treatment (VAAFT) in Cryptoglandular fistula-in-ano: A systematic review and proportional meta-analysis. *Int J Surg*. oct 2017;46:85-91.
25. Lohsiriwat V, Yodying H, Lohsiriwat D. Incidence and factors influencing the development of fistula-in-ano after incision and drainage of perianal abscesses. *J Med Assoc Thai*. janv 2010;93(1):61-5.
26. Bouchard D. RECOMMANDATIONS POUR LA PRATIQUE CLINIQUE DES LESIONS ANO-PERINEALES DE LA MALADIE DE CROHN.
27. Eddama MMR, Everson M, Renshaw S, Taj T, Boulton R, Crosbie J, et al. Radiofrequency ablation for the treatment of haemorrhoidal disease: a minimally invasive and effective treatment modality. *Tech Coloproctol*. août 2019;23(8):769-74.
28. Casana R, Tolva VS, Odero A, Malloggi C, Parati G. Three-year follow-up and quality of life of endovenous radiofrequency ablation of the great saphenous vein with the ClosureFast™ procedure: Influence of BMI and CEAP class. *Vascular*. oct 2018;26(5):498-508.
29. Spiliopoulos S, Theodosiadou V, Sotiriadi A, Karnabatidis D. Endovenous ablation of incompetent truncal veins and their perforators with a new radiofrequency system. Mid-term outcomes. *Vascular*. déc 2015;23(6):592-8.
30. Gupta PJ. Radiosurgical fistulotomy; an alternative to conventional procedure in fistula in ano. *Curr Surg*. oct 2003;60(5):524-8.
31. Filingeri V, Gravante G, Cassisa D. Clinical applications of radiofrequency in proctology: a review. *Eur Rev Med Pharmacol Sci*. avr 2006;10(2):79-85.
32. Xiarchos A, Tshijanu F, Tsakpini A. Endoscopic Radiofrequency Ablation of Fistula in Ano (E-RaFisTura) in the Era of Surgical Innovation. A Serial Prospective Evaluation of 10 Patients. *Gastroint Hepatol Dig Dis [Internet]*. 30 déc 2021 [cité 7 juin 2022];4(1). Disponible sur:

<http://scivisionpub.com/pdfs/endoscopic-radiofrequency-ablation-of-fistula-in-ano-er-fistura-in-the-era-of-surgical-innovation-a-serial-prospective-evaluation--1978.pdf>

33. Vaizey CJ, Carapeti E, Cahill JA, Kamm MA. Prospective comparison of faecal incontinence grading systems. *Gut*. janv 1999;44(1):77-80.
34. Merlini l'Héritier A, Siproudhis L, Bessi G, Le Balc'h E, Wallenhorst T, Bouguen G, et al. Sphincter-sparing surgery for complex anal fistulas: radiofrequency thermocoagulation of the tract is of no help. *Colorectal Dis*. août 2019;21(8):961-6.
35. Wilhelm A, Fiebig A, Krawczak M. Five years of experience with the FiLaC™ laser for fistula-in-ano management: long-term follow-up from a single institution. *Tech Coloproctol*. avr 2017;21(4):269-76.
36. de Groof EJ, Sahami S, Lucas C, Ponsioen CY, Bemelman WA, Buskens CJ. Treatment of perianal fistula in Crohn's disease: a systematic review and meta-analysis comparing seton drainage and anti-tumour necrosis factor treatment. *Colorectal Dis*. juill 2016;18(7):667-75.
37. Williams G, Williams A, Tozer P, Phillips R, Ahmad A, Jayne D, et al. The treatment of anal fistula: second ACPGBI Position Statement – 2018. *Colorectal Disease*. 2018;20(S3):5-31.
38. Giamundo P, Geraci M, Tibaldi L, Valente M. Closure of fistula-in-ano with laser--FiLaC™: an effective novel sphincter-saving procedure for complex disease. *Colorectal Dis*. févr 2014;16(2):110-5.
39. Giamundo P, Esercizio L, Geraci M, Tibaldi L, Valente M. Fistula-tract Laser Closure (FiLaC™): long-term results and new operative strategies. *Tech Coloproctol*. août 2015;19(8):449-53.
40. Lauretta A, Falco N, Stocco E, Bellomo R, Infantino A. Anal Fistula Laser Closure: the length of fistula is the Achilles' heel. *Tech Coloproctol*. déc 2018;22(12):933-9.
41. Isik O, Gulcu B, Ozturk E. Long-term Outcomes of Laser Ablation of Fistula Tract for Fistula-in-Ano: A Considerable Option in Sphincter Preservation. *Dis Colon Rectum*. juin 2020;63(6):831-6.
42. Marref I, Spindler L, Aubert M, Lemarchand N, Fathallah N, Pommaret E, et al. The optimal indication for FiLaC® is high trans-sphincteric fistula-in-ano: a prospective cohort of 69 consecutive patients. *Tech Coloproctol*. sept 2019;23(9):893-7.
43. Garcia-Granero A, Granero-Castro P, Frasson M, Flor-Lorente B, Carreño O, Espí A, et al. Management of cryptoglandular supralelevator abscesses in the magnetic resonance imaging era: a case series. *Int J Colorectal Dis*. déc 2014;29(12):1557-64.
44. Elfeki H, Shalaby M, Emile SH, Sakr A, Mikael M, Lundby L. A systematic review and meta-analysis of the safety and efficacy of fistula laser closure. *Tech Coloproctol*. avr 2020;24(4):265-74.