



HAL
open science

Saksenaea erythrospora infection after medical tourism for esthetic breast augmentation surgery

José Rodríguez, Gerson Rodríguez, Soraya Morales-López, Carlos Cantillo, Patrice
Le Pape, Carlos Alvarez-Moreno

► **To cite this version:**

José Rodríguez, Gerson Rodríguez, Soraya Morales-López, Carlos Cantillo, Patrice Le Pape, et al.. Saksenaea erythrospora infection after medical tourism for esthetic breast augmentation surgery. International Journal of Infectious Diseases, 2016, 49, pp.107-110. <10.1016/j.ijid.2016.05.032>. <hal-03800624>

HAL Id: hal-03800624

<https://hal.science/hal-03800624v1>


Submitted on 18 Sep 2024

HAL is a multi-disciplinary open access archive for the deposit and dissemination of scientific research documents, whether they are published or not. The documents may come from teaching and research institutions in France or abroad, or from public or private research centers.

L'archive ouverte pluridisciplinaire **HAL**, est destinée au dépôt et à la diffusion de documents scientifiques de niveau recherche, publiés ou non, émanant des établissements d'enseignement et de recherche français ou étrangers, des laboratoires publics ou privés.



Distributed under a Creative Commons CC BY-NC-ND 4.0 - Attribution - Non-commercial use - No
Derivative Works - International License



Saksenaea erythrospora infection after medical tourism for esthetic breast augmentation surgery[☆]



José Y. Rodríguez^a, Gerson J. Rodríguez^a, Soraya E. Morales-López^b, Carlos E. Cantillo^a, Patrice Le Pape^{c,d}, Carlos A. Álvarez-Moreno^{e,*}

^a Centro de Investigaciones Microbiológicas del Cesar (CIMCE), Clínica Médicos S.A., Valledupar, Colombia

^b Departamento de Microbiología, Universidad Popular del Cesar, Valledupar, Colombia

^c Département de Parasitologie-Mycologie, Université de Nantes, Nantes Atlantique Universités, EA1155-IICiMed, Faculté de Pharmacie, Nantes, France

^d Laboratoires de Parasitologie-Mycologie, Institut de Biologie, CHU de Nantes, France

^e Unidad de Enfermedades Infecciosas, Departamento de Medicina Interna, Facultad de Medicina, Universidad Nacional de Colombia. Clínica Universitaria Colombia, Av calle 127 No. 20-78, Oficina 508, Colsanitas S.A., Bogotá, Colombia

ARTICLE INFO

Article history:

Received 27 April 2016

Received in revised form 28 May 2016

Accepted 31 May 2016

Corresponding Editor: Eskild Petersen, Aarhus, Denmark.

Keywords:

Medical tourism

Mucormycosis

Saksenaea

Esthetic surgery

SUMMARY

Background: Mucormycosis caused by *Saksenaea erythrospora* is rarely reported in humans. Three previous cases have been reported in the literature, two associated with trauma (a sailing accident in Argentina and a combat trauma in Iraq) and one as a cause of invasive rhinosinusitis (India), all in immunocompetent patients. The first case of mucormycosis following esthetic surgery, associated with medical tourism, is reported herein.

Case report: A case study of an *S. erythrospora* infection in an immunocompetent woman after the completion of esthetic surgery (dermolipectomy and breast augmentation) is reported. The infection presented as a rapidly progressive necrotizing infection of the skin and soft tissue, which required a bilateral mastectomy and extensive surgical debridement associated with prolonged antifungal therapy. The organism was identified phenotypically and confirmed biologically after rDNA amplification and sequencing. Two months later, the patient remains hospitalized awaiting the start of reconstructive surgeries. The present case is, to the best of the authors' knowledge, the first report from Colombia.

Conclusions: Mucormycosis should be considered in the differential diagnosis of necrotizing infections of the skin and soft tissue that evolve rapidly after cosmetic surgery performed in tropical or subtropical countries.

© 2016 The Authors. Published by Elsevier Ltd on behalf of International Society for Infectious Diseases. This is an open access article under the CC BY-NC-ND license (<http://creativecommons.org/licenses/by-nc-nd/4.0/>).

1. Introduction

Mucormycosis is a rare infection caused by fungi of the order Mucorales.^{1,2} Mucormycosis typically occurs in patients with comorbidities such as neutropenia, hematological malignancy, diabetes, or steroid use. There are several different clinical manifestations of the infection, including rhinocerebral, pulmonary, gastrointestinal, cutaneous, or disseminated onset, which typically correlate with the predisposing condition.³

Rhizopus spp are the most common causes of invasive mucormycosis (50%), followed by *Mucor spp*, *Apophysomyces spp*, and *Lichtheimia spp*. *Saksenaea vasiformis* is responsible for less than 2% of these infections, most of which occur in tropical or subtropical climates.⁴

S. vasiformis was previously considered to be the only species of the genus, until the discovery of *Saksenaea oblongispora* and *Saksenaea erythrospora* in 2010.⁵ Although these fungi will grow on routine mycological media, they do not sporulate easily, which makes them difficult to identify. Therefore, the use of molecular methods based on PCR amplification and internal transcribed spacer (ITS) sequencing is necessary. Being a soil saprophyte, infections by these microorganisms are typically associated with a history of trauma, burns, bites, or animal bites. Additionally, these organisms have been associated with nosocomial infections, such as intramuscular injections, catheter-related bloodstream infections, and

[☆] The sequence obtained in this study was submitted to GenBank under accession number **KU951560**.

* Corresponding author. Tel.: +57 13143302367.

E-mail address: caalvarezmo@unal.edu.co (C.A. Álvarez-Moreno).

surgical site infections.^{6,7} More than 80% of *S. vasiformis* infections have been reported in previously healthy or nonimmunocompromised patients; these infections are clinically characterized by necrotizing fasciitis or cellulitis that rapidly spreads to the surrounding tissues.

2. Case report

A previously healthy 29-year-old Colombian woman with a history of dermolipectomy and breast augmentation performed in the city of Maracaibo, Venezuela presented fever and chills associated with pain and erythema in the surgical wound of the right breast on the fifth postoperative day. The patient underwent an operation for the removal of the breast implants, and broad-spectrum antibiotic therapy was initiated. The patient was admitted to the local hospital in Valledupar, Colombia on the ninth postoperative day due to the persistence of inflammatory signs in the right breast, leukocytosis (19×10^9 cells/l), and neutrophilia (80%). Blood and surgical wound cultures were taken, and antimicrobial therapy with meropenem and vancomycin was initiated. On the 11th postoperative day, a clinical deterioration was evident, and the patient reported increased pain at the surgical site; the presence of skin necrosis, with the production of pus in the right breast, was noted (Figure 1A). A radical right breast mastectomy, surgical debridement of the necrotic tissue, and drainage were performed. In addition, a sample was taken for histopathology studies and microbiological cultures. Following the surgical procedure, the patient was admitted to the intensive care unit for invasive mechanical ventilation and was given antibiotic management with tigecycline and cefepime.

Forty-eight hours later, the patient had an increased white blood cell count (64×10^9 cells/l), and a persistent clinical deterioration was evident. The left periareolar area was erythematous and there was soft tissue necrosis extending from the right

axillary line to the left breast and upper-third of the abdomen (Figure 1B). A radical left mastectomy and debridement of the necrotic tissue were then performed (Figure 1C).

Three sets of blood cultures were persistently negative for bacteria, and direct microbiological examination of the samples did not show the presence of fungi, bacteria, or mycobacteria (Gram and Ziehl–Neelsen stains were negative). In addition, cultures of the necrotic tissue for bacteria and mycobacteria did not show signs of microbial growth. However, the primary fungal culture of this clinical specimen showed the presence of mycelial fungi with no septate hyphae, suggestive of mucormycosis. Amphotericin B and caspofungin were thus added to the treatment regime. The patient was then transferred to a hospital with greater capabilities 72 h later for hyperbaric oxygen therapy. Two months later, the patient remains hospitalized awaiting the start of reconstructive surgeries.

The fungal isolate was incubated at 37 °C for 10 days in potato dextrose agar (PDA; Scharlab S.L, Barcelona, Spain), malt extract agar (MEA; Scharlab S.L), and Sabouraud–glucose agar (SDA; Scharlab S.L). Rapidly growing colonies with white aerial mycelia were found in all of the samples. Microscopic examination showed sterile broad non-septate hyphae with sporadic hemispherical columella (Figure 1D). Despite multiple cultures in various mycological media, it was not possible to obtain fungal sporulation. The strains were then subcultured in Czapek Dox agar (CZA; Oxoid, UK) and showed the presence of dichotomously branching rhizoids at the base of the hyaline sporangiophores and the typical flask-shaped sporangia (Figure 1E).

Histopathological analyses showed abundant granulated tissue with the foreign body reaction and multiple aseptate hyphae in the intravascular space with branching at right angles, suggestive of mucormycosis (Figure 1F). The fungal culture was sent to the Laboratorio Corpogen Corporation for molecular identification. This was performed by amplification and sequencing of the ITS and 5.8S RNA of the nuclear rDNA by PCR using the primers ITS1 (5'-TCC GTA

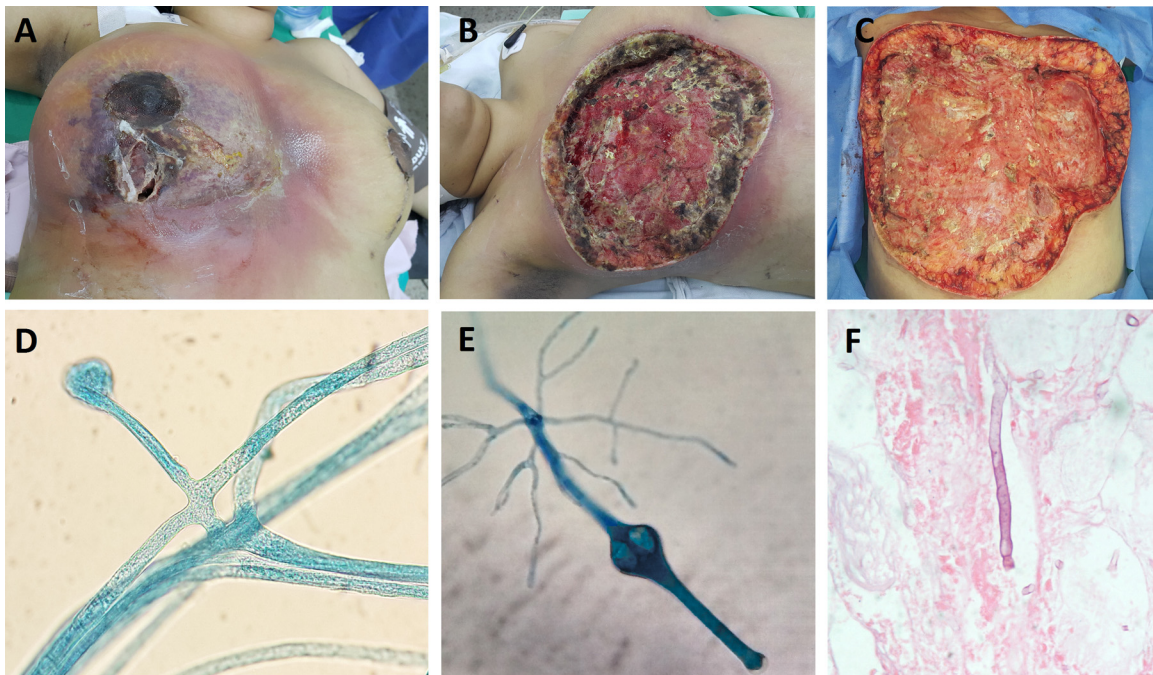


Figure 1. (A) Image showing the mammoplasty and dermolipectomy on the 11th postsurgical day; skin necrosis with the production of pus in the right breast is shown. (B) Postoperative image following mastectomy of the right breast. (C) Intraoperative image after mastectomy of the left breast and debridement of the surrounding skin and soft tissue. (D) Microscopic image of the fungal columella on PDA agar (40×). (E) Classical structures (sporangium, sporangiophore, rhizoids) of *Saksenea* spp on CZA agar (40×). (F) A section of the patient's skin and soft tissue infected with mucormycosis stained with hematoxylin and eosin, showing broad aseptate hyphae in the intravascular space with branching at right angles (40×).

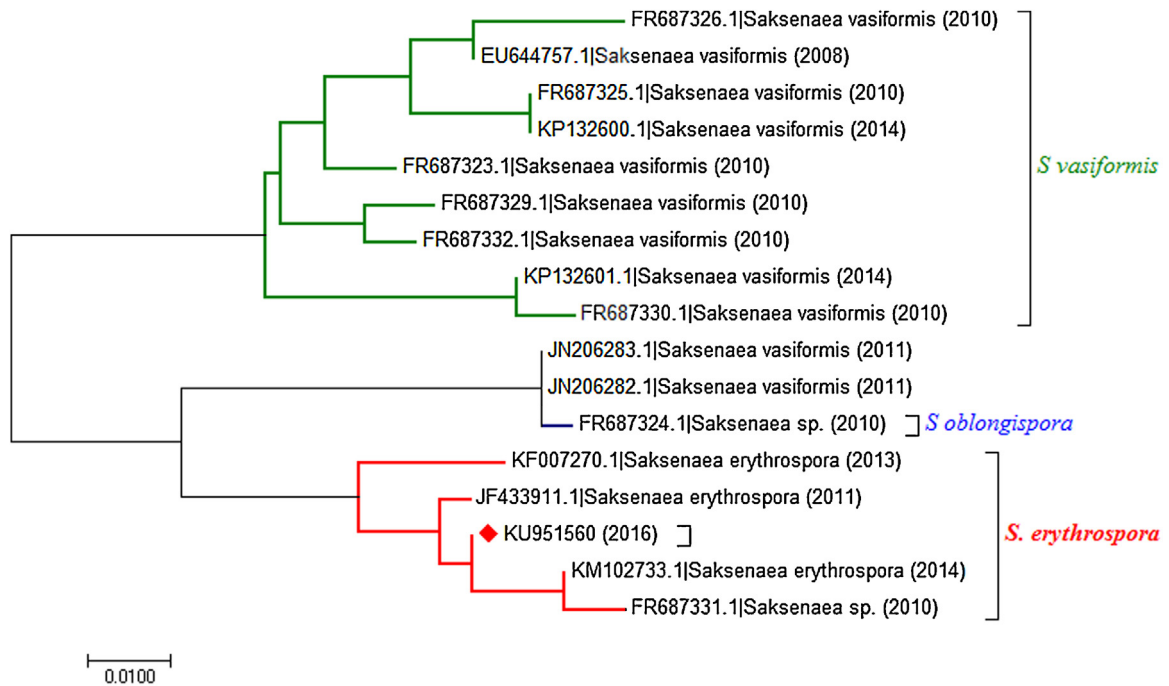


Figure 2. Phylogenetic trees were constructed using the 19 closest sequences, based on the information in the NCBI (nr/nt) database. **KU951560** corresponds to the nucleotide sequence analyzed.

GGT GAA CCT GCG G-3'), ITS4 (5'-TCC TCC GCT TAT TGA TAT GC-3'), and ITS 5 (5'-GGAAGTAAAAGTCGTAACAAGG-3'). The 768-bp sequencing product was compared with the GenBank database using BLASTN (National Center for Biotechnology Information (NCBI)) and UNITE. It showed 98.2% homology of its full-length sequence with the species *S. erythrospora* from the family *Saksenaeaceae* (Figure 2). The sequence obtained in this study was submitted to GenBank under accession number **KU951560**.

3. Discussion

This is the first case of mucormycosis following a breast augmentation procedure reported in the literature and the fourth reported case of a human infection caused by *S. erythrospora*. Two previous cases were associated with trauma (a sailing accident in Argentina and a combat trauma in Iraq) and one as a cause of invasive rhinosinusitis (India), all in immunocompetent patients.^{8–10}

The treatment of these infections should include aggressive surgical debridement, antifungal therapy, and correction of the predisposing condition when possible. It is incorrectly assumed that the antifungal treatment of mucormycosis is the same regardless of the species involved. However, for *Saksenaea spp.*, antifungal susceptibility testing has shown low minimum inhibitory concentrations (MICs) for posaconazole, itraconazole, and terbinafine and high MICs for amphotericin B, echinocandins, and voriconazole.⁵ These findings are important for selecting the appropriate treatment for these infections, particularly with the empirical use of amphotericin B. The utility of combining antifungal therapy, the use of a hyperbaric oxygen chamber, and interferon therapy is not entirely clear.^{6–9,11,12}

Medical tourism is an increasingly common activity that has many benefits, including lower cost, avoidance of long waiting times, and access to particular health services, technologies, or procedures. Many procedures may be unavailable in certain areas, too expensive, or not covered by local health systems, or may even

be considered illegal in some countries.^{13,14} Elective cosmetic procedures are the most common medical tourism surgeries, and the most frequent complication is infection of the surgical site.^{11,12} In addition, there is a risk of acquiring microorganisms with multidrug resistance profiles that may be unusual or not seen in the home country, with catastrophic complications such as those that occurred in the present case.^{13,14} It is noteworthy that the microbes that are most often associated with this type of surgical procedure are the non-tuberculous mycobacteria.¹³

Although many of the institutions involved in medical tourism work very well and are organized with high quality standards, many procedures may be performed in an unconventional way or in institutions that either do not meet the appropriate infection control standards or have minimal patient monitoring and post-surgical recovery times. It is necessary to advise patients on the procedure-related risks of medical tourism, including the risk of infection; in turn, physicians must be vigilant and suspect organisms based on the local epidemiological characteristics of the locations where the medical tourism procedures were performed.

In conclusion, mucormycosis should be considered in the differential diagnosis of necrotizing infections of the skin and soft tissue that evolve rapidly after cosmetic surgeries performed in tropical or subtropical countries. Physicians should advise patients on the prevention of surgical site infections, because the risk of such infections can be catastrophic and often fatal. Finally, this is the first report, to the authors' knowledge, of an infection with *S. erythrospora* in Colombia, confirming the presence of this Mucorales species in South America.

Author contributions

JR and CC were involved in the clinical management of this patient. SM helped with the microorganism identification process. All microbiological, histopathological, and molecular analyses were revised by SM, JR, GR, PL, and CA. This manuscript was

initially drafted by JR, GR, and CA, and then revised by the other authors of this study. All authors approved the final manuscript.

Acknowledgements

The authors express their sincere thanks to the Corpogen Corporation for the services provided in the molecular identification of the fungal isolates.

Ethics statement: Written informed consent was obtained from the patient for the publication of this case report.

Conflict of interest: None of the authors report a conflict of interest, and there were no funding sources. All of the authors have submitted the ICMJE Form for the Disclosure of Potential Conflicts of Interest.

References

1. Kwon-Chung KJ. Taxonomy of fungi causing mucormycosis and entomophthoramycesis (zygomycosis) and nomenclature of the disease: molecular mycologic perspectives. *Clin Infect Dis* 2012;**54**(Suppl 1):S8–15.
2. Pozo Laderas JC, Pontes Moreno A, Pozo Salido C, Robles Arista JC, Linares Sicilia MJ. Disseminated mucormycosis in immunocompetent patients: a disease that also exists. *Rev Iberoam Micol* 2015;**32**:63–70.
3. Severo CB, Guazzelli LS, Severo LC. Chapter 7: zygomycosis. *J Bras Pneumol* 2010;**36**:134–41.
4. Kennedy KJ, Daveson K, Slavin MA, van Hal SJ, Sorrell TC, Lee A, et al. Mucormycosis in Australia: contemporary epidemiology and outcomes. *Clin Microbiol Infect* 2016 .
5. Alvarez E, Garcia-Hermoso D, Sutton DA, Cano JF, Stchigel AM, Hoinard D, et al. Molecular phylogeny and proposal of two new species of the emerging pathogenic fungus *Saksenaea*. *J Clin Microbiol* 2010;**48**:4410–6.
6. Gomes MZ, Lewis RE, Kontoyiannis DP. Mucormycosis caused by unusual mucormycetes, non-*Rhizopus*, -*Mucor*, and -*Lichtheimia* species. *Clin Microbiol Rev* 2011;**24**:411–45.
7. Chakrabarti A, Kumar P, Padhye AA, Chatha L, Singh SK, Das A, et al. Primary cutaneous zygomycosis due to *Saksenaea vasiformis* and *Apophysomyces elegans*. *Clin Infect Dis* 1997;**24**:580–3.
8. Relloso S, Romano V, Landaburu MF, Herrera F, Smayevsky J, Vecino C, et al. *Saksenaea erythrospora* infection following a serious sailing accident. *J Med Microbiol* 2014;**63**(Pt 2):317–21.
9. Hospenthal DR, Chung KK, Laird K, Thompson EH, Guarro J, Renz EM, et al., *Saksenaea erythrospora* infection following combat trauma. *J Clin Microbiol* 2011;**49**:3707–9.
10. Tendolkar U, van Diepeningen A, Joshi A, Koomen J, Bradoo R, Baveja S, et al. Rhinosinusitis caused by *Saksenaea erythrospora* in an immunocompetent patient in India: a first report. *JMM Case Rep* 2015;**2**:1–4.
11. Danion F, Aguilar C, Catherinot E, Alanio A, DeWolf S, Lortholary O, et al. Mucormycosis: new developments into a persistently devastating infection. *Semin Respir Crit Care Med* 2015;**36**:692–705.
12. Peman J, Quindos G. [State of the art in invasive diseases by filamentous fungi]. *Rev Iberoam Micol* 2014;**31**:213–8.
13. Nelson R. Infectious risks of medical tourism. *Lancet Infect Dis* 2014;**14**:680–1.
14. Cai SS, Chopra K, Lifchez SD. Management of *Mycobacterium abscessus* infection after medical tourism in cosmetic surgery and a review of literature. *Ann Plast Surg* 2016.