



**HAL**  
open science

## **HCV eradication does not protect from fibrosis progression in patients with fibrosing cholestatic hepatitis after liver transplantation**

Audrey Coilly, Mylene Sebah, C. Fougerou-Leurent, Georges-Philippe Pageaux, Vincent Leroy, Sylvie Radenne, Christine Silvain, Pascal Lebray, Pauline Houssel-debry, Carole Cagnot, et al.

### ► To cite this version:

Audrey Coilly, Mylene Sebah, C. Fougerou-Leurent, Georges-Philippe Pageaux, Vincent Leroy, et al.. HCV eradication does not protect from fibrosis progression in patients with fibrosing cholestatic hepatitis after liver transplantation. *Clinics and Research in Hepatology and Gastroenterology*, 2022, 46 (9), pp.102024. 10.1016/j.clinre.2022.102024 . hal-03799246

**HAL Id: hal-03799246**

**<https://hal.science/hal-03799246>**

Submitted on 21 Feb 2023

**HAL** is a multi-disciplinary open access archive for the deposit and dissemination of scientific research documents, whether they are published or not. The documents may come from teaching and research institutions in France or abroad, or from public or private research centers.

L'archive ouverte pluridisciplinaire **HAL**, est destinée au dépôt et à la diffusion de documents scientifiques de niveau recherche, publiés ou non, émanant des établissements d'enseignement et de recherche français ou étrangers, des laboratoires publics ou privés.



Distributed under a Creative Commons Attribution - NonCommercial 4.0 International License

**HCV eradication does not protect from fibrosis progression in patients with fibrosing cholestatic hepatitis after liver transplantation**

Audrey Coilly<sup>1</sup>, Mylène Sebah<sup>2</sup>, Claire Fougerou-Leurent<sup>3</sup>, Georges-Philippe Pageaux<sup>4</sup>,  
Vincent Leroy<sup>5</sup>, Sylvie Radenne<sup>6</sup>, Christine Silvain<sup>7</sup>, Pascal Lebray<sup>8</sup>, Pauline Houssel-Debry<sup>9</sup>,  
Carole Cagnot<sup>10</sup>, Emilie Rossignol<sup>3</sup>, H el ene Danjou<sup>3</sup>, Aur elie Veislinger<sup>3</sup>, Didier Samuel<sup>1</sup>,  
Jean-Charles Duclos-Vall ee<sup>1</sup>, J er ome Dumortier<sup>11</sup>

**Short Title: Fibrosis progression after HCV fibrosing cholestatic hepatitis**

<sup>1</sup> AP-HP H opital Paul-Brousse, Centre H epato-Biliaire; Universit  Paris-Saclay, UMR-S 1193; Inserm Unit  1193; FHU Hepatinov, Villejuif, France

<sup>2</sup> AP-HP H opital Bic tre, Service d'Anatomie Pathologique, Kremlin-Bic tre, France

<sup>3</sup> Rennes University Hospital, Unit of Clinical Pharmacology; INSERM Clinical Investigation Centre 1414, Rennes, France

<sup>4</sup> CHU Saint-Eloi, D partement d'h epato-gastroent rologie et de transplantation h epatique; Universit  Montpellier 1, Montpellier, France

<sup>5</sup> CHU de Grenoble, P le Digidune, Clinique Universitaire d'H epato-Gastroent rologie; Unit  INSERM / Universit  Grenoble Alpes U823, IAPC Institut Albert Bonniot, Grenoble, France

<sup>6</sup> Hospices Civils de Lyon, H opital de la Croix Rouse, Service d'H epato-gastroent rologie, Lyon, France

<sup>7</sup> CHU de Poitiers, D partement d'H epato-gastroent rologie; EA 4331, P le Biologie Sant , Poitiers, France

<sup>8</sup> AP-HP, D partement d'h epatologie et de gastroenterologie, Groupe Hospitalier Piti -Salp triere, Universit  Pierre et Marie Curie Paris 6, Paris, France

<sup>9</sup> CHU Rennes, Service des Maladies du Foie, Rennes, France

<sup>10</sup> Unit for Basic and Clinical research on viral hepatitis, ANRS (France Recherche Nord&sud Sida-hiv Hépatites), Paris, France

<sup>11</sup> Hospices Civils de Lyon, Hôpital Edouard Herriot, Service d'Hépatogastroentérologie; Université Claude Bernard Lyon 1, Lyon, France

### Highlights

- Fibrosing cholestatic hepatitis is a rare and very severe form of HCV recurrence after liver transplantation.
- Prognosis of HCV recurrence after liver transplantation has been dramatically modified because of direct antivirals.
- Histological outcome of 17 patients has been studied.
- Fibrosis stage worsened in the majority of patients with fibrosing cholestatic hepatitis despite HCV cure.

**Abbreviations**

ANRS: Agence Nationale de Recherches sur le SIDA et les Hépatites Virales

CUPILT: Compassionate use of protease inhibitors in viral C in liver transplantation

DAA: Direct Acting Antivirals

FCH: Fibrosing Cholestatic Hepatitis

HCV: Hepatitis C Virus

HIV: Human Immunodeficiency Virus

IQR: Interquartile Range

LT: Liver Transplantation

RBV: Ribavirin

SVR: Sustained Virological Response

**Address for correspondence:**

- Jérôme Dumortier, MD, PhD,

Hôpital Edouard Herriot, Pavillons D et L,

69437 Lyon Cedex 03, France

Fax number: +33 (0)4 72 11 01 47

Phone number: +33 (0)4 72 11 01 11

E-mail: [jerome.dumortier@chu-lyon.fr](mailto:jerome.dumortier@chu-lyon.fr)

- Audrey Coilly, MD, PhD,

Centre Hépato-Biliaire, Hôpital Paul Brousse, APHP

94800 Villejuif, France

Fax number: +33 (0)1 45 59 38 57

Phone number: +33 (0)1 45 59 33 36

E-mail: [audrey.coilly@aphp.fr](mailto:audrey.coilly@aphp.fr)

**Disclosures:**

- Audrey Coilly has been a clinical investigator, speaker and/or consultant for Astellas, Bristol-Myers Squibb, Gilead Sciences, Janssen Pharmaceuticals, Novartis, Merck Sharp & Dohme and Abbvie.
- Vincent Leroy has been a clinical investigator, speaker and/or consultant for Abbvie, Bristol-Myers Squibb, Gilead Sciences, Janssen Pharmaceuticals, Merck Sharp & Dohme, and Roche.
- Mylène Sebagh has nothing to disclose.
- Claire Fougerou-Leurent has nothing to disclose.
- Georges-Philippe Pageaux has been a clinical investigator, speaker and/or consultant for Astellas, Bristol-Myers Squibb, Gilead Sciences, Janssen Pharmaceuticals, Merck Sharp & Dohme, Novartis and Roche.
- Sylvie Radenne has nothing to disclose.
- Christine Silvain has been a clinical investigator or speaker for Astellas, Bristol-Myers Squibb, Gilead Sciences, Janssen Pharmaceuticals, Abbvie, and Roche.
- Pascal Lebray has been a clinical investigator and speaker for Astellas, Bristol-Myers Squibb, Boehringer Ingelheim, Gilead Sciences, Janssen Pharmaceuticals and Roche.
- Pauline Houssel-Debry has been speaker and/or consultant for Astellas, Novartis and Gilead Sciences.
- Carole Cagnot has nothing to disclose
- Emilie Rossignol has nothing to disclose
- Hélène Danjou has nothing to disclose
- Aurélie Veislinger has nothing to disclose
- Jean-Charles Duclos-Vallée has been a clinical investigator, speaker and/or consultant for Astellas, Bristol-Myers Squibb, Gilead Sciences, Janssen Pharmaceuticals, Abbvie, Novartis and Roche.

- Jérôme Dumortier has been a clinical investigator, speaker and/or consultant for Astellas, Gilead Sciences, Janssen Pharmaceuticals, Novartis and Roche.

**Clinical Trial Identifier:** NCT01944527

**Grant support:** The study was sponsored and funded by The National Agency for Research on AIDS and Viral Hepatitis (ANRS, France Recherche Nord&sud Sida-hiv Hépatites).

**Title character count:** 150

**Overall manuscript word count:** 2566 (Abstract: 224)

**Author Contributions:**

Audrey Coilly, Vincent Leroy, Georges-Philippe Pageaux, Jean-Charles Duclos-Vallée and Jérôme Dumortier contributed to the conception and design of this study and to the preparation and finalization of the manuscript. Audrey Coilly, Georges-Philippe Pageaux, Sylvie Radenne, Christine Silvain, Pascal Lebray, Pauline Houssel-Debry, Vincent Leroy, Jean-Charles Duclos-Vallée and Jérôme Dumortier recruited patients into the study and participated in data collection and data analysis. Mylène Sebahg performed centralized histological review of liver biopsy specimens. Claire Fougerou-Leurent, Emilie Rossignol, Hélène Danjou, and Aurélie Veislinger contributed to data analysis. Carole Cagnot was in charge of regulatory aspects on behalf of the sponsor. All authors critically reviewed the article for important intellectual content and approved the final draft for submission.

**ABSTRACT**

**Introduction:** Hepatitis C virus (HCV) may recur after liver transplantation (LT) in the severe form of fibrosing cholestatic hepatitis (FCH). The prognosis dramatically improved by the use of direct acting antivirals (DAAs). The aim of the present study was to describe the change in histological features of FCH after virological eradication. **Methods:** From the ANRS CUPILT cohort we included 17 patients who presented FCH and at least two graft biopsies, one before DAA-treatment and one after. A single expert pathologist, blinded for clinical outcome, retrospectively confirmed the diagnosis of FCH and progression of fibrosis. **Results:** Diagnosis of FCH was made after a median [IQR] 6.0 [3.1-11.8] months after LT, and the median interval between diagnosis and onset of treatment was 1.2 [0.7-6.1] months. The rate of viral eradication was 94.1%. The median delay between the pre-treatment and the treatment biopsies was 12.5 [11.1-20.0] months. Between the end of treatment and the second biopsy, the delay was 5.3 [0.6-7.4] months. Fibrosis stage worsened in 10 patients (58.8%); 6 patients had cirrhosis (35.3%). Chronic rejection appeared in 4 (23.5%) patients. **Conclusion:** Our results suggest that, despite viral eradication in patients presenting FCH after LT, fibrosis progression was observed in half of patients. This should encourage monitoring fibrosis progression despite HCV cure.

**KEY WORDS:** liver transplantation; HCV; recurrence; fibrosing cholestatic hepatitis; treatment, pathology.

## Introduction

Liver disease associated with hepatitis C virus (HCV) infection used to be the main indication for liver transplantation (LT) worldwide [1]. The most frequent complication after LT is the recurrence of HCV infection and liver graft cirrhosis, which occurs in up to 20-30% of patients 5 years after LT [2, 3]. Fibrosing cholestatic hepatitis (FCH) is a rare form of recurrence and is characterized by portal and persinusoidal fibrosis and cholestasis leading to fast deterioration of the liver [4-7]. The rate of FCH is estimated to range from 2 to 10% with higher prevalence in HIV/HCV co-infected patients [8, 9].

In the era of interferon-based antiviral therapy, the prognosis of FCH was poor with 50 to 90% mortality rate at two years, and re-transplantation for this specific complication remained controversial because of frequently poor outcome [7, 8, 10]. The recent use of direct antiviral agents (DAA) dramatically changed the natural history of HCV recurrence after LT owing to both their antiviral potency and good tolerance. The CUPILT prospective cohort study enrolled transplanted patients with HCV-recurrence benefiting from second generation DAAs from 2013 to 2015 and found that these treatments were highly effective in LT patients, including those with severe HCV recurrence [11-13]. More specifically, we reported that sofosbuvir-based therapy could lead to virological eradication, clinical and biological improvement in most patients with FCH following LT with very good tolerance [14].

To date, no study reports on fibrosis outcome after viral eradication using DAA liver transplant patients. In non-transplant patients, the use of biopsy is uncommon to evaluate fibrosis stage, both before and after treatment. In liver transplant patients, biopsy is still performed to assess diagnosis of recurrence, stage fibrosis and exclude other specific conditions such as rejection, biliary and vascular complications. In this context, FCH is an interesting model for analyzing a change in fibrosis kinetics on the graft after DAA. The aim of the present study was to report histopathological findings after viral eradication in liver transplant patients, presenting FCH.



## Patients and methods

### *Study population and study design*

The ANRS CO23 CUPILT study was conducted in 25 French and Belgium LT centers (ClinicalTrials.gov number NCT01944527). To be included patients had to be transplanted for HCV-related liver complication and treated with second generation DAAs for HCV recurrence on the graft. Antiviral treatment regimens and duration were at the discretion of investigators. HCV eradication was defined as sustained virological response 12 weeks after the end of treatment (SVR12). The main exclusion criteria were age <18 and pregnancy. Written informed consent was obtained from each patient before enrolment. The study was conducted in accordance with the Declaration of Helsinki and French law for medical research and was approved by the “Sud Méditerranée I” Ethics Committee (France). From October 2013 to December 2015, 695 patients with HCV recurrence were included.

### *Diagnosis of FCH and histological outcome*

Were selected patients who were diagnosed by local investigators as having FCH and had undergone at least two graft biopsies, one before DAA-treatment and one after, in order to analyze histopathological changes. Patients presenting FCH have been previously identified and reported in the study of Leroy *et al.* [14]. In summary, three hepatologists (AC, VL, and JD) had reviewed patient records and an expert pathologist (MS) independently reviewed liver biopsy samples. The pathologist was blind of medical history, but was aware of the suspicion of FHC. Definite diagnosis was based on histological analysis of the initial liver biopsy. Diagnosis of FCH was retained only for patients meeting the criteria proposed by Verna *et al.* [15] that include elevated total bilirubin >34  $\mu\text{mol/L}$ , aspartate aminotransferase (AST) > 70 IU/L, and  $\gamma$  glutamyltransferase ( $\gamma\text{GT}$ ) serum levels >150 IU/mL at > 1 month after LT, detectable HCV-RNA in serum, no evidence of biliary complications on MRI cholangiography or of hepatic artery thrombosis.

Samples were fixed in formalin-, paraffin-embedded, and stained with hematein-eosin-safran and picrosirius. FCH was defined according to the histological criteria described by Davies *et al.* [4] and recently refined to include the presence of dense portal fibrosis with immature fibrous bands extending into the sinusoidal spaces, ductular proliferation, cholestasis, and hepatocyte ballooning with lobular disarray [8, 15]. Moreover, the severity and composition of the portal inflammatory infiltrate was assessed semi-quantitatively. Cholestasis and tissue changes due to cholestasis (hepatocellular bile pigment, canalicular bile plugs, Kupffer cell bile pigment, hepatocyte ballooning, as a sign of chronic cholestasis) were also noted. In addition, cholestasis and sinusoidal fibrosis were quantified according to the scoring systems described by Dixon *et al.* [16]. Liver fibrosis was assessed according to the METAVIR scoring system [17]. Therefore, F0 and F1 were grouped as mild, F2 as moderate, and F3 and F4 as severe fibrosis. Acute and chronic rejections were diagnosed according to the Banff classifications [18]. A diagnosis of “biliary obstruction” was based on a combination of portal edematous fibrosis, ductular proliferation, portal mixed inflammatory infiltrate, cholangiolitis, and cholestasis.

Changes, such as fibrosis stage and activity grade, degree of steatosis, rate of ductopenia, and onset of new disorders, between the pre- and post-treatment liver biopsies were assessed. In case of several biopsies were available after antiviral treatment, changes were considered between the initial and the last biopsy. The discordance between the initial (local) description of histopathological lesions from pathological reports and the current review was noted, regarding activity score, fibrosis stage and ductopenia.

### ***Statistical analysis***

Statistical analyses were performed using SAS statistical software (SAS Institute, Cary, NC, USA). Continuous variables are expressed as median and inter-quartile range (IQR). Categorical variables are expressed by the number of patients and percentages. Given the small sample size and the non-normal distribution of data, a repeated-measure analysis of variance (ANOVA) on ranks was used to test for

change over time for continuous variables; logistic regression models for repeated measures were constructed for categorical data. Differences between fibrosis progressions were evaluated using Mann-Whitney Wilcoxon test for continuous data and the Chi-square test or Fisher's exact test for categorical data. All statistical tests had a significance level of 0.05.

Journal Pre-proof

## Results

### *Patient characteristics*

The study population consisted of 17 patients who presented a FCH with available paired liver biopsies, before (at the time of the diagnosis) and after antiviral therapy. Initial (local) diagnosis of FCH was confirmed in all cases. Main characteristics are presented in Table 1. The majority was male and all but one was infected by genotype 1 HCV. Immunosuppression was mainly based on cyclosporine (52.9%) or tacrolimus (41.2%). Diagnosis of FCH was made after a median 6.0 [3.1-11.8] months after LT, and the median interval between diagnosis and onset of treatment was 1.2 [0.7-6.1] months. No patient had cirrhosis at baseline. The main antiviral therapy was combination of sofosbuvir, daclatasvir, and ribavirin (52.9%) for a total duration of 24 weeks in 88% of patients. All but one patient (94.1%) had SVR12.

### *Liver function outcome and survival*

Median follow-up after the end of antiviral treatment was 11.5 [11.0-12.0] months. As shown in Table 2, a significant improvement in clinical and laboratory liver function parameters was observed after antiviral treatment including bilirubin level.

Overall survival was 88.2% and graft survival was 82.4% at one year post-treatment. One patient died from hepatocellular carcinoma recurrence at week 60 and one patient died from sepsis at week 44. One patient was retransplanted because of decompensated cirrhosis at week 17.

### *Histological analysis*

An extensive description of histological elementary lesions is reported in Table 3. Some discrepancies between the local review and the centralized review of liver biopsies were identified in 10/34 biopsies. This mainly concerned with the fibrosis stage (it was mainly observed for fibrosis stage: 6 cases of 34). Regarding fibrosis stage, a discordance of one grade was observed in 4 cases, of 2 grades in 1, of 3 grades in 1. In addition, there were two cases of activity score discordance (of 1 grade), and two cases of initially unrecognized ductopenia.

The median delay between the pre-treatment biopsy and the second biopsy was 12.5 [11.1-20.0] months.

The median delay between the end of treatment and the second biopsy was 5.3 [0.6-7.4] months.

On the pre-treatment liver biopsies, there were 5 (29.4%) patients with METAVIR fibrosis stage F1, 9 (52.9%) with stage F2, and 3 (17.6%) with stage F3; there was 1 patient with activity score A0, 7 with score A1, 8 with score A2, and 1 with score A3. One pre-treatment liver biopsy found concomitant ductopenia (of 50%). There was no sign of acute cellular rejection.

On the post-treatment liver biopsy, there were 2 patients with METAVIR fibrosis stage F1, 9 with stage F2, and 6 with stage F4. Therefore, fibrosis progressed in 10 patients, was stable in 5 patients and decreased in 2 patients (Figure 1). There were 6 patients with activity score A0, 8 with score A1, 2 with score A2, and 1 with score A3. Therefore, activity decreased in 11 patients, was stable in 5 patients, and increased in 1 patient (Figure 1). There was no significant difference in the activity decrease between patients with fibrosis progression and those without (9/10 vs. 5/7,  $p=0.70$ ). Four patients showed the onset of a ductopenia on the post-treatment biopsy, with 27, 34, 52, 56% of missing bile ducts, respectively. One patient with ductopenia on the pre-treatment liver biopsy had the same degree of ductopenia on the post-treatment biopsy (i.e. 52% versus 50%). Histological features of chronic rejection were present in 4 (24%) patients. There was no sign of acute cellular rejection. Only one patient exhibited onset of macrovacuolar steatosis at 30%.

Clinically relevant parameters did not differ according to the progression of fibrosis or the absence of progression, except initial fibrosis stage (Table 4).

## Discussion

The present study is the first to describe the evolution of graft fibrosis after antiviral treatment in liver transplant patient who experienced the most severe form of HCV infection named FCH.

FCH used to be a life-threatening form of HCV recurrence after LT. The new era of antiviral treatment for FCH started with 2 cases for whom sofosbuvir-based therapy led to rapid jaundice and ascites resolution after treatment initiation [19, 20]. Thereafter, Forns *et al.* reported 10 patients with FCH, from whom 8/10 achieved SVR12 [21]. These promising results were confirmed in the first paper reporting the CUPILT cohort; the 23 patients with FCH experienced rapid and dramatic improvement in clinical status and all patients survived without re-transplantation until the end of follow-up (week 36). In addition, tolerance was good, with no grade 3 or 4 adverse events related to DAAs, and 22 patients (96%) achieved a SVR12 [14].

The present study is the first to focus on histological features of FCH. This was possible because second generation DAAs dramatically modified the prognosis of the disease, leading to long-term survival in most patients. Before these drugs became available, the expected short-term mortality rate was 50% with time between LT and death ranging from 2 to 10 months [7]. However, fibrosis worsened for most patients (58.8%) despite of the achievement of SVR and reversion of histological signs of FCH. We believe that these results are of great relevance, and somewhat surprising. It could be hypothesized that this was due to the rapid evolution of histological lesions before the start of antiviral therapy and subsequent HCV elimination. This is supported by the more rapid treatment initiation in patients who did not experience fibrosis progression (0.8 vs. 2.3 months) but the difference did not reach statistical significance, probably because of low statistical power. This is also supported by a slow virological response: only 27% of patients had undetectable HCV-RNA at W4 in our initial report [14]. In addition, significant histological lesions included ductopenia. The combined histological features of chronic rejection are in favor of immunologically mediated lesions rather than consequences of biliary damage associated with FCH. This

was probably not related to DAA-related drug-drug interactions, since sofosbuvir, daclatasvir, and ledipasvir are not reported to have any significant drug-drug interactions with calcineurin inhibitors [22]. Nevertheless, it could be hypothesized that immunosuppression had been reduced at the time of diagnosis of FCH because of initial liver function impairment together with high viral replication. Indeed, it has been suggested that FCH is related to direct viral cytotoxicity in the context of immunosuppression [23]. It cannot be totally excluded that ductopenia was not related to HCV treatment and FCH but to natural history post-transplantation since it is one of histological features which can be found on protocol liver biopsy after LT [24]. Finally, it could be hypothesized that the improvement of clinical condition could lead to a gain of weight and steatohepatitis features on the graft, which could worsen fibrosis progression. But, in the present study, there was no difference regarding diabetes or hypertension or BMI between patients who progressed versus not. The study period and small sample population are probably too short to observe such consequences.

The evolution of fibrosis, based on repeated liver biopsies, has been previously evaluated, in non-LT patients presenting chronic HCV hepatitis. In most cases, virological eradication led to improvement of histological lesions, especially fibrosis [25, 26]. Nevertheless, the regression of fibrosis seems to be a slow process in those who achieve a SVR but also to progress in some patients. For instance, in a recent study that included 97 patients who achieved SVR and who had paired liver biopsies, the stage of liver fibrosis had regressed in 44 patients (45%), remained stable in 47 patients (48%), and progressed in six patients (6%), a mean 5.8 years after treatment [27]. This suggests that, even if a FCH evolves much more rapidly than chronic hepatitis, a longer-term histological evaluation may be of great interest as the median delay between the 2 biopsies in the present study was only approximately 1 year.

The present study has several limitations. The first one is sample size, and it is of note that we included only patients of the CUPILT cohort with available paired liver biopsies, which may have induced selection bias. Nevertheless, FCH is a very rare entity. The liver biopsies were reviewed by a single expert

pathologist, but this made possible to analyze the discrepancies by comparison with the local results. The most important limitation is probably the use of the METAVIR scoring system but there is no specific score available for FCH and the METAVIR Scoring system is largely used and universally understood by clinicians, even outside the field of HCV-related chronic hepatitis. In particular, the METAVIR system does not account for perisinusoidal fibrosis. More generally, the global impact of the findings may be limited in the present context of massive eradication of HCV, and the related decrease in indications for LT [28]. Moreover, almost all LT HCV patients will now be transplanted after pre-LT virological eradication. Nevertheless, some patients will be transplanted with persistent HCV infection (*i.e.* in case of high MELD score or in order to access to HCV positive liver grafts). Therefore, the number of FCH cases will decrease but a risk will persist, and it is of note that this may also concern HCV recipients of other solid organ transplants. Finally, non-invasive tests were not usually done in the present cohort, probably because of their poor performance in LT recipients, especially in case of FCH [29].

In conclusion, the results suggest that, despite virological eradication and massive improvement of biological and clinical status of patients presenting FCH after LT, fibrosis progression is observed in half of the patients. This should encourage physicians to treat early, better control associated factors and monitor fibrosis progression despite HCV cure on long-term follow-up.



**Acknowledgements**

The authors gratefully thank all the patients and their families who participated to the study; and the physicians and research teams in participating centers for their active participation in screening, including, treating, and monitoring of the patients. We also thank Dr Philip Robinson, Direction de la Recherche et de l'Innovation, Hospices Civils de Lyon, for critically reading and editing the manuscript.

Journal Pre-proof

## References

1. Merion RM. Current status and future of liver transplantation. *Semin Liver Dis.* **30**, 2010; 411.
2. Berenguer M. Natural history of recurrent hepatitis C. *Liver Transpl.* **8**, 2002; S14.
3. Berenguer M, Prieto M, San Juan F, et al. Contribution of donor age to the recent decrease in patient survival among HCV-infected liver transplant recipients. *Hepatology.* **36**, 2002; 202.
4. Davies SE, Portmann BC, O'Grady JG, et al. Hepatic histological findings after transplantation for chronic hepatitis B virus infection, including a unique pattern of fibrosing cholestatic hepatitis. *Hepatology.* **13**, 1991; 150.
5. Zylberberg H, Carnot F, Mamzer MF, Blancho G, Legendre C, Pol S. Hepatitis C virus-related fibrosing cholestatic hepatitis after renal transplantation. *Transplantation.* **63**, 1997; 158.
6. Wiesner RH, Sorrell M, Villamil F. Report of the first International Liver Transplantation Society expert panel consensus conference on liver transplantation and hepatitis C. *Liver Transpl.* **9**, 2003; S1.
7. Narang TK, Ahrens W, Russo MW. Post-liver transplant cholestatic hepatitis C: a systematic review of clinical and pathological findings and application of consensus criteria. *Liver Transpl.* **16**, 2010; 1228.
8. Antonini TM, Sebah M, Roque-Afonso AM, et al. Fibrosing cholestatic hepatitis in HIV/HCV co-infected transplant patients-usefulness of early markers after liver transplantation. *Am J Transplant.* **11**, 2011; 1686.
9. Duclos-Vallee JC, Feray C, Sebah M, et al. Survival and recurrence of hepatitis C after liver transplantation in patients coinfecting with human immunodeficiency virus and hepatitis C virus. *Hepatology.* **47**, 2008; 407.
10. McCashland TM. Retransplantation for recurrent hepatitis C: positive aspects. *Liver Transpl.* **9**, 2003; S67.
11. Coilly A, Fougerou-Leurent C, de Ledinghen V, et al. Multicentre experience using daclatasvir and sofosbuvir to treat hepatitis C recurrence - The ANRS CUPILT study. *J Hepatol.* **65**, 2016; 711.
12. Dumortier J, Leroy V, Duvoux C, et al. Sofosbuvir-based treatment of hepatitis C with severe fibrosis (METAVIR F3/F4) after liver transplantation. *Liver Transpl.* **22**, 2016; 1367.
13. Houssel-Debry P, Coilly A, Fougerou-Leurent C, et al. 12 weeks of a Ribavirin-free Sofosbuvir and NS5A inhibitor regimen is enough to treat recurrence of hepatitis C after liver transplantation. *Hepatology.* 2018.

14. Leroy V, Dumortier J, Coilly A, et al. Efficacy of Sofosbuvir and Daclatasvir in Patients with Fibrosing Cholestatic Hepatitis C After Liver Transplantation. *Clin Gastroenterol Hepatol*. 2015.
15. Verna EC, Abdelmessih R, Salomao MA, Lefkowitz J, Moreira RK, Brown RS, Jr. Cholestatic hepatitis C following liver transplantation: an outcome-based histological definition, clinical predictors, and prognosis. *Liver Transpl*. **19**, 2013; 78.
16. Dixon LR, Crawford JM. Early histologic changes in fibrosing cholestatic hepatitis C. *Liver Transpl*. **13**, 2007; 219.
17. Intraobserver and interobserver variations in liver biopsy interpretation in patients with chronic hepatitis C. The French METAVIR Cooperative Study Group. *Hepatology*. **20**, 1994; 15.
18. Demetris AJ, Bellamy C, Hubscher SG, et al. 2016 Comprehensive Update of the Banff Working Group on Liver Allograft Pathology: Introduction of Antibody-Mediated Rejection. *Am J Transplant*. **16**, 2016; 2816.
19. Fontana RJ, Hughes EA, Bifano M, et al. Sofosbuvir and daclatasvir combination therapy in a liver transplant recipient with severe recurrent cholestatic hepatitis C. *Am J Transplant*. **13**, 2013; 1601.
20. Kim B, Trivedi A, Thung SN, Grewal P. Case report of successful treatment of fibrosing cholestatic hepatitis C with sofosbuvir and ribavirin after liver transplantation. *Semin Liver Dis*. **34**, 2014; 108.
21. Forns X, Charlton M, Denning J, et al. Sofosbuvir compassionate use program for patients with severe recurrent hepatitis C after liver transplantation. *Hepatology*. **61**, 2015; 1485.
22. Neant N, Solas C. Drug-Drug Interactions Potential of Direct Acting Antivirals for the treatment of Chronic Hepatitis C infection. *Int J Antimicrob Agents*. 2018.
23. Xiao SY, Lu L, Wang HL. Fibrosing cholestatic hepatitis: clinicopathologic spectrum, diagnosis and pathogenesis. *Int J Clin Exp Pathol*. **1**, 2008; 396.
24. Sebagh M, Samuel D, Antonini TM, et al. Twenty-year protocol liver biopsies: Invasive but useful for the management of liver recipients. *J Hepatol*. **56**, 2012; 840.
25. Serfaty L. Follow-up of patients with chronic hepatitis C and a sustained viral response. *Liver Int*. **36 Suppl 1**, 2016; 67.
26. van der Meer AJ, Berenguer M. Reversion of disease manifestations after HCV eradication. *J Hepatol*. **65**, 2016; S95.
27. Tachi Y, Hirai T, Miyata A, et al. Progressive fibrosis significantly correlates with hepatocellular carcinoma in patients with a sustained virological response. *Hepatol Res*. **45**, 2015; 238.

28. Belli LS, Berenguer M, Cortesi PA, et al. Delisting of liver transplant candidates with chronic hepatitis C after viral eradication: A European study. *J Hepatol.* **65**, 2016; 524.
29. Dumortier J, Besch C, Moga L, et al. Non-invasive diagnosis and follow-up in liver transplantation. *Clin Res Hepatol Gastroenterol.* **46**, 2022; 101774.

Journal Pre-proof

## Figure legends

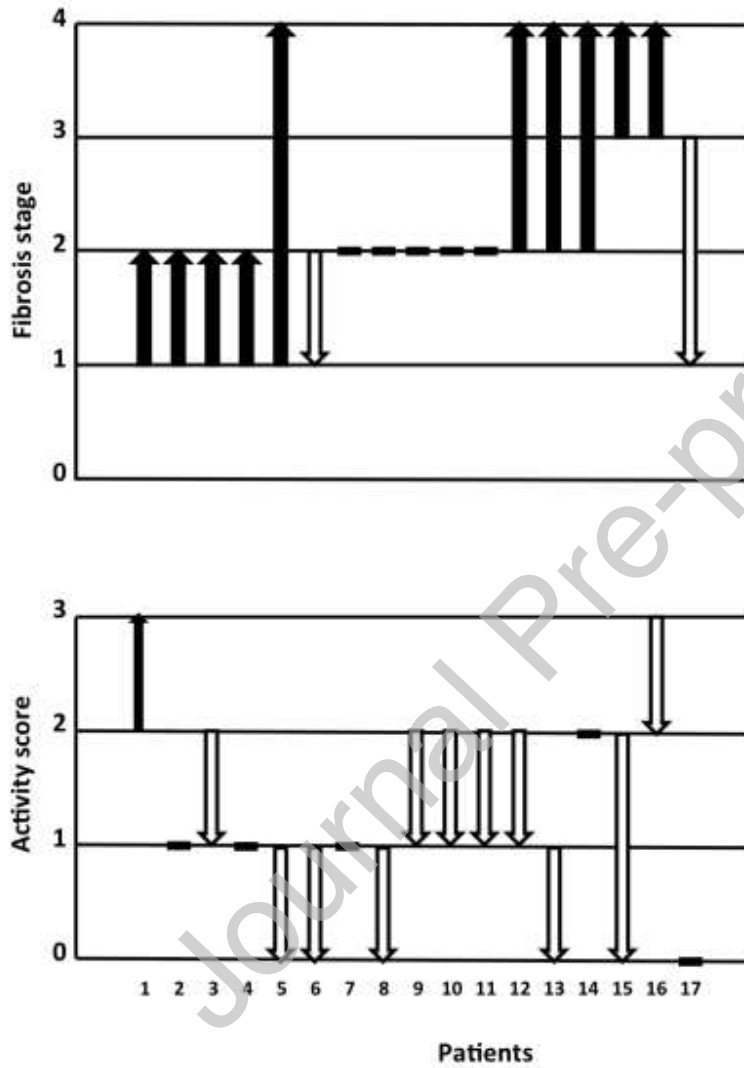


Figure 1: Evolution of histological features (activity score and fibrosis stage) from the paired liver biopsies (n=17).

**Table 1: Baseline characteristics of the 17 liver transplant patients**

	Total population, n=17
Median age, years [IQR]	55 [49-60]
Male gender, n (%)	12 (70.6)
Body mass index (Kg/m <sup>2</sup> , median and IQR)	21.9 [18.4-23.5]
Retransplantation (n, %)	2 (11.8)
Diabetes/Hypertension (n, %)	6 (35.3) / 10 (58.8)
Tacrolimus/Cyclosporine (n, %)	7 (41.2) / 9 (52.9)
HIV co-infection (n, %)	4 (23.5)
Genotype (n, %)	G1: 16 (94.1) / G4: 1 (5.9)
Interval (months, median and IQR)	
LT-FCH	6.0 [3.1-11.8]
FCH-DAA	1.2 [0.7-6.1]
DAA-2 <sup>nd</sup> biopsy	11.1 [9.2-13.5]
Total bilirubin (µmol/L, median and IQR)	72 [34-147]
PAL/GGT (IU/L, median and IQR)	222 [155-568] / 614 [200-1362]
AST/ALT (IU/L, median and IQR)	141 [83-226] / 120 [49-188]
Creatinine (µmol/L, median and IQR)	85 [61-104]
Viral load (log <sub>10</sub> IU/mL, median and IQR)	6.94 [5.94-7.25]
Fibrosis stage (METAVIR) (n, %)	
F1	5 (29.4)
F2	9 (52.9)
F3	3 (17.6)
HCV treatment (n, %)	
sofosbuvir	17 (100.0)
ribavirin	14 (82.4)
daclatasvir	12 (70.6)
ledipasvir	1 (5.9)
PEG-IFN	1 (5.9)
Duration of DAA therapy (n, %)	
12 weeks	1 (5.9)
24 weeks	15 (88.2)
48 weeks	1 (5.9)
SVR12 (n, %)	16 (94.1)

HIV: human immunodeficiency virus; LT: liver transplantation; FCH: fibrosing cholestatic hepatitis; DAA: direct acting antivirals; HCV: hepatitis C virus; PEG-IFN: pegylated interferon; SVR: sustained virological response.

**Table 2: Outcome of clinical features and laboratory tests during and after treatment**

	Day 0	End of treatment	SVR12	End of follow-up	p
Ascites (n, %)	6 (35.3)	1 (7.1)	3 (17.6)	2 (11.8)	0.12
Encephalopathy (n, %)	1 (5.9)	0 (0.0)	0 (0.0)	0 (0.0)	NA
Bilirubin ( $\mu\text{mol/L}$ , median and IQR)	72.0 [34.0-147.0]	16.0 [12.0-20.0]	17.0 [10.0-20.0]	13.0 [8.0-16.0]	< 0.01
Albumin (g/L, median and IQR)	29.7 [26.0-39.0]	36.6[29.6-39.0]	39.0 [31.0-46.0]	40.2 [33.9-46.0]	< 0.01
INR (median and IQR))	1.05 [1.00-1.25]	1.10 [1.07-1.14]	1.04 [1.01-1.16]	1.06 [1.01-1.17]	0.78
Platelets (G/L, median and IQR)	121 [79-203]	127 [99-181]	112 [92-139]	140 [86-152]	0.50
ALT (IU/L, median and IQR)	120 [49-188]	25 [19-41]	29 [20-46]	44 [24-69]	<0.01
GGT (IU/L, median and IQR)	614 [200-1362]	51 [35-249]	52 [38-539]	133 [34-340]	<0.01

NA: not applicable

**Table 3: Histological features on pre- and post-treatment liver graft biopsies**

	Timing of biopsy	Fibrosis stage*	Perisinusoidal fibrosis	Infiltrate	Ductular proliferation	Cholangiolitis	Periportal activity	Activity score*	Ductopenia	Cholangitis	Endothelitis	Lobular activity	Cholestasis	Discordance <sup>§</sup>	Conclusion of first local evaluation
Patient 1	Pre	2	0	3	1	0	1	1	0	0	0	0	1	Yes	F4
	Post	2	0	1	1	0	1	1	0	0	0	0	1	No	
Patient 2	Pre	2	2	2	1	0	2	2	0	0	0	2	1	No	
	Post	3/4	0	2	1	0	1	1	0	0	0	1	1	No	
Patient 3	Pre	2	3	1	1	0	0	1	0	0	0	1	1	No	
	Post	3/4	0	1	1	0	0	0	0	0	0	0	1	No	
Patient 4	Pre	1	0	2	1	0	2	2	50%	0	0	1	1	Yes	ductopenia
	Post	2	0	3	1	0	2	3	52%	0	0	3	1	No	
Patient 5	Pre	3	2	1	1	0	0	0	0	0	0	0	0	Yes	F4
	Post	1	0	0	0	0	0	0	0	0	0	0	0	Yes	F4
Patient 6	Pre	2	3	1	1	0	1	1	0	0	0	1	1	No	
	Post	2	0	1	1	0	0	0	0	0	0	0	1	No	
Patient 7	Pre	1	1	1	1	0	1	1	0	0	0	0	1	Yes	F2
	Post	4	0	1	1	0	0	0	0	0	0	0	0	No	
Patient 8	Pre	2	1	1	1	0	2	2	0	1	1	2	1	Yes	ductopenia
	Post	2	3	1	1	0	0	1	27%	0	0	1	1	Yes	F1
Patient 9	Pre	2	1	1	1	0	1	1	0	0	0	1	1	No	
	Post	1	0	1	1	0	0	0	0	0	0	0	0	No	
Patient 10	Pre	2	3	2	1	0	2	2	0	1	1	2	1	No	
	Post	2	0	2	1	0	1	1	0	0	0	0	0	Yes	F1
Patient 11	Pre	1	0	1	1	0	0	1	0	0	1	2	1	No	
	Post	2	1	2	1	1	1	1	17%	0	0	1	0	No	
Patient 12	Pre	3	1	2	2	0	2	2	0	0	0	2	0	No	
	Post	4	1	1	1	0	0	0	0	0	0	0	0	No	
Patient 13	Pre	2	0	2	2	0	2	2	0	0	0	1	0	No	
	Post	3/4	2	1	1	0	1	2	0	0	0	2	0	Yes	A1
Patient 14	Pre	1	2	2	1	0	2	2	0	0	0	0	0	No	
	Post	2	0	1	1	0	1	1	0	0	0	1	1	No	
Patient 15	Pre	1	1	1	1	0	1	1	0	0	0	1	0	Yes	A2
	Post	2	1	2	1	0	1	1	0	0	0	1	0	No	
Patient 16	Pre	3	2	3	2	0	3	3	0	0	0	2	0	No	
	Post	4	1	3	2	0	3	2	0	0	0	0	0	No	
Patient 17	Pre	2	1	2	2	0	2	2	0	0	0	2	1	No	
	Post	2	1	2	1	0	2	1	38%	0	0	0	0	No	

\*According to Metavir scoring system

§Discordance regarding activity score, fibrosis stage and/or ductopenia between two pathologists (first local and expert)

Except for fibrosis stage and activity score, features are classified as 0: absent, 1: mild, 2: moderate, 3: severe



**Table 4: Predictive factors for fibrosis progression**

	Progression, n=10	No progression, n=7	p
Age (years, median and IQR)	54 [49 -58]	60 [48-62]	0.62
Male gender (n, %)	6 (60.0)	6 (85.7)	0.34
Body mass index (Kg/m2, median and IQR)	23.1 [20.4-25.5]	19.8 [17.6-21.4]	0.11
Diabetes (n, %)	2 (20.0)	4 (57.1)	0.16
Hypertension (n, %)	7 (70.0)	3 (42.9)	0.35
Delay diagnosis of FCH/DAAAs (months, median and IQR)	2.3 [1.1-6.9]	0.8 [0.7-5.0]	0.35
Tacrolimus (n, %)	5 (50.0)	2 (28.6)	0.62
Cyclosporine (n, %)	5 (50.0)	4 (57.1)	1.00
ALT (IU/L, median and IQR) 2 <sup>nd</sup> biopsy	25 [16-36]	38 [20-111]	0.26
GGT (IU/L, median and IQR) 2 <sup>nd</sup> biopsy	44 [22-249]	155 [39-753]	0.41
Initial fibrosis stage (n, %)			0.04
1	5 (50.0)	0 (0.0)	
2	3 (30.0)	6 (85.7)	
3	2 (20.0)	1 (14.3)	
Donor Age (years, median and IQR)	60.5 [51.0-67.0]	55.0 [41.0-70.0]	0.81