



HAL
open science

Arthroscopic osteosynthesis of capitellum fractures: Feasibility study and clinical study on 2 cases

Valérie Matter-Parrat, David Eichler, Christian Sommaire, Philippe Gicquel,
Philippe Clavert

► **To cite this version:**

Valérie Matter-Parrat, David Eichler, Christian Sommaire, Philippe Gicquel, Philippe Clavert.
Arthroscopic osteosynthesis of capitellum fractures: Feasibility study and clinical study on 2 cases.
Journal of Orthopaedic Science, 2021, 26 (4), 10.1016/j.jos.2020.05.018 . hal-03797749

HAL Id: hal-03797749

<https://hal.science/hal-03797749v1>

Submitted on 2 Aug 2023

HAL is a multi-disciplinary open access archive for the deposit and dissemination of scientific research documents, whether they are published or not. The documents may come from teaching and research institutions in France or abroad, or from public or private research centers.

L'archive ouverte pluridisciplinaire **HAL**, est destinée au dépôt et à la diffusion de documents scientifiques de niveau recherche, publiés ou non, émanant des établissements d'enseignement et de recherche français ou étrangers, des laboratoires publics ou privés.



Distributed under a Creative Commons Attribution - NonCommercial 4.0 International License

Arthroscopic osteosynthesis of capitellum fractures: feasibility study and clinical study on 2 cases.

Valérie Matter-Parrat¹, David Eichler¹, Christian Sommaire², Philippe Gicquel^{3,4}, Philippe Clavert^{1,2,4}

1. Shoulder and Elbow Service, CHRU Strasbourg, Avenue Molière, 67098 Strasbourg cedex, France, France

2. Institut of Anatomy, Faculté de Médecine, 4, Rue Kirschleger, 67085, Strasbourg Cedex, France.

3. ICube-GEBOAS, CNRS, UMR 7357, Faculté de Médecine, 4, Rue Kirschleger, 67085, Strasbourg Cedex, France.

4. Hôpitaux Universitaires de Strasbourg, Centre de Chirurgie Pédiatrique, Strasbourg, France

Corresponding author:

Philippe CLAVERT,

Institut of Anatomy,

Faculté de Médecine,

4, Rue Kirschleger,

67085, Strasbourg Cedex, France.

E-mail: philippe.clavert@chru-strasbourg.fr

Declare

Conflict of interest: the corresponding author (PhC) is a payed consultant and received royalties from Wright-Tornier / there is no direct conflict of interest with this study

Funding: there is no outside funding for this study

Ethical approval: the present manuscript respects all ethical rules for anatomical studies (Henry BM, Vikse J, Pekala P, Loukas M, Tubbs RS, Walocha JA, Jones DG, Tomaszewski KA. Consensus guidelines for the uniform reporting for study ethics in anatomical research within the framework of the Anatomical Quality Assurance (AQUA) checklist. Clin Anat. May. 2018 ; 31(4) : 521-524.), and for retrospective patient's data analysis.

Authors' contributions: all authors contribute equally to the study design, experiments and writing.

1 **Abstract**

2 **Background:** The current management of displaced capitellum fractures is traditionally surgical.
3 Most authors perform open reduction and internal fixation.

4 The working hypothesis was that closed reduction and internal fixation of capitellum fractures is
5 achievable by arthroscopy.

6 **Methods:** We carried out a cadaveric study on six fresh frozen elbows. We performed two Bryan
7 and Morrey type I fractures of the capitellum, three type II and one type IV using a 15mm
8 osteotome. Fracture reduction was performed under arthroscopy using a probe hook and an aiming
9 femoral instrument set. Fixation with a lag screw was performed under arthroscopy and radioscopic
10 control. We reviewed, two patients who had been operated on for a type I and type II capitellum
11 fracture and osteosynthesized under arthroscopy with a 7.5 years follow-up.

12 **Results:** In our cadaveric study, we obtained anatomical reduction and stable osteosynthesis in four
13 cases. We had two failures (2 type II fractures) due to a fracture of the fragment during screwing. In
14 our clinical study, range of motion was very satisfactory with only a 5° extension deficit. The x-rays
15 did not reveal any signs of osteoarthritis or periarticular ossification. One patient had minimal signs
16 of osteonecrosis.

17 **Conclusions:** Arthroscopic osteosynthesis of capitellum fractures is feasible and reproducible. We
18 recommend cannulated lag screws for Bryan and Morrey type I and IV fractures and adjustable lock
19 pins for type II fractures. We have shown that this technique gives good results on two patients with
20 a 7.5-year follow-up.

21 **Level of evidence: IV**

22

23

24

25

26 **Introduction**

27 Hahn and Steinthal were the first to describe capitellum fractures in the middle of the 19th century.
28 Capitellum fractures represent 1 to 2% of distal humerus fractures [1]. By definition the fracture is
29 articular. In the frontal plane, the fracture line is slightly oblique downward and backward with an
30 anterior and proximal displacement. The fragment is of variable size. Several classifications attempt
31 to describe the different types of fractures. Bryan and Morrey [2] classification modified by Mc Kee
32 [3] is the most commonly used:

- 33 - type I fracture, concerning the capitellum with or without a small lateral portion of the trochlea,
- 34 - type II fracture, which is a thin osteochondral fragment detached from the capitellum,
- 35 - type III fracture, which is a comminuted fracture of the capitellum
- 36 - type IV fracture, concerning the capitellum and a large part of the trochlea.

37 The traditional management of displaced capitellum fractures is surgical. Fractures type I, III and
38 IV are treated by open reduction and internal fixation (ORIF) [3-9] and fractures type II are either
39 treated by ORIF [10] or removal of the loose fragment [6, 9, 11-13].

40
41 The working hypothesis was that closed reduction and internal fixation of capitellum fractures is
42 achievable by arthroscopy. The primary objective of this study was to carry out an anatomical study
43 on cadaveric specimens in order to evaluate the feasibility and reproducibility of arthroscopic
44 capitellum fracture osteosynthesis. The secondary objective was to evaluate the long-term clinical
45 and radiological outcomes of two patients treated with arthroscopic osteosynthesis.

46

47 **Material and Methods**

48 **Anatomical study**

- 49 - Preparation of specimens and fractures:

50 We used six fresh frozen elbows from bodies donation, that respects all ethical recommendations for
51 anatomical studies [14]. Dissections were performed after a night of thawing at room temperature.

52 The upper limbs had no previous fractures, no previous incisions, and showed no evidence of
53 degenerative joint disease. The average age of the subjects was 85 years (range 78-92). There were
54 five right and one left elbows from four men and two women. We created through a short lateral
55 approach two type I fractures (Figure 1-A), three type II capitellum fractures and one type IV
56 fracture using a 15 mm osteotome. The arthrotomy was then hermetically sealed.

57 - Osteosynthesis protocol

58 We used an arthroscopic column, a standard scope with a diameter of 4.5 angled 30° and a probe
59 hook. For fragment reduction, we used an outside-inside femoral knee ligamentoplasty instrument
60 set, a 1.2mm diameter pin, a cannulated screwdriver and 3.5mm diameter partially threaded
61 cannulated screws.

62 - Surgical technique:

63 Underlying bony structures were palpated and marked before any joint distension. The capsule was
64 distended with twenty milliliters of saline injected into the joint through the posterior soft-point.
65 The arthroscope was introduced through an anterolateral portal, 2cm below the lateral epicondyle,
66 just in front of the humeroradial line. The anteromedial portal was localized by trans-illumination,
67 2cm in front of the medial condyle, and by an outside-inside technique using a needle allowing
68 precise identification. The scope was then introduced through the anteromedial portal. The
69 anterolateral portal was then used for instrumentation (probe hook and an aiming femoral
70 instrument set). The fracture was then reduced under arthroscopic control using a probe hook
71 (Figure 1-B). Subsequently, an aiming femoral instrument set was introduced to complete the
72 reduction using its hook and to maintain the reduction (Figure 1-C). Using the appropriate guide
73 sleeve, the guiding pin was placed from back to front under radioscopic and arthroscopic control to
74 check its positioning, the absence of extrusion beyond the capsule, and to measure the length of the
75 screw. The instrument set was removed to allow the cannulated drill bit to pass through, still under
76 radioscopic control. Finally, the 3.5mm short thread cannulated screw was inserted on the guiding
77 pin under fluoroscopic and arthroscopic control (Figure 1-D).

78

79 **Evaluation criteria:** The quality of reduction and osteosynthesis was assessed after dissection of
80 each specimen. The reduction was considered insufficient if the displacement in one direction was
81 greater than 1 mm. The positioning of the screw in relation to the fracture line and surrounding
82 elements was assessed, as well as the absence of joint protrusion of the screw or posterior
83 protrusion of the screw head, which could lead to conflict with the olecranon. The duration of the
84 intervention was recorded.

85

86 **Clinical application**

87 We retrospectively evaluated two patients operated on for an isolated capitellum fracture: a Bryan
88 and Morrey [2] type II fracture in a 14-year-old female (Figure 2-A, 2-B and 2-C) and a type I
89 fracture in a 70-year-old female (Figure 3-A and 3-B).

90 These patients were clinically reviewed for the study. The clinical evaluation assessed elbow's range
91 of motion, stability and pain on a scale from 0 to 10. Functional results were assessed by the
92 functional scores: Quick-Dash and Mayo Clinic Elbow Performance Score (MEPS).
93 Anteroposterior and lateral x-rays were analyzed at last follow-up for signs of capitellum
94 osteonecrosis, nonunion, periarticular ossification and osteoarthritis according to the Broberg and
95 Morrey scale [15].

96

97

98 **Results**

99 - Anatomical study

100 We had two failures and four good results. Both failures were two of the type II capitellum fractures
101 whose fragment's thickness was insufficient to allow placement of a lag screw without causing a
102 fracture. The other four specimens showed stable osteosynthesis and anatomical reductions. The
103 screws were in the correct position (perpendicular to the fracture line).

104 The average operating time between the skin incision and osteosynthesis is 29 minutes (minimum:
105 22 min - maximum: 37 min).

106 Table 1 summarizes the data collected after dissection of the six anatomic specimens.

107

108 - Clinical cases

109 The average follow-up was 7.5 years. The clinical results are listed in Table 2. At the last
110 radiological follow-up, no nonunion, osteoarthritis or peri-articular ossification was diagnosed
111 (Figures 2-F, 2-G, 3-C and 3-D). Signs of osteonecrosis were diagnosed in the 14-year-old patient
112 (Figure 2-F and 2-G).

113

114

115

116 **Discussion**

117 Capitellum fractures fixation can be performed under arthroscopy. The long-term results are very
118 satisfactory, offering mobility and indolence without signs of radiological osteoarthritis.

119 Depending on the type of capitellum fracture, several therapeutic options have been described. In
120 the case of displaced Bryan and Morrey type I fractures, closed reduction [9] and ORIF [4, 5, 7, 8,
121 16, 17] with screws, pins or plates have been described. In a 2002 case report, Hardy et al. [18]
122 proposed an arthroscopic anteroposterior screwing technique for osteosynthesis of the capitellum on
123 a 35-year-old patient with a type I fracture. Union was obtained at 2 months. At last follow-up,
124 range of motion of the elbow was 140° in flexion and -15° in extension with unlimited prono-
125 supination.

126 In case of a non-displaced type II fracture, nonoperative treatment is most often chosen and in the
127 case of a displaced fracture, osteosynthesis is seldom recommended due to the risk of fracture
128 fragmentation during the placement of a compression lag screw [12]. Most authors recommended
129 open excision of the fragment [6, 9, 11-13] or in a case report, Feldman [19] described arthroscopic

130 excision of the fragment and Sodl [10] in a case report open osteosynthesis with osteosuture. In our
131 anatomical study, the arthroscopic screw fixation of type II capitellum fractures was a failure due to
132 a secondary fracture of the fragment during screw fixation. In our clinical study, the 14-year-old
133 patient had a type II fracture. Osteosynthesis was performed with adjustable lock pins to limit the
134 risk of fragmentation of the capitellum. The thinness of the anterior part of the fractured capitellum
135 does not allow a screw to be placed satisfactorily; the risk of fracture of the fragment is greater
136 when the screw itself is placed or when compression is performed. Based on our anatomical study,
137 we do not recommend osteosynthesis by screwing type II capitellum fractures, nevertheless, our
138 clinical experience suggest that an alternative to a fragment excision might be to use adjustable lock
139 pins [20].

140 Authors disagree regarding type III comminuted fracture. Lasanios [12] recommended ORIF and, in
141 the event of a major comminution, conservative treatment. Bilsel [4] and Mighell [7] performed
142 ORIF with screws and pins in the event of a major comminution. Grantham [11] removed the
143 fragments in most cases. Faber [21] proposed total elbow arthroplasty for significant comminution
144 in the elderly.

145 Type IV fracture described by Mc Kee is rare and the preferred treatment is osteosynthesis [3]. Its
146 reduction must be perfect as the risk of instability is major because it concerns the capitellum and
147 the lateral part of the trochlea [22].

148

149 Concerning osteosynthesis, there are two controversial fixation methods: anteroposterior and
150 posteroanterior screwing. In our anatomical series, all fixations were done with posteroanterior
151 3.5mm percutaneous cannulated lag screws. For the 14-year-old patient, pinning was
152 posteroanterior and for the 70-year-old patient, due to the weakness of the posterior cortex, the
153 screw had to be placed in a lateromedial direction. According to Mosheiff [23], a posteroanterior lag
154 screw may expose its placement into the articular surface. According to Muller [24], this screwing
155 method for this type of fracture does not provide optimal primary mechanical hold. We believe that

156 performing this type of osteosynthesis under arthroscopic control and dynamically testing it
157 significantly reduces these risks. In addition, it would also seem interesting to consider
158 osteosynthesis with double threaded screws, such as double-threaded screws, to optimize their hold
159 with a better compression of the bony fragment.

160 Arthroscopic osteosynthesis of the capitellum offers many advantages. Classical advantages:
161 reduced risk of infection, no arthrotomy, respect for cartilage and ligaments. New advantages:
162 reduction of the risk of devascularization of the fragment thanks to periosteum preservation and
163 thus reduction of the risk of osteonecrosis, precision of the reduction, control of the positioning of
164 the screw and in particular the risk of cartilage intrusion, dynamic control of the stability of the
165 osteosynthesis and better accessibility to the medial compartment for injury evaluation. However,
166 this technique requires extensive experience in elbow arthroscopy and is most often performed in a
167 delayed emergency.

168 Feldman [19] published in 1997 a case report on two patients with a Bryan and Morrey type II
169 capitellum fracture treated with arthroscopic excision of the osteochondral fragment with good
170 clinical results. Arthroscopic resection of thin fragments and comminuted fragments therefore
171 seems to be a good alternative to osteosynthesis of type II capitellum fractures while maintaining
172 the benefit of arthroscopy.

173 The clinical results of our series are consistent with the literature. Most series of patients operated
174 on for capitellum osteosynthesis had an extension deficit ranging from 5° [4, 8] to 15° [3, 16] to 20°
175 [17] and a flexion ranging from 128° [16, 17] to 141° [3]. Regarding the functional scores found in
176 the literature, the MEPS averaged 90 [4, 25] and the Quick-Dash ranged from 8 to 15 [4, 17].

177 Concerning the radiological results at last follow-up, we found one case of osteonecrosis. This 14-
178 year-old patient had very limited osteonecrosis with no impact on joint mobility or stability.
179 Osteonecrosis is the most feared complication. For some authors, osteonecrosis was frequent around
180 10% for Lansiger and Mare in 1981, 20% for Jupiter et al. in 1988, up to 30% for Scapinelli in
181 1990. For other authors, it did not occur [3, 4, 16, 17]. Concerning post-traumatic osteoarthritis, we

182 did not observe any, unlike some authors [16, 17, 25] who observed in the majority of cases grade 1
183 and 2 arthrosis according to Broberg and Morrey [15].

184 There are limitations to our study. Our anatomical study would require a larger number of
185 specimens to be performed. In order to increase the relevance of the results, we plan to carry out a
186 new series of interventions, with five pieces per fracture type. The small number of subjects
187 reported in this study is related to the difficulty of obtaining specimens. A preliminary statistical
188 study had shown that a minimum of 20 cases per fracture type was required to answer all the
189 questions we were asking ourselves before finalizing the study protocol. It is obvious that such a
190 number of subjects are not available. As this is a preliminary feasibility study of an operating
191 technique, we have deliberately chosen to carry out only 6 tests.

192 Our clinical study is a retrospective study reporting the results of two patients. The long-term
193 evaluation focuses on elbow radiographs but for a better assessment of degenerative joint disease
194 and the development of osteonecrosis, a CT arthrography or an MRI of the elbow would be
195 recommended.

196

197 **Conclusions**

198 Through this study on cadaveric specimens, we have shown the feasibility and reproducibility of
199 arthroscopic osteosynthesis of capitulum fractures. We recommend cannulated screw
200 osteosynthesis for type I and IV fractures, what seems not possible for type II fractures, because of
201 the thickness of the fragment ; an osteosynthesis with wires might be an alternative to a simple
202 excision of the displaced fragment. We have shown that this technique gives good long-term results
203 on two patients with a 7.5-year follow-up

204

205

206 **References**

- 207 1. Mehdian H, McKee M. Fractures of the capitellum and trochlea. *Orthop Clin North Am.*
208 2000 Jan;31(1):115-27.
- 209 2. Bryan R, Morrey B. Fractures of the distal humerus. In: Morrey B, editor. *The Elbow and its*
210 *Disorders.* Philadelphia, PA: WB Saunders; 1985. p. 302-39.
- 211 3. McKee M, Jupiter J, Bamberger H. Coronal shear fractures of the distal end of the humerus.
212 *J Bone Joint Surg Am.* 1996;78(1):49-54.
- 213 4. Bilsel K, Atalar A, Erdil M, Elmadag M, Sen C, Demirhan M. Coronal plane fractures of the
214 distal humerus involving the capitellum and trochlea treated with open reduction internal fixation.
215 *Arch Orthop Trauma Surg.* 2013 Jun;133(6):797-804.
- 216 5. Clough T, Jago E, Sidhu D, Markovic L. Fractures of the capitellum: a new method of
217 fixation using a maxillofacial plate. *Clin Orthop Relat Res.* 2001 Mar(384):232-6.
- 218 6. Dushuttle R, Coyle M, Zawadsky J, Bloom H. Fractures of the capitellum. *J Trauma.* 1985
219 Apr;25(4):317-21.
- 220 7. Mighell M, Harkins D, Klein D, Schneider S, Frankle M. Technique for Internal Fixation of
221 Capitellum and Lateral Trochlea Fractures. *J Orthop Trauma.* 2006 Nov-Dec;20(10):699-704.
- 222 8. Poyton A, Kelly I, O'Rourke S. Fractures of the capitellum — a comparison of two fixation
223 methods. *Injury.* 1998 Jun;29(5):341-3.
- 224 9. Puloski S, Kemp K, Sheps D, Hildebrand K, Donaghy J. Closed reduction and early
225 mobilization in fractures of the humeral capitellum. *J Orthop Trauma.* 2012 Jan;26(1):62-5.
- 226 10. Sodl J, Ricchetti E, Huffman G. Acute Osteochondral Shear Fracture of the Capitellum in a
227 Twelve-Year-Old Patient. A Case Report. *J Bone Joint Surg Am.* 2008 Mar;90(3):629-33.
- 228 11. Grantham S, Norris T, Bush D. Isolated fracture of the humeral capitellum. *Clin Orthop*
229 *Relat Res.* 1981 Nov-Dec(161):262-9.
- 230 12. Lasanios N, Makridis K. Capitellum fractures. *Trauma and orthopaedic classifications: a*
231 *comprehensive overview:* Springer-Verlag; 2015.

- 232 13. Garner M, Schottel P, Hotchkiss R, Daluiski A, Lorich D. Capitellum Fracture Fragment
233 Excision: a Case Series. *HSS J.* 2015 Oct;11(3):204-8.
- 234 14. Henry B, Vikse J, Pekala P, Loukas M, Tubbs R, Walocha J, Jones D, Tomaszewski K.
235 Consensus guidelines for the uniform reporting for study ethics in anatomical reseach within the
236 framezwork of the Anatomical Quality Assurance (AQUA) checklist. *Clin Anat.* 2018
237 May;31(4):521-4.
- 238 15. Broberg M, Morrey B. Results of delayed excision of the radial head after fracture. *J Bone*
239 *Joint Surg Am.* 1986 Jun;68(5):669-74.
- 240 16. Ashwood N, Verma M, Hamlet M, Garlapati A, Fogg Q. Transarticular shear fractures of the
241 distal humerus. *J Shoulder Elbow Surg.* 2010 Jan;19(1):46-52.
- 242 17. Guitton T, Doornberg J, Raaymakers E, Ring D, Kloen P. Fractures of the capitellum and
243 trochlea. *J Bone Joint Surg Am.* 2009 Feb;91(2):390-7.
- 244 18. Hardy P, Menguy F, Guillot S. Arthroscopic treatment of capitellum fracture of the humerus.
245 *Arthroscopy.* 2002 Apr;18(4):422-6.
- 246 19. Feldman M. Arthroscopic excision of type II capitellar fractures. *Arthroscopy.*
247 1997;13(6):743-8.
- 248 20. Gicquel P, Giacomelli M, Karger C, Clavert J. Treatment of epiphyseo-metaphyseal
249 fractures in children with an original implant. The threated pin with an adjustable lock (Fixano).
250 *Oper Orthop Traumatol.* 2005;17(1):51-65.
- 251 21. Faber K. Coronal shear fractures of the distal humerus: the capitellum and trochlea. *Hand*
252 *Clin.* 2004 Nov;20(4):455-64.
- 253 22. Sabo M, Fay K, McDonald C, Ferreira L, Johnson J, King G. Effect of coronal shear
254 fractures of the distal humerus on elbow kinematics and stability. *J Shoulder Elbow Surg.* 2010
255 Jul;19(5):670-80.
- 256 23. Mosheiff R, Liebergall M, Elyashuv O, Mattan Y, Segal D. Surgical treatment of fractures of
257 the capitellum in adults: a modified technique. *J Orthop Trauma.* 1991;5(3):297-300.

258 24. Muller H, Schild H. [Diagnosis and therapy of capitulum humeri fractures]. Unfallchirurgie.
259 1983 Apr;9(2):59-70.

260 25. Dubberley J, Faber K, MacDermid J, Patterson S, King G. Outcome After Open Reduction
261 and Internal Fixation of Capitellar and Trochlear Fractures. J Bone Joint Surg Am. 2006
262 Jan;88(1):46-54.

263

264

265

266

267

268

269 **Figures Legends**

270

271 **Figure 1: Arthroscopic views of the procedure**

272 A - McKee modified Bryan and Morrey type I capitellum fracture / B - Reduction of the fragment
273 using a probe hook / C - Arthroscopic reduction and its preservation using an aiming femoral
274 instrument set / D - Reduction and fixation quality assessment after screw fixation of a type I
275 fracture

276

277 **Figures 2:** Bryan and Morrey type II capitellum fracture in a 14 years-old female: preoperative
278 standard x-rays (2-A and 2-B) and CT-scan (2-C). Capitellum arthroscopic osteosynthesis using
279 adjustable lock pins, 6 months follow-up x-rays (2-D and 2-E). 93 months follow-up radiographic
280 results (2-F and 2-G).

281

282 **Figures 3:** Type I Bryan and Morrey capitellum fracture in a 70 years-old female: preoperative
283 standard x-rays (3-A and 3-B). Arthroscopic capitellum screwing: 88 months follow-up
284 radiographic results (3-F and 3-G)

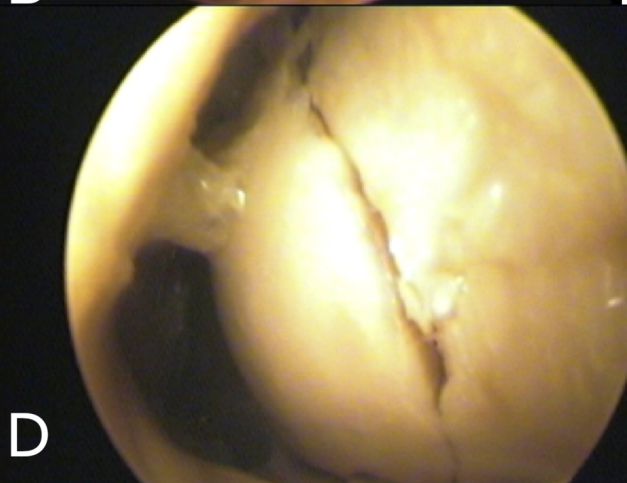
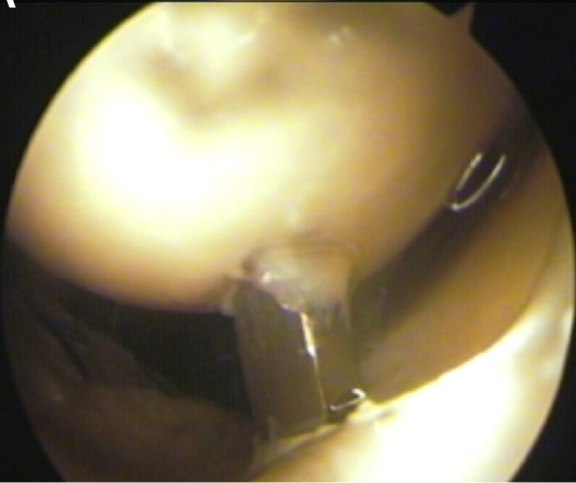
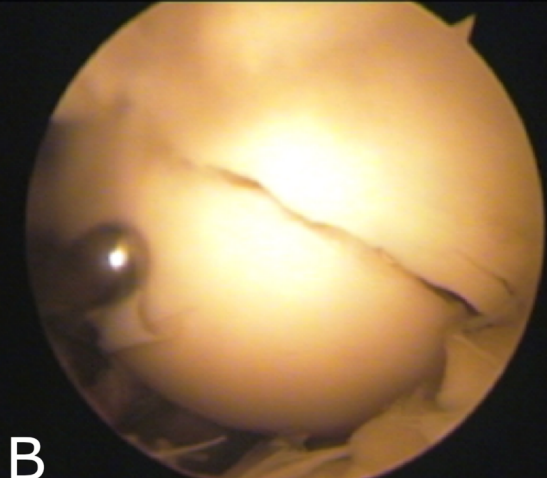
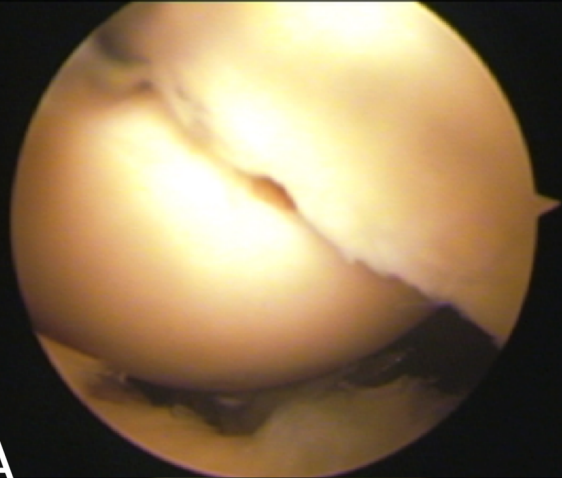
285

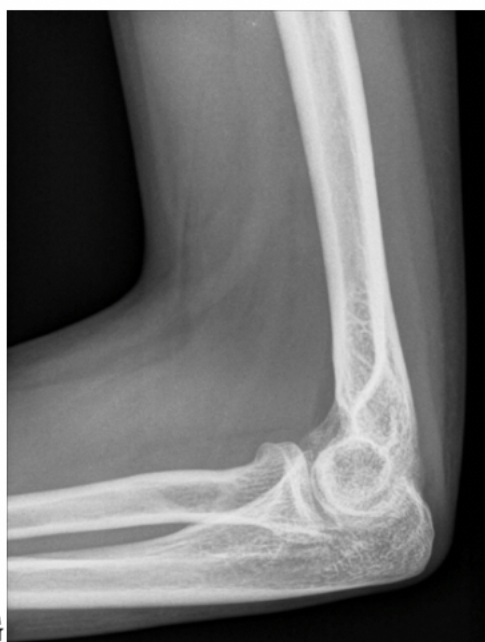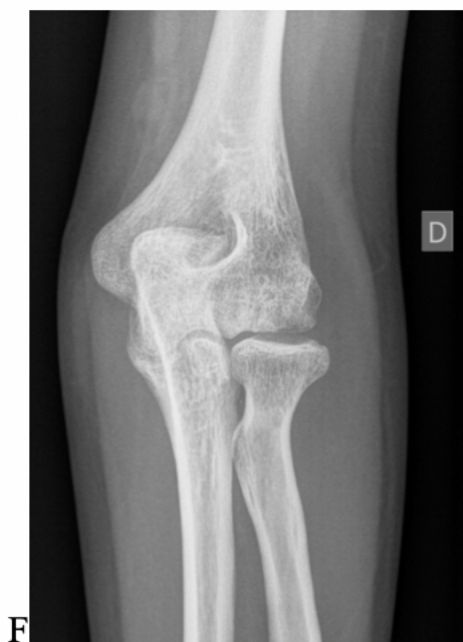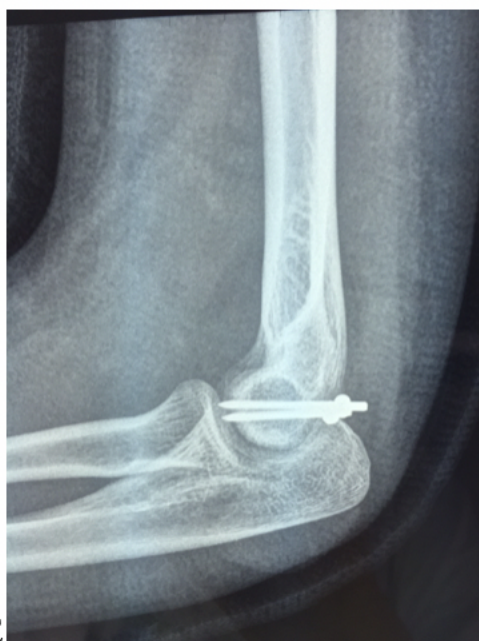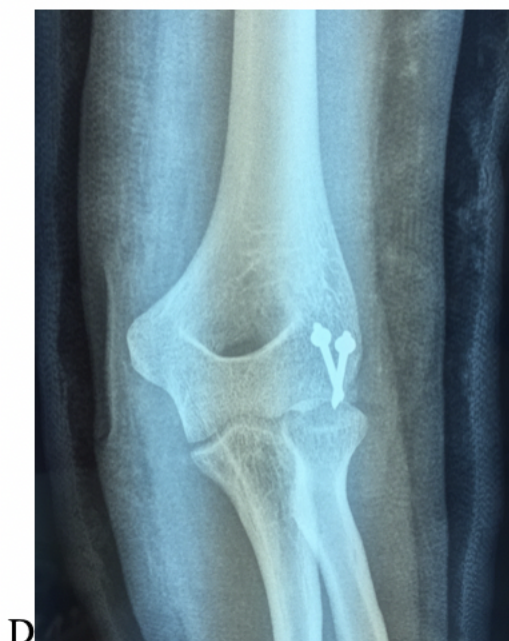
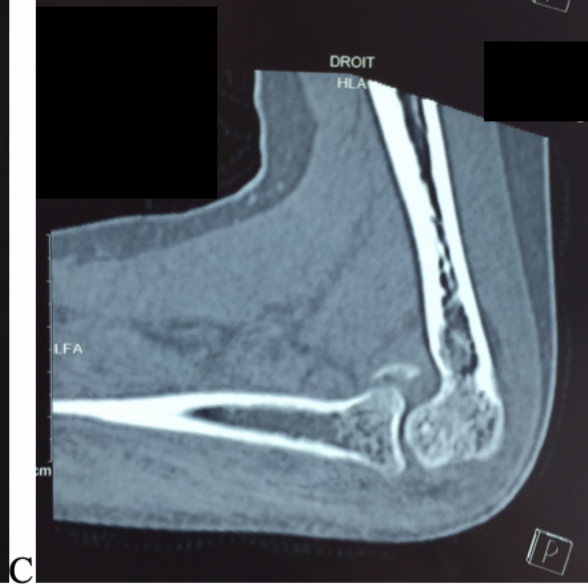
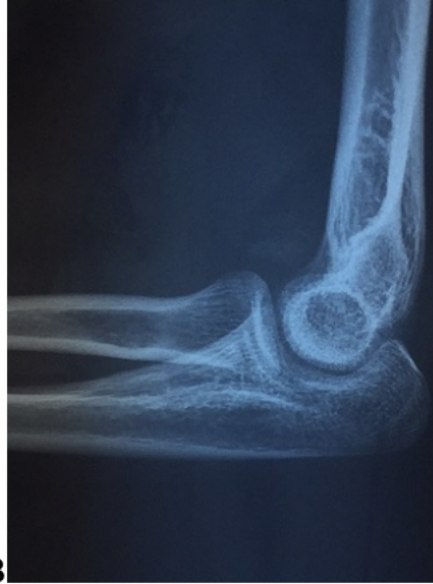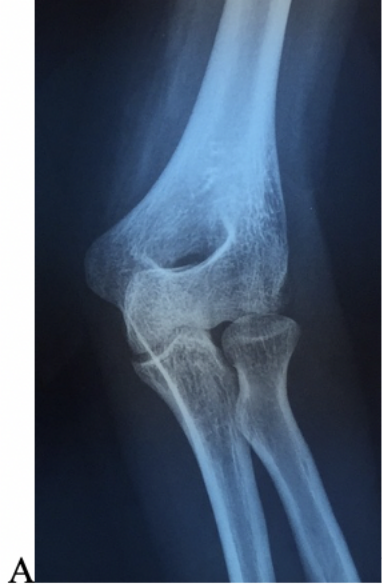
286

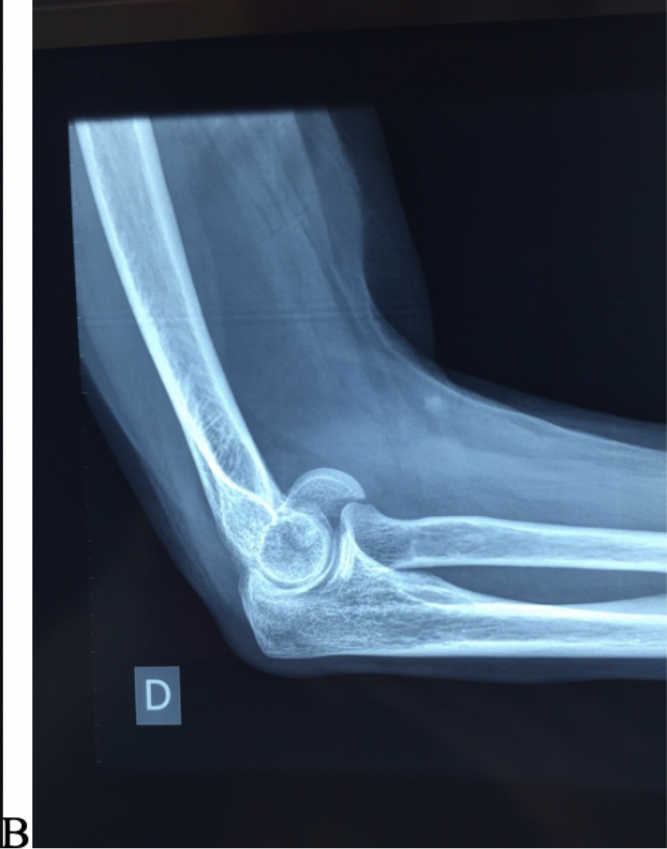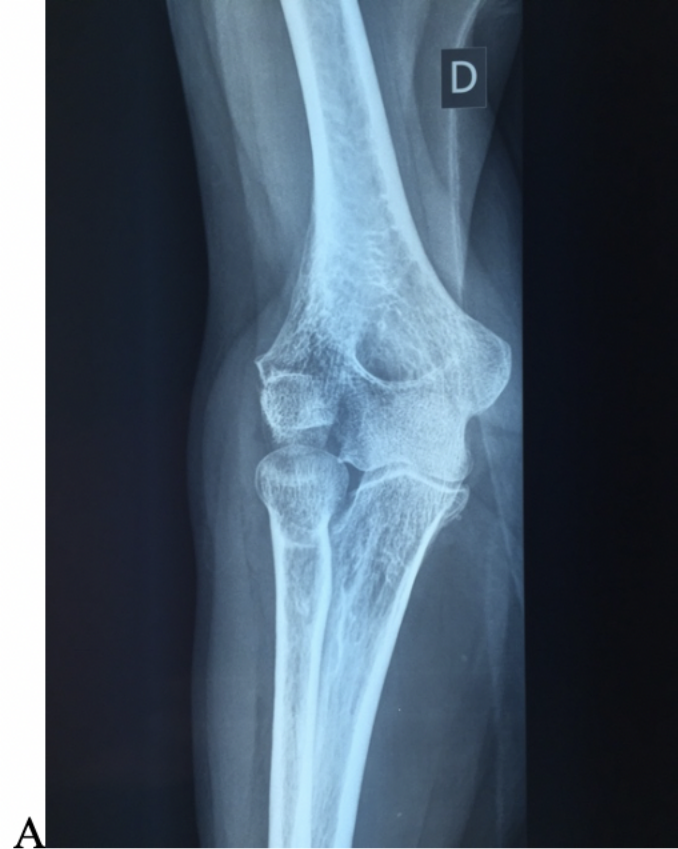287

288

289

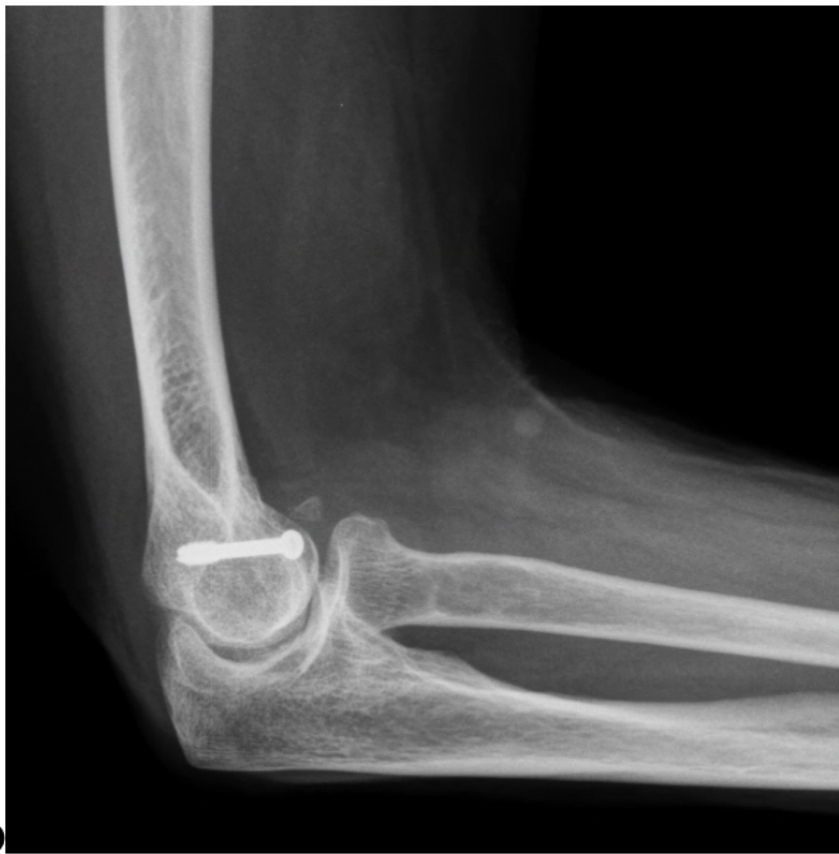
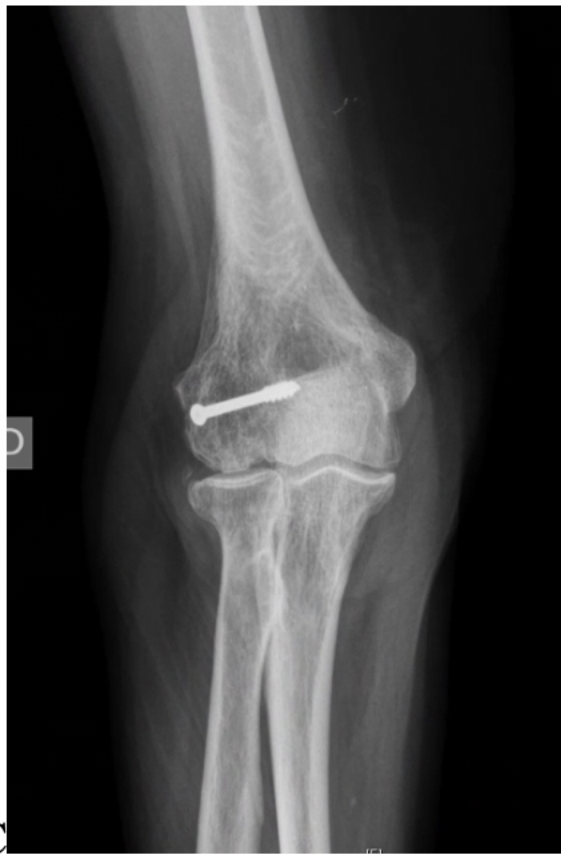




A

B



C

D

Anatomical specimen N°	Fracture type	Procedure time (min)	Reduction quality	Articular effraction
1	II	37	GOOD	NO
2	I	32	GOOD	NO
3	IV	30	GOOD	NO
4	II	22	POOR	YES
5	II	26	POOR	YES
6	I	28	GOOD	NO
Average:		29.16		

Table 1: capitellum arthroscopic osteosynthesis results on 6 cadaveric specimens.

Patient (n°)	Sex	Age	Fracture type	Treatment	Follow-up (months)	Mobility E/F	Mobility P/S	VAS	Quick-DASH	MEPS
1	F	14	II	Arthroscopic pinning	93	0/5/150	90/0/90	2	6.82	85
2	F	70	I	Arthroscopic screwing	88	0/5/145	90/0/90	0	6.82	100

Table 2: Clinical results of capitellum arthroscopic osteosynthesis