



HAL
open science

Arthroscopic intramedullary nailing of humeral fractures through the rotator interval

Maxime Antoni, Priscille Lazarus, Jean-François Kempf, Philippe Clavert

► To cite this version:

Maxime Antoni, Priscille Lazarus, Jean-François Kempf, Philippe Clavert. Arthroscopic intramedullary nailing of humeral fractures through the rotator interval. *Orthopaedics & Traumatology: Surgery & Research*, 2021, 107 (1), 10.1016/j.otsr.2020.102750 . hal-03797695

HAL Id: hal-03797695

<https://hal.science/hal-03797695>

Submitted on 22 Mar 2023

HAL is a multi-disciplinary open access archive for the deposit and dissemination of scientific research documents, whether they are published or not. The documents may come from teaching and research institutions in France or abroad, or from public or private research centers.

L'archive ouverte pluridisciplinaire **HAL**, est destinée au dépôt et à la diffusion de documents scientifiques de niveau recherche, publiés ou non, émanant des établissements d'enseignement et de recherche français ou étrangers, des laboratoires publics ou privés.



Distributed under a Creative Commons Attribution - NonCommercial 4.0 International License

Original article

Arthroscopic intramedullary nailing of humeral fractures through the rotator interval

Maxime ANTONI*, Priscille LAZARUS*, Jean-François KEMPF*, Philippe CLAVERT*

Service de Chirurgie du Membre Supérieur, CHU Strasbourg, Strasbourg, France

Corresponding author: Maxime ANTONI

*: Service de Chirurgie du Membre Supérieur

Pôle de Chirurgie Orthopédique et de Traumatologie

Hôpital Hautepierre 2 - CHU Strasbourg

1, Avenue Molière

67200 Strasbourg, France

dr.maxime.antoni@gmail.com

+33 6 50 35 21 12

Abstract

Introduction: Antegrade nailing of humeral fractures is a proven technique with well-documented results. The standard surgical approach requires incision of the supraspinatus tendon to insert a nail, which comes with the risk of damaging the rotator cuff. The aims of this study were to describe a new surgical technique for arthroscopic humeral nailing that does not require opening the rotator cuff and to report the clinical and radiological outcomes of this technique.

Materials and Methods: This was a single center, retrospective study of patients who had a humeral shaft or surgical neck fracture at our hospital in 2017 and underwent antegrade intramedullary nailing by arthroscopy. The nail was introduced through the rotator interval without opening the rotator cuff. All were reviewed at 1-year postoperative: clinical examination (joint range of motion and Constant score) plus AP and lateral radiographs of the shoulder.

Results: Eighteen patients (12 women, 6 men) with a mean age of 65.4 years (37-84) were included retrospectively. One patient died during the follow-up period thus 17 patients were available for analysis. At the 1-year follow-up, the mean forward flexion was 152.1° (90-180), the mean external rotation was 56.1° (30-80), the mean absolute Constant score was 73.9 (54-88) points and the mean adjusted Constant score was 93.5 (67-100) points. Bone union was achieved in 16/17 patients (94%) with 1 patient experiencing a nonunion. There were no complications.

Conclusion: Arthroscopic antegrade nailing of humeral shaft and surgical neck fractures through the rotator interval yields good clinical and radiological results in our hands. This new, rotator cuff-sparing technique is a viable option for treating humeral fractures by arthroscopy.

Level of evidence: IV; retrospective study without control group

Keywords: humeral fracture, intramedullary nailing, arthroscopy, rotator cuff

Introduction

Antegrade intramedullary nailing of humeral fractures is a relatively standardized surgical technique with well-documented results [1]. Plate fixation is an alternative to nailing with similar functional outcomes and union rates. Nevertheless, the complication rate reported with plates is higher than

with nailing [1, 2, 3] and the mechanical superiority of nails over plates has been suggested by several publications, especially for surgical neck fractures [4, 5].

Antegrade nailing typically requires making an incision in the supraspinatus tendon to insert the nail, which may cause secondary tendon lesions [6] and iatrogenic subacromial impingement if the nail sticks out [7], leading to postoperative pain and shoulder stiffness [1]. To avoid opening the rotator cuff, Park et al [8] described in 2008 a new surgical approach through the rotator interval by a standard superolateral skin incision. In 2017, Christ et al [9] added tenotomy-tenodesis of the long head of biceps. Lill et al in 2012 [10] and Dedeoglu et al in 2017 [11] published two studies on arthroscopic humeral nailing in which the nail was inserted through an incision in the supraspinatus tendon.

To combine the advantages of arthroscopy and of a surgical approach that does not require opening the supraspinatus tendon, we developed a new arthroscopic humeral nailing technique that passes through the rotator interval. The aims of this study were (1) to describe a new surgical technique for arthroscopic humeral nailing that does not require opening the rotator cuff and (2) to report the clinical and radiological outcomes of this technique.

Materials and Methods

This was a retrospective, single-center study of patients operated in 2017 for arthroscopic intramedullary nailing of a humeral fracture at a French university orthopedic and trauma surgery department.

Study population

The following inclusion criteria were used: (1) humeral shaft or surgical neck fracture, (2) antegrade intramedullary nailing, (3) insertion of nail through the rotator interval without opening the rotator cuff, (4) procedure done entirely by arthroscopy, (5) at least 1 year of clinical and radiological follow-up. The exclusion criteria were: (1) proximal humerus fracture, (2) complete superior rotator cuff tear discovered intraoperatively. Eighteen patients (12 women, 6 men) with a mean age of 65.4 years (37-84) were operated during the inclusion period. Among them, one patient died 3 months after the procedure from cardiac failure, thus 17 patients were available for analysis.

Surgical technique

All patients were operated by a single surgeon under general anesthesia with an interscalene block. The same set-up was used as for standard IM nailing: beach-chair position with fluoroscopy unit installed under the surgical drapes. After making a standard posterior arthroscopic portal (**Figure 1**), the scope was inserted directly into the joint. An intra-articular assessment was done to look for rotator cuff lesions. A second arthroscopic portal was made in front of the acromion (**Figure 1**), after pin-pointing the location with a needle. The rotator interval was opened through the portal (**Figure 2**) to introduce a square awl and position it at the apex of the humeral head by passing over and behind the biceps tendon (**Figures 3a, 3b**). Mediolateral positioning was confirmed by fluoroscopy (**Figure 3c**) and the anteroposterior position by arthroscopy by positioning the entry point behind the long head of biceps tendon. The nail's entry point was set with the square awl, which was then removed to apply the curved drilling guide (**Figure 4**) through the same anterior portal. A curved drill guide is used to cross the fracture site. Drilling was then done using the guide as needed and the nail inserted (**Figure 5**) (Aequalis, Tornier-Wright®, Montbonnot France). The nail's height was evaluated with fluoroscopy and arthroscopy to ensure that it did not stick out proximally (**Figures 6a, 6b**). Proximal and distal locking were done in the typical manner with percutaneous incisions and aiming guides placed on the instrumentation. After removing the instrumentation, the nail's height was verified by arthroscopy (**Figure 7**).

Follow-up and final assessment

Postoperatively, no immobilization was used thus motion was allowed immediately. Rehabilitation was prescribed upon discharge from the surgery ward. The patients were reviewed in person at 6 weeks, 3 months, 6 months and 1 year postoperative. Complications were documented throughout the follow-up period. At the 1-year follow-up visit, patients underwent a clinical examination (shoulder range of motion and Constant [12] score) and AP and lateral axillary radiographs were made. The main outcome was the Constant score at the 1-year follow-up visit. The secondary outcomes were the joint range of motion, bone union at 1 year and the occurrence of complications or need for reoperation.

Statistics

Quantitative variables were summarized by their mean and standard deviation values when they were normally distributed, or by the median and interquartile range when they were not. Qualitative variables were summarized by their counts and percentages.

Results

Nine patients had a surgical neck fracture, six had a mid-shaft fracture and three had both surgical neck and mid-shaft fractures. The mean time between the injury event and the procedure was 8.9 days (2-21). The mean operative time was 61 minutes (36-93). A short nail was used in nine patients and a long nail in the other nine patients. Proximal locking required three screws in 11 patients and two screws in 7 patients. Distal locking required two screws in 16 patients and one screw in 2 patients. Tenotomy of the long head of biceps was done in three patients because advanced degenerative lesions in the tendon were discovered intraoperatively. The procedure was done entirely by arthroscopy in all patients; no conversion to open surgery was needed.

The mean follow-up was 12.4 months (12–15). At the final assessment, the mean absolute Constant score was 73.9 points (54-88) and the mean age-adjusted score was 93.5 (67-100) points. Shoulder range of motion at the final assessment was 152.1° (90-180) in forward flexion, 56.1° (30-80) in external rotation with elbow at body and 6.9 (4-10) in internal rotation (0 = greater trochanter, 2 = buttocks, 4 = sacrum, 6 = L3, 8 = T12, 10 = T7).

Bone union was achieved in 16/17 patients (**Figures 8a, 8b, 8c**). One patient had a nonunion at the final assessment (**Figure 9**) but did not want to be reoperated. This patient also had the lowest age-adjusted Constant score in the cohort (67 points). There were no other complications, and no reoperations were needed. The appearance of the incisions at the final assessment is shown in **Figure 10**.

Discussion

The aim of this study was to describe a new surgical technique for arthroscopic humeral nailing that passes through the rotator interval, without opening the rotator cuff. The clinical outcomes were satisfactory at the final assessment and bone union was achieved in 94% of patients. No reoperations were needed and there was only one case of nonunion.

Antegrade intramedullary nailing is a surgical option for fixation of humeral fractures with well-documented results in the literature [1, 7]. The various nail designs that are commercially available have similar outcomes in terms of shoulder ROM and clinical scores [6, 7]. Curved nails that have a proximal valgus require a lateral approach on the proximal humerus at the distal part of the supraspinatus through the least vascularized zone of the tendon [7, 13]. This increases the risk of iatrogenic rotator cuff damage [6, 7, 13, 14]. Straight nails [6, 7] require a more medial approach on the tendon, limiting the tendon approach in the poorly vascularized zone. Consequently, pain related to rotator cuff pathology (attributed to the surgical approach passing through the supraspinatus

tendon) is more common with curved nails than straight nails: 73% versus 35% in a randomized study comparing these two types of nails [6]. But no matter the nail shape, iatrogenic lesions of the rotator cuff related to opening the tendon, or the development of iatrogenic subacromial impingement when the nail sticks out proximally, can cause pain and shoulder stiffness [6, 14-18]. (Figure 11)

When compared to nails, locking plates are associated with less subacromial impingement [19], since they are placed on the lateral side of the humerus. The clinical outcomes and union rates are similar [19], although there are more complications and reoperations [1, 2, 3].

To avoid passing through the poorly vascularized area of the rotator cuff and to reduce the risk of iatrogenic tendon damage, several authors have described alternative surgical approaches [9, 13, 20]. In a 2013 cadaver study, Knierim et al [20] suggested using the Neviaser approach to avoid opening the tendon in the distal poorly vascularized area by passing through the muscle when inserting a straight nail. After implanting the nails and dissecting the shoulders, it was confirmed that the surgical approach passed through the supraspinatus muscle in 100% of cases. When it is normally inserted preoperatively, the supraspinatus tendon was never injured by the nail, just like the long head of biceps tendon.

In 2019, Boileau et al [13] published a clinical study of percutaneous humeral nailing by the Neviaser approach in which they went through the supraspinatus muscle. Our study results are similar to theirs. Of the 41 patients operated and reviewed after a mean of 26 months, active forward flexion was 146°, mean external rotation was 50°, and the mean Constant score was 71 (43-95) points. All the fractures had healed. There were two complications: one malunion and one humeral head avascular necrosis.

Continuing with the idea of not crossing the rotator cuff tendons, Park et al [8] published a 34-patient case study (35 shoulders) of humeral nailing by the rotator interval with a minimum follow-up of 24 months. An anterolateral approach was used with detachment of the deltoid from the acromion. The patients' shoulder was immobilized with a sling for 6 weeks. Forward flexion was 144°, external rotation was 66° and the mean Constant score was 84 points at the final assessment. No reoperations were needed during the postoperative course.

Christ et al [9] also published a study of IM nailing by the rotator interval in which tenotomy-tenodesis of the long head of biceps was also done. They hypothesized that shoulder pain after IM nailing was related to involvement of the rotator cuff on one hand, but also lesions in the long head of biceps

tendon. Eight patients with a mean age of 60.8 years were reviewed after 1 year of follow-up. Bone union occurred in all patients and there were no neurological complications.

Other authors proposed using arthroscopic techniques to limit tissue damage in the deltoid. In 2012, Lill et al [10] published a retrospective comparative study of humeral nailing. Sixteen patients with mid-shaft or surgical neck humeral fractures were included retrospectively in two groups: one group (eight patients) underwent standard nailing, and the second group (eight patients) underwent arthroscopic nailing. The clinical and radiological outcomes were the same in the two groups as was the surgery time and length of hospital stay. One patient in each group suffered avascular necrosis during the postoperative course while one patient in the standard nailing group suffered radial nerve irritation.

In 2017, Dedeoglu et al [11] published a prospective randomized study of arthroscopic nailing. Forty patients were enrolled into two groups that underwent either standard IM nailing (n=20) or arthroscopic nailing (n=20). There was no difference between groups in the length of hospital stay. Conversely, the number of fluoroscopy images taken intraoperatively was significantly lower in the arthroscopy group. Bone union occurred in 95% of the patients in the arthroscopy group and 90% of the patients in the standard nailing group (no statistical difference). The mean Constant score at the final assessment statistically higher in the arthroscopy group than the standard group (89 points vs. 85 points) but not clinically different [21].

These are the only two published studies of arthroscopic humeral nailing; however, the nail was inserted through a standard supraspinatus tendon incision, limiting the benefits of arthroscopy to doing smaller skin incisions. Our technique combines the advantages of not opening the rotator cuff by passing through the rotator interval, with an arthroscopy approach that is less damaging for the deltoid. The absence of intraoperative and postoperative complications means the technique itself is not iatrogenic. Neither of the two previous studies of humeral nailing by arthroscopy found more complications when using arthroscopy compared to the standard open technique [10, 11], just like the published studies of arthroscopic nail removal [22, 23].

No conversion to a standard open approach was necessary, even though the cases included the surgeon's learning curve. The operative time was reasonable although there was no control group to compare how arthroscopy impacted this parameter. This technique is easy to do and not technically demanding, in comparison to other arthroscopic procedures that have a long learning curve, for example arthroscopic coracoid bone graft [24]. Furthermore, no specific instrumentation is needed for

this technique; a standard 30° scope and arthroscopy coagulation electrode is sufficient. Another advantage is that the joint area can be examined during the same surgical session and any lesions treated.

Cost may be a concern. In fact, doing shoulder arthroscopy implies using costly consumables that would not be needed for a standard humeral nailing protocol. Additional studies would be needed to answer this question, by looking at the potential advantages of arthroscopy relative to increase procedure costs.

The only complication in our study was one case of nonunion (6.3% rate), which was well tolerated by the patient who did not want to undergo surgical revision. Comparatively, in the review of literature by Lanting et al [25], the complication rate after nailing was 12% of which 5% were nonunions or malunions.

However, our study has certain limitations. The main one was the lack of a control group, which prevents us from drawing conclusions about our technique being better than the others. The obvious next step is a prospective randomized study comparing standard IM nailing with arthroscopic IM nailing to prove that one technique is superior to the other. It would also be interesting to follow the changes in joint ROM during the first year postoperative to determine if recovery is quicker after arthroscopic IM nailing and to compare the number of fluoroscopy images taken when doing the standard IM nailing techniques.

Our study also has its strengths. This is the first published study of arthroscopic humeral nailing through the rotator interval with a cohort of continuous, non-selected patients. This technique is feasible and does not have a long learning curve, making it accessible to all surgeons who are experienced in shoulder arthroscopy.

Conclusion

Arthroscopic IM nailing of humeral fractures through the rotator interval yields good results in our hands, like those achieved after standard open IM nailing. No complications occurred and bone union was achieved in 94% of patients in our cohort. This is an easy technique to do, and most importantly, the rotator cuff does not need to be opened. Arthroscopic IM nailing through the rotator interval reduces tissue damage and may help to limit complications by not crossing the supraspinatus and

thereby to accelerating functional recovery. Furthermore, the view provided by the scope helps to verify the nail's position under the cartilage surface to prevent secondary iatrogenic subacromial impingement.

Conflict of interest: none related to this article

Funding: none received for this study

Author contributions:

Maxime Antoni: development of study protocol, analysis of medical records, review of patients and writing of manuscript

Priscille Lazarus, Jean-François Kempf, Philippe Clavert: critical revision of manuscript.

References

- [1] Walker M, Palumbo B, Badman B, Brooks J, Van Gelderen J, Mighell M. Humeral shaft fractures: a review. *J Shoulder Elbow Surg* (2011) 20: 833-44
- [2] McCormack RG, Brien D, Buckley RE, McKee MD, Powell J, Schemitsch EH. Fixation of fractures of the shaft of the humerus by dynamic compression plate or intramedullary nail. A prospective, randomised trial. *J Bone Joint Surg Br* (2000) 82: 336-9
- [3] Zhu Y, Lu Y, Shen J, Zhang J, Jianc C. Locking intramedullary nails and locking plates in the treatment of two-parts proximal humeral surgical neck fractures: a prospective randomized trial with a minimum of three years of follow-up. *J Bone Joint Surg Am* (2011) 93: 159-68
- [4] Edwards SL, Wilson NA, Zhang LQ, Flores S, Merk BR. Two-part surgical neck fractures of the proximal part of the humerus. A biomechanical evaluation of 2 fixation techniques *J Bone Joint Surg Am* (2006) 88: 2258-64
- [5] Führtmeier B, May R, Hente R, Maghsudi M, Völk M, Hammer J et al. Proximal humerus fractures: a comparative biomechanical analysis of intra and extramedullary implants. *Arch Orthop Trauma Surg* (1998) 7: 586-90
- [6] Lopiz Y, Garcia-Coiradas J, Garcia-Fernandez C, Marco F. Proximal humerus nailing: a randomized clinical trial between curvilinear and straight nails. *J Shoulder Elbow Surg* (2013) 23 (3): 369-76
- [7] Dilisio MF, Nowinski RJ, Hatzidakis AM, Fehring EV. Intramedullary nailing of the proximal humerus: evolution, technique and results. *J Shoulder Elbow Surg* (2016) 25: e130-8
- [8] Park JY, Pandhers DS, Chun JY, Lee ST. Antegrade humeral nailing through the rotator cuff interval: a new entry portal. *J Orthop Trauma* (2008) 22 (6): 419-25
- [9] Christ AB, Gausden EB, Warner SJ, Nellestein AM, Thacher RR, Lorich DG. Rotator cuff sparing approach for antegrade nailing humeral nailing with biceps tenodesis: a technical trick with clinical implications. *J Orthop Traum* (2017) 31 (2): e60-5

- [10] Lill H, Katthagen C, Hertel A, Gille J, Voigt C. All-arthroscopic intramedullary nailing of 2- and 3-part proximal humeral fractures: a new arthroscopic technique and preliminary results. *Arch Orthop Traum Surg* (2012) 132: 641-7
- [11] Dedeoglu SS, Imren Y, Cabuk H, Tekin AC, Kir MC, Gürbüz H. Arthroscopy-assisted versus standard intramedullary nail fixation in diaphyseal fractures of the humerus. *J Orthop Surg* (2017) 25 (3): 1-6
- [12] Constant CR, Murley AH. A clinical method of functional assessment of the shoulder. *Clin Orthop Relat Res* (1987) 214: 160-4
- [13] Boileau P, d'Ollonne T, Bessière C, Wilson A, Clavert P, Hatzidakis AM, Chelli M. Displaced surgical neck fractures: classification and results of third generation percutaneous intramedullary nailing. *J Shoulder Elbow Surg* (2019) 28: 276-87
- [14] Verdano MA, Pellegrini A, Schiavi P, Somenzi L, Concari G, Ceccarelli F. Humeral shaft fractures treated with antegrade intramedullary nailing: what are the consequences for the rotator cuff? *International Orthopaedics (SICOT)* (2013) 37: 2001-7
- [15] Baltov A, Mihail R, Dian E. Complications after interlocking intramedullary nailing of humeral shaft fractures. *Injury* (2014) 45 (Suppl 1): S9-15
- [16] Chapman JR, Henley MB, Agel J, Benca PJ. Randomized prospective study of humeral shaft fracture fixation: intramedullary nails versus plates. *J Orthop Trauma* (2000) 14: 162-6
- [17] Nolan BM, Kippe MA, Wiater JM, Nowinski GP. Surgical treatment of displaced proximal humerus fractures treated with a short intramedullary nail. *J Shoulder Elbow Surg* (2011) 20: 1241-7
- [18] Mall NA, Kim HM, Keener JD et al. Symptomatic progression of asymptomatic rotator cuff tears: a prospective study of clinical and sonographic variables. *J Bone Joint Surg (Am)* (2010) 92 (16): 2623-33
- [19] Kurup H, Hossain M, Andrew JG. Dynamic compression locking plating versus locked intramedullary nailing for humeral shaft fractures in adults. *Cochrane Database Syst Rev* (2011) CD005959

[20] Knierim AE, Bollinger AJ, Wirth MA, Fehringer EV. Short, locked humeral nailing via Neviaser portal: an anatomic study. *J Orthop Trauma* (2013) 27 (2): 63-7

[21] Dabija DI, Jain NB. Minimal Clinically Important Difference of Shoulder Outcome Measures and Diagnoses: A Systematic Review. *Am J Phys Med Rehabil.* (2019) 98 (8): 671-676.

[22] Maroun C, Aliani D, Hass A, Werthel JD, Vidil A, Valenti P. Shoulder arthroscopy combined to hardware removal in proximal humeral fractures: a series of 58 cases with a mean follow-up of 2 years. *Eur J Orthop Surg Traumatol.* (2017) 27(3): 317-321

[23] Kim KC, Rhee KJ, Shin HD, Kim YM. Arthroscopic removal of an intramedullary nail in the humerus. *Knee Surg Sports Traumatol Arthrosc.* (2007) 15(7):922-6.

[24] Hurley ET, Lim Fat D, Farrington SK, Mullett H. Open Versus Arthroscopic Latarjet Procedure for Anterior Shoulder Instability. A Systematic Review and Meta-analysis. *Am J Sports Med.* (2019) 47(5): 1248-1253.

[25] Lanting B, McDermid J, Drosdowech D, Faber KJ. Proximal humeral fracture: a systematic review of treatment modalities. *J Shoulder Elbow Surg* (2008) 17: 42-54

Figure legends

Figure 1: Portals used for arthroscopy

Figure 2: Opening of the rotator interval by the anterior approach

Figures 3(a, b, c): Entry point being made at the top of the humeral head

Figure 4: Inserting the drill guide

Figure 5: Inserting the nail

Figures 6a, b: Verifying the nail's height

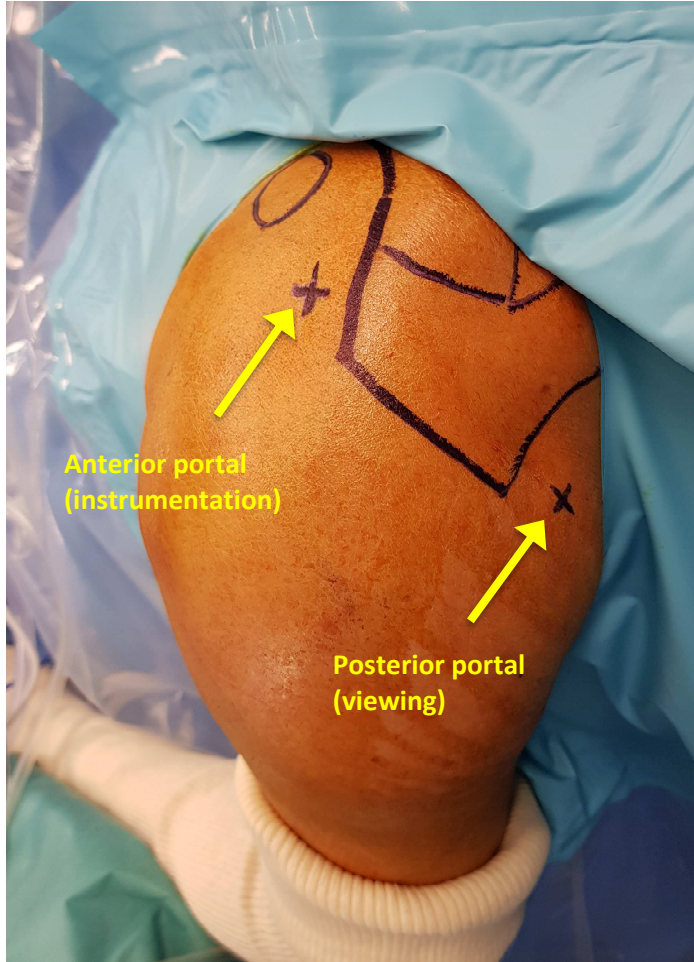
Figure 7: Final arthroscopic check of the nail's height

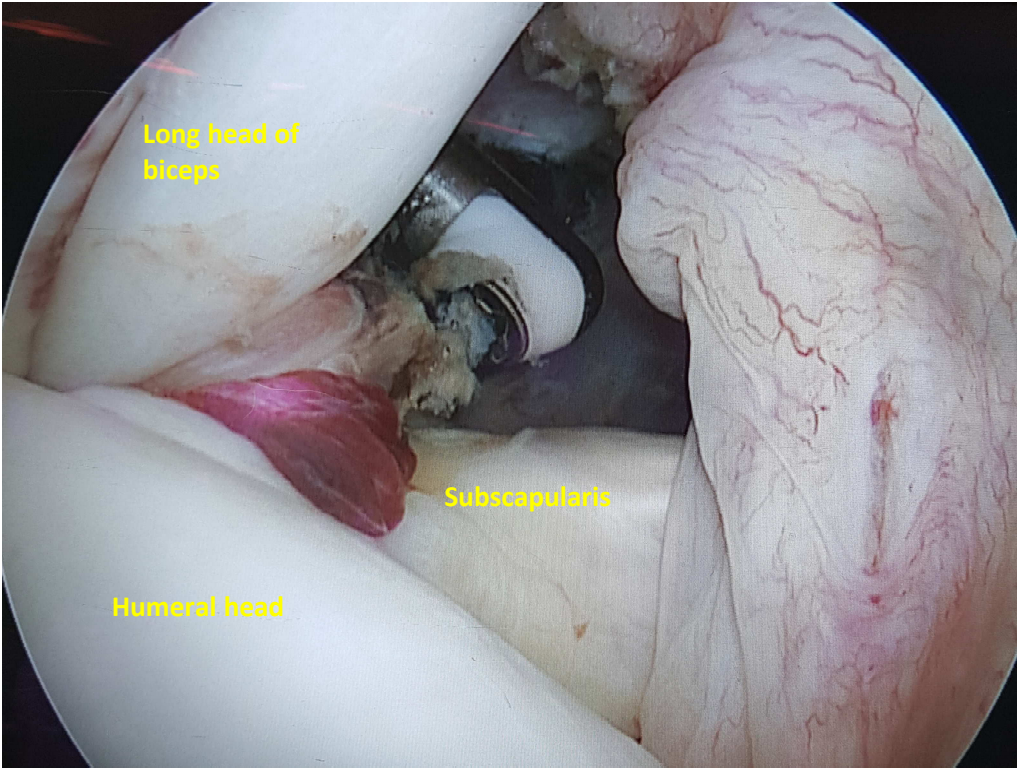
Figure 8(a, b, c): Examples of radiographs

Figure 9: Nonunion at the final assessment

Figure 10: Healed skin incisions at the final assessment

Figure 11: Nail that sticks out past the humeral head cartilage





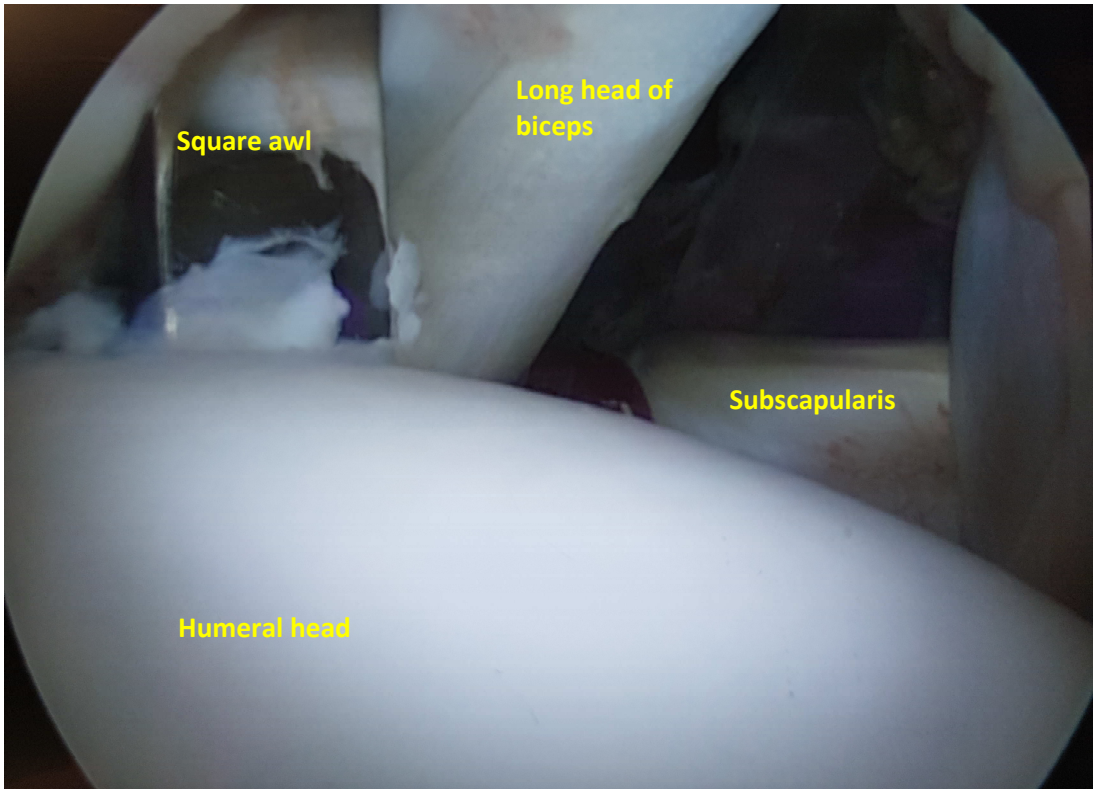


Image : Mise en place pointe carrée

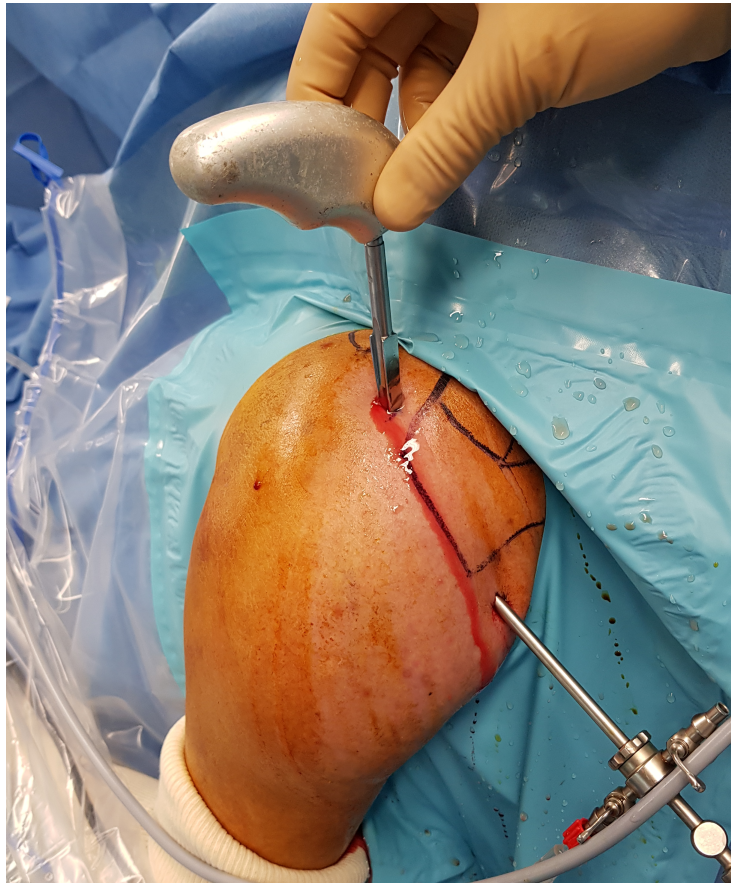


Image : Contrôle scopique lors de la mise en place de la pointe carrée

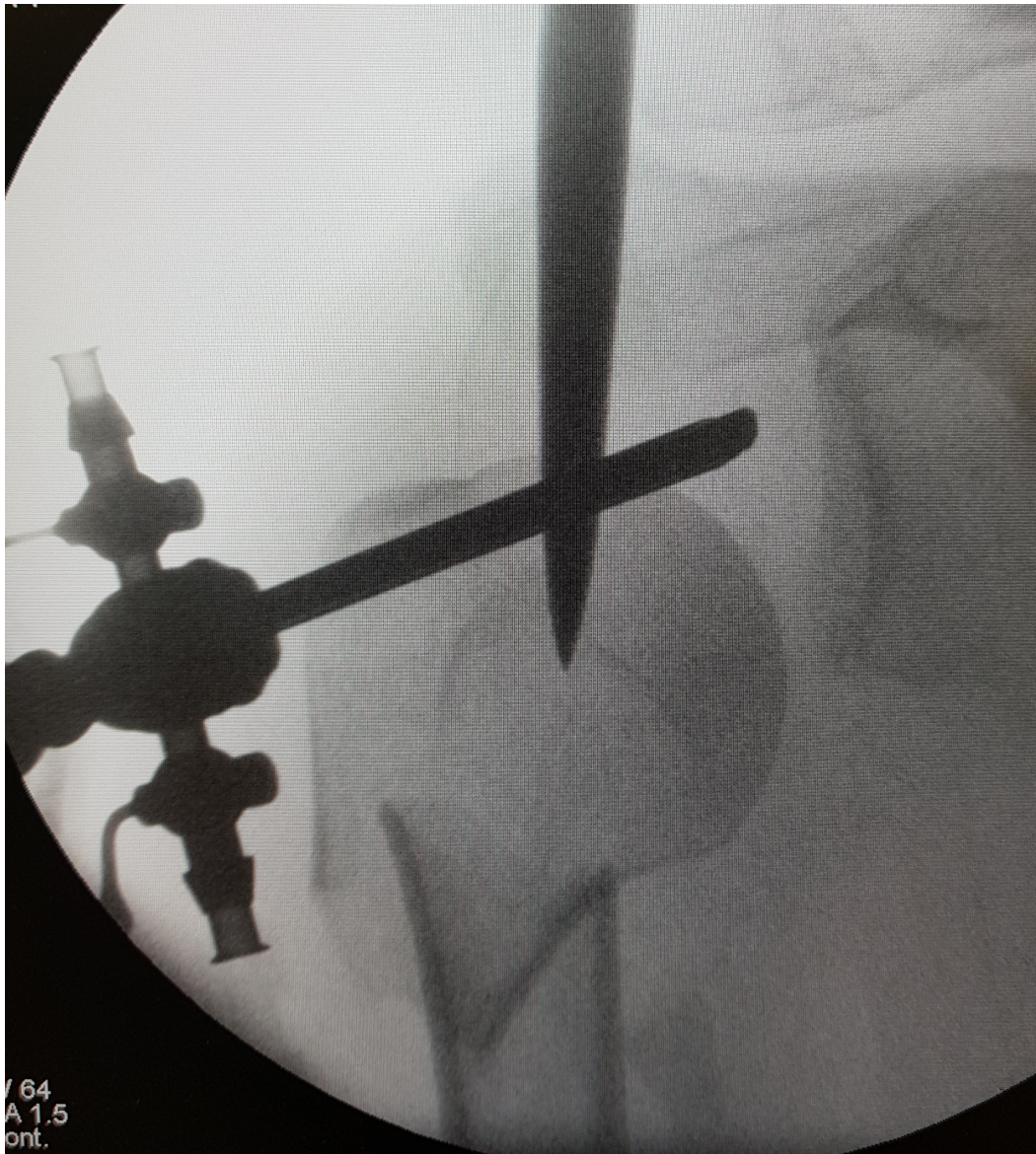


Image : Contrôle scopique lors de la mise en place du guide d'alésage

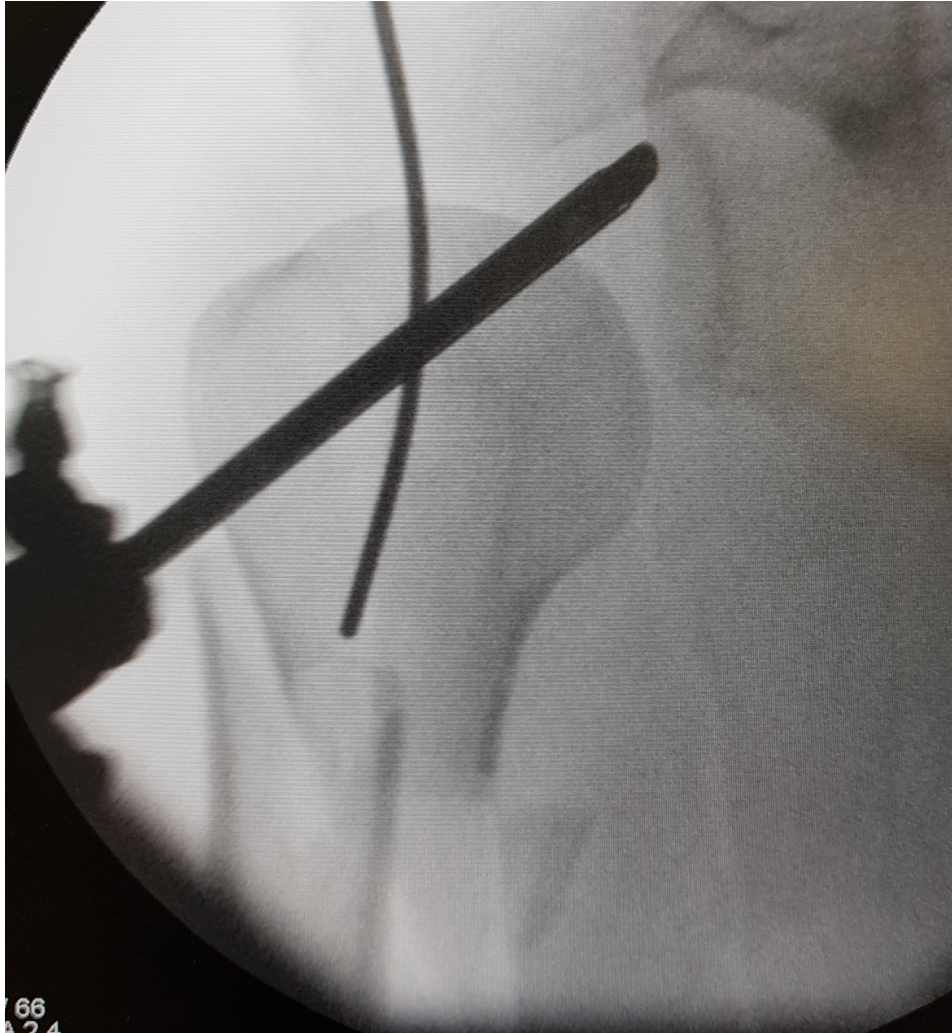
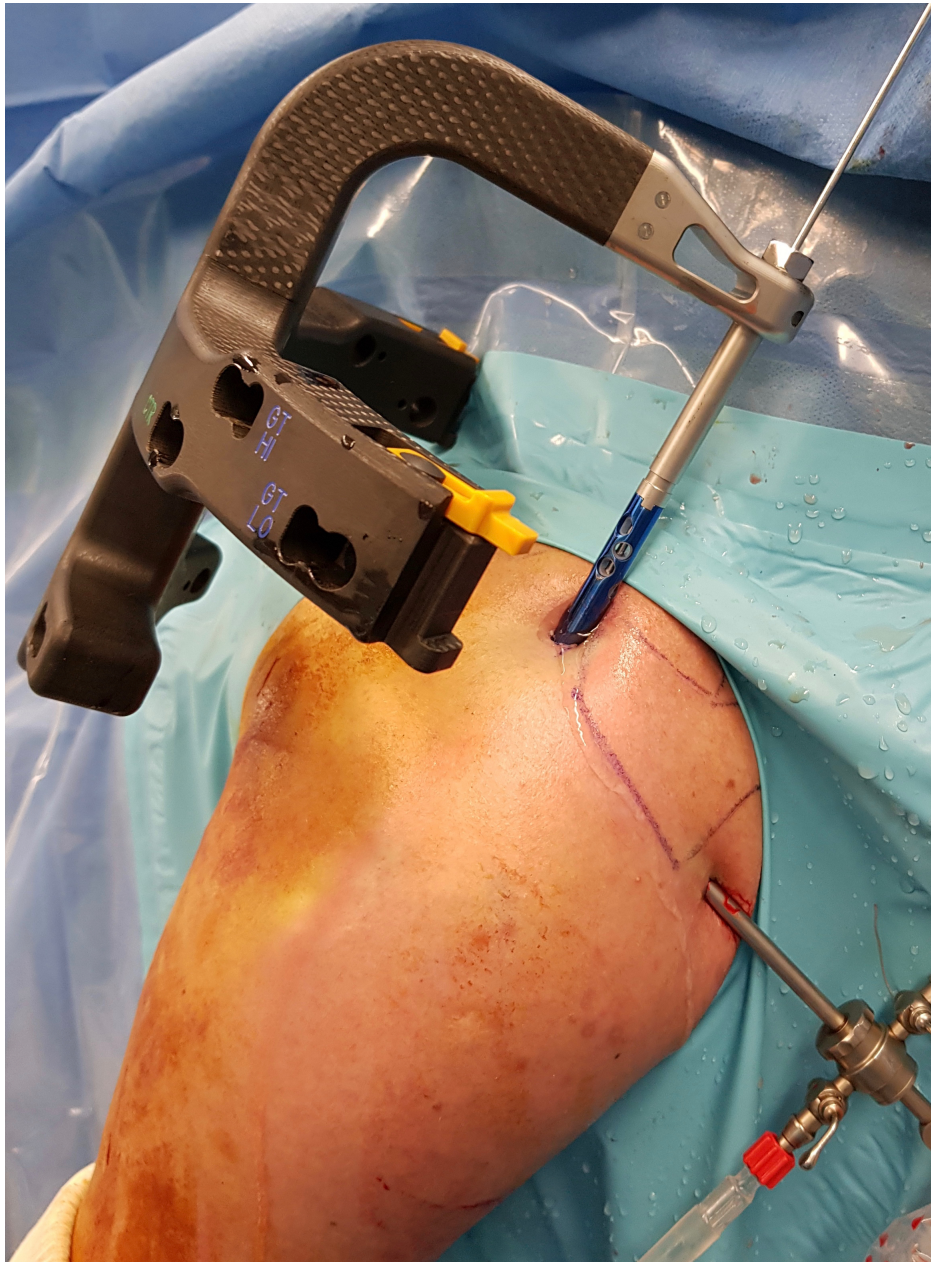


Image : Introduction du clou par le portail antérieur



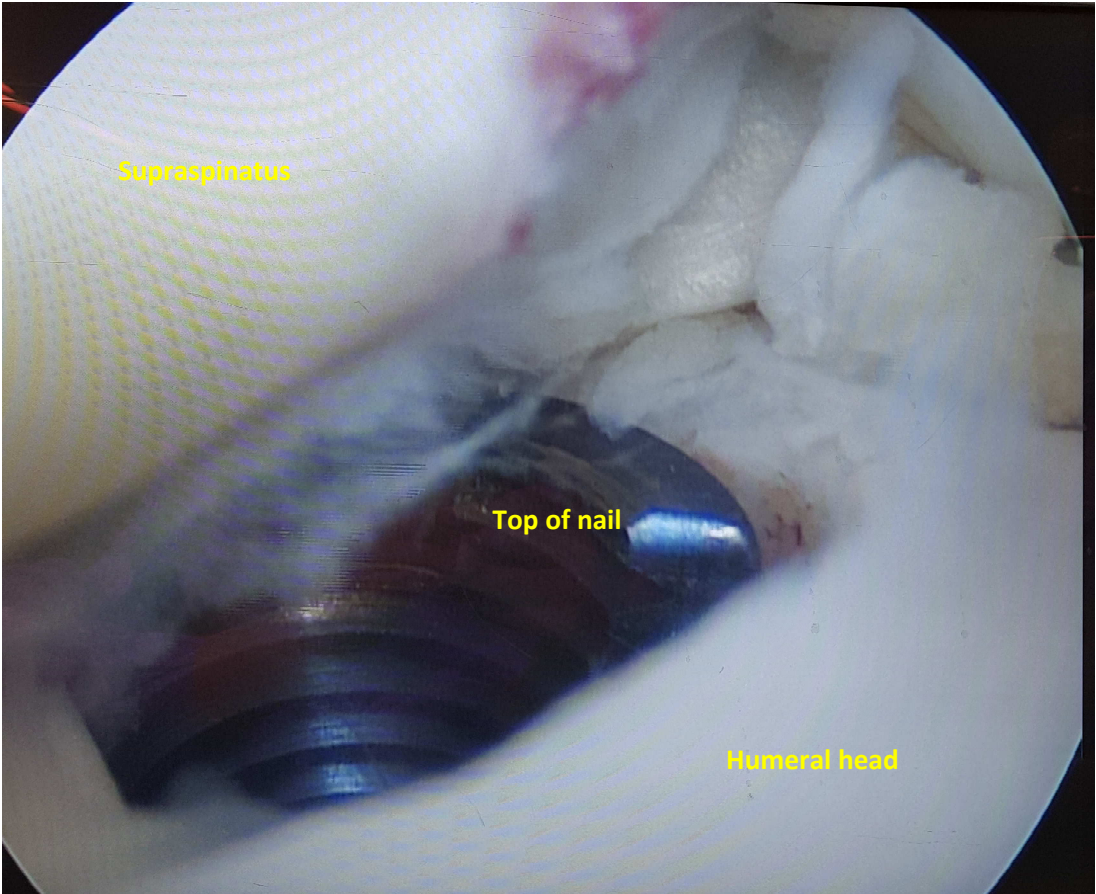
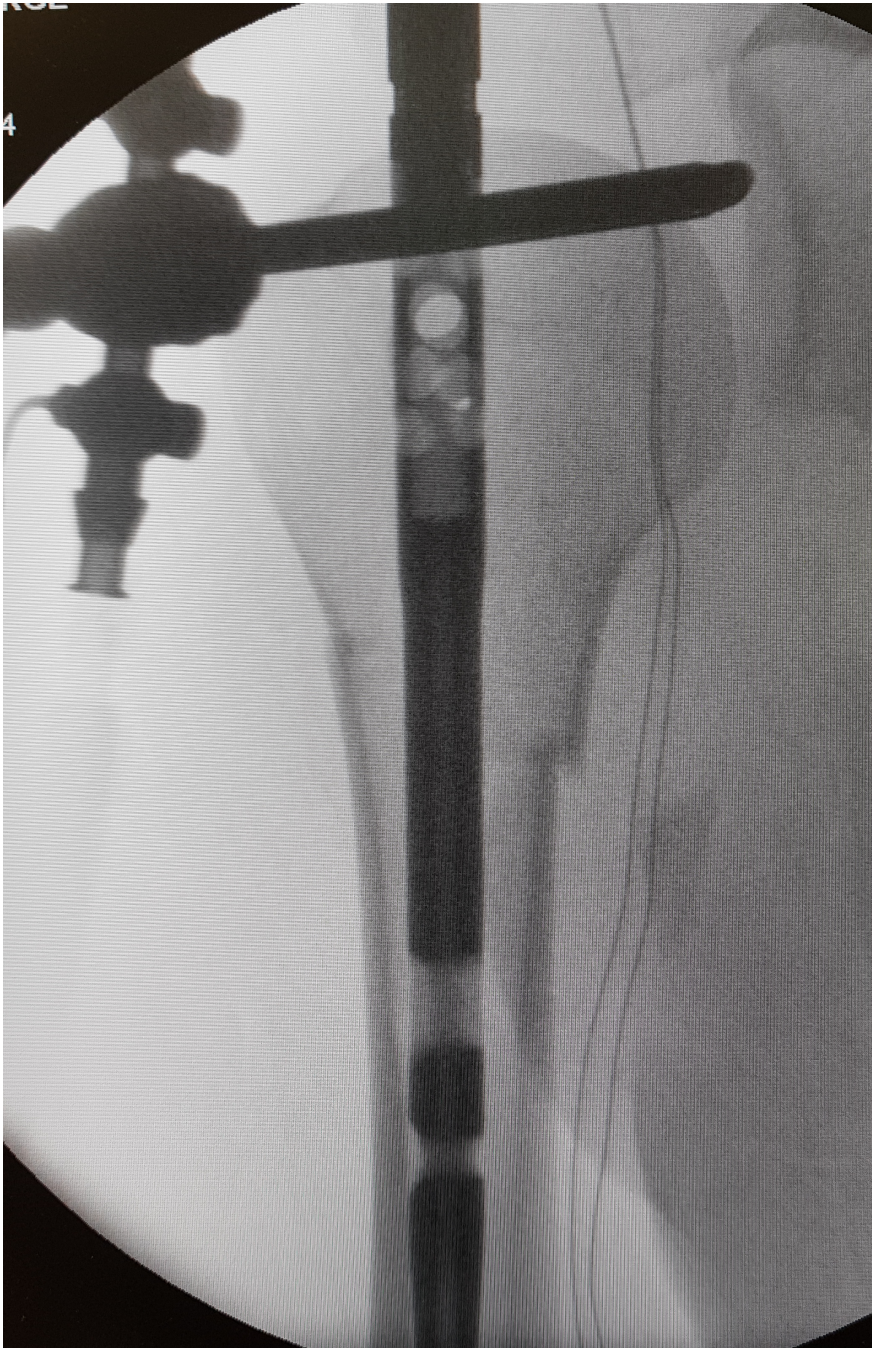
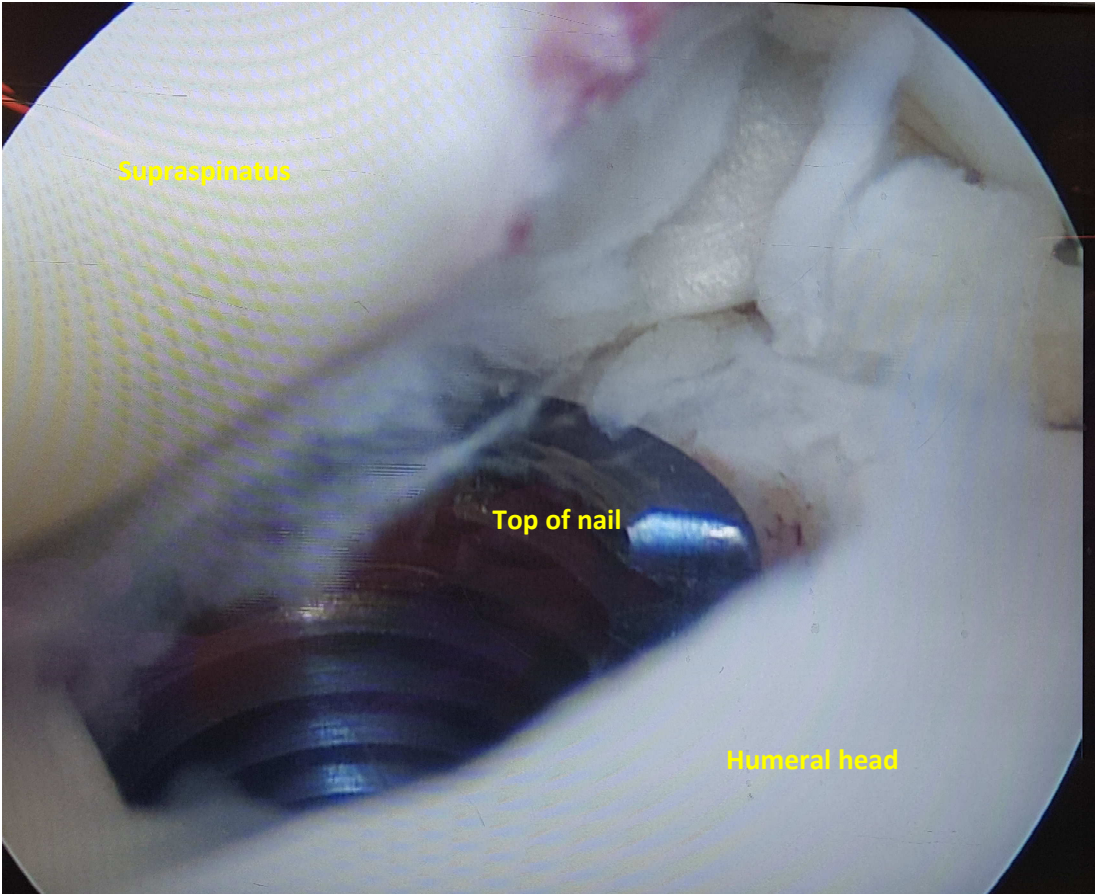


Image : Contrôle radioscopique hauteur clou





Supraspinatus

Top of nail

Humeral head

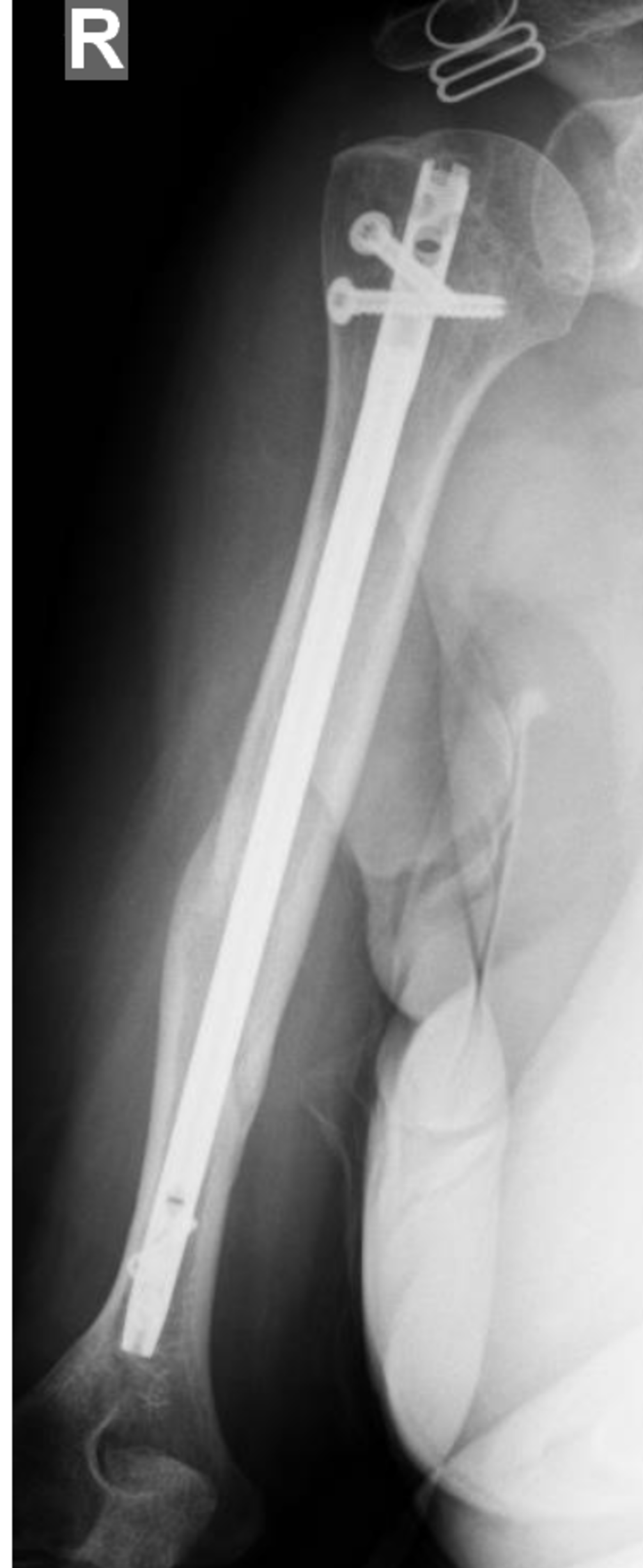
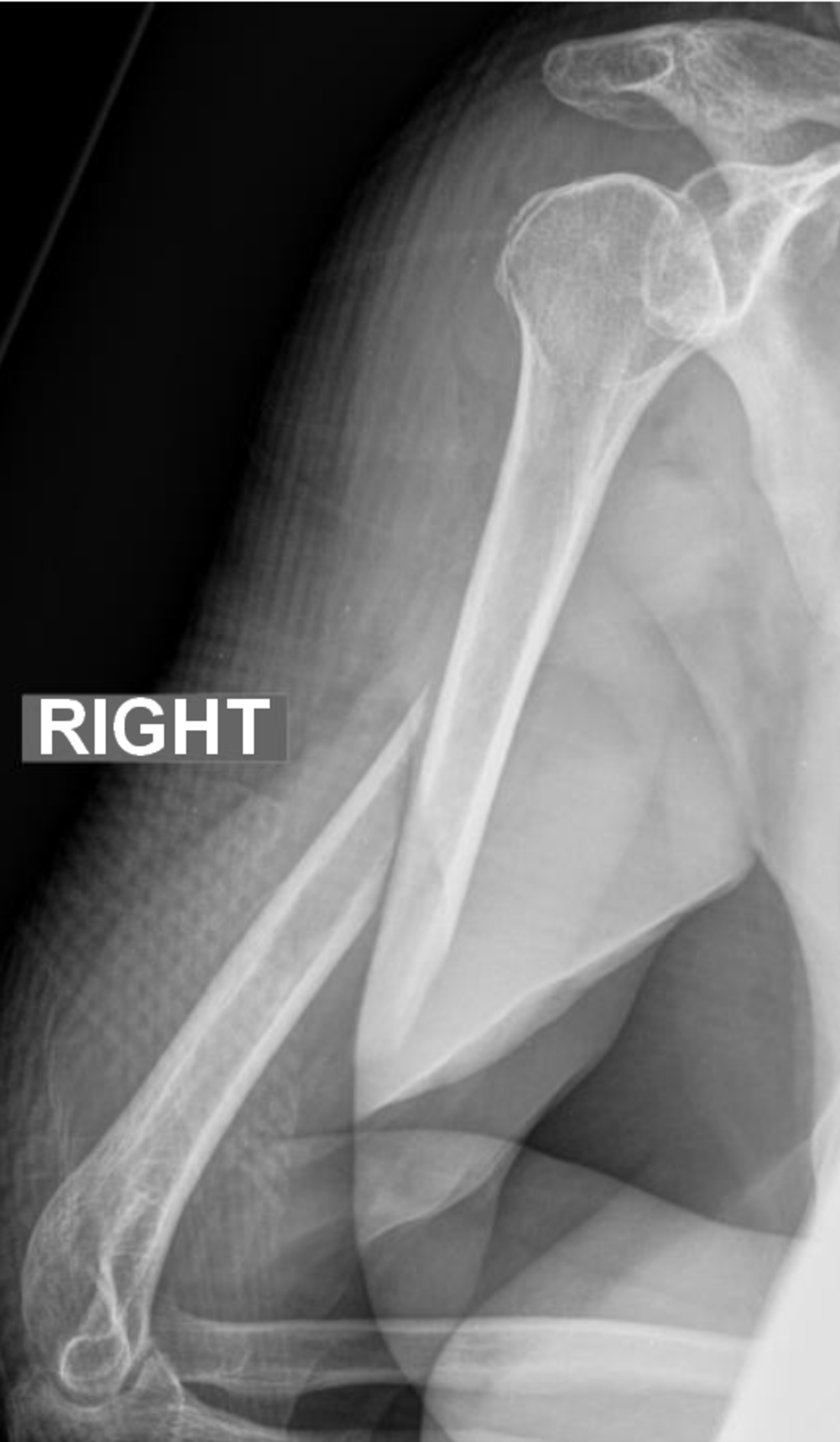

Figure 8b : Exemple de radiographies préopératoire, postopératoires et au dernier recul

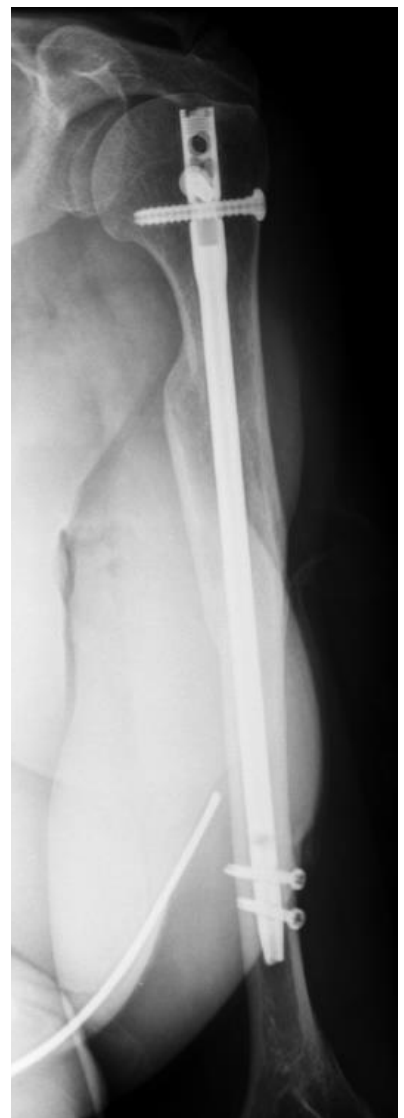
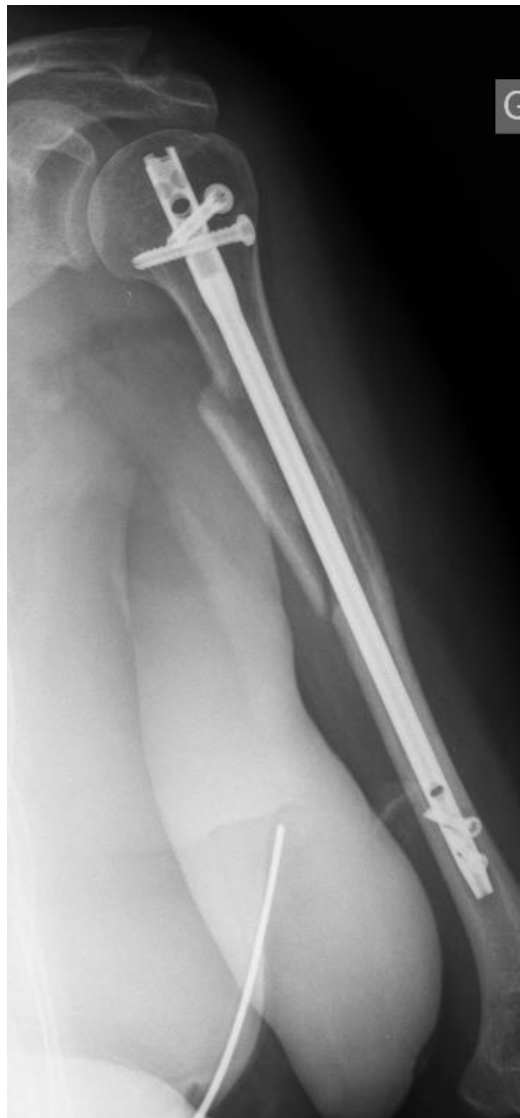
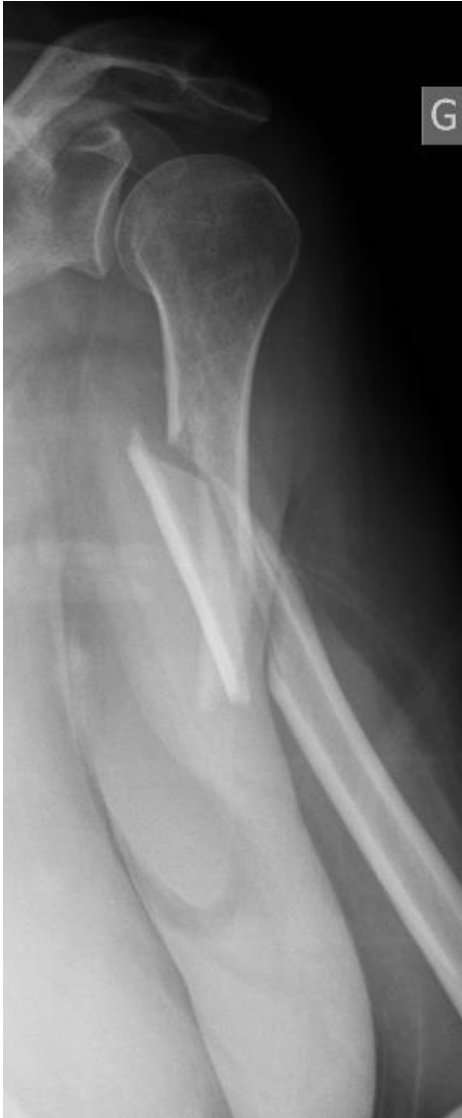Figure 8c : Exemples de radiographies pré-opératoires et à 1 an

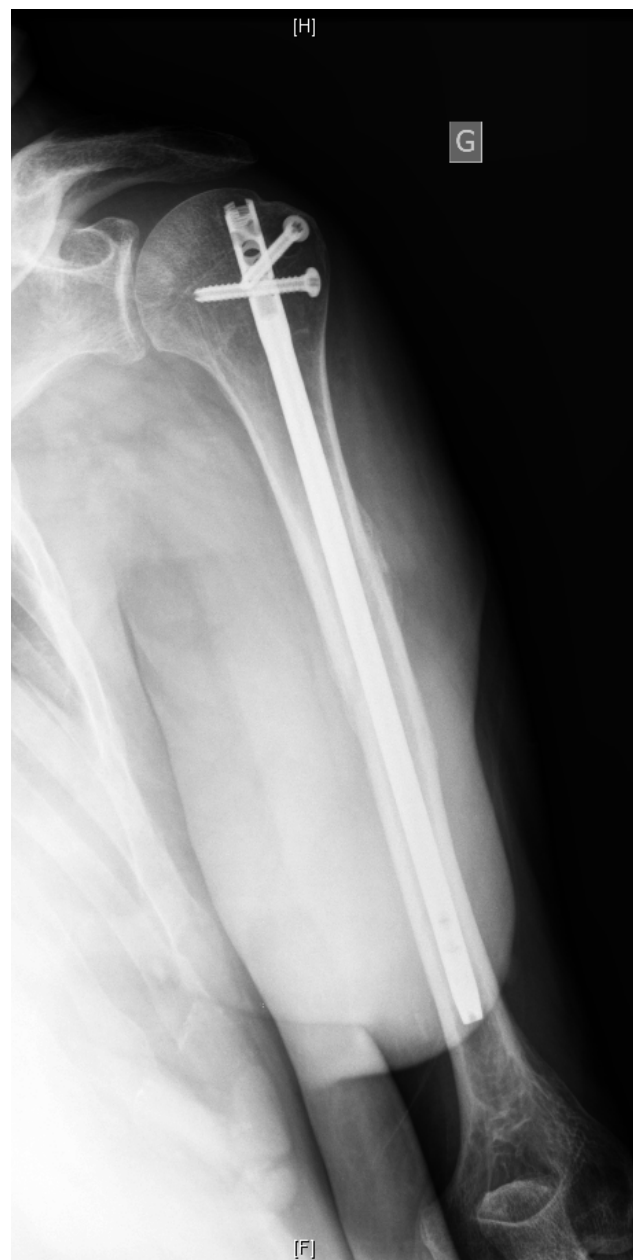
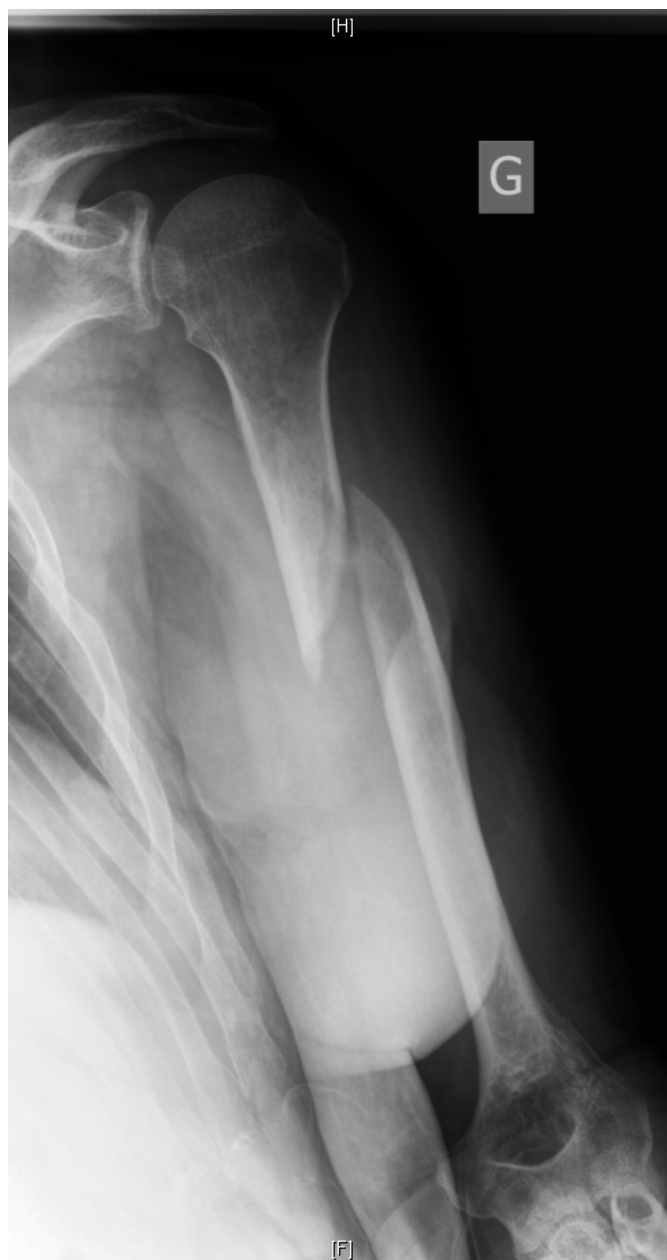
Figure 9 : Radiographies pré-opératoire et au dernier recul (pseudarthrose)

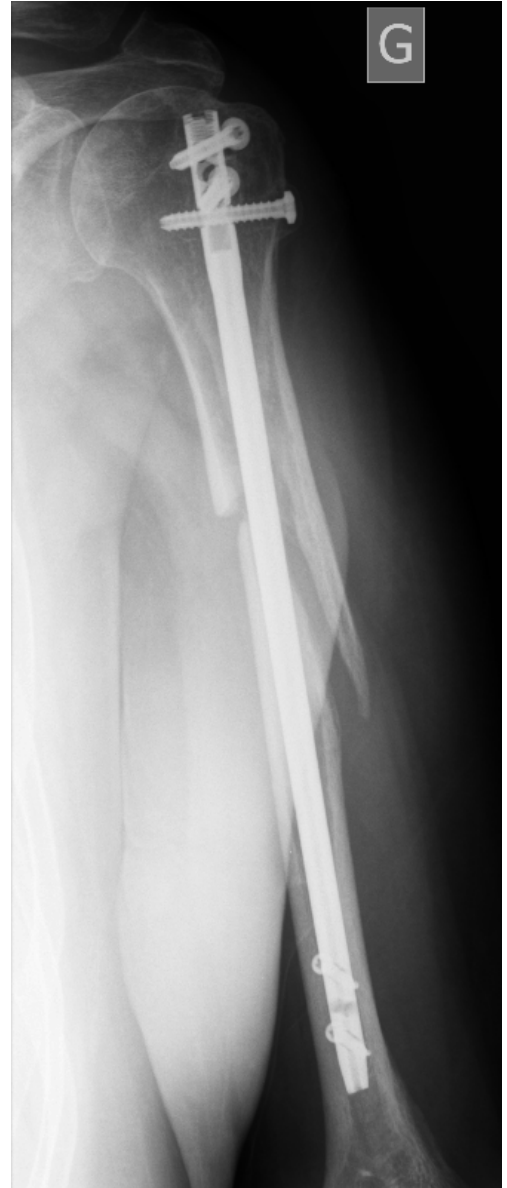
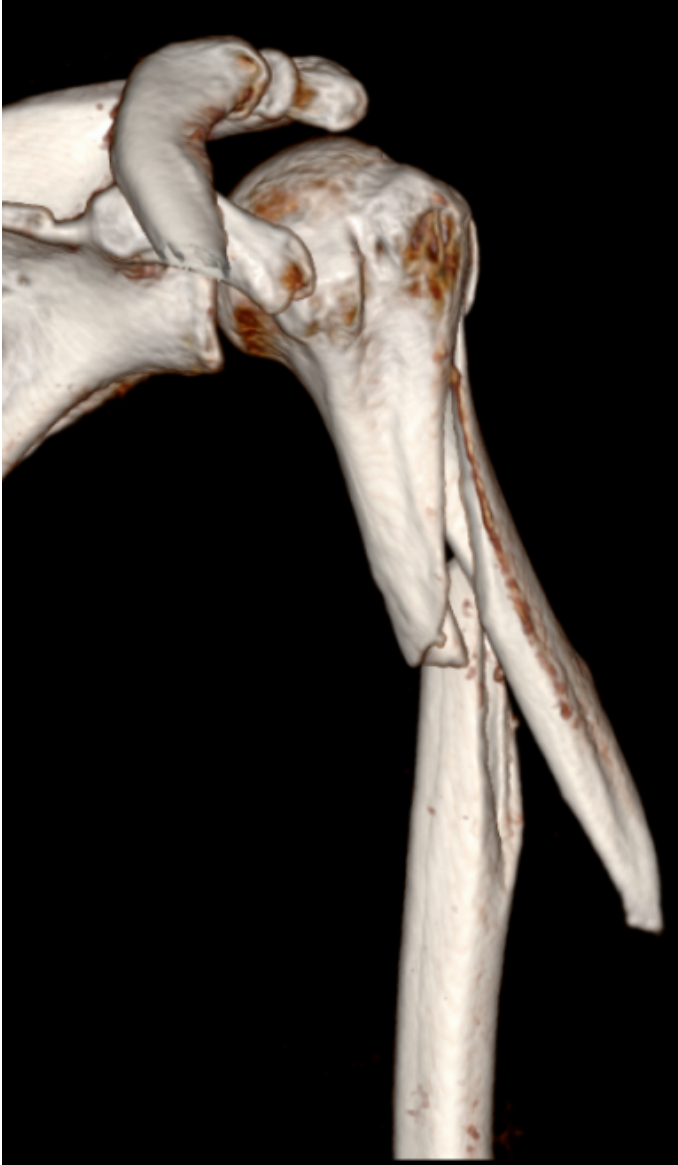
Figure 10 : Cicatrices au dernier recul

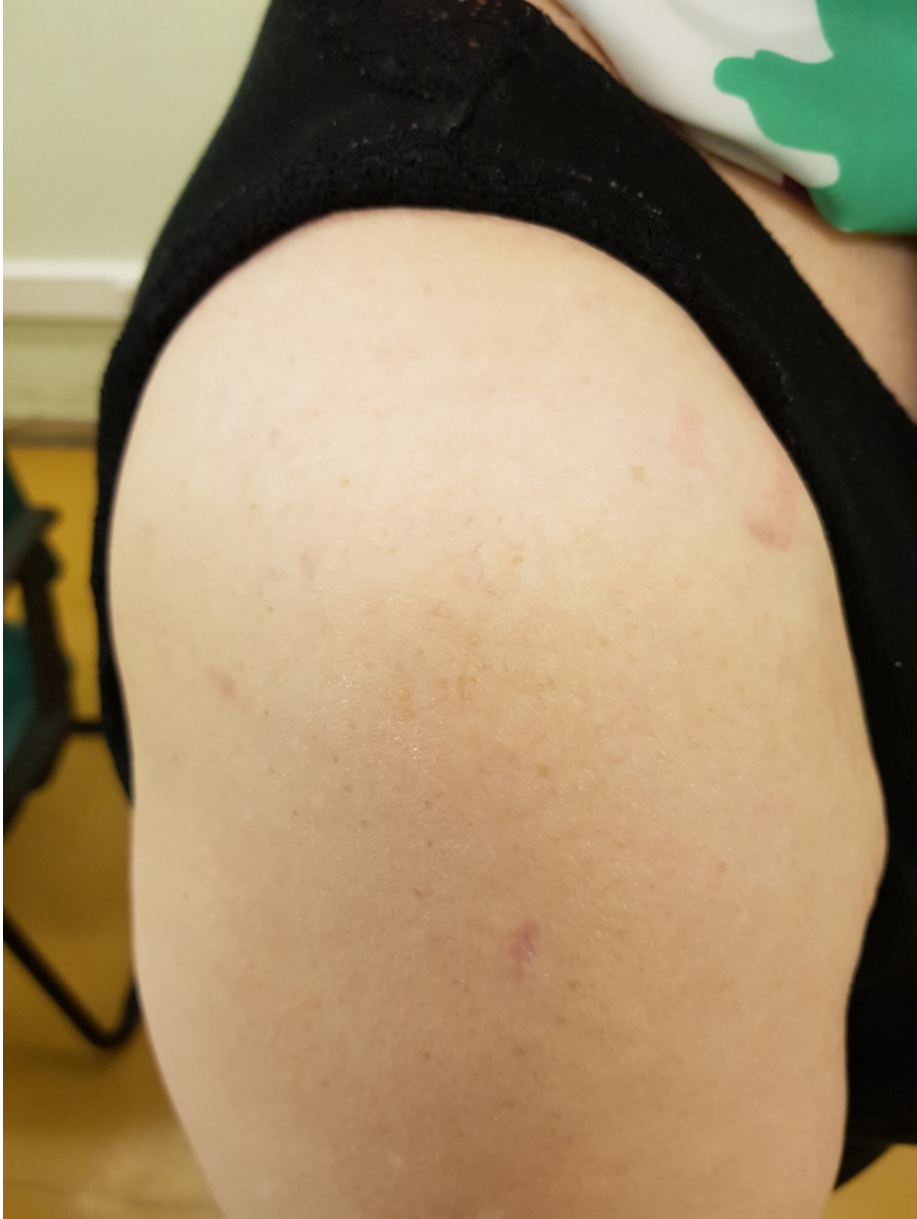


Figure 11 : Clou dépassant le cartilage de la tête humérale

