



HAL
open science

The detection of three new *Haemaphysalis* ticks (Acari: Ixodidae) in Singapore and their potential threat for public health, companion animals, and wildlife

Mackenzie L Kwak, Abigail Ng

► **To cite this version:**

Mackenzie L Kwak, Abigail Ng. The detection of three new *Haemaphysalis* ticks (Acari: Ixodidae) in Singapore and their potential threat for public health, companion animals, and wildlife. *Acarologia*, 2022, 62 (4), pp.927-940. 10.24349/fz2l-kg9r . hal-03784832

HAL Id: hal-03784832

<https://hal.science/hal-03784832v1>

Submitted on 23 Sep 2022

HAL is a multi-disciplinary open access archive for the deposit and dissemination of scientific research documents, whether they are published or not. The documents may come from teaching and research institutions in France or abroad, or from public or private research centers.

L'archive ouverte pluridisciplinaire **HAL**, est destinée au dépôt et à la diffusion de documents scientifiques de niveau recherche, publiés ou non, émanant des établissements d'enseignement et de recherche français ou étrangers, des laboratoires publics ou privés.



Distributed under a Creative Commons Attribution 4.0 International License

Acarologia

A quarterly journal of acarology, since 1959
Publishing on all aspects of the Acari

All information:

<http://www1.montpellier.inra.fr/CBGP/acarologia/>
acarologia-contact@supagro.fr



**Acarologia is proudly non-profit,
with no page charges and free open access**

Please help us maintain this system by
encouraging your institutes to subscribe to the print version of the journal
and by sending us your high quality research on the Acari.

Subscriptions: Year 2022 (Volume 62): 450 €

<http://www1.montpellier.inra.fr/CBGP/acarologia/subscribe.php>

Previous volumes (2010-2020): 250 € / year (4 issues)

Acarologia, CBGP, CS 30016, 34988 MONTFERRIER-sur-LEZ Cedex, France

ISSN 0044-586X (print), ISSN 2107-7207 (electronic)

The digitalization of Acarologia papers prior to 2000 was supported by Agropolis Fondation under the reference ID 1500-024 through the « Investissements d'avenir » programme (Labex Agro: ANR-10-LABX-0001-01)



Acarologia is under free license and distributed under the terms of the Creative Commons-BY

The detection of three new *Haemaphysalis* ticks (Acari: Ixodidae) in Singapore and their potential threat for public health, companion animals, and wildlife

Mackenzie L. Kwak ^a, Abigail Ng ^b

^aDepartment of Biological Science, National University of Singapore, 16 Science Drive 4, (117558) Singapore.

^bMount Pleasant Veterinary Centre, 2 Jln Gelenggang, (578187) Singapore.

Original research

ABSTRACT

Efforts to safeguard human and animal health against ticks and tick-borne diseases are principally reliant on careful surveillance. Within Singapore, the importance of ticks and tick-borne diseases is increasingly recognized. However, developing foundational knowledge of the local diversity of ticks and tick-borne microbes, as well as their ecology, is ongoing. Nation-wide surveillance efforts revealed the presence of three previously unreported species of *Haemaphysalis* from Singapore, namely: *H. bispinosa*, *H. hystricis*, and *H. wellingtoni*. All three species are known to feed on humans and appear to have established populations within Singapore. We record the first infestation of humans by *H. hystricis* and *H. wellingtoni* within Singapore and present all known local host records from these three newly detected tick species. The threat posed by these species to local public health, companion animals, and wildlife is discussed.

Keywords tick-borne disease; exotic tick; invasive species; *Haemaphysalis wellingtoni*; *Haemaphysalis hystricis*; *Haemaphysalis bispinosa*

Introduction

Ticks and tick-borne diseases can pose major challenges to the health of humans, animals, and ecosystems (Dantas-Torres *et al.* 2012). Human and animal health can be affected when non-native ticks invade new ecosystems, or when the ecology of native ticks is altered by anthropogenic changes (Léger *et al.* 2013; Medlock *et al.* 2013). The recent invasion of *Haemaphysalis longicornis* in North America is just one example of the serious impacts that the introductions of exotic tick species can have in new regions (Rainey *et al.* 2018). In an era of global interconnectedness, biosurveillance has never been more crucial to preventing the introduction and establishment of non-native ticks. Biosurveillance requires participation from local clinicians, veterinarians, and national ministries, as well as the general public. It is also critically dependent on both a detailed understanding of the local tick fauna and extensive monitoring efforts to detect changes in community composition or the emergence of novel species.


Singapore is a tropical nation with an abundance of both natural and artificial green spaces, as well as a high human population density (Henderson 2013). This has resulted in overlaps in land use between humans and wildlife, and occasionally direct conflict (Yeo and Neo 2010; Yong *et al.* 2010). However, this overlap can also have less obvious consequences such as an

Received 13 August 2021

Accepted 27 July 2022

Published 16 September 2022

Corresponding author

Mackenzie L. Kwak 

mackenziekwak@gmail.com

Academic editor

McCoy, Karen

<https://doi.org/10.24349/fz21-kg9r>

ISSN 0044-586X (print)

ISSN 2107-7207 (electronic)



Kwak M. L. and Ng A.

Licensed under

Creative Commons CC-BY 4.0



How to cite this article Kwak M. L. and Ng A. (2022), The detection of three new *Haemaphysalis* ticks (Acari: Ixodidae) in Singapore and their potential threat for public health, companion animals, and wildlife. *Acarologia* 62(4): 927-940. <https://doi.org/10.24349/fz21-kg9r>

increased potential for zoonotic spillover. A range of zoonotic parasites and pathogens have been detected in wildlife in Singapore including parasitic worms (Mendenhall *et al.* 2018), ticks (Kwak *et al.* 2021a), bacteria (Neves *et al.* 2018) and arboviruses (Yap *et al.* 2019). Local interest in ticks and tick-borne diseases has only emerged recently and has built upon a small number of historical studies (e.g., Theis and Franti 1971; Paperna 2006; Leong 2010). In recent years, more intensive efforts have been made to survey the diversity of ticks in Singapore (Kwak 2018), along with their host associations (Kwak *et al.* 2018; 2019; 2021a), ecologies and zoonotic potential (Kwak 2021a; 2021b).

Within Singapore, three members of the genus *Haemaphysalis* have previously been recorded, namely *H. doenitzi*, *H. nadchatrami*, and *H. semermis* (Hoogstraal *et al.* 1966; Hoogstraal and Wassef 1973; Kwak 2018). However, nation-wide biosurveillance efforts in Singapore revealed the presence of *Haemaphysalis* specimens which did not match the descriptions of the three known species. Three new species were found, doubling the *Haemaphysalis* fauna known from Singapore and represents three species known to bite humans. We describe the biosurveillance work below and discuss its importance in terms of public health.

Material and methods

Beginning in 2018, Singapore's first nationwide tick surveillance program was initiated; it involved a network of veterinarians, clinicians, and field biologists who sourced ticks from humans, companion animals, wildlife, and the environment. Under this program, ticks were collected opportunistically from human and animal hosts by careful removal using tweezers. Opportunistic flagging was also undertaken to collect ticks from the environment (e.g., from vegetation and leaf litter). All collected ticks were fixed in ethanol (70-100%) for later identification.

Between 2018 and 2021, a total of 2,163 ticks were collected across Singapore (Figure 1) from 303 individual hosts representing 40 different species (Table 1), as well as from local vegetation. All ticks were examined using a LEICA M80 light microscope. Specimens were retained within the Singapore National Tick Reference Collection (SNTRC) presently held within the Medical Faculty (Yong Loo Lin School of Medicine) at the National University of Singapore and curated by one of the authors (M. L. Kwak). Among the specimens collected, three tick taxa were identified which did not belong to known species from Singapore. These taxa were identified to species level based on keys and descriptions from Yamaguti *et al.* (1971), Tanskul and Inlao (1989), Trapido *et al.* (1964), Hoogstraal *et al.* (1965), and Geevarghese and Mishra (2011).

Results

The three unknown taxa were confirmed as members of the genus *Haemaphysalis* based on a combination of: 1) lack of eyes, 2) base of palpal article 2 flared laterally, 3) festoons. All three taxa were then confirmed as members of the subgenus *Kaiseriana* based on a combination of: 1) presence of a spur on the posteroventral edge of palpal article III, 2) presence of a spur on the posterodorsal edge of palpal article III. Females, males, nymphs, and larvae were collected for the three species (except for *H. hystricis* for which the male stage was not collected), each specimen was individually identified.

The females of the first unknown *Haemaphysalis* taxon had the following combination of characters: 1) 4/4 dentition, 2) scutum longer than wide, 3) internal, retroverted spur extending from posterodorsal edge of palpal article III, 4) internal, retroverted spur extending from posteroventral edge of palpal article III, 5) short, blunt cornuae. The males of this taxon had: 1) medium sized blunt cornuae, 2) small, blunt, posterointernally directed spur on dorsal surface of palpal article III, 3) lateral grooves on conscutum, 4) blunt, distinctive spurs of similar size on all coxae, 5) spurs on trochanters (though smaller on trochanter III and IV),

Table 1 Host species from which ticks were collected in Singapore.

Host species	Common name	Number of hosts sampled	Captive/Wild
<i>Boiga dendrophila</i>	Gold-ringed cat snake	1	Wild
<i>Callosciurus notatus</i>	Plantain squirrel	4	Wild
<i>Canis familiaris</i>	Domestic dog	41	Wild
<i>Crocodylus porosus</i>	Saltwater crocodile	1	Wild
<i>Cuora amboinensis</i>	Amboina box turtle	2	Wild
<i>Eonycteris spelaea</i>	Cave nectar bat	14	Wild
<i>Felis catus</i>	Domestic cat	1	Wild
<i>Galeopterus variegatus</i>	Sunda colugo	1	Wild
<i>Gallus gallus</i>	Jungle fowl	3	Wild
<i>Heosemys spinosa</i>	Spiny hill turtle	2	Wild
<i>Homo sapiens</i>	Human	30	Wild
<i>Lanius cristatus</i>	Brown shrike	1	Wild
<i>Laticauda colubrina</i>	Yellow-lipped sea krait	3	Wild
<i>Malayopython reticulatus</i>	Reticulated python	53	Wild
<i>Manis javanica</i>	Sunda pangolin	47	Wild
<i>Mus castaneus</i>	Southeast Asian house mouse	1	Wild
<i>Ophiophagus hannah</i>	King cobra	14	Wild
<i>Penthetor lucasi</i>	Dusky fruit bat	6	Wild
<i>Pitta moluccensis</i>	Blue-winged pitta	1	Wild
<i>Rattus annandalei</i>	Annandale's rat	24	Wild
<i>Rattus tanezumi</i>	Asian house Rat	7	Wild
<i>Rattus tiomanicus</i>	Malaysian wood rat	1	Wild
<i>Suncus murinus</i>	Asian house shrew	1	Wild
<i>Sus scrofa</i>	Wild boar	17	Wild
<i>Tragulus napu</i>	Greater mouse-deer	1	Wild
<i>Tupaia glis</i>	Tree shrew	2	Wild
<i>Varanus nebulosus</i>	Clouded monitor	1	Wild
<i>Varanus salvator</i>	Asian water monitor	2	Wild
<i>Acrocodia indica</i>	Malayan tapir	3	Captive
<i>Ailuropoda melanoleuca</i>	Giant panda	6	Captive
<i>Ailurus fulgens</i>	Red panda	1	Captive
<i>Alligator sinensis</i>	Chinese alligator	1	Captive
<i>Arctictis binturong</i>	Binturong	2	Captive
<i>Axis porcinus</i>	Indian hog deer	1	Captive
<i>Dendrolagus goodfellowi</i>	Goodfellow's tree kangaroo	2	Captive
<i>Macropus giganteus</i>	Eastern grey kangaroo	1	Captive
<i>Neofelis nebulosa</i>	Asian cloud leopard	1	Captive
<i>Nycticebus coucang</i>	Sunda slow loris	1	Captive
<i>Paleosuchus palpebrosus</i>	Cuvier's dwarf caiman	2	Captive
<i>Suricata suricatta</i>	Meerkat	1	Captive

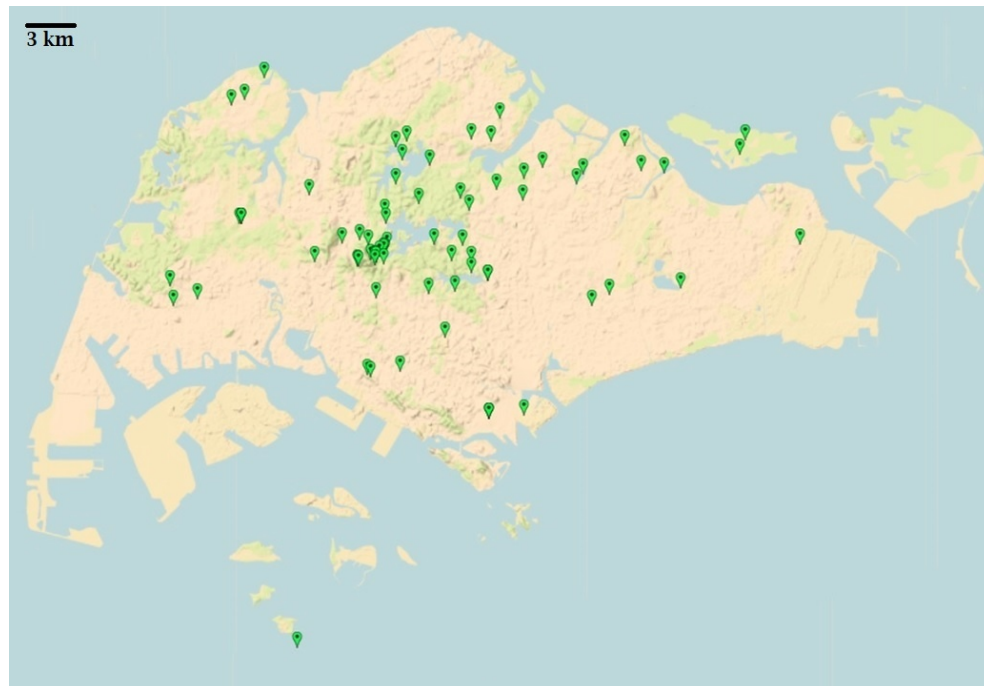


Figure 1 Locations across Singapore from which ticks (including *Haemaphysalis*) were collected between 2018-2021 as part of nation-wide tick surveillance efforts.

large, pointed posterointernally directed spur on ventral surface of palpal article III, 6) 4/4 dentition throughout most of hypostome. The nymphs were characterized by: 1) 2/2 dentition, 2) a distinctively larger spur on coxa II than on coxa I, 3) cornuae blunt and small, 4) coxal spurs pointed, 5) lateral salience on palpal article II shallow with dorsal surface of article II of similar width to article III, 6) obvious spurs on trochanters I and II, 7) posterointernally directed spur on dorsal surface of palpal article III. Finally, the larvae had the following combination of characters: 1) lateral edge of palpal article II distinctly rounded, 2) cornuae absent, 3) distinctive, broad, blunt spurs present on all coxae, 4) scutum width less than 1.5 times that of length, 5) posterointernally directed spur on ventral surface of palpal article III. These character combinations distinguished each life stage as *H. wellingtoni* (Figure 2 a, b). In total, 94 *H. wellingtoni* were collected from 10 individual hosts during the period from 2018 – 2021 (Table 2). During this time period of the tick surveillance program, we recorded one case of human infestation by a *H. wellingtoni* larva.

Females of the second newly detected *Haemaphysalis* taxon had the following combination of characters: 1) 4/4 dentition, 2) palps with slight basolateral salience, 3) posterodorsal spur of palpal segment III overlapping anterior quarter or more of segment II, 4) spurs of coxa IV short, broadly ridgelike, 5) Posterodorsal spur of palpal segment III overlapping anterior

Table 2 Numbers of each life stage of *H. bispinosa*, *H. hystricis*, and *H. wellingtoni* collected in Singapore (both on-host and off-host) between 2018 – 2021.

	Total	Females	Males	Nymphs	Larvae
<i>H. bispinosa</i>	251	61	86	83	21
<i>H. hystricis</i>	29	8	0	2	19
<i>H. wellingtoni</i>	94	15	66	5	8




Figure 2 Adult female *Haemaphysalis* ticks from the three species newly recorded in Singapore. A) *Haemaphysalis wellingtoni* dorsal view, B) *Haemaphysalis wellingtoni* ventral view, C) *Haemaphysalis bispinosa* dorsal view, D) *Haemaphysalis bispinosa* ventral view, E) *Haemaphysalis hystricis* dorsal view, F) *Haemaphysalis hystricis* ventral view

third of segment II. Males were characterized by: 1) 4/4 dentition, 2) lateral grooves on conscutum, 3) large posterointernally directed spur on dorsal surface of palpal article III, 4) large posterointernally directed spur on ventral surface of palpal article III, 5) blunt salience on lateral edge of palpal article II, 6) large, blunt cornuae, 7) spurs on all coxae, 8) broad blunt spur on coxa IV, 9) spurs on all trochanters. Nymphs had the following combination of characters: 1) 2/2 dentition, 2) moderately flared lateral salience on palpal article II, 3) spurs on all coxae, 4) small, blunt, wide spur on coxa IV, 5) small, blunt cornuae, 6) small, blunt posterointernally directed spur on ventral surface of palpal article III. Finally, larvae of this taxon had: 1) 2/2 dentition, 2) weakly flared lateral salience on palpal article II, 3) spurs present on all coxae, 4) coxae II and III with a shallow, wide, blunt, spur, 5) scutum almost twice as wide as long, 6) extremely small, subtle cornuae present, 7) posterointernally directed spur on ventral surface of palpal article III. These character combinations distinguished each life stage as *H. bispinosa* (Figure 2 c, d). In total, 251 *H. bispinosa* were collected from 22 individual hosts during the period from 2018 – 2021 (Table 2).

Females of the third newly detected *Haemaphysalis* taxon in Singapore had the following combination of characters: 1) 4/4 dentition, 2) palps with slight basolateral salience, 3) posterodorsal spur of palpal segment III overlapping anterior quarter or more of segment II, 4) spurs of coxa IV distinct and not ridge-like with a narrowly rounded apex, 5) posterodorsal spur of palpal segment III overlapping anterior quarter of segment II. Nymphs were characterized by: 1) 2/2 dentition, 2) widely flared lateral salience on palpal article II, 3) lateral edge of lateral salience on palpal article II rounded, 4) small, bluntly rounded cornuae, 5) short, blunt, broad spurs on all coxae, 6) spur on coxae IV distinctly smaller than those on other coxae, 7) small, blunt posterointernally directed spur on ventral surface of palpal article III, 8) spur on coxa I short. Finally, larvae of this taxon had: 1) 2/2 dentition, 2) widely flared lateral salience on palpal article II, 3) spurs present on all coxae, 4) coxae III with extremely small, blunt spur, 5) scutum approximately 1.5 times wide as long. These character combinations were distinctive of each life stage of *H. hystricis* (Figure 2 e, f). In total, 24 *H. hystricis* were collected from 9 individual hosts during the period from 2018 – 2021 (Table 2). Notably, no males were collected. Over the 2018 – 2021 time period, we recorded two cases of human infestation, on both occasions by a female *H. hystricis*.

All life stages of all taxa were also matched using DNA barcodes generated as part of this work (methods and data not shown). This data will soon to be available in a published DNA barcode library for the ticks of Singapore using the Cytochrome c oxidase subunit I (COI) locus.

An index was compiled of host species in Singapore from which *H. bispinosa*, *H. hystricis*, and *H. wellingtoni* were collected (Table 3). A key to distinguish among the six *Haemaphysalis* species found in Singapore is included in this paper for females (Figure 3), males (Figure 4), and nymphs (Figure 5). As the larvae of *H. semermis* and *H. nadchatrami* have not yet been described, no key is presented for larval *Haemaphysalis* of Singapore.

Discussion

Exotic invaders or overlooked natives?

Identifying a tick fauna and their ecology are key factors to consider when developing management policy for ticks and tick-borne diseases. This information, in conjunction with host interaction data, can help determine whether local eradication efforts could or should be undertaken; especially given that during the early stages of invasion, there is sometimes a chance of eradicating exotic ticks to minimize their impact on native ecosystems. However, the status of particular tick species as native or exotic can be challenging to determine as it can be difficult to differentiate between natural range expansions and anthropogenic introductions of ticks. It can also be complicated by cases of local tick extirpations (both historically or prehistorically) followed by recolonization of their former range. *Dermacentor auratus*

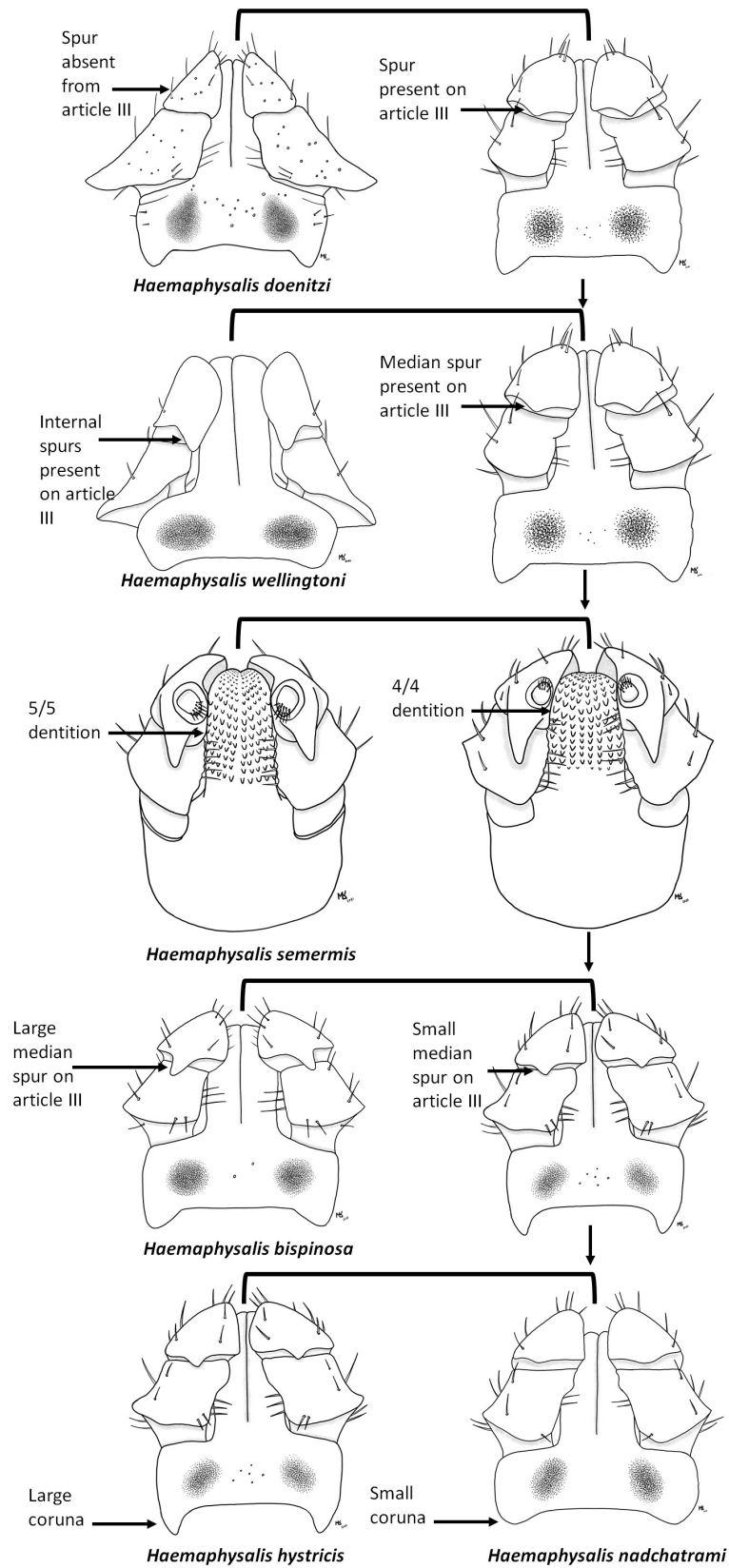


Figure 3 Visual key to female *Haemaphysalis* ticks of Singapore

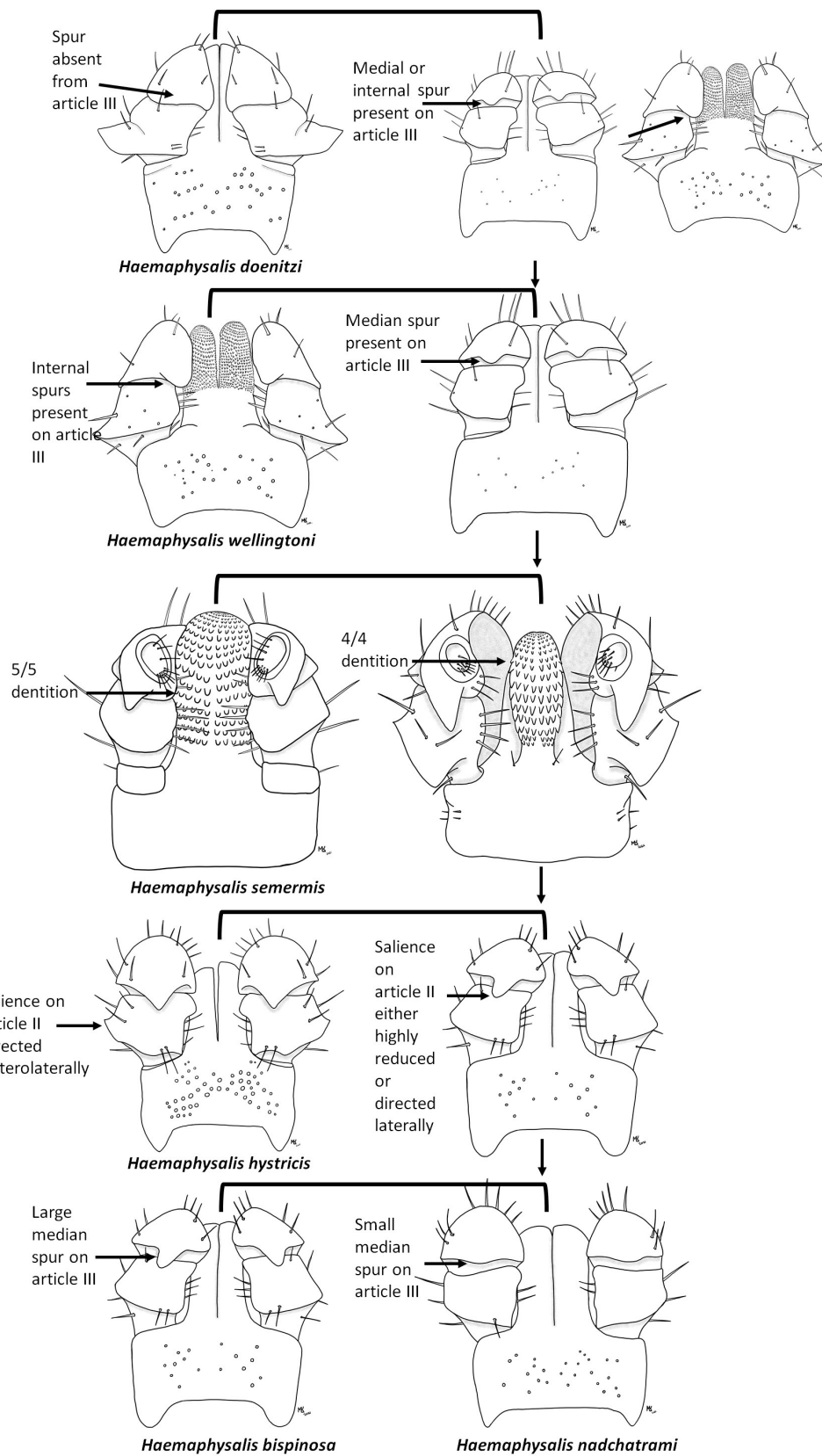


Figure 4 Visual key to male *Haemaphysalis* ticks of Singapore

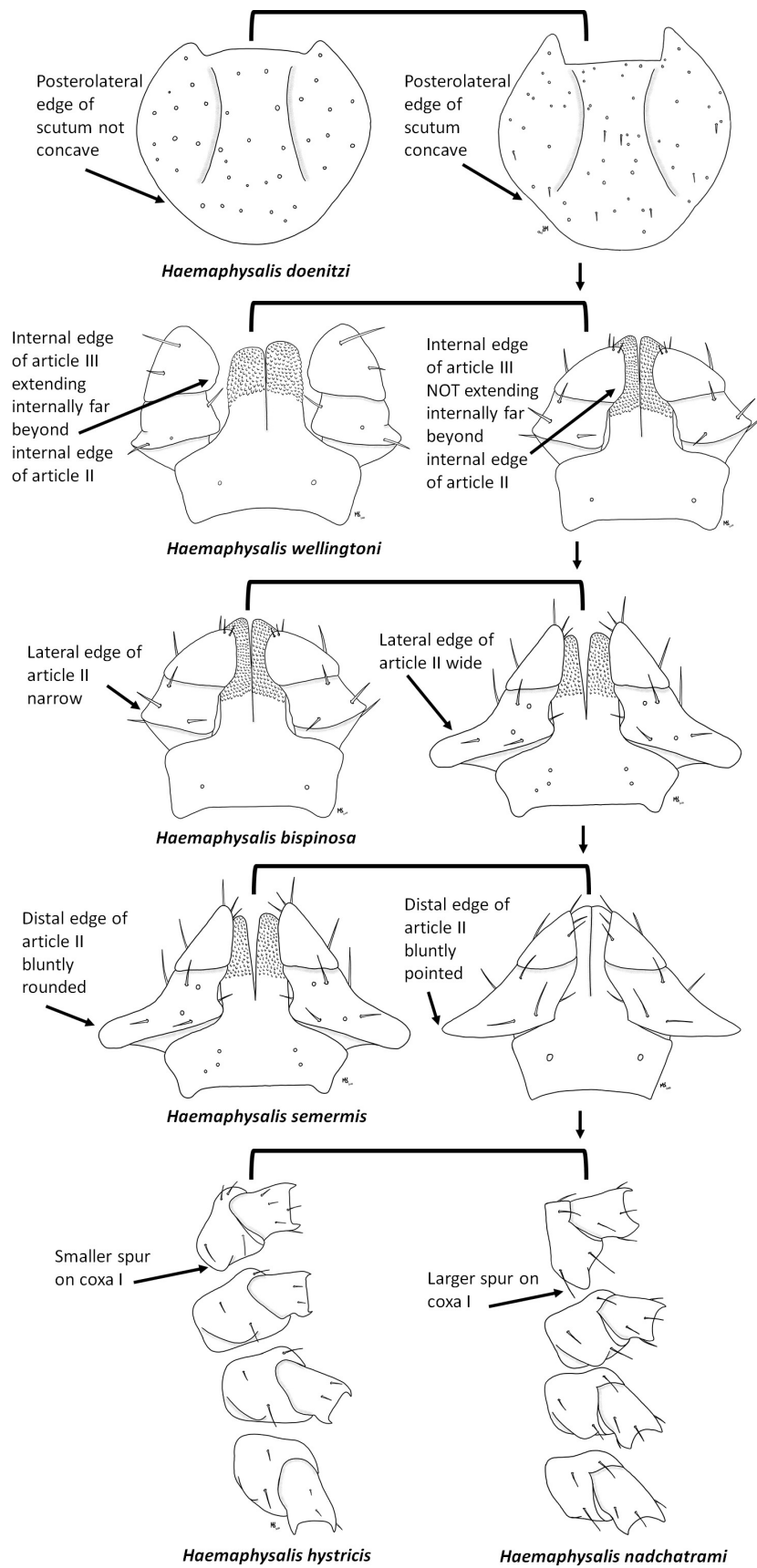


Figure 5 Visual key to nymphal *Haemaphysalis* ticks of Singapore

recently emerged as a major tick of public health importance in Singapore (Kwak *et al.* 2021a). Although apparent absence may initially be interpreted as evidence of *D. auratus* being exotic (Hoogstraal and Wassef 1985), biogeographic and host data suggest that the emergence of *D. auratus* in Singapore is simply an example of a native species reestablishing into a section of its former range after local extirpation (Kwak *et al.* 2021a). While *D. auratus* appears to be native, two non-native ticks have been recorded in Singapore, namely *Rhipicephalus sanguineus* and *R. microplus* (Kwak 2018). The former is a specialist parasite of dogs and the latter (now locally extinct in Singapore) is a specialist of cattle (Guglielmone *et al.* 2014; Kwak 2018).

Among the three *Haemaphysalis* species newly detected in Singapore, *H. bispinosa* is of particular interest as it has long been considered an exotic species on the Malay Peninsula, but native to India (Hoogstraal *et al.* 1969). This is largely because of its synanthropic occurrence in tropical southeast Asia on domestic dogs (*Canis lupus familiaris*), and its general absence from forested habitats and the native species of Carnivora and Artiodactyla which occur within them. The majority of specimens examined in this study were also collected from domestic dogs, though a small number also came from the native banded pig (*Sus scrofa vittatus*) (Table 1). We therefore consider *H. bispinosa* to be an exotic species that was likely introduced with domestic dogs. Although this is the first time *H. bispinosa* has been officially reported from Singapore, historical specimens held in the US national tick collection indicate that this species was present in Singapore at least as far back as 1913 (specimen reference code: USNTC 111274) and was also collected in 1963 (specimen reference code: USNTC 87282). Theis and Franti (1971) undertook an extensive study on dog ticks in Singapore. However, as their study focused on *R. sanguineus* and they did not mention *H. bispinosa*, it is unclear if this species was collected during their work.

Haemaphysalis hystricis is a widely distributed species throughout East Asia and occurs from southern Japan as far south as Indonesia and west into India (Hoogstraal *et al.* 1965; Petney *et al.* 2019). Although it is commonly called the East Asian Mountain haemaphysalid because it is relatively common at high altitudes, *H. hystricis* can also sometimes occur at

Table 3 Number of *H. bispinosa*, *H. hystricis*, and *H. wellingtoni* ticks collected from different host species in Singapore between 2018 – 2021.

Tick species (number of ticks collected on- host/off-host)	Host species	Common name	Wild/Captive	No. ticks
<i>H. bispinosa</i> (250/1)	<i>Acrocodia indica</i>	Malayan tapir	Captive	10
	<i>Axis porcinus</i>	Indian hog deer	Captive	43
	<i>Canis familiaris</i>	Dog	Wild & Captive	195
	<i>Rattus tanezumi</i>	Tanezumi rat	Wild	1
	<i>Rusa unicolor</i>	Sambar deer	Wild	1
<i>H. hystricis</i> (10/19)	<i>Canis familiaris</i>	Dog	Wild	3
	<i>Homo sapiens</i>	Human	-	2
	<i>Rattus annandalei</i>	Annandale's rat	Wild	1
	<i>Rattus tiomanicus</i>	Malayan field rat	Wild	1
	<i>Rusa unicolor</i>	Sambar deer	Wild	1
	<i>Sus scrofa</i>	Wild boar	Wild	2
	<i>H. wellingtoni</i> (94/0)	<i>Gallus gallus</i>	Jungle fowl	Wild
<i>Homo sapiens</i>		Human	-	1
<i>Ixobrychus flavicollis</i>		Black bittern	Wild	1
<i>Lanius cristatus</i>		Brown shrike	Wild	1
<i>Pitta moluccensis</i>		Blue-winged pitta	Wild	4

sea-level (Hoogstraal *et al.* 1965). As Singapore is well within the broad range of *H. hystricis*, we regard this species as a previously unreported native species. This is further supported by the local host associations; *H. hystricis* commonly infests both *C. l. familiaris* and *S. sc. vittatus* throughout its range (Hoogstraal *et al.* 1965). In addition, this species typically occurs close to the equator (Hoogstraal *et al.* 1965), and Singapore is almost exactly on the equator. It is noteworthy that this species was collected infrequently in this study, and although a viable local population of *H. hystricis* seems to be present, it's possible that it does not thrive in the lowland equatorial conditions that prevail in Singapore –the highest elevation on the island is 164m above sea-level (Bukit Timah).

Haemaphysalis wellingtoni is also widely distributed throughout East Asia, and although it occurs primarily in the Oriental Zoogeographic Region, it is also known from New Guinea (the northern Australasian region) (Petney *et al.* 2019). Singapore is well within its range and we therefore consider the species to be native (Petney *et al.* 2019). *H. wellingtoni* feeds predominantly on gallinaceous birds, and within Singapore, the red jungle fowl (*Gallus gallus*) serves as its main host, though other birds (and in rare cases mammals) are also occasionally infested (Table 1).

Health risks?

Given its small size, Singapore hosts a surprisingly rich tick fauna, of which a number of species infest humans (Kwak 2018). Ticks have become an increasingly important threat to local public health, particularly with the increased abundance of *D. auratus* since its recent recolonization of the island (Kwak *et al.* 2021a). To inform public health policy and biosurveillance, it is crucial to understand the potential zoonotic risk posed by ticks, including the three newly detected *Haemaphysalis* species.

Haemaphysalis bispinosa occasionally infests humans through its range, and infestations have been recorded in India (Sharma 1993), Sri Lanka (Ariyaratne *et al.* 2016), and Thailand (Tanskul and Inlao 1989). Although the authors have seen no cases of this species infesting humans in Singapore, local cases of human infestation may emerge in the future. This is particularly likely given the propensity of this species to infest local dogs, which are a highly synanthropic species in Singapore and are now commonly seen in local parks, gardens, and nature reserves. Pathogenic bacterial genera have been detected in *H. bispinosa* in the region, including *Rickettsia* (Malaisri *et al.* 2015) and *Bartonella* (Kho *et al.* 2015). The detection of *B. bovis* in *H. bispinosa*, in neighboring Malaysia (Koh *et al.* 2015), is of particular interest given that this pathogen infects ungulates and could impact wildlife health in Singapore, particularly sambar deer (*Rusa unicolor*) and mouse deer (*Tragulus* spp.) (Chua *et al.* 2009; Chua and Lim 2011). *Hemaphysalis bispinosa* has also been found in association with *Babesia* infected dogs, though the role of *H. bispinosa* as a vector remains unclear (Augustine *et al.* 2017). Nonetheless, the close association this tick has with dogs in Singapore indicates that it may serve as a vector of some tick-borne pathogens in local canines. Research should now focus on studying the pathobiome of *H. bispinosa* in Singapore to better understand which microbes are present in the Singaporean population. Special attention should also be given to this tick as bites from its sister species, *H. longicornis*, have been suggested to cause mammalian red-meat allergy in other parts of Asia, as well as numerous other diseases of humans (Chinuki *et al.* 2016).

Haemaphysalis hystricis also occasionally feeds on humans and records exist from China, Japan, Taiwan, Vietnam, Laos, Thailand, and Myanmar (Guglielmone and Robbins 2018). Despite its apparent rarity within Singapore, we recorded two separate local human infestations by *H. hystricis*. This tick species feeds on a wide range of host species including members of numerous mammal families, and occasionally also birds (Guglielmone *et al.* 2014). While the two records of human tick bites by *H. hystricis* in Singapore mentioned in the present study represent the first recorded cases in Singapore, further infestations will likely occur in coming years. Indeed, many of the rodent and large mammal host species used by *H. hystricis* have

expanding populations within Singapore (e.g., wild pigs, samba deer, wild dogs) bringing them into increasing contact with humans and urban greenspaces. A number of important microbial genera have been detected in *H. hystricis* including an undescribed *Borrelia* species from the relapsing fever clade (Khoo *et al.* 2017), as well as *Coxiella*-like bacteria (Arthan *et al.* 2015), *Ehrlichia* and *Rickettsia* (Mahara 1997; Parola *et al.* 2003). The pathogenic protozoan *Babesia gibsoni* has also been detected in *H. hystricis* and is known to be transmitted transovarially between generations (Jongejan *et al.* 2018). The wide range of pathogenic genera recorded from *H. hystricis* suggest that it may be a vector of importance in Singapore and therefore requires further study to determine its potential threat to local public health.

Although *H. wellingtoni* has been recorded feeding on humans, this appears to occur more rarely than with *H. hystricis* and *H. bispinosa* (Guglielmone and Robbins 2018). Just one case of human infestation by *H. wellingtoni* has been recorded in Thailand (Parola *et al.* 2003) and may be due to the species' preference for avian hosts (Guglielmone *et al.* 2014). The record of human infestation by *H. wellingtoni* presented in this study represents the first from Singapore and the second globally. Though fewer pathogenic microbes have been detected within *H. wellingtoni*, it has been shown to be a competent vector of Kyasanur forest disease virus, which is frequently deadly to humans and other primates (Bhat and Naik 1978). Therefore, the microbiome (including the virome) of this tick species should be carefully studied in Singapore to ascertain public health risk. This is particularly important given the rapid population expansion of red jungle fowl (*Gallus gallus*) in Singapore, which serve as the primary host of this tick (Wu *et al.* 2020).

Surveillance of ticks and tick-borne diseases is crucial for safeguarding public health in Singapore. The recent detection of *H. bispinosa*, *H. hystricis*, and *H. wellingtoni* in Singapore highlights the need for more extensive research into these parasites and potential disease vectors, both within the island nation and across Asia more broadly. Expanded research into Singapore's tick fauna should not only focus on their microbiomes, but also their ecologies, as understanding their life histories and habitat needs is key to predicting and mitigating future disease spillover.

Acknowledgement

We kindly thank Dr Chia-Da Hu and the team at Wildlife Reserves Singapore as well as Dr Benjamin P.Y.-H. Lee and the team at NParks for their assistance with tick surveillance. We are also extremely grateful to Dr Richard G. Robbins and Dr Allen C. G. Heath for their helpful feedback on the manuscript.

ORCID

Mackenzie L. Kwak  <https://orcid.org/0000-0001-7672-9672>

Abigail Ng  <https://orcid.org/0000-0001-8594-1034>

References

- Ariyaratne S., Apanaskevich D.A., Amarasinghe P.H., Rajakaruna R.S. 2016. Diversity and distribution of tick species (Acari: Ixodidae) associated with human otoacariasis and socio-ecological risk factors of tick infestations in Sri Lanka. *Exp Appl Acarol*, 70:90-123. <https://doi.org/10.1007/s10493-016-0056-z>
- Arthan W., Sumrandee C., Hirunkanokpun S., Kitthawee S., Baimai V., Trinachartvanit W., Ahantarig A. 2015. Detection of *Coxiella*-like endosymbiont in *Haemaphysalis* tick in Thailand. *Tick Tick-borne Dis*, 6(1): 63-68. <https://doi.org/10.1016/j.ttbdis.2014.09.005>
- Augustine S., Sabu L., Lakshmanan B. 2017. Molecular identification of *Babesia* spp. in naturally infected dogs of Kerala, South India. *J Parasit Dis*, 41(2): 459-462. <https://doi.org/10.1007/s12639-016-0827-9>
- Bhat H.R., Naik S.V. 1978. Transmission of Kyasanur forest disease virus by *Haemaphysalis wellingtoni* Nuttall and Warburton, 1907 (Acarina: Ixodidae). *Ind J Med Res*, 67(5): 697-703.

- Chinuki Y., Ishiwata K., Yamaji K., Takahashi H., Morita E. 2016. *Haemaphysalis longicornis* tick bites are a possible cause of red meat allergy in Japan. *Allergy*, 71(3): 421-425. <https://doi.org/10.1111/all.12804>
- Chua M.A.H., Lim K.K.P. 2011. Deer. in: Ng, P.K.L., Corlett, R.T., Tan H.T.W. (eds), Singapore Biodiversity: An Encyclopedia of Natural Environment and Sustainable Development. Editions Didier Millet, Singapore. pp. 290.
- Chua M., Sivasothi N., Teo R. 2009. Rediscovery of greater mouse deer, *Tragulus napu* (Mammalia: Artiodactyla: Tragulidae) in Pulau Ubin, Singapore. *NiS*, 2: 373-378.
- Dantas-Torres F., Chomel B.B., Otranto D. 2012. Ticks and tick-borne diseases: a One Health perspective. *Trends Parasitol*, 28(10): 437-446. <https://doi.org/10.1016/j.pt.2012.07.003>
- Geevarghese G., Mishra A.C. 2011. *Haemaphysalis* ticks of India. Elsevier, London.
- Guglielmone A.A., Robbins R.G. 2018. Hard ticks (Acari: ixodida: ixodidae) parasitizing humans. Cham, Springer. <https://doi.org/10.1007/978-3-319-95552-0>
- Guglielmone A.A., Robbins R.G., Apanaskevich D.A., Petney T.N., Estrada-Peña A., Horak I.G. 2014. The hard ticks of the world. Dordrecht, Springer. <https://doi.org/10.1007/978-94-007-7497-1>
- Henderson J.C. 2013. Urban parks and green spaces in Singapore. *Manag*, 18(3): 213-225. <https://doi.org/10.1080/13606719.2013.796181>
- Hoogstraal H., Wassef H.Y. 1973. The *Haemaphysalis* ticks (Ixodoidea: Ixodidae) of birds. 3. *H. (Ornithophysalis)* subgen. n.: definition, species, hosts, and distribution in the Oriental, Palearctic, Malagasy, and Ethiopian faunal regions. *J Parasitol*, 59(6): 1099-1117. <https://doi.org/10.2307/3278650>
- Hoogstraal H., Wassef H.Y. 1985. *Dermacentor (Indocentor) auratus* (Acari: Ixodoidea: Ixodidae): hosts, distribution, and medical importance in tropical Asia. *J Med Entomol*, 22(2): 170-177. <https://doi.org/10.1093/jmedent/22.2.170>
- Hoogstraal H., Lim B.L., Anastos G. 1969. *Haemaphysalis (Kaiseriana) bispinosa* Neumann (Ixodoidea: Ixodidae): evidence for consideration as an introduced species in the Malay Peninsula and Borneo. *J Parasitol*, 55(5): 1075-1077. <https://doi.org/10.2307/3277178>
- Hoogstraal H., Trapido H., Kohls G.M. 1965. Studies on southeast Asian *Haemaphysalis* ticks (Ixodoidea, Ixodidae). The identity, distribution, and hosts of *H.(Kaiseriana) hystricis* Supino. *The J Parasitol*, 51(3): 467-480. <https://doi.org/10.2307/3275974>
- Hoogstraal H., Trapido H., Kohls G.M. 1966. Studies on southeast Asian *Haemaphysalis* ticks (Ixodoidea, Ixodidae). Speciation in the *H.(Kaiseriana) obesa* group: *H. semermis* Neumann, *H. obesa* Larrousse, *H. roubaudi* Toumanoff, *H. montgomeryi* Nuttall, and *H. hirsuta* sp. n. *J Parasitol*, 52(1): 169-191. <https://doi.org/10.2307/3276410>
- Jongejan F., Su B.L., Yang H.J., Berger L., Bevers J., Liu P.C., Fang J.C., Cheng Y.W., Kraakman C., Plaxton N. 2018. Molecular evidence for the transovarial passage of *Babesia gibsoni* in *Haemaphysalis hystricis* (Acari: Ixodidae) ticks from Taiwan: a novel vector for canine babesiosis. *Parasite Vector*, 11(1): 1-8. <https://doi.org/10.1186/s13071-018-2722-y>
- Kho K.L., Koh F.X., Jaafar T., Nizam Q.N.H., Tay S.T. 2015. Prevalence and molecular heterogeneity of *Bartonella bovis* in cattle and *Haemaphysalis bispinosa* ticks in Peninsular Malaysia. *BMC Vet Res*, 11(1): 1-9. <https://doi.org/10.1186/s12917-015-0470-1>
- Khoo J.J., Lim F.S., Tan K.K., Chen F.S., Phoon W.H., Khor C.S., Pike B.L., Chang L.Y., AbuBakar S. 2017. Detection in Malaysia of a *Borrelia* sp. from *Haemaphysalis hystricis* (Ixodida: Ixodidae). *J Med Entomol*, 54(5): 1444-1448. <https://doi.org/10.1093/jme/tjx131>
- Kwak M.L. 2018. Ticks in the Lion City: a preliminary review of the tick fauna of Singapore. *Exp Appl Acarol*, 76(2): 263-267. <https://doi.org/10.1007/s10493-018-0305-4>
- Kwak M.L., Foo M., Pocklington K., Hsu C.D., Cheong W., How C.B., Shunari M., Tahir M.G. 2019. Tick-crocodilian interactions: a review, with the first record of tick (Acari: Ixodidae) infestation in the saltwater crocodile (*Crocodylus porosus*), and a concise host-parasite index. *Exp Appl Acarol*, 78(1): 127-132. <https://doi.org/10.1007/s10493-019-00378-0>
- Kwak M.L., Hsu C.D., Douay G., Ahmad A.A. 2018. The first authenticated record of the pangolin tick *Amblyomma javanense* (Acari: Ixodidae) in Singapore, with notes on its biology and conservation. *Exp Appl Acarol*, 76(4): 551-557. <https://doi.org/10.1007/s10493-018-0310-7>
- Kwak M.L., Chavatte J.M., Chew K.L., Lee B.P.H. 2021a. Emergence of the zoonotic tick *Dermacentor (Indocentor) auratus* Supino, 1897 (Acari: Ixodidae) in Singapore. *Tick Tick-borne Dis*, 12(1): e101574. <https://doi.org/10.1016/j.ttbdis.2020.101574>
- Kwak M.L., Neves E.S., Borthwick S.A., Smith G.J., Meier R., Mendenhall I.H. 2021b. Habitat impacts the abundance and network structure within tick (Acari: Ixodidae) communities on tropical small mammals. *Tick Tick-borne Dis*, 12(3): e101654. <https://doi.org/10.1016/j.ttbdis.2021.101654>
- Léger E., Vourc'h G., Vial L., Chevillon C., McCoy K.D. 2013. Changing distributions of ticks: causes and consequences. *Exp Appl Acarol*, 59(1): 219-244. <https://doi.org/10.1007/s10493-012-9615-0>
- Leong T.M., Shunari M., Lim K.K. 2010. The narrow-winged pipistrelle, *Pipistrellus stenopterus* (Dobson) in Singapore (Mammalia: Chiroptera: Vespertilionidae). *NiS*, 3: 159-165.
- Mahara F. 1997. Japanese Spotted Fever: Report of 31 cases and review of the literature. *Emerg Infect Dis*, 3: 105-111. <https://doi.org/10.3201/eid0302.970203>
- Malaisri P., Hirunkanokpun S., Baimai V., Trinachartvanit W., Ahantari A. 2015. Detection of *Rickettsia* and *Anaplasma* from hard ticks in Thailand. *J Vector Ecol*, 40(2): 262-268. <https://doi.org/10.1111/jvec.12163>
- Medlock J.M., Hansford K.M., Bormane A., Derdakova M., Estrada-Peña A., George J.C., Golovljova I., Jaenson T.G., Jensen J.K., Jensen P.M., Kazimirova M. 2013. Driving forces for changes in geographical distribution of *Ixodes ricinus* ticks in Europe. *Parasite Vector*, 6(1): 1-11. <https://doi.org/10.1186/1756-3305-6-1>

- Mendenhall I.H., Ch'ng L., Neves E.S., Borthwick S.A., Smith G.J.D. 2018. High diversity of medically important gastrointestinal rodent-borne helminths in Singapore. *Zoonoses Public Health*, 65(3): 361-366. <https://doi.org/10.1111/zph.12438>
- Neves E.S., Mendenhall I.H., Borthwick S.A., Su Y.C.F., Smith G.J.D. 2018. Detection and genetic characterization of diverse *Bartonella* genotypes in the small mammals of Singapore. *Zoonoses Public Health*, 65(1): e207-215. <https://doi.org/10.1111/zph.12430>
- Paperna I. 2006. The tick *Ixodes granulatus* infests *Rattus rattus* populating a small island offshore of Singapore. *Parasite*, 13(1), 83-84. <https://doi.org/10.1051/parasite/2006131083>
- Parola P., Cornet J-P., Sanogo Y.O., Miller R.S., Van Thien H., Gonzalez J.P., Raoult D., Telford III S.R., Wongsrichanalai C. 2003. Detection of *Ehrlichia* spp., *Anaplasma* spp., *Rickettsia* spp. and other Eubacteria in ticks from the Thai-Myanmar border and Vietnam. *J Clin Microbiol*, 41: 1600-1608. <https://doi.org/10.1128/JCM.41.4.1600-1608.2003>
- Petney T.N., Saijuntha W., Boulanger N., Chitimia-Dobler L., Pfeffer M., Eamudomkarn C., Andrews R.H., Ahamad M., Putthasorn N., Muders S.V., Petney D.A. 2019. Ticks (Argasidae, Ixodidae) and tick-borne diseases of continental Southeast Asia. *Zootaxa*, 4558(1): 1-89. <https://doi.org/10.11646/zootaxa.4558.1.1>
- Rainey T., Occi J.L., Robbins R.G., Egizi A. 2018. Discovery of *Haemaphysalis longicornis* (Ixodida: Ixodidae) parasitizing a sheep in New Jersey, United States. *J Med Entomol*, 55(3): 757-759. <https://doi.org/10.1093/jme/tjy006>
- Sharma B.D. 1993. *Medical and Veterinary Arthropod-Disease Ecology*. New Delhi, Ashish Publishing House.
- Tanskul P., Inlao I. 1989. Keys to the adult ticks of *Haemaphysalis* Koch, 1844, in Thailand with notes on changes in taxonomy (Acari: Ixodoidea: Ixodidae). *J Med Entomol*, 26(6): 573-600. <https://doi.org/10.1093/jmedent/26.6.573>
- Theis J.H., Franti C.E. 1971. Changing infestation rates of *Rhipicephalus sanguineus* (Latreille)(Ixodidae) ticks on dogs on Singapore Island, 1965-1966. *J Med Entomol*, 8(1): 23-28. <https://doi.org/10.1093/jmedent/8.1.23>
- Trapido H., Varma, M.G.R., Rajagopalan, P.K., Singh, K.R.P. & Rebello, M.J. 1964. A guide to the identification of all stages of *Haemaphysalis* ticks of south India. *Bull Entomol*, 55(1): 249-270. <https://doi.org/10.1017/S0007485300049439>
- Wu M.Y., Low G.W., Forcina G., van Grouw H., Lee B.P.Y.H., Oh R.R.Y., Rheindt F.E. 2020. Historic and modern genomes unveil a domestic introgression gradient in a wild red junglefowl population. *Evo Appl*, 13(9): 2300-2315. <https://doi.org/10.1111/eva.13023>
- Yamaguti N., Tipton V.J., Keegan H.L., Toshioka S. 1971. Ticks of Japan, Korea, and the Ryukyu islands. *Brigham Young University Science Bulletin, Biological Series*, 15(1). <https://doi.org/10.5962/bhl.part.25691>
- Yap G., Lim X.F., Chan S., How C.B., Humaidi M., Yeo G., Mailepessov D., Kong M., Lai Y.L., Okumura C., Ng L.C. 2019. Serological evidence of continued Japanese encephalitis virus transmission in Singapore nearly three decades after end of pig farming. *Parasites Vector*, 12(1): e1-7. <https://doi.org/10.1186/s13071-019-3501-0>
- Yeo J.H., Neo H. 2010. Monkey business: Human-animal conflicts in urban Singapore. *Soc Cult Geog*, 11(7): 681-699. <https://doi.org/10.1080/14649365.2010.508565>
- Yong D.L., Lee B.P.Y.H., Ang A., Tan K.H. 2010. The status on Singapore island of the Eurasian wild pig *Sus scrofa* (Mammalia: Suidae). *NiS*, 3: 227-237.