HAL open science

Epidermal melanocytes in segmental vitiligo show altered expression of E-cadherin, but not P-cadherin

C. Grill, L. Benzekri, A. Rubod, Z. Aktary, K. Ezzedine, A. Taïeb, Y. Gauthier, L. Larue, V. Delmas

To cite this version:

C. Grill, L. Benzekri, A. Rubod, Z. Aktary, K. Ezzedine, et al.. Epidermal melanocytes in segmental vitiligo show altered expression of E-cadherin, but not P-cadherin. British Journal of Dermatology, 2018, 178 (5), pp.1204-1206. 10.1111/bjd.16352 . hal-03780836

HAL Id: hal-03780836

https://hal.science/hal-03780836v1

Submitted on 20 Sep 2022

HAL is a multi-disciplinary open access archive for the deposit and dissemination of scientific research documents, whether they are published or not. The documents may come from teaching and research institutions in France or abroad, or from public or private research centers.

L'archive ouverte pluridisciplinaire **HAL**, est destinée au dépôt et à la diffusion de documents scientifiques de niveau recherche, publiés ou non, émanant des établissements d'enseignement et de recherche français ou étrangers, des laboratoires publics ou privés.

Check for updates

DR KHALED EZZEDINE (Orcid ID : 0000-0002-5468-4589)
DR LIONEL LARUE (Orcid ID : 0000-0002-2010-6107)

Author Manuscript

Article type : Research Letter

Epidermal melanocytes of segmental vitiligo show altered expression of E-cadherin, but not P-cadherin

Authors: C. Grill[1-3], B. Laila[4], A. Rubod[1-3], Z. Aktary[1-3], K. Ezzedine[5,6], A. Taieb[5,6], Y. Gauthier[5,6], L. Larue[1-3*$], and V. Delmas[1-3$]

[1]Institut Curie, PSL Research University, INSERM U1021, Normal and Pathological Development of Melanocytes, Orsay, France,
[2]Univ Paris-Sud, Univ Paris-Saclay, CNRS UMR 3347, Orsay, France,
[3]Equipe Labellisée Ligue Contre le Cancer, Orsay, France
[4]Mohammed V University in Rabat, Department of Dermatology, Ibn Sina University Hospital, Rabat, Morocco.
[5]Department of Dermatology and Pediatric Dermatology, National Reference Centre for Rare Skin Disorders, Hôpital Saint-André Bordeaux, France.
[6]INSERM U1035, University of Bordeaux, Bordeaux, France.

$ Lionel Larue and Véronique Delmas are co-last authors

This is the author manuscript accepted for publication and has undergone full peer review but has not been through the copyediting, typesetting, pagination and proofreading process, which may lead to differences between this version and the Version of Record. Please cite this article as doi: 10.1111/bjd.16352

This article is protected by copyright. All rights reserved

*Address correspondence to Lionel Larue, e-mail: lionel.larue@curie.fr

Author Manuscript

DEAR EDITOR: Vitiligo is the most common pigmentation disorder, with a worldwide prevalence of 1%. The loss of melanocytes from the skin is the main clinical feature of patients with vitiligo, resulting in depigmentation macules [1]. Vitiligo has been classified into two major forms: non-segmental vitiligo (NSV) and segmental vitiligo (SV) [2-4]. NSV lesions are generally bilateral or symmetrically scattered over the entire body. Onset may occur at any age, but most patients develop vitiligo before 40 years of age, and the depigmentation evolves over time [2]. SV is characterized by its unilateral distribution, early onset, and rapid stabilisation [3]. The etiopathogenesis of NSV and SV has not been fully elucidated and it is possible that the two subtypes share common mechanisms for initiation of the disease, but diverge in the progression phase, as depigmentation rapidly stabilizes in SV, but not NSV [5]. There is much data to support an autoimmune phase in the extension of vitiligo and mechanical and chemical trauma are known environmental stressors that accelerate disease appearance. However, the events that initiate the loss of melanocytes are still a subject of debate.

We aim to explore cell adhesion defects in melanocytes before clinical lesions appear as an indicator of early events in pathogenesis of vitiligo. We have recently shown that E-cadherin, which mediates the adhesion between melanocytes and keratinocytes in the epidermis, is discontinuously/heterogeneously distributed within (or lost from) melanocyte membranes of NSV patients [6]. This alteration of melanocyte E-cadherin distribution is observed in biopsies distant from the depigmentation macules, before clinical lesions appear, indicating that the alteration of E-cadherin distribution is an early event in the pathogenesis of vitiligo. Furthermore, we have shown that this primary defect that affects adhesion, combined with stress conditions, leads to the disappearance of melanocytes in human epidermal reconstructed skin and mouse models [6]. Here, we assessed whether alteration of E-cadherin is a common first step in the various subtypes of vitiligo by studying the distribution of E-cadherin in epidermal melanocytes of frozen skin biopsies from SV and NSV patients (taken from clinically normal looking skin).

This article is protected by copyright. All rights reserved

Briefly, we classified each melanocyte based on its E-cadherin labelling (BD Bioscience #610182) by immunochemistry. Type I melanocytes correspond to a homogenous membrane distribution of E-cadherin, whereas Type II melanocytes correspond to heterogeneous distribution or lack of E-cadherin. We counted and analysed at least 50 melanocytes per patient from ten control, ten SV and ten NSV patients. TRP-2 (shown in red; Santa Cruz SC-10451) was used as a marker for melanocytes. In control patients, E-cadherin (shown in green) displayed type I homogenous membrane staining in 78% of melanocytes (Fig. 1a [panel 1]) with the remaining 22% showing type II staining (Fig.1b). We observed a similar pattern of distribution at the melanocyte membrane (of control patients) for β-catenin (BD Bioscience #610154), a major cytoplasmic partner of E-cadherin (Fig. 1a [panel 2], Fig.1b). In contrast, melanocytes from SV patients showed only 43% and 46% type I staining for E-cadherin and β-catenin, respectively (Fig. 1a [panels 7,8], Fig.1b). There was no statistical difference for E-cadherin and β-catenin staining between the two vitiligo subtypes, however both were significantly different compared to control patients (Fig. 1c). Thus, our results demonstrate that melanocytes of both SV and NSV share the same altered distribution pattern for E-cadherin and β-catenin, which is different from that of melanocytes of non-vitiligo subjects. Moreover, we detected a similar number of suprabasal melanocytes in the buttock of normal epidermis of SV and NSV, 14% and 18%, respectively. These percentages are higher than the normal situation, with 5% of suprabasal melanocytes. We could not find any correlation between the E-cadherin staining and the number of suprabasal melanocytes according to the apparition of the vitiligo.

P-cadherin is the other type 1 cadherin expressed in melanocytes and its gene is located in the same chromosomal region as E-cadherin in humans and various mammals [7,8]. We then examined whether a modification in melanocyte E-cadherin membrane distribution could have some *cis* influence on the distribution of P-cadherin (BD Bioscience #610228). We found that P-cadherin was homogeneously distributed throughout the plasma membrane of melanocytes (Fig. 1a [panels 3,6,9] and Fig. 1b) in controls as well as NSV and SV patients. In conclusion, P-cadherin distribution was similar for both vitiligo subtypes and controls, despite its structural and functional similarity to E-cadherin.

In conclusion, NSV and SV showed the same reduction in E-cadherin expression in melanocytes relative to normal pigmented skin and a similar increase of suprabasal melanocytes in the epidermis. This finding indicates that the changes in cell-adhesion

Author Manuscript

This article is protected by copyright. All rights reserved

mediated by E-cadherin in melanocytes are similar in both NSV and SV. This favours the cell-adhesion defect theory, called melanocytorrhagy [9], not only for the initiation step of NSV, as originally proposed, but also for the SV subtype. In addition, P-cadherin expression remained the same for both vitiligo subtypes and controls. Thus, alteration of E-cadherin distribution is an intrinsic defect of this protein and not a general defect affecting other cadherin molecules. A noticeable difference between SV and NSV was found in the architecture of the epidermis of the normal-pigmented buttock skin; SV presents an notable increase of the rete ridges, and NSV an acanthosis compared to healthy controls. This feature might impact melanocyte integrity differently and eventually participate in the progression of the disease.

Acknowledgements

This work was supported by the Ligue Contre le Cancer - Comité de l'Oise, INCa, ITMO Cancer, ARC, and is covered by the program «Investissements d'Avenir», launched by the French Government and implemented by ANR Labex CelTisPhyBio (ANR-11-LBX-0038 and ANR-10-IDEX-0001-02 PSL). CG has a fellowship from the Fondation ARC. We are grateful to the imaging facility of Institut Curie and to Pierre Sohier for histopathological comments.

Conficts of interest : none declared

References

1 Picardo M, Taieb A. Vitiligo. *Heildelberg/ Springer-Verlag* 2010: 1-504.

2 Ezzedine K, Lim HW, Suzuki T *et al.* Revised classification/nomenclature of vitiligo and related issues: the Vitiligo Global Issues Consensus Conference. *Pigment cell & melanoma research* 2012; **25**: E1-13.

3 van Geel N, Speeckaert R. Segmental Vitiligo. *Dermatol Clin* 2017; **35**: 145-50.

4 van Geel N, Speeckaert R, Mollet I *et al.* In vivo vitiligo induction and therapy model: double-blind, randomized clinical trial. *Pigment cell & melanoma research* 2012; **25**: 57-65.

Author Manuscript

This article is protected by copyright. All rights reserved

5 Anbar TS, El-Badry MM, McGrath JA *et al.* Most individuals with either segmental or non-segmental vitiligo display evidence of bilateral cochlear dysfunction. *Br J Dermatol* 2015; **172**: 406-11.

6 Wagner RY, Luciani F, Cario-Andre M *et al.* Altered E-Cadherin Levels and Distribution in Melanocytes Precede Clinical Manifestations of Vitiligo. *The Journal of investigative dermatology* 2015; **135**: 1810-9.

7 Nose A, Takeichi M. A novel cadherin cell adhesion molecule: its expression patterns associated with implantation and organogenesis of mouse embryos. *J Cell Biol* 1986; **103**: 2649-58.

8 Niessen CM, Leckband D, Yap AS. Tissue organization by cadherin adhesion molecules: dynamic molecular and cellular mechanisms of morphogenetic regulation. *Physiol Rev* 2011; **91**: 691-731.

9 Gauthier Y, Cario-Andre M, Lepreux S *et al.* Melanocyte detachment after skin friction in non lesional skin of patients with generalized vitiligo. *Br J Dermatol* 2003; **148**: 95-101.

Figure Legend

Figure 1. Loss of E-cadherin and β-catenin, but not P-cadherin, in NSV and SV. Biopsies were taken from clinically normal looking skin of SV patients (buttock area; 5 femelles, 5 males). The mean age was 29 years. NSV and controls patients were described previously[5].

a) Immunofluorescence of controls (1, 2, 3), NSV (4, 5, 6), and SV (7, 8, 9) for E-cadherin (1, 4, 7), β-catenin (2, 5, 8), and P-cadherin (3, 6, 9). E-cadherin, β-catenin, and P-cadherin are each shown in green, TRP-2 in red. The nuclei (in blue) were counterstained with DAPI. The white dotted line indicates the basal membrane. Scale bar = 10 μm.

b) Average percentages of controls, NSV, and SV melanocytes showing type I and II staining for E-cadherin, β-catenin, and P-cadherin. Ten biopsies for each condition (control, NSV and SV) were analyzed. Patients provided signed, informed consent before the study, which was approved by the relevant local ethics committees (Bordeaux CNIL #1545937 v.0 and Rabat Hospitals).

c) Average percentages of controls (blue), NSV (red), and SV (orange) melanocytes showing type I and II staining of E-cadherin, β-catenin, and P-cadherin. *** *P-value* < 10^{-3}, **** *P-value* < 10^{-4}, ns: non-significant.

This article is protected by copyright. All rights reserved

Author Manuscript

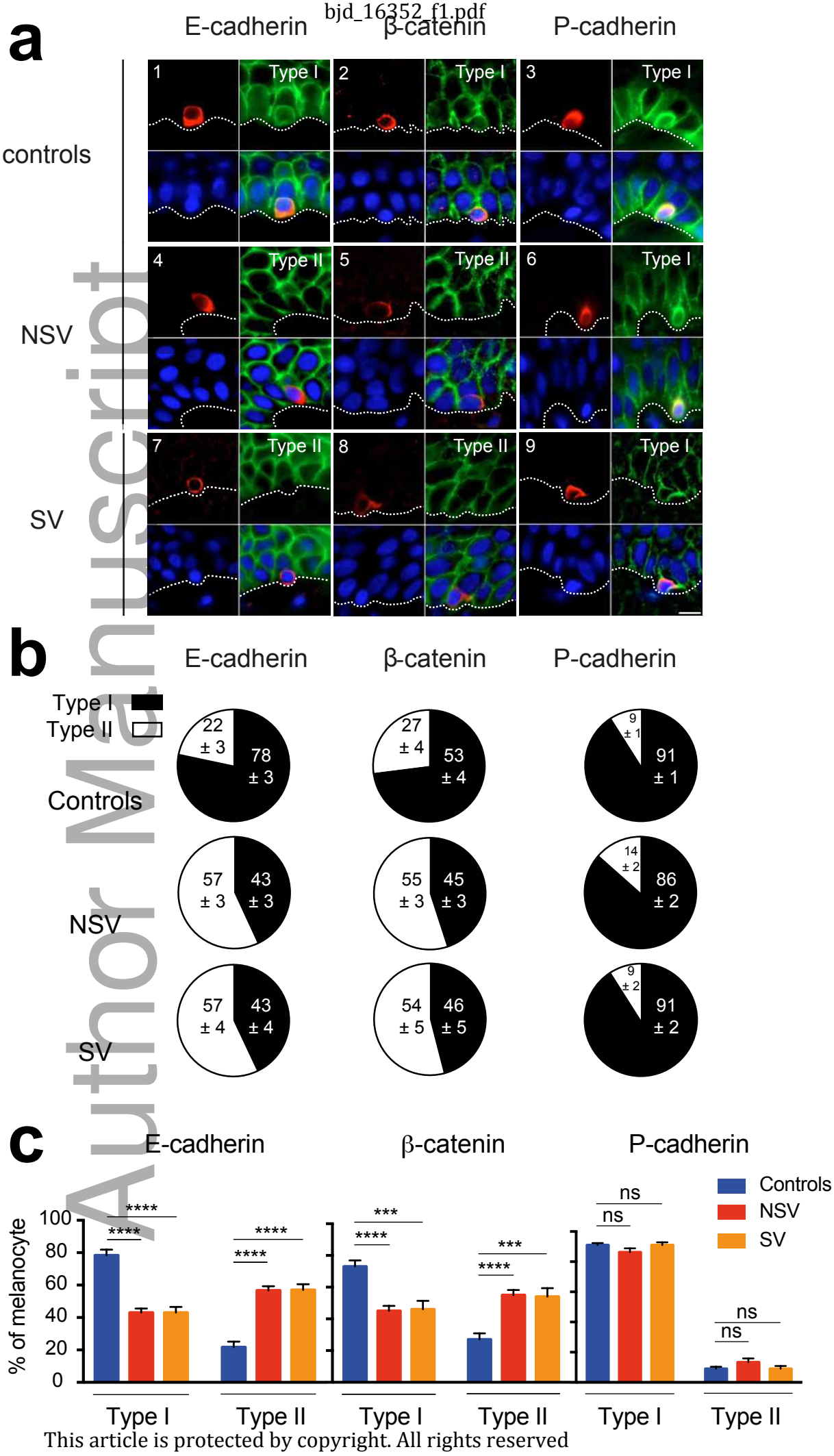

Author Manuscript

This article is protected by copyright. All rights reserved

Figure 1