



**HAL**  
open science

## **Tuberous xanthomatosis is not necessarily associated with increased plasma concentrations of cholestanol in cerebrotendinous xanthomatosis**

Jb Bonnet, P Couvert, M Di-Filippo, F Boissiere, Jean-Paul Cristol, T Sutra, D Cheillan, P Moulin, A Sultan

### ► To cite this version:

Jb Bonnet, P Couvert, M Di-Filippo, F Boissiere, Jean-Paul Cristol, et al.. Tuberous xanthomatosis is not necessarily associated with increased plasma concentrations of cholestanol in cerebrotendinous xanthomatosis. *Journal of Internal Medicine*, In press, 293 (1), pp.121-123. 10.1111/joim.13568 . hal-03780181

**HAL Id: hal-03780181**

**<https://hal.science/hal-03780181v1>**

Submitted on 31 Oct 2022

**HAL** is a multi-disciplinary open access archive for the deposit and dissemination of scientific research documents, whether they are published or not. The documents may come from teaching and research institutions in France or abroad, or from public or private research centers.

L'archive ouverte pluridisciplinaire **HAL**, est destinée au dépôt et à la diffusion de documents scientifiques de niveau recherche, publiés ou non, émanant des établissements d'enseignement et de recherche français ou étrangers, des laboratoires publics ou privés.

Jean-Baptiste Bonnet<sup>1,2</sup> Philippe Couvert<sup>3,4,5</sup>,  
Mathilde Di-filippo<sup>6,7</sup>, Florian Boissiere<sup>8</sup>,  
Jean-Paul Cristol<sup>9,10</sup>, Thibault Sutra<sup>10</sup>, David Cheillan<sup>7,11</sup>,  
Philippe Moulin<sup>7,12</sup> & Ariane Sultan<sup>2,9</sup>

# Tuberous xanthomatosis is not necessarily associated with increased plasma concentrations of cholestanol in cerebrotendinous xanthomatosis

Dear Editor,

Cerebrotendinous xanthomatosis (CTX) is a rare recessive disease that results from a loss of function of sterol-27-hydroxylase, which then affects bile acid synthesis [1]. This leads to an accumulation of several metabolites, especially cholestanol, with an early accumulation in the tissues [1]. A hundred identified mutations of the *CYP27A1* gene encoding sterol-27-hydroxylase have been described [2], all leading to pleomorphic phenotypic presentations and different degrees of severity.

In 2018, Sekijima et al. proposed inclusion criteria with a high cholestanol level as a required criterion [3]. However, several series have reported a few cases of atypical CTX with normal cholestanol levels but with biallelic *CYP27A1* pathogenic variants [4].

The objective of this study was to explore the case of a patient with major xanthomas but no neurological disease and a normal plasma concentration of cholestanol to determine whether the diagnosis should be CTX.

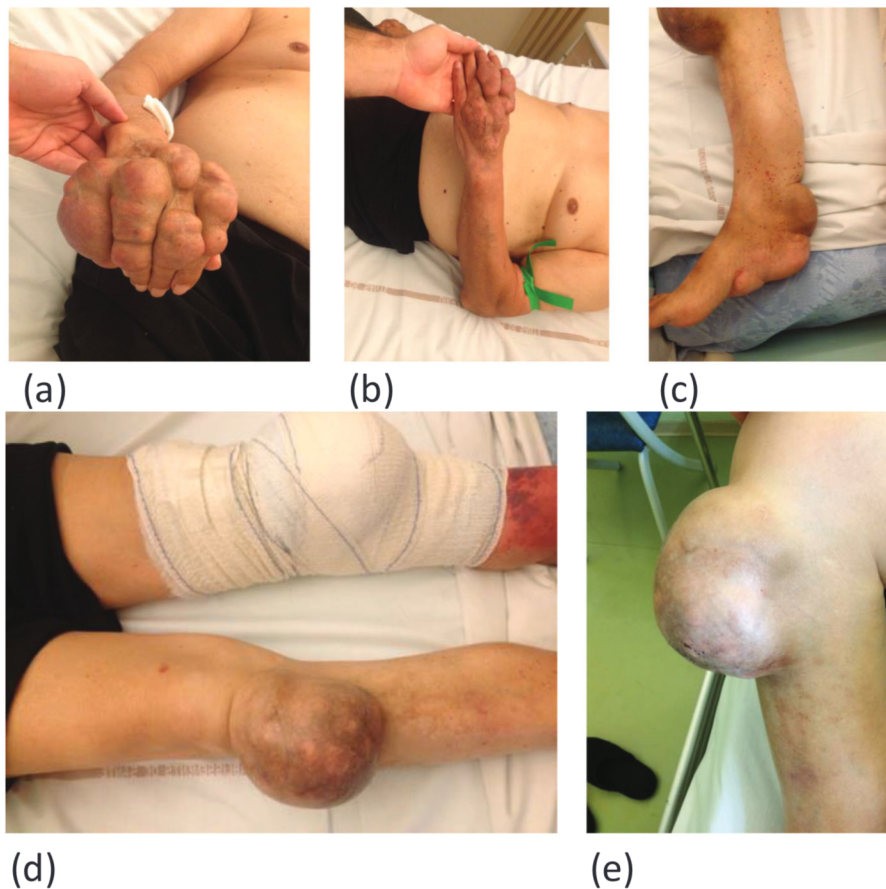
Mr. M, 74 years old, presented several homogeneous tuberous tumors. They were preferentially attached to tendons (dorsal surface of both hands, tricipital insertion, knees: >10 cm diameter, Achilles tendons, and the plantar surface of both feet) (Fig. 1). Xanthomas first appeared on the knees at the age of 22 years. Several xanthoma surgeries were performed in youth with systematic recurrences. In 2014, an ulceration of the knee prompted an extended surgical resection. The results from the anatomic pathology analysis fitted with xanthoma diagnosis (see Supporting Information). At the patient's death from colon cancer in 2020, no recurrence was observed in either knee, operated on in 2014 and 2016.

The patient had no cardiovascular or neurological disease, except for a single stroke sequela without clinical consequences and revealed on a brain magnetic resonance imaging (MRI) in 2017. A second brain MRI in 2020 did not reveal any signal suggestive of CXT in T2-weighted images. The family history, with no consanguinity, revealed a sister with similar lesions that had appeared when she was 30 years old (see Supporting Information). His parents and children were healthy. The neurological evaluation of the patient by a skilled neurologist was normal (absence of pyramidal signs, cerebellar signs, and dementia), as was the psychiatric evaluation. Electrocardiogram and cardiac MRI were within normal limits.

Sitosterolemia was first hypothesized. Treatment included 10 mg of ezetimibe and 40 mg of atorvastatin once daily. We found no hypersitosterolemia or campesterolemia, and the lipid profile was normal (see Supporting Information). Blood bile acid assays were normal (see Supporting Information). Sterol-27-hydroxylase activity was not analyzed.

CTX was then suspected, and next-generation sequencing following capture of the *CYP27A1* gene led to the identification of two previously described heterozygous mutations: c.379C>T (p.Arg127Trp) [5] and c.1435C>G (p.Arg479Gly) [6]. Each of his three children carried one or the other variant, showing that these mutations were not carried by the same allele. Surprisingly, the patient's plasma cholestanol concentration was normal or slightly above the normal range (8  $\mu\text{mol/L}$  and 13  $\mu\text{mol/L}$ ; normal range <10  $\mu\text{mol/L}$ ) after 15 days without the hypolipidemic drug. The capture panel covered the *ABCG5* and *ABCG8* genes, with no deleterious variant found. We concluded to an unusual form of CTX.

The inconstant increase in plasma cholestanol concentration is unusual in CTX. Cholestanol was not assayed in cerebrospinal fluid or urine.



**Fig. 1** Xanthomas of Mr. M: (a) right hand; (b) left hand; (c) Achilles tendon; (d) knees; (e) left knee

The first mutation in the *CYP27A1* gene, c.379C>T (p.Arg127Trp), was previously described in a patient with spinal xanthomatosis without xanthomas [5] and more recently identified in a compound heterozygous state [7, 8] and a homozygous state [9] (see Supporting Information).

The second mutation, c.1435C>G (p.Arg479Gly), was also described twice [6, 8] (see Supporting Information). Another variation affecting this amino acid, R479C, strongly decreases enzymatic activity in vitro [1]. We found five alleles in CTX for the first mutation compared to 20/282716 in gnomAD and four alleles in CTX for the second mutation compared to 4/282188 in gnomAD. These two results are strongly suggestive of their pathogenicity.

Interestingly, this case diverges from the typical clinical form of CTX by plasma cholestanol in the

upper normal range; the absence of neurological disease, cataract or chronic diarrhea; and the severity of the xanthomatosis with development in adulthood [10]. It should be noted that one of the rare reported cases of CTX with normal cholestanol did not present any neurological symptomatology [4].

In the case of severe xanthomas, the clinical situation of the patient presented here argues for genetic exploration of the *CYP27A1* gene after exclusion of familial hypercholesterolemia and sitosterolemia, regardless of the plasma cholestanol concentration.

#### Acknowledgments

The authors would like to acknowledge the support of Dr. B. Carlander for the neurological evaluation and Dr. F. Bekara for the surgical care.



## Funding

This research received no specific grant from any funding agency in public, commercial, or not-for-profit sectors.

## Conflict of interest

The authors declare no conflict of interest.

## Ethical statement

The patient and family have given their consent to this research.

## Author contributions

Study concept and design: J. B. Bonnet, A. Sultan, and D. Cheillan; genetic analysis: P. Couvert; surgical procedure: F. Boissiere; biochemical analysis: M. Di-filippo, J. P. Cristol, and D. Cheillan; study supervision: A. Sultan and P. Moulin; writing the first draft of the manuscript: J. B. Bonnet and A. Sultan. All authors read, significantly improved, and approved the final version of the manuscript.

**Jean-Baptiste Bonnet<sup>1,2</sup> Philippe Couvert<sup>3,4,5</sup>,  
Mathilde Di-filippo<sup>6,7</sup>, Florian Boissiere<sup>8</sup>,  
Jean-Paul Cristol<sup>9,10</sup>, Thibault Sutra<sup>10</sup>, David Cheillan<sup>7,11</sup>,  
Philippe Moulin<sup>7,12</sup> & Ariane Sultan<sup>2,9</sup>**

From the <sup>1</sup>UMR 1302, Desbrest Institute of Epidemiology and Public Health, University of Montpellier, INSERM, CHU, Montpellier, France; <sup>2</sup>Endocrinology-Diabetes-Nutrition Department, CHU Montpellier, University of Montpellier, Montpellier, France; <sup>3</sup>APHP, Sorbonne University, Pitié-Salpêtrière Hospital, Endocrine and Oncologic Biochemistry, Paris, France; <sup>4</sup>National Institute for Health and Medical Research (INSERM) UMR\_S 1166, Faculty of Medicine Pitié-Salpêtrière, Paris, France; <sup>5</sup>Sorbonne University, Paris, France; <sup>6</sup>Dyslipidemia, Nutritional and Digestive Dysfunctions Unit, Department of Biochemistry and Molecular Biology, Biology and Pathology Center - East, Hospices Civils de Lyon, Bron, France; <sup>7</sup>CarMeN Laboratory, UMR INSERM U1060/INRA U1397, Claude Bernard Lyon 1 University, Bron, France; <sup>8</sup>Department of Plastic, Reconstructive and Aesthetic Surgery, Burns and Wound Healing Unit, CHRU Lapeyronie, Montpellier, France; <sup>9</sup>PhyMedExp, University of Montpellier, INSERM U1046, CNRS UMR 9214, M, Montpellier, France; <sup>10</sup>Department of Biochemistry, Hôpital Lapeyronie, CHU Montpellier, Montpellier, France; <sup>11</sup>Inborn Errors of Metabolism Unit, Department of Biochemistry and Molecular Biology, Biology and

Pathology Center - East, Hospices Civils de Lyon, Bron, France; and <sup>12</sup>Department of Endocrinology, Nutrition and Metabolic Diseases, Hospices Civils de Lyon, Louis Pradel Cardiovascular Hospital, Bron, France

## References

- 1 Cali JJ, Hsieh CL, Francke U, Russell DW. Mutations in the bile acid biosynthetic enzyme sterol 27-hydroxylase underlie cerebrotendinous xanthomatosis. *J Biol Chem.* 1991;**266**(12):7779–83.
- 2 Appadurai V, DeBarber A, Chiang PW, Patel SB, Steiner RD, Tyler C, et al. Apparent underdiagnosis of cerebrotendinous xanthomatosis revealed by analysis of ~60,000 human exomes. *Mol Genet Metab.* 2015;**116**(4): 298–304.
- 3 Sekijima Y, Koyama S, Yoshinaga T, Koinuma M, Inaba Y. Nationwide survey on cerebrotendinous xanthomatosis in Japan. *J Hum Genet.* 2018;**63**(3):271–80.
- 4 Guenzel AJ, DeBarber A, Raymond K, Dhamija R. Familial variability of cerebrotendinous xanthomatosis lacking typical biochemical findings. *JIMD Rep.* 2021;**59**(1):3–9.
- 5 Verrips A, Lycklama à Nijeholt GJ, Barkhof F, Van Engelen BGM, Wesseling P, Luyten J Q FM, et al. Spinal xanthomatosis: a variant of cerebrotendinous xanthomatosis. *Brain.* 1999;**122**(8):1589–95.
- 6 Guyant-Maréchal L, Verrips A, Girard C, Wevers RA, Zijlstra F, Sistermans E, et al. Unusual cerebrotendinous xanthomatosis with fronto-temporal dementia phenotype. *Am J Med Genet A.* 2005;**139A**(2):114–7.
- 7 Wang Z, Yuan Y, Zhang W, Zhang Y, Feng L. Cerebrotendinous xanthomatosis with a compound heterozygote mutation and severe polyneuropathy. *Neuropathology.* 2007;**27**(1):62–6.
- 8 Stelten BML, Raal FJ, Marais AD, Riksen NP, Lennep JER van, Duell PB, et al. Cerebrotendinous xanthomatosis without neurological involvement. *J Intern Med.* 2021;**290**(5):1039–47.
- 9 Kapás I, Katkó M, Harangi M, Paragh G, Balogh I, Kóczi Z, et al. Cerebrotendinous xanthomatosis with the c.379C>T (p.R127W) mutation in the CYP27A1 gene associated with premature age-associated limbic tauopathy. *Neuropathol Appl Neurobiol.* 2014;**40**(3):345–50.
- 10 Ly H, Bertorini TE, Shah N. An adult male with progressive spastic paraparesis and gait instability. *J Clin Neuromuscul Dis.* 2014;**16**(2):98–103.

Correspondence: Ariane Sultan, Département Nutrition Endocrinologie Diabète, Hôpital Lapeyronie, 191 avenue du doyen Gaston Giraud, 34295 Montpellier, France. Email: a-sultan@chu-montpellier.fr