



HAL
open science

Infertility workup: identifying endometriosis

Paul Pirtea, Nicolas R. Vulliemoz, Dominique de Ziegler, Jean Marc Ayoubi

► **To cite this version:**

Paul Pirtea, Nicolas R. Vulliemoz, Dominique de Ziegler, Jean Marc Ayoubi. Infertility workup: identifying endometriosis. *Fertility and Sterility*, 2022, 118 (1), pp.29-33. 10.1016/j.fertnstert.2022.03.015 . hal-03775769

HAL Id: hal-03775769

<https://hal.science/hal-03775769v1>

Submitted on 22 Jul 2024

HAL is a multi-disciplinary open access archive for the deposit and dissemination of scientific research documents, whether they are published or not. The documents may come from teaching and research institutions in France or abroad, or from public or private research centers.

L'archive ouverte pluridisciplinaire **HAL**, est destinée au dépôt et à la diffusion de documents scientifiques de niveau recherche, publiés ou non, émanant des établissements d'enseignement et de recherche français ou étrangers, des laboratoires publics ou privés.



Distributed under a Creative Commons Attribution - NonCommercial 4.0 International License

Infertility workup: identifying endometriosis

Paul Pirtea, MD^{1,2}

Nicolas Vulliemoz, MD³

Dominique de Ziegler, MD¹

Jean Marc Ayoubi, MD, PhD¹

¹Dept of Ob Gyn and Reproductive Medicine, Hopital Foch – Faculté de Medicine Paris Ouest (UVSQ),
Suresnes France 92150

³Dept

Address for correspondence:

Paul PIRTEA

Dept of Ob Gyn and Reproductive Medicine

Hopital Foch

Suresnes 92150 France

E-mail: paulpirtea@gmail.com

Summary

Endometriosis was classically diagnosed on the occasion of diagnostic laparoscopies, which used to be routinely performed up until a decade ago or so. This practice fitted with the long-held belief that surgery was the gold standard for diagnosing endometriosis. Today the abandon of routine diagnostic laparoscopies – in favor for *ART-first* therapeutic approaches – has created a void for diagnosis endometriosis. Modern-day imaging – ultrasound and MRI – when used with a systematic approach have offered a reliable replacement option for diagnosing endometriosis. In infertility, endometriosis should be identified or excluded based on past history or confirmation or exclusion suspicion based on history and/or physical examination.

Keywords

Endometriosis; Infertility; diagnosis; ultrasound; workup, MRI

Introduction

Classically, endometriosis was a surgical diagnosis, ideally with histological confirmation of the lesions removed (1) (2). The high efficacy of modern-day ART has led to progressively adopt *ART-first* approaches particularly, for women in their thirties. These new characteristics of infertility management lead therefore to raise the following practical questions:

- How should endometriosis be diagnosed today in infertile women?
- What is the impact of endometriosis on oocyte quality and ART outcome?
- What is the impact of endometriosis on endometrial receptivity?
- Is there still a place for surgery in the management of infertility associated with endometriosis?

The present review article addresses in practical terms the management of infertility associated with endometriosis with particular emphasis on its diagnosis and the consequences for clinical management.

The progressive subsidence of diagnostic laparoscopies

Not too long ago, diagnostic laparoscopies were still routinely performed in infertility workups notably (3), for diagnosing and treating endometriosis found in 35%-40% of infertile women (4). Today, ART achieves livebirth rates in excess of 40% in women under 35 years of age (https://www.sartcorsonline.com/rptCSR_PublicMultYear.aspx?reportingYear=2019) and similar results in older women provided that only euploid embryos are transferred (5). These remarkable results together with the fact that women seek infertility treatments at an ever-increasing age has led infertility specialists to more and more often offer *ART-first* approaches, at least when women are in their thirties.

The progressive abandon of diagnostic laparoscopies follows the accumulation of evidence that surgery for endometriosis – including endometriomas – does not improve ART outcome (6) (7) (8). On the contrary, reports have accumulated to indicate that surgery may actually harm by impairing ovarian reserve (9), more than endometriosis itself (10). Furthermore, contrary to observations made in ovarian stimulation and insemination, ART does not worsen endometriosis symptoms and has no impact on ovarian endometriomas or deep infiltrating endometriosis (11). While widely predominant, the view of no-surgery-before-ART is challenged by a few however notably, in case of colorectal endometriosis (12) (13).

The remaining indication for surgery in case of infertility associated with endometriosis is for enhancing the chances of conceiving naturally in the 12-18 months following surgery. In a seminal article, Vecellini et al. reported that surgery for pelvic endometriosis increased the chances of conceiving naturally

in the 18 months following surgery by approximately 50% (14). These data were later confirmed by others (15) (16). Prior to considering surgery for infertility associated with endometriosis one needs to verify that natural conception is possible – normal sperm and patent tubes – and that time and ovarian reserve exist for dedicating 12-18 months to attempt to conceive naturally (16). Practically, surgery is primarily envisioned in women in their twenties. One important new parameter is that the possible benefit from surgery should be established preoperatively, not during the procedure itself. Indeed determining beforehand – prior to surgery – whether a person is likely to benefit from surgery differs from prior practices that established the chance of conceiving during the surgical procedure (17).

The progressive abandon of diagnostic laparoscopies had two practical consequences: (i) Recent data have reported a decreased prevalence of endometriosis in infertile women over a 10-year study interval (18). This is in keeping with data of a study conducted using the Society for Assisted Reproductive Technologies (SART) database reporting an abnormally low incidence of endometriosis in only 11% in a cohort of 400,059 ART cycles (19). (ii) The demise of diagnostic laparoscopies has created a void for diagnosing endometriosis. This is now being filled in part by imaging-based approaches, using ultrasound or MRI for diagnosing ovarian and deep infiltrating endometriosis. Unfortunately, imaging-based approaches are poor at diagnosing superficial endometriosis.

One landmark publication on the use of ultrasound for diagnosing endometriosis has emphasized the role of systematic analysis of all areas where endometriosis is likely to develop, an approach defined as *mapping* technique (20). These results were then confronted with findings made at laparoscopies (20) and later refined (21) (22) (23). MRI, using a similar *mapping* technique, likewise allows to precisely characterize and diagnose endometriosis (24) as well as adenomyosis (25). Recently, it was concluded that trans-vaginal ultrasound with bowel preparation was equivalent to diagnostic laparoscopy, except for its inability to identify superficial endometriosis (26). Superficial endometriosis indeed escapes diagnosis by imaging (26).

In the future, truly non-invasive markers of endometriosis based on a panel of miRNAs may serve for singling out women affected with endometriosis (27). Like for other non-invasive biomarkers of endometriosis (28) (29) (30) (31), these data remain at research stage for the time being. As discussed below, to avoid under reporting endometriosis and failing to apply proper approaches while undertaking ART, proper imaging-based approaches for diagnosis ought to be deployed once endometriosis is clinically suspected.

Oocyte quality in case of endometriosis

The classical view portrayed endometriosis as being responsible for altering oocyte quality and thereby altering ART outcome. Our judgment is more subtle now, realizing that endometriosis may affect ovarian response to gonadotropin. While this effect may not impact actual implantation rates (32), even in the presence of endometriomas (33), it is likely however to diminish the ultimate cumulative pregnancy rate.

The actual information proffering that endometriosis altered oocyte quality were all indirect. These were either based on granulosa cell or follicular fluid markers (34), or using animal model based on in vivo fertilization (35) (36). Contrary to these views of altered oocyte quality in in-vivo derived conditions, there is now evidence that ART by sparing contact between the oocyte and the toxic environment of the pelvic cavity (37) (38) provides oocytes of unaltered quality. Indeed oocytes obtained by ART develop into embryos that have similar euploidy and implantation rates as those of age-matched controls (39) (40).

Today therefore we are confronted to a dichotomy when it comes to oocyte quality in case of infertility associated with endometriosis. On the one side, oocytes ovulated in vivo and therefore exposed even transitorily to the toxic characteristics of the pelvic cavity are of altered quality (36), whereas those obtained by ART are functionally normal (39) (40). This duality explains the reduced natural conception chances encountered in women with endometriosis, while recent ART studies indicated that implantation and livebirth rates are most often normal (41).

To account for the improved pregnancy chances observed following surgery for endometriosis (14) (15), one is inclined to postulate that surgery decreases – if only for a time – the toxic pelvic environment (37) (38) prevailing in endometriosis. On the contrary, clinical evidence suggests that this is not the case following medical treatment for endometriosis. Indeed, medical treatments of endometriosis, which all block ovulation and are therefore contraceptive (42) (43), reduce symptoms and risk of recurrence. Yet, the pelvic effects of these treatments, contrary to surgery, are not associated with a rebound of fertility upon stopping (44). Hence, medical treatment holds no place in the management of infertility associated with endometriosis.

Endometrial receptivity in case of endometriosis

The eutopic endometrium – in the uterus itself – is altered in case of endometriosis, a fact that is believed to affect endometrial receptivity to embryo implantation (45). These alterations have been incriminated in the presumed decreased embryo implantation rates once related in case of endometriosis.

In an extensive review of the topic, Bulun et al. report that the eutopic endometrium displays numerous cellular and molecular abnormalities (46). These include activation of oncogenic pathways or biosynthetic

cascades that favor increased production of estrogen, cytokines, prostaglandins, and metalloproteinases (47). This in turn causes an improper transformation of decidualized cells, as studied in vitro (48). In endometrial stromal cells, estrogen receptor β levels are 142-fold higher and estrogen receptor α 9-fold lower compared with normal endometrium (49), as a result of epigenetic changes (50) (46). The resulting abnormally high ratio of receptors β over receptors α affects the normal activation of the progesterone receptor gene. This in turn causes the characteristic progesterone resistance, which is emblematic of the endometrial changes encountered in endometriosis (51). Moreover, nerve tissue has been immunohistochemically identified in the functional layer of eutopic endometrial tissue in all women with endometriosis but not in the eutopic endometrium of disease-free women (52) (53).

The resulting inflammation of the eutopic endometrium has been hypothesized to generate or perpetuate the disease itself by disseminating activated endometrial progenitor cells through retrograde menstruation (54). Practically, the alterations of the eutopic endometrium have been claimed to alter endometrial receptivity to embryo implantation, including in ART (55) (28).

Ovarian suppression by hormone treatment appears to reverse the effects of endometriosis on the eutopic endometrium notably, on nerve fibers (56), markers of inflammation (57), local production of estradiol (58) and progesterone resistance (59). Recent ART data suggest that the ovarian suppression induced by the E2 and progesterone treatments used for timing FETs exerts a similar beneficial effects (40). Indeed, Bishop et al. reported that transfers of euploid blastocysts timed with estradiol and progesterone hormone replacement cycles had similar implantation rates in endometriosis and age-matched control women (40). This approach – freeze all and deferred embryo transfer – likely will replace the old approach that recommended prolonged ovarian suppression using either GnRH-a (60) or the contraceptive pill before ART cycles (61).

Endometriosis workup in infertility

At the onset of the infertility workup, one has to establish whether endometriosis exists, as per past surgery or ad hoc imaging procedures, or when suspected based on symptoms and/or pelvic examination (62). In case of clinical suspicion, appropriate imaging-based screening – ultrasound and/or MRI – ought to be undertaken. While in expert hands, ultrasounds and MRI appear equivalent in their ability to diagnose ovarian and deep infiltrating endometriosis, MRI images are operator independent and can be reassessed by a different radiologist. A recent systematic review and meta-analysis concluded that ultrasound and MRI were equivalent for diagnosing deep infiltrating endometriosis (63), as illustrated in Fig 1.

If endometriosis is diagnosed, the choice is between surgery for enhancing the chances of natural conception or ART. *ART-first* approaches are generally preferred today in women in their thirties. Indeed, in these women, delaying management by expecting to conceive naturally for 12-18 months after surgery might impair their overall prospect for pregnancy. This is also the cases if other elements compound infertility such as ovulatory, male factor or tubal issues or a sense of urgency from the side of the couple. If ART is opted for – whatever the reason – surgery is unnecessary and in general one proceeds directly to ART, following a new *no-surgery-before-ART* rule.

If endometriosis is diagnosed – either by prior history or because the clinical suspicion is confirmed – and ART is opted for, the following precautions are recommended. Exclusively use antagonist ovarian stimulation protocols, as a measure to avoid the risk of frank ovarian hyperstimulation syndrome (OHSS) with similar overall efficacy (64). Triggering of ovulation with GnRH-a is recommended. Not only using GnRH-a for inducing the final stage of oocyte maturation is preferred for avoiding OHSS, but it also decreases the risk of cyst formation – not desired in case of endometriosis. Differed embryo is in all cases preferred as ovarian suppression by hormone replacement cycles used for timing FETs quells the effects of endometriosis on the eutopic endometrium (40), as previously shown with GnRH-a treatment. Freeze all and deferred embryo transfer using E2 and progesterone replacement cycle optimizes implantation rates (40) as compared to fresh transfer (65), even if this view is not shared by all (66).

Conclusion

The workup of infertile women has been drastically changed over the past decade or so, notably by the abandon diagnostic laparoscopies, which were nearly routinely done in yesteryears. Today, *ART-first* approaches are most often preferred in women in their thirties and overwhelming data indicate that their results are not altered in case of endometriosis including endometriomas. In these cases, the novel *no-surgery-before-ART* is prone by most unless unmanageable pelvic pain exists and/or hydrosalpinges are present. In a few cases however – for women in their twenties – surgery may be preferred for enhancing the chances of conceiving naturally provided that there is time – age and ovarian reserve – to dedicate for natural conception. In the latter case, the sperm tubes and ovulatory functions need to be normal.

References

1. de Ziegler D, Borghese B, Chapron C. Endometriosis and infertility: pathophysiology and management. *Lancet*. 2010;376(9742):730-8.
2. Kennedy S, Bergqvist A, Chapron C, D'Hooghe T, Dunselman G, Greb R, et al. ESHRE guideline for the diagnosis and treatment of endometriosis. *Hum Reprod*. 2005;20(10):2698-704.
3. Tanahatoc S, Hompes PG, Lambalk CB. Accuracy of diagnostic laparoscopy in the infertility work-up before intrauterine insemination. *Fertil Steril*. 2003;79(2):361-6.
4. Evans MB, Decherney AH. Fertility and Endometriosis. *Clin Obstet Gynecol*. 2017;60(3):497-502.
5. Pirtea P, De Ziegler D, Tao X, Sun L, Zhan Y, Ayoubi JM, et al. Rate of true recurrent implantation failure is low: results of three successive frozen euploid single embryo transfers. *Fertil Steril*. 2021;115(1):45-53.
6. Brink Laursen J, Schroll JB, Macklon KT, Rudnicki M. Surgery versus conservative management of endometriomas in subfertile women. A systematic review. *Acta Obstet Gynecol Scand*. 2017;96(6):727-35.
7. Wu CQ, Albert A, Alfaraj S, Taskin O, Alkusayer GM, Havelock J, et al. Live Birth Rate after Surgical and Expectant Management of Endometriomas after In Vitro Fertilization: A Systematic Review, Meta-Analysis, and Critical Appraisal of Current Guidelines and Previous Meta-Analyses. *J Minim Invasive Gynecol*. 2019;26(2):299-311 e3.
8. Khan S, Lee CL. Treating Deep Endometriosis in Infertile Patients before Assisted Reproductive Technology. *Gynecol Minim Invasive Ther*. 2021;10(4):197-202.
9. Benaglia L, Castiglioni M, Paffoni A, Sarais V, Vercellini P, Somigliana E. Is endometrioma-associated damage to ovarian reserve progressive? Insights from IVF cycles. *Eur J Obstet Gynecol Reprod Biol*. 2017;217:101-5.
10. Streuli I, de Ziegler D, Gayet V, Santulli P, Bijaoui G, de Mouzon J, et al. In women with endometriosis anti-Mullerian hormone levels are decreased only in those with previous endometrioma surgery. *Hum Reprod*. 2012;27(11):3294-303.
11. Somigliana E, Vigano P, Benaglia L, Busnelli A, Paffoni A, Vercellini P. Ovarian stimulation and endometriosis progression or recurrence: a systematic review. *Reprod Biomed Online*. 2019;38(2):185-94.
12. Casals G, Carrera M, Dominguez JA, Abrao MS, Carmona F. Impact of Surgery for Deep Infiltrative Endometriosis before In Vitro Fertilization: A Systematic Review and Meta-analysis. *J Minim Invasive Gynecol*. 2021;28(7):1303-12 e5.
13. Bendifallah S, Roman H, Mathieu d'Argent E, Touleimat S, Cohen J, Darai E, et al. Colorectal endometriosis-associated infertility: should surgery precede ART? *Fertil Steril*. 2017;108(3):525-31 e4.
14. Vercellini P, Somigliana E, Vigano P, Abbiati A, Barbara G, Crosignani PG. Surgery for endometriosis-associated infertility: a pragmatic approach. *Hum Reprod*. 2009;24(2):254-69.
15. Muzii L, C DIT, Galati G, Mattei G, Chine A, Casciulli G, et al. Endometriosis-associated infertility: surgery or IVF? *Minerva Obstet Gynecol*. 2021;73(2):226-32.
16. Duckelmann AM, Taube E, Abesadze E, Chiantera V, Sehouli J, Mechsner S. When and how should peritoneal endometriosis be operated on in order to improve fertility rates and symptoms? The experience and outcomes of nearly 100 cases. *Arch Gynecol Obstet*. 2021;304(1):143-55.

17. Adamson GD, Pasta DJ. Endometriosis fertility index: the new, validated endometriosis staging system. *Fertil Steril.* 2010;94(5):1609-15.
18. Christ JP, Yu O, Schulze-Rath R, Grafton J, Hansen K, Reed SD. Incidence, prevalence, and trends in endometriosis diagnosis: a United States population-based study from 2006 to 2015. *Am J Obstet Gynecol.* 2021.
19. Senapati S, Sammel MD, Morse C, Barnhart KT. Impact of endometriosis on in vitro fertilization outcomes: an evaluation of the Society for Assisted Reproductive Technologies Database. *Fertil Steril.* 2016;106(1):164-71 e1.
20. Exacoustos C, Malzoni M, Di Giovanni A, Lazzeri L, Tosti C, Petraglia F, et al. Ultrasound mapping system for the surgical management of deep infiltrating endometriosis. *Fertil Steril.* 2014;102(1):143-50 e2.
21. Van den Bosch T, Van Schoubroeck D. Ultrasound diagnosis of endometriosis and adenomyosis: State of the art. *Best Pract Res Clin Obstet Gynaecol.* 2018;51:16-24.
22. Chapron C, Marcellin L, Borghese B, Santulli P. Rethinking mechanisms, diagnosis and management of endometriosis. *Nat Rev Endocrinol.* 2019;15(11):666-82.
23. Piessens S, Edwards A. Sonographic Evaluation for Endometriosis in Routine Pelvic Ultrasound. *J Minim Invasive Gynecol.* 2020;27(2):265-6.
24. Jaramillo-Cardoso A, Shenoy-Bhangle A, Garces-Descovich A, Glickman J, King L, Morteale KJ. Pelvic MRI in the diagnosis and staging of pelvic endometriosis: added value of structured reporting and expertise. *Abdom Radiol (NY).* 2020;45(6):1623-36.
25. Chapron C, Vannuccini S, Santulli P, Abrao MS, Carmona F, Fraser IS, et al. Diagnosing adenomyosis: an integrated clinical and imaging approach. *Hum Reprod Update.* 2020;26(3):392-411.
26. Goncalves MO, Siufi Neto J, Andres MP, Siufi D, de Mattos LA, Abrao MS. Systematic evaluation of endometriosis by transvaginal ultrasound can accurately replace diagnostic laparoscopy, mainly for deep and ovarian endometriosis. *Hum Reprod.* 2021;36(6):1492-500.
27. Bendifallah S, Dabi Y, Suisse S, Jornea L, Bouteiller D, Touboul C, et al. MicroRNome analysis generates a blood-based signature for endometriosis. *Sci Rep.* 2022;12(1):4051.
28. Lessey BA, Lebovic DI, Taylor RN. Eutopic endometrium in women with endometriosis: ground zero for the study of implantation defects. *Semin Reprod Med.* 2013;31(2):109-24.
29. Nisenblat V, Bossuyt PM, Shaikh R, Farquhar C, Jordan V, Scheffers CS, et al. Blood biomarkers for the non-invasive diagnosis of endometriosis. *Cochrane Database Syst Rev.* 2016(5):CD012179.
30. Coutinho LM, Ferreira MC, Rocha ALL, Carneiro MM, Reis FM. New biomarkers in endometriosis. *Adv Clin Chem.* 2019;89:59-77.
31. Chen T, Wei JL, Leng T, Gao F, Hou SY. The diagnostic value of the combination of hemoglobin, CA199, CA125, and HE4 in endometriosis. *J Clin Lab Anal.* 2021;35(9):e23947.
32. Matalliotakis IM, Cakmak H, Mahutte N, Fragouli Y, Arici A, Sakkas D. Women with advanced-stage endometriosis and previous surgery respond less well to gonadotropin stimulation, but have similar IVF implantation and delivery rates compared with women with tubal factor infertility. *Fertil Steril.* 2007;88(6):1568-72.
33. Hamdan M, Dunselman G, Li TC, Cheong Y. The impact of endometrioma on IVF/ICSI outcomes: a systematic review and meta-analysis. *Hum Reprod Update.* 2015;21(6):809-25.

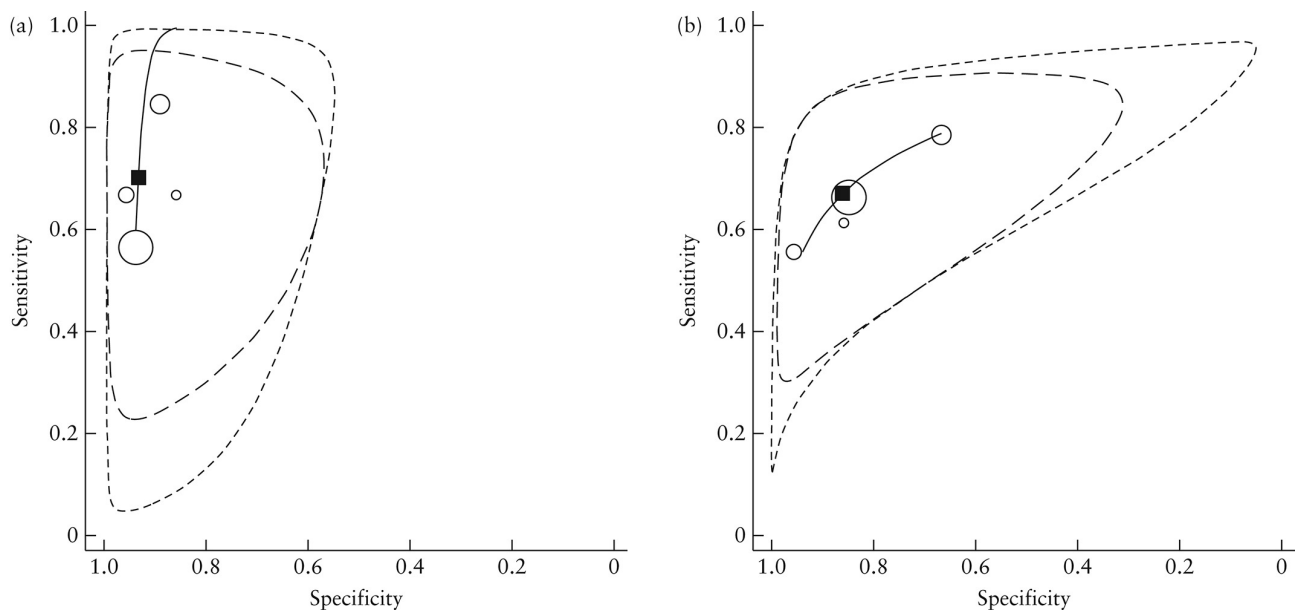
34. Carlberg M, Nejaty J, Froysa B, Guan Y, Soder O, Bergqvist A. Elevated expression of tumour necrosis factor alpha in cultured granulosa cells from women with endometriosis. *Hum Reprod.* 2000;15(6):1250-5.
35. Bilotas MA, Olivares CN, Ricci AG, Baston JI, Bengochea TS, Meresman GF, et al. Interplay between Endometriosis and Pregnancy in a Mouse Model. *PLoS One.* 2015;10(4):e0124900.
36. Cohen J, Ziyat A, Naoura I, Chabbert-Buffet N, Aractingi S, Darai E, et al. Effect of induced peritoneal endometriosis on oocyte and embryo quality in a mouse model. *J Assist Reprod Genet.* 2015;32(2):263-70.
37. Agostinis C, Balduit A, Mangogna A, Zito G, Romano F, Ricci G, et al. Immunological Basis of the Endometriosis: The Complement System as a Potential Therapeutic Target. *Front Immunol.* 2020;11:599117.
38. Lee YH, Yang JX, Allen JC, Tan CS, Chern BSM, Tan TY, et al. Elevated peritoneal fluid ceramides in human endometriosis-associated infertility and their effects on mouse oocyte maturation. *Fertil Steril.* 2018;110(4):767-77 e5.
39. Juneau C, Kraus E, Werner M, Franasiak J, Morin S, Patounakis G, et al. Patients with endometriosis have aneuploidy rates equivalent to their age-matched peers in the in vitro fertilization population. *Fertil Steril.* 2017;108(2):284-8.
40. Bishop LA, Gunn J, Jahandideh S, Devine K, Decherney AH, Hill MJ. Endometriosis does not impact live-birth rates in frozen embryo transfers of euploid blastocysts. *Fertil Steril.* 2020.
41. Metzemaekers J, Lust E, Rhemrev J, Van Geloven N, Twijnstra A, Van Der Westerlaken L, et al. Prognosis in fertilisation rate and outcome in IVF cycles in patients with and without endometriosis: a population-based comparative cohort study with controls. *Facts Views Vis Obgyn.* 2021;13(1):27-34.
42. Archer DF, Ng J, Chwalisz K, Chiu YL, Feinberg EC, Miller CE, et al. Elagolix Suppresses Ovulation in a Dose-Dependent Manner: Results From a 3-Month, Randomized Study in Ovulatory Women. *J Clin Endocrinol Metab.* 2020;105(3).
43. Vercellini P, Vigano P, Barbara G, Buggio L, Somigliana E, Luigi Mangiagalli. Endometriosis Study G. Elagolix for endometriosis: all that glitters is not gold. *Hum Reprod.* 2019;34(2):193-9.
44. Vercellini P, Crosignani P, Somigliana E, Vigano P, Frattaruolo MP, Fedele L. 'Waiting for Godot': a commonsense approach to the medical treatment of endometriosis. *Hum Reprod.* 2011;26(1):3-13.
45. Benaglia L, Cardellicchio L, Guarneri C, Paffoni A, Restelli L, Somigliana E, et al. IVF outcome in women with accidental contamination of follicular fluid with endometrioma content. *Eur J Obstet Gynecol Reprod Biol.* 2014;181:130-4.
46. Bulun SE, Yilmaz BD, Sison C, Miyazaki K, Bernardi L, Liu S, et al. Endometriosis. *Endocr Rev.* 2019;40(4):1048-79.
47. Noble LS, Takayama K, Zeitoun KM, Putman JM, Johns DA, Hinshelwood MM, et al. Prostaglandin E2 stimulates aromatase expression in endometriosis-derived stromal cells. *J Clin Endocrinol Metab.* 1997;82(2):600-6.
48. Barragan F, Irwin JC, Balayan S, Erikson DW, Chen JC, Houshdaran S, et al. Human Endometrial Fibroblasts Derived from Mesenchymal Progenitors Inherit Progesterone Resistance and Acquire an Inflammatory Phenotype in the Endometrial Niche in Endometriosis. *Biol Reprod.* 2016;94(5):118.

49. Xue Q, Lin Z, Cheng YH, Huang CC, Marsh E, Yin P, et al. Promoter methylation regulates estrogen receptor 2 in human endometrium and endometriosis. *Biol Reprod.* 2007;77(4):681-7.
50. Dyson MT, Roqueiro D, Monsivais D, Ercan CM, Pavone ME, Brooks DC, et al. Genome-wide DNA methylation analysis predicts an epigenetic switch for GATA factor expression in endometriosis. *PLoS Genet.* 2014;10(3):e1004158.
51. Aghajanova L, Tatsumi K, Horcajadas JA, Zamah AM, Esteban FJ, Herndon CN, et al. Unique transcriptome, pathways, and networks in the human endometrial fibroblast response to progesterone in endometriosis. *Biol Reprod.* 2011;84(4):801-15.
52. Tokushige N, Markham R, Russell P, Fraser IS. High density of small nerve fibres in the functional layer of the endometrium in women with endometriosis. *Hum Reprod.* 2006;21(3):782-7.
53. Tokushige N, Markham R, Russell P, Fraser IS. Different types of small nerve fibers in eutopic endometrium and myometrium in women with endometriosis. *Fertil Steril.* 2007;88(4):795-803.
54. Wang Y, Nicholes K, Shih IM. The Origin and Pathogenesis of Endometriosis. *Annu Rev Pathol.* 2020;15:71-95.
55. Brosens I, Brosens JJ, Benagiano G. The eutopic endometrium in endometriosis: are the changes of clinical significance? *Reprod Biomed Online.* 2012;24(5):496-502.
56. Tokushige N, Markham R, Russell P, Fraser IS. Effects of hormonal treatment on nerve fibers in endometrium and myometrium in women with endometriosis. *Fertil Steril.* 2008;90(5):1589-98.
57. Matson BC, Quinn KE, Lessey BA, Young SL, Caron KM. Elevated levels of adrenomedullin in eutopic endometrium and plasma from women with endometriosis. *Fertil Steril.* 2018;109(6):1072-8.
58. Maia H, Jr., Casoy J, Correia T, Freitas LA, Pimentel K, Athayde C. The effect of oral contraceptives on aromatase expression in the eutopic endometrium of patients with endometriosis. *Gynecol Endocrinol.* 2008;24(3):123-8.
59. Patel BG, Rudnicki M, Yu J, Shu Y, Taylor RN. Progesterone resistance in endometriosis: origins, consequences and interventions. *Acta Obstet Gynecol Scand.* 2017;96(6):623-32.
60. Surrey ES, Silverberg KM, Surrey MW, Schoolcraft WB. Effect of prolonged gonadotropin-releasing hormone agonist therapy on the outcome of in vitro fertilization-embryo transfer in patients with endometriosis. *Fertil Steril.* 2002;78(4):699-704.
61. de Ziegler D, Gayet V, Aubriot FX, Fauque P, Streuli I, Wolf JP, et al. Use of oral contraceptives in women with endometriosis before assisted reproduction treatment improves outcomes. *Fertil Steril.* 2010;94(7):2796-9.
62. Chapron C, Lafay-Pillet MC, Santulli P, Bourdon M, Maignien C, Gaudet-Chardonnet A, et al. A new validated screening method for endometriosis diagnosis based on patient questionnaires. *EClinicalMedicine.* 2022;44:101263.
63. Guerriero S, Saba L, Pascual MA, Ajossa S, Rodriguez I, Mais V, et al. Transvaginal ultrasound vs magnetic resonance imaging for diagnosing deep infiltrating endometriosis: systematic review and meta-analysis. *Ultrasound Obstet Gynecol.* 2018;51(5):586-95.
64. Drakopoulos P, Rosetti J, Pluchino N, Blockeel C, Santos-Ribeiro S, de Brucker M, et al. Does the type of GnRH analogue used, affect live birth rates in women with endometriosis undergoing IVF/ICSI treatment, according to the rAFS stage? *Gynecol Endocrinol.* 2018;34(10):884-9.

65. Bourdon M, Santulli P, Maignien C, Gayet V, Pocate-Cheriet K, Marcellin L, et al. The deferred embryo transfer strategy improves cumulative pregnancy rates in endometriosis-related infertility: A retrospective matched cohort study. *PLoS One*. 2018;13(4):e0194800.
66. Tan J, Cerrillo M, Cruz M, Cecchino GN, Garcia-Velasco JA. Early Pregnancy Outcomes in Fresh Versus Deferred Embryo Transfer Cycles for Endometriosis-Associated Infertility: A Retrospective Cohort Study. *J Clin Med*. 2021;10(2).

Fig. 1

Diagnosis of deep infiltrating endometriosis of the utero sacral ligament by MRI (a) and ultrasound (b)



Receiver–operating characteristics curves (—) for detection of deep infiltrating endometriosis involving uterosacral ligaments, using magnetic resonance imaging (a) or transvaginal ultrasound (b). ○, Study estimate; ■, summary point; - - -, 95% prediction region; — · —, 95% confidence region. From Guerriero et al. 2018 (63). (with permission)