



HAL
open science

Transient modifications of the olfactory bulb on MR follow-up of COVID-19 patients with related olfactory dysfunction

Amine Ammar, Léa Distinguin, Anaëlle Chetrit, Dominique M.L. Safa, Stéphane Hans, Robert Yves Carlier, Jérôme René Lechien, Myriam Edjlali

► To cite this version:

Amine Ammar, Léa Distinguin, Anaëlle Chetrit, Dominique M.L. Safa, Stéphane Hans, et al.. Transient modifications of the olfactory bulb on MR follow-up of COVID-19 patients with related olfactory dysfunction. *Journal de Neuroradiologie / Journal of Neuroradiology*, 2022, 49 (4), pp.329-332. 10.1016/j.neurad.2022.03.003 . hal-03775063

HAL Id: hal-03775063

<https://hal.science/hal-03775063>

Submitted on 22 Jul 2024

HAL is a multi-disciplinary open access archive for the deposit and dissemination of scientific research documents, whether they are published or not. The documents may come from teaching and research institutions in France or abroad, or from public or private research centers.

L'archive ouverte pluridisciplinaire **HAL**, est destinée au dépôt et à la diffusion de documents scientifiques de niveau recherche, publiés ou non, émanant des établissements d'enseignement et de recherche français ou étrangers, des laboratoires publics ou privés.



Distributed under a Creative Commons Attribution - NonCommercial 4.0 International License

Title:

Transient modifications of the olfactory bulb on MR follow-up of COVID-19 patients with related olfactory dysfunction

Authors:

Amine Ammar¹, Lea Distinguin², Anaëlle Chetrit¹, Dominique Safa¹, Stéphane Hans², Robert Carlier¹, Jerome R. Lechien^{2,3,4}, Myriam Edjlali^{1,5}

1. Department of Radiology, APHP, Hôpitaux Raymond-Poincaré & Ambroise Paré, DMU Smart Imaging, GH Université Paris-Saclay, U 1179 UVSQ/Paris-Saclay, Paris, France
2. Department of Otolaryngology-Head & Neck Surgery, Hôpital Foch, UVSQ/Paris-Saclay, Paris, France
3. Department of Otolaryngology-Head & Neck Surgery, CHU Saint-Pierre, Université Libre de Bruxelles, Brussels, Belgium
4. Department of Human Anatomy and Experimental Oncology, UMONS Research Institute for Health Sciences and Technology, University of Mons, Mons, Belgium
5. Laboratoire d'imagerie Biomédicale Multimodale (BioMaps), Université Paris-Saclay, CEA, CNRS, Inserm, Service Hospitalier Frédéric Joliot, Orsay, France

Authors' Note:

Amine Ammar and Lea Distinguin contributed equally to this article.

Jerome R. Lechien and Myriam Edjlali are senior authors who also contributed equally to this article.

Corresponding author:

Name: Dr. Amine Ammar

Professional address: Department of Radiology of AP-HP - Garches Hospital, 104 Boulevard Raymond-Poincaré, 92380 Garches, France

Personal phone number: 0033 643468055

Email address: amine.ammar@aphp.fr

Declarations of interest:

None.

1 **ABSTRACT**

2 **Background:** Olfactory dysfunction (OD) has been reported with a high prevalence on mild
3 to moderate COVID-19 patients. Previous reports suggest that volume and signal intensity of
4 olfactory bulbs (OB) have been reported as abnormal on acute phase of COVID-19 anosmia,
5 but a prospective MRI and clinical follow-up study of COVID-19 patients presenting with
6 OD was missing, aiming at understanding the modification of OB during patients' follow-up.

7 **Methods:** A prospective multicenter study was conducted including 11 COVID-19 patients
8 with OD. Patients underwent MRI and psychophysical olfactory assessments at baseline and
9 6-month post-COVID-19. T2 FLAIR-Signal intensity ratio (SIR) was measured between the
10 average signal of the OB and the average signal of white matter. OB volumes and obstruction
11 of olfactory clefts (OC) were evaluated at both evaluation times.

12 **Results:** The psychophysical evaluations demonstrated a 6-month recovery in 10/11 patients
13 (90.9%). The mean values of OB-SIR significantly decreased from baseline (1.66 ± 0.24) to 6-
14 month follow-up (1.35 ± 0.27), reporting a mean variation of $-17.82\pm 15.20\%$ ($p<0.001$).
15 The mean values of OB volumes significantly decreased from baseline ($49.22\pm 10.46\text{ mm}^3$) to
16 6-month follow-up ($43.70\pm 9.88\text{ mm}^3$), ($p=0.006$).

17 **Conclusion:** Patients with demonstrated anosmia reported abnormalities in OB imaging that
18 may be objectively evaluated with the measurement of SIR and OB volumes. SIR and OB
19 volumes significantly normalized when patient recovered smell. This supports the underlying
20 mechanism of a transient inflammation of the OB as a cause of Olfactory Dysfunction in
21 COVID-19 patients.

22

23 **KEY WORDS**

24 Anosmia; COVID-19; SARS-CoV-2; Magnetic Resonance Imaging; Olfaction Disorders

25

26 **ABBREVIATION**

27 COVID-19: coronavirus disease 2019

28 OB: olfactory bulb

29 OC: olfactory cleft

30 OD: olfactory dysfunction

31 SARS-CoV-2: severe acute respiratory syndrome coronavirus 2

32 SIR: signal intensity ratio

33 **INTRODUCTION**

34 Coronavirus disease-2019 (COVID-19), linked to the severe acute respiratory syndrome
35 coronavirus 2 (SARS-CoV-2), has been associated with many clinical pictures, ranging from
36 simple rhinitis to acute respiratory distress syndrome. Frequently, the infection has been
37 linked to smell and taste dysfunctions, reported in 50 to 86% of mild-to-moderate cases [1].
38 The olfactory dysfunction (OD) may develop through nasal obstruction, such as in common
39 cold, or be related to neurological viral spread through the olfactory cleft mucosa. In the first
40 paper reporting OD as a key symptom of the COVID-19 [1], more than 80% of patients
41 presented with OD without associated rhinorrhea or nasal obstruction. Volume and signal
42 intensity of OB have been reported as abnormal on acute phase of COVID-19 anosmia [2].
43 Although the symptoms remain most of the time regressive, MRI findings in patients with
44 prolonged COVID-19-induced OD was significantly associated with lower olfactory bulbs
45 (OB) heights [3], compared to controls. These findings support the perception that SARS-
46 CoV-2 may invade the central nervous system through the olfactory pathway, inflicting
47 immediate and potentially irreversible damage to neuronal structures like the OB. However, a
48 prospective longitudinal study was missing to demonstrate the existence of OB modifications
49 in terms of volume and aspect in parallel with the clinical follow up of patients recovering or
50 not from COVID-19 anosmia. We here report a prospective MRI and clinical follow-up study
51 of COVID-19 patients presenting with OD, aiming at understanding the modification of OB
52 during patients' follow-up.

53

54 **MATERIAL AND METHODS**

55 **Ethics, patient and setting**

56 The study was approved by the IRB of Foch Hospital (ID-RCB: 2020-A00832-37). Written
57 informed consent was obtained for participants.

58 From March to May 2020, COVID-19 patients with self-reported sudden OD were
59 prospectively recruited from two University Hospitals (Foch Hospital and Garches Hospital,
60 APHP, Paris, France). Patients had demonstrated mild to moderate COVID-19 through
61 serology or reverse transcription polymerase chain reaction (RT-PCR) findings. Patients with
62 a history of OD before the pandemic, nasal surgery, chronic rhinosinusitis, head and neck
63 trauma, degenerative neurological disease, or contraindication to MRI were excluded from the
64 study.

65 **Olfactory assessments**

66 Patients benefited from psychophysical olfactory assessments (Sniffin' Sticks tests,
67 Medisense, Groningen, Netherlands). The Sniffin' Sticks test is a validated psychophysical
68 olfactory test using 16 smell pens. Each pen was presented to the individual who had to
69 choose the adequate smell between four given options. The final score ranges from 0 (no
70 olfaction) to 16 (perfect olfaction). Hyposmia was defined by a score ranging from 9 to 11
71 and anosmia if <9 [4]. The objective evaluations were made within the two or four weeks
72 following the onset of the olfactory disease and throughout the follow-up.

73 The olfactory cleft specific Lund-Kennedy scoring (OC-LK) was performed to evaluate cleft
74 obstruction, this endoscopic score being correlated with the olfactory function in patients with
75 smell disorder [5].

76 The impact of COVID-19 on sinonasal symptoms was evaluated through the French version
77 of the sino-nasal outcome test-22 (SNOT-22) [6], which is a validated patient-reported
78 outcome questionnaire developed from the U.S. version [7].

79 **Imaging acquisition**

80 Imaging studies were performed on a 3 Tesla device (Discovery TM MR750, General
81 Electric, Milwaukee, WI, USA) with a 20-elements head and neck coil. The sequences
82 performed in order to assess the OB signal were 3D-FLAIR-CUBE and 3D-T2-FIESTA
83 acquired respectively in coronal and sagittal planes. The 3D-FLAIR sequence parameters
84 were: TR/TE 8000/133ms; section thickness 2mm; matrix 240×240; FOV 230×230mm; flip
85 angle 90° and acquisition time = 4min-36sec. The 3D-T2 FIESTA sequence parameters were:
86 TR/TE 5.9/2.5ms; section thickness 0.6mm; matrix 320×320; FOV 180×180mm; flip angle
87 55° and acquisition time=4min-32sec. The same protocol was conducted at the initial stage of
88 the infection and at 6-months follow-up.

89 **Image analysis**

90 Two experienced neuroradiologists, blinded to clinical data, independently reviewed the
91 images. A third neuroradiologist resolved potential discordances. Volumes of OB were
92 measured on 3D-T2 sequence using a post-processing application dedicated to
93 segmentation[8]: ITK-SNAP® 3.8 (www.itksnap.org).

94 Olfactory Cleft (OC) obstruction was evaluated on T2/FLAIR images and was defined partial
95 if it didn't affect the entire anteroposterior length.

96 Quantitative analysis was performed on T2/FLAIR image by adjusting contours of a ROI
97 centered on the OB on a coronal plane, in order to measure the average OB signal intensity. A
98 signal intensity ratio (SIR) was then calculated between the average signal of the OB and the

99 average signal of a ROI placed in the frontal white matter of normal appearance at the same
100 slice level.

101 **Statistical Analysis**

102 Statistical analyses were performed using the Statistical Package for the Social Sciences
103 (SPSS version 22.0; IBM Corp, Armonk, NY, USA). Intraclass correlation coefficient was
104 used to assess the reproducibility of OC obstruction, SIR and volume measurements of OB
105 across readers. For statistical analysis, a consensual proofreading was retained for
106 measurements of SIR and OB volumes. The outcomes were compared from baseline to 6-
107 month post-COVID-19 with Wilcoxon signed-rank test. A level of significance of $p < 0.05$ was
108 used.

109

110 **RESULTS**

111 Eleven anosmic patients were included. The mean age was 41.5 years (range 24-75 years).
112 Patients' characteristics are summarized in Table 1.

113 **Olfactory assessments**

114 Whereas all patients were initially anosmic, only 1 patient remained hyposmic on the 6
115 months follow-up (9.09%). The latter had a partial recovery with Sniffin' Sticks test
116 improving from 3 to 8.

117 At the initial examination, OC-LK was normal (score 0) in 8/11 patients (72.72%).

118 The mean SNOT-22 was 18.45 ± 19.65 (0-61) on the first exam, and was 10.36 ± 16.36 (range
119 0-47) on the follow-up examination. The hyposmic patient at the second examination had an
120 improvement of the SNOT-22 score from 43 to 0.

121 **Image analysis**

122 Five patients (45.54%) had partial OC obstruction, bilateral in 3 patients on the initial MRI.
123 These obstructions were regressive in all cases on the control MRI.

124 As for SIR and volume measurements of the OB, the intra-class correlation coefficient was
125 good for SIR measurement ($r=0.898$, 95%CI [0.770–0.956], $p < 0.001$) and excellent for OB
126 volumes measurement ($r=0.996$, 95%CI [0.991–0.998], $p < 0.001$).

127 The mean values of OB-SIR significantly normalized from baseline (1.66 ± 0.24) to 6-month
128 follow-up (1.35 ± 0.27), reporting a mean variation of -17.82 ± 15.20 % ($p < 0.001$; Figure 1).

129 The mean values of OB volumes significantly decreased from baseline (49.22 ± 10.46 mm³) to
130 6-month follow-up (43.70 ± 9.88 mm³), with a mean variation of -10.30 ± 13.01 % ($p = 0.006$;
131 Figure 2).

132 Concerning the patient with persistent hyposmia on the follow-up examination, MRI showed
133 a severe drop in signal intensity ratio (-23.96% and -27.72%) and of volumes (-27.03% and -
134 28.38%) in the right and left OB respectively.

135 Note that one patient presented multiple sclerosis-like lesions at first MRI, the disease being
136 not previously known.

137

138 **DISCUSSION**

139 MR imaging in COVID-19 anosmic patients showed initial increase in signal intensity and
140 volume of olfactory bulbs with a normalisation on 6 months-MRI-follow-up whilst 90% of
141 our patients clinically recovered smell. This supports the underlying mechanism of a transient
142 inflammation of the OB as a cause of OD in COVID-19 patients who recover. Initial signals
143 and volumes would then be increased due to inflammation, followed by a normalization of
144 these measures over time.

145 Laurendon *et al.* [9] reported similar findings in a 27-year-old COVID-19 anosmic patient
146 reporting edema and transient swelling of the OB. Initial inflammatory reaction in the OB
147 suggest a neural spread of the SARS-CoV-2 into the OC mucosa. Many viruses, including
148 previous forms of coronaviruses, are known to spread from the nasal epithelium to the
149 olfactory bulb and brain but in smaller proportion of cases [10,11]. Interestingly, the brain
150 spread of the virus was associated with concomitant brain damage in two recent studies
151 [12,13]. Accordingly, COVID-19 RNA was identified in the brains of patients, supporting the
152 neurological pattern of the virus [14]. The virus spreads through the angiotensin converting
153 enzyme 2 receptor (ACE2) and transmembrane serine protease 2 (TMPRSS2), which are both
154 expressed in OC epithelium and in the sustentacular cells of the OB [10,15]. The
155 inflammatory reaction starts in the neuroepithelium, which may appear obstructed on the
156 initial MRI. Eliezer *et al.* [16] found that OD and OC obstruction are present at the early stage
157 of the disease, and improved both at one-month follow-up, suggesting that OD in Covid-19
158 patients was caused, at least in part, by reversible inflammatory changes in the OC. In a recent
159 systematic review [17], opacification of OC (60/218 - 27.5%) together with normal OB
160 morphology and signal intensity (68/218 - 31.2%) were the most common imaging findings in
161 patients with olfactory dysfunction secondary to COVID-19. In our study, we found only
162 partial OC obstruction in only 4/11 patients on the initial MRI, totally regressive during
163 follow-up, explaining only partly OD. By adding a quantitative analysis of OB signal
164 intensity, our study supports the presence of an initial inflammation of OB as a cause of OD.
165 OB involvement in COVID-19 OD was also mentioned by Aragão *et al.* [18] who found a

166 hypersignal and/or an enhancement of OB on T1-weighted images, explaining the OD by the
167 presence of microbleeding and/or blood-brain barrier break. Kandemirli *et al.* [19] also
168 suggested the potential microhemorrhagic complications by finding a punctate hypointense
169 T2-weighted pattern within the OB in 4/23 patients with persistent COVID-19 OD. Those
170 abnormalities may represent a subsequent marker of severity of inflammatory lesion of the
171 OB.

172

173 Interestingly, patients with prolonged OD may develop OB atrophy. Tsivgoulis *et al.* [3]
174 demonstrated that prolonged SARS-CoV2-induced OD is significantly associated with lower
175 OB heights bilaterally compared to controls. Concerning our patient with persistent hyposmia
176 on the follow-up examination, MRI showed a severe decrease in volumes, corroborating this
177 hypothesis.

178 Certain limitations of the present study should be highlighted, including the small sample size
179 of our population and the fact that a vast majority of our patients recovered from anosmia,
180 which was not predictable at the initial time point.

181

182 **CONCLUSION**

183 COVID-19 anosmic patients reported initial increase in signal intensity and volume of
184 olfactory bulbs, followed by a normalization at 6 months-MRI-follow-up whilst patient
185 recovered smell. This supports the underlying mechanism of a transient inflammation of the
186 OB as a cause of Olfactory Dysfunction in COVID-19 patients who then recover. In a context
187 where the clinical examination of infected patient is still discouraged because of
188 aerosolization risk, our study supports that the investigation of anosmia through MRI is
189 feasible.

190

191

192 **ACKNOWLEDGEMENTS**

193 We thank Isabelle Ducamp for the management of the patient appointment, Pierre-Frédéric
194 Bourcier for his technical support on the optimization of MR sequence parameters, Florence
195 Toutain, Clément Serpette and all the MRI technicians involved in MRI examinations,
196 Florence Couppey and all the members of Foch DRCI for the project management.

197

198 **FUNDING**

199 This research did not receive any specific grant from funding agencies in the public,
200 commercial, or not-for-profit sectors.

201

202 **DATA AVAILABILITY STATEMENT**

203 The data that support the findings of this study are available on request from the
204 corresponding author. The data are not publicly available due to privacy or ethical
205 restrictions.

206 **REFERENCES**

- 207 [1] Lechien JR, Chiesa-Estomba CM, De Siati DR, Horoi M, Le Bon SD, Rodriguez A, et
208 al. Olfactory and gustatory dysfunctions as a clinical presentation of mild-to-moderate forms
209 of the coronavirus disease (COVID-19): a multicenter European study. *Eur Arch*
210 *Otorhinolaryngol* 2020;277:2251–61. <https://doi.org/10.1007/s00405-020-05965-1>.
- 211 [2] Chetrit A, Lechien JR, Ammar A, Chekkoury-Idrissi Y, Distinguin L, Circiu M, et al.
212 Magnetic resonance imaging of COVID-19 anosmic patients reveals abnormalities of the
213 olfactory bulb: Preliminary prospective study. *J Infect* 2020;81:816–46.
214 <https://doi.org/10.1016/j.jinf.2020.07.028>.
- 215 [3] Tsvigoulis G, Fragkou PC, Lachanis S, Palaiodimou L, Lambadiari V, Papathanasiou
216 M, et al. Olfactory bulb and mucosa abnormalities in persistent COVID-19-induced anosmia:
217 a magnetic resonance imaging study. *European Journal of Neurology* 2021;28:e6–8.
218 <https://doi.org/10.1111/ene.14537>.
- 219 [4] Hummel T, Kobal G, Gudziol H, Mackay-Sim A. Normative data for the “Sniffin’
220 Sticks” including tests of odor identification, odor discrimination, and olfactory thresholds:
221 an upgrade based on a group of more than 3,000 subjects. *Eur Arch Otorhinolaryngol*
222 2007;264:237–43. <https://doi.org/10.1007/s00405-006-0173-0>.
- 223 [5] Poletti SC, Murta G, Hähner A, Hummel T. Olfactory cleft evaluation: a predictor for
224 olfactory function in smell-impaired patients? *Eur Arch Otorhinolaryngol* 2018;275:1129–37.
225 <https://doi.org/10.1007/s00405-018-4913-8>.
- 226 [6] de Dorlodot C, Horoi M, Lefebvre P, Collet S, Bertrand B, Eloy P, et al. French
227 adaptation and validation of the sino-nasal outcome test-22: a prospective cohort study on
228 quality of life among 422 subjects. *Clin Otolaryngol* 2015;40:29–35.
229 <https://doi.org/10.1111/coa.12315>.
- 230 [7] Piccirillo JF, Merritt MGJ, Richards ML. Psychometric and clinimetric validity of the
231 20-Item Sino-Nasal Outcome Test (SNOT-20). *Otolaryngol Head Neck Surg* 2002;126:41–7.
232 <https://doi.org/10.1067/mhn.2002.121022>.
- 233 [8] Yushkevich PA, Piven J, Hazlett HC, Smith RG, Ho S, Gee JC, et al. User-guided 3D
234 active contour segmentation of anatomical structures: significantly improved efficiency and
235 reliability. *Neuroimage* 2006;31:1116–28. <https://doi.org/10.1016/j.neuroimage.2006.01.015>.
- 236 [9] Laurendon T, Radulesco T, Mugnier J, Géralt M, Chagnaud C, El Ahmadi A-A, et al.
237 Bilateral transient olfactory bulb edema during COVID-19–related anosmia. *Neurology*
238 2020;95:224. <https://doi.org/10.1212/WNL.0000000000009850>.
- 239 [10] Brann D, Tsukahara T, Weinreb C, Logan DW, Datta SR. Non-neural expression of
240 SARS-CoV-2 entry genes in the olfactory epithelium suggests mechanisms underlying
241 anosmia in COVID-19 patients. *BioRxiv* 2020:2020.03.25.009084.
242 <https://doi.org/10.1101/2020.03.25.009084>.
- 243 [11] Katal S, Balakrishnan S, Gholamrezanezhad A. Neuroimaging and neurologic findings
244 in COVID-19 and other coronavirus infections: A systematic review in 116 patients. *Journal*
245 *of Neuroradiology* 2021;48:43–50. <https://doi.org/10.1016/j.neurad.2020.06.007>.
- 246 [12] Politi LS, Salsano E, Grimaldi M. Magnetic Resonance Imaging Alteration of the
247 Brain in a Patient With Coronavirus Disease 2019 (COVID-19) and Anosmia. *JAMA*
248 *Neurology* 2020. <https://doi.org/10.1001/jamaneurol.2020.2125>.
- 249 [13] Girardeau Y, Gallois Y, De Bonnecaze G, Escudé B, Lafont C, Chattelier G, et al.
250 Confirmed central olfactory system lesions on brain MRI in COVID-19 patients with
251 anosmia: a case-series. *MedRxiv* 2020:2020.07.08.20148692.
252 <https://doi.org/10.1101/2020.07.08.20148692>.
- 253 [14] Li Y-C, Bai W-Z, Hashikawa T. The neuroinvasive potential of SARS-CoV2 may
254 play a role in the respiratory failure of COVID-19 patients. *J Med Virol* 2020;92:552–5.

255 <https://doi.org/10.1002/jmv.25728>.
256 [15] Meinhardt J, Radke J, Dittmayer C, Franz J, Thomas C, Mothes R, et al. Olfactory
257 transmucosal SARS-CoV-2 invasion as a port of central nervous system entry in individuals
258 with COVID-19. *Nature Neuroscience* 2020. <https://doi.org/10.1038/s41593-020-00758-5>.
259 [16] Eliezer M, Hamel A-L, Houdart E, Herman P, Housset J, Jourdain C, et al. Loss of
260 smell in COVID-19 patients: MRI data reveals a transient edema of the olfactory clefts.
261 *Neurology* 2020;10.1212/WNL.0000000000010806.
262 <https://doi.org/10.1212/WNL.0000000000010806>.
263 [17] Keshavarz P, Haseli S, Yazdanpanah F, Bagheri F, Raygani N, Karimi-Galougahi M.
264 A Systematic Review of Imaging Studies in Olfactory Dysfunction Secondary to COVID-19.
265 *Academic Radiology* 2021;28:1530–40. <https://doi.org/10.1016/j.acra.2021.08.010>.
266 [18] Aragão MFVV, Leal MC, Cartaxo Filho OQ, Fonseca TM, Valença MM. Anosmia in
267 COVID-19 Associated with Injury to the Olfactory Bulbs Evident on MRI. *Am J Neuroradiol*
268 2020. <https://doi.org/10.3174/ajnr.A6675>.
269 [19] Kandemirli SG, Altundag A, Yildirim D, Tekcan Sanli DE, Saatci O. Olfactory Bulb
270 MRI and Paranasal Sinus CT Findings in Persistent COVID-19 Anosmia. *Academic*
271 *Radiology* 2021;28:28–35. <https://doi.org/10.1016/j.acra.2020.10.006>.
272

273 **TABLE AND FIGURE LEGENDS:**

274 **Table 1:** Patients characteristics

275

276 **Figure 1: Signal intensity ratio (SIR) measurement**

277 Coronal Flair-weighted at the same level slices through the olfactory bulbs (OB) in a 32-year-
278 old anosmic female at the initial exam (A) and at the follow-up exam (B), performed
279 respectively at day 4 and 147 from onset of anosmia. The SIR between the average signal of
280 the OB (manual ROI) and the average signal of a ROI placed in the frontal same level white-
281 matter (circle) went from 1.63 to 1.05 on the right and from 1.68 to 0.96 on the left (fall of
282 35.26% and 42.45% respectively). There was a partial obstruction of right olfactory cleft
283 (dotted arrow) which regressed on control. Note the isointense signal OB (arrows) compared
284 to normal brain cortex (head of arrows).

285

286 **Figure 2: Measurement of the olfactory bulbs (OB) volumes**

287 Same level reformatted axial, frontal and sagittal 3D-T2-weighted slices through the
288 olfactory bulbs (OB) in a 26-year-old anosmic female at the initial exam (A, B, C) and at the
289 follow-up exam (D, E, F), performed respectively at 7 and 147 days from onset of anosmia.
290 OB volumes varied from 54.91 to 41.80 mm³ on the right and from 57.73 to 42.7 mm³ on the
291 left (decrease of 41.0% and 37.85% respectively).

292 **TABLE:**

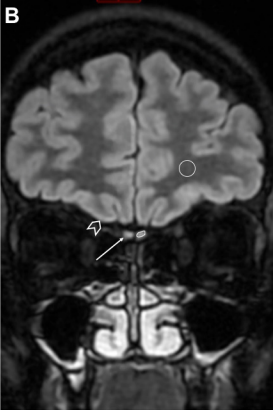
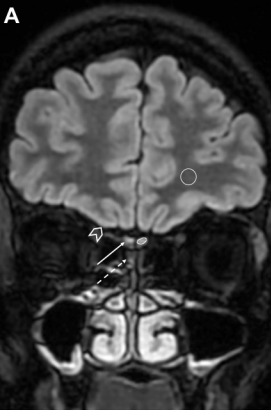
293

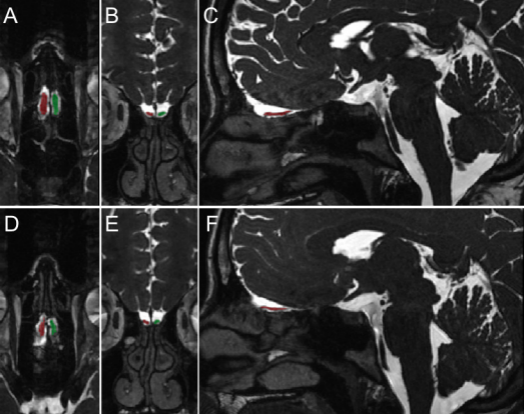
294

Table 1: Patients characteristics

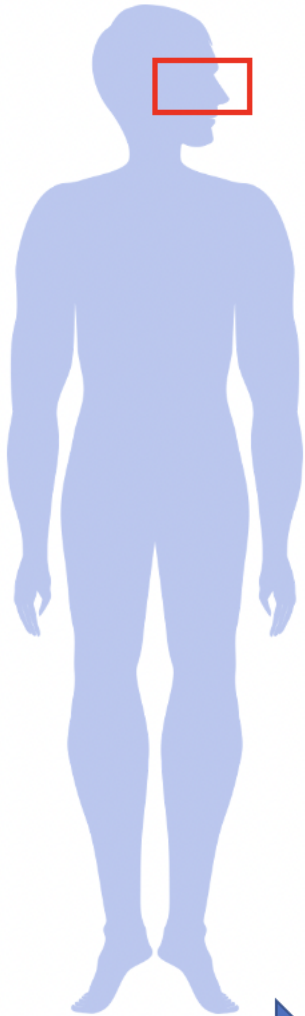
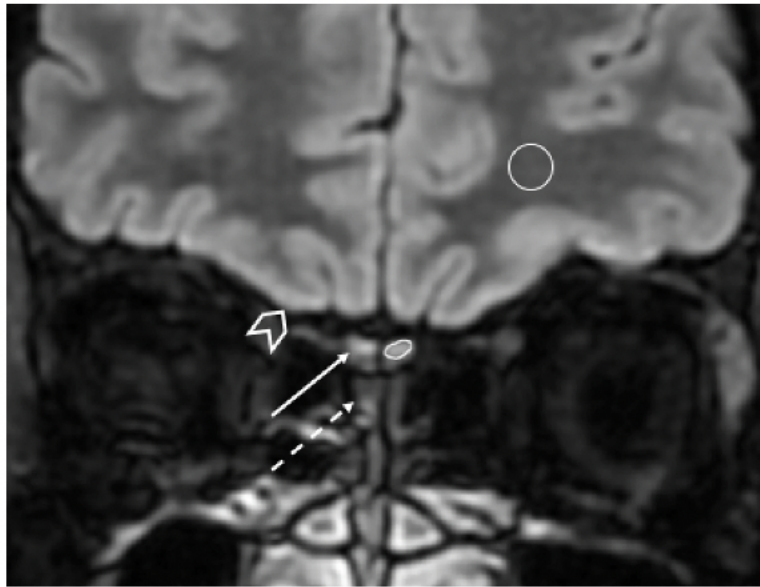
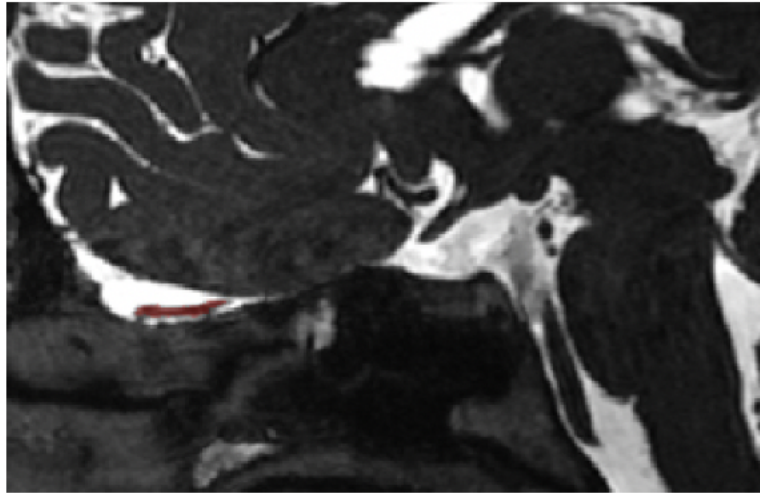
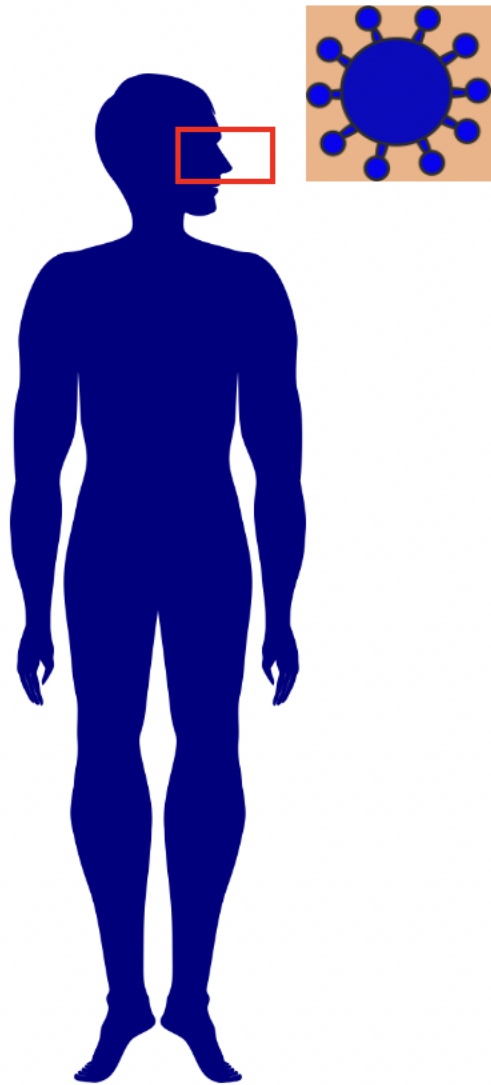
Characteristics	Patients (N-%)
Age (mean \pm SD) – years old	41.5 \pm 19.5
Gender (female/male)	7/4
Rhinological history	
Patients with seasonal allergy	3/11 (27.3)
Septoplasty	2/11 (18.2)
Other antecedents	
Dysthyroidism	2/11 (18.2)
Hypertension	1/11 (9.1)
Cardiac stent	1/11 (9.1)
Autoimmune disease	1/11 (9.1)
Endometriosis	1/11 (9.1)

295 SD: standard deviation





MR follow-up of COVID-19 patients with related olfactory dysfunction



Initial increase in T2 signal and in volume, with a normalization during follow-up, consecutive to smell recovery for patients