



HAL
open science

Aortic–tibial transiliac wing extra-anatomic bypass with distal fistula for treatment of an infected deep femoral pseudoaneurysm

Sébastien Multon, Jérémie Jayet, Isabelle Javerliat, Raphaël Coscas, Marc Coggia

► **To cite this version:**

Sébastien Multon, Jérémie Jayet, Isabelle Javerliat, Raphaël Coscas, Marc Coggia. Aortic–tibial transiliac wing extra-anatomic bypass with distal fistula for treatment of an infected deep femoral pseudoaneurysm. *Journal of Vascular Surgery Cases and Innovative Techniques*, 2022, 8 (2), <10.1016/j.jvscit.2022.02.008>. <hal-03775062>

HAL Id: hal-03775062

<https://hal.science/hal-03775062v1>

Submitted on 25 Oct 2022

HAL is a multi-disciplinary open access archive for the deposit and dissemination of scientific research documents, whether they are published or not. The documents may come from teaching and research institutions in France or abroad, or from public or private research centers.

L'archive ouverte pluridisciplinaire **HAL**, est destinée au dépôt et à la diffusion de documents scientifiques de niveau recherche, publiés ou non, émanant des établissements d'enseignement et de recherche français ou étrangers, des laboratoires publics ou privés.



Distributed under a Creative Commons CC BY 4.0 - Attribution - International License

Aortic–tibial transiliac wing extra-anatomic bypass with distal fistula for treatment of an infected deep femoral pseudoaneurysm

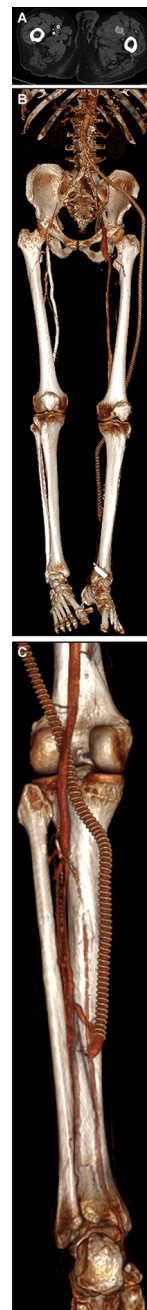
Sébastien Multon, MD,^a Jérémie Jayet, MD,^a Isabelle Javerliat, MD,^a Raphaël Coscas, MD, PhD,^{a,b} and Marc Coggia, MD,^a *Boulogne-Billancourt and Villejuif, France*

Transiliac wing bypass has been reported to be a viable extra-anatomic alternative technique for patients presenting with a history of groin infection or irradiation.¹ Of the 32 reported cases, only two patients had undergone transiliac aortic–tibial or iliotibial bypass.^{2,3} We report the case of a 72-year-old man with a complex history of multiple lower limb revascularizations, who had been admitted for a deep femoral infected anastomotic pseudoaneurysm (A) and left chronic limb threatening ischemia. Computed tomography showed chronic occlusions at the femoropopliteal level, with a previous thrombosed obturator canal bypass. The only patent lower leg artery was the posterior tibial artery (PTA) from its mid-third to the foot.

A transiliac wing aortic–tibial prosthetic bypass was performed through a pararectal retroperitoneal approach (B/Cover). The infrarenal aorta and common iliac arteries were cross-clamped before implanting an 8-mm expanded polytetrafluoroethylene graft soaked in rifampicin at the terminal aorta level. It was tunneled into the retroperitoneal space, over the psoas muscle. A U-shape osteotomy was performed at the anterior left iliac wing border through a second lateral incision to guide the bypass. Another incision was made at the lateral side of the thigh to guide the graft route between the femoral condyles. It was associated with a distal arteriovenous bypass between the PTA and a fibular vein (C), before the distal anastomosis of the aortic–tibial bypass, to partially deviate the aortic blood flow from the PTA into the venous circulation.

The second part of the procedure consisted of deep femoral pseudoaneurysm repair. It was developed at the distal anastomosis level of the thrombosed obturator canal bypass, which was removed to the obturator canal during the same procedure. The deep femoral artery was then ligated with 5-0 polypropylene suture.

Microbiologic analyses found the presence of methicillin-susceptible *Staphylococcus aureus* in the deep femoral false aneurysm, which was treated by 6 weeks of antibiotic therapy (intravenous daptomycin-cefepime for 3 days, which was switched to oral levofloxacin-rifampicin for a total of 6 weeks). At 3 months, the bypass was patent, and his symptoms were relieved. The patient provided institutional written informed consent for the report of his clinical information and imaging studies.



REFERENCES

1. Enzmann FK, Nierlich P, Eder SK, Aspalter M, Dabernig W, Aschacher T, et al. Trans-iliac bypass grafting for vascular groin complications. *Eur J Vasc Endovasc Surg* 2019;58:930-5.
2. Sekanina C, Lemminger F, Bruecher D. Iliaco-crural bypass through a borehole in the iliac fossa as extra-anatomic vascular bypass in infected inguinal canal and posterior aspect of the knee. *Chirurg* 1995;66:142-5.
3. Heldenberg E, Lorber J, Cheyn D, Bass A. Transiliac wing alternate route bypass for infected groin vascular graft. *J Vasc Surg* 2014;60:504-5.

Submitted Dec 3, 2021; accepted Feb 5, 2022.

From the Department of Vascular Surgery, Ambroise Paré University Hospital, Boulogne-Billancourt^a, and the UMR 1018, Inserm-Paris11 – CESP, Versailles Saint-Quentin-en-Yvelines University, Paris-Saclay University, Paul Brousse Hospital, Villejuif.^b

Author conflict of interest: none.

E-mail: multons@yahoo.fr.

The editors and reviewers of this article have no relevant financial relationships to disclose per the Journal policy that requires reviewers to decline review of any manuscript for which they may have a conflict of interest.

J Vasc Surg Cases Innov Tech 2022;8:201

2468-4287

© 2022 The Author(s). Published by Elsevier Inc. on behalf of Society for Vascular Surgery. This is an open access article under the CC BY-NC-ND license (<http://creativecommons.org/licenses/by-nc-nd/4.0/>).

<https://doi.org/10.1016/j.jvscit.2022.02.008>