



**HAL**  
open science

## Magic truffle intoxication: A case report

Brendan Le Daré, Romain Pelletier, Aurélien Couette, Isabelle Morel, Thomas Gicquel

### ► To cite this version:

Brendan Le Daré, Romain Pelletier, Aurélien Couette, Isabelle Morel, Thomas Gicquel. Magic truffle intoxication: A case report. *Emergency Care Journal*, 2022, 18 (2), pp.10347. 10.4081/ecj.2022.10347 . hal-03774788

HAL Id: hal-03774788

<https://hal.science/hal-03774788>

Submitted on 12 Sep 2022

**HAL** is a multi-disciplinary open access archive for the deposit and dissemination of scientific research documents, whether they are published or not. The documents may come from teaching and research institutions in France or abroad, or from public or private research centers.

L'archive ouverte pluridisciplinaire **HAL**, est destinée au dépôt et à la diffusion de documents scientifiques de niveau recherche, publiés ou non, émanant des établissements d'enseignement et de recherche français ou étrangers, des laboratoires publics ou privés.



Distributed under a Creative Commons Attribution - NonCommercial 4.0 International License

# Magic truffle intoxication: A case report

Brendan Le Daré,<sup>1</sup> Romain Pelletier,<sup>1,2</sup> Aurélien Couette,<sup>2</sup> Isabelle Morel,<sup>1,2</sup> Thomas Gicquel<sup>1,2</sup>

<sup>1</sup>Univ Rennes, INSERM, INRAE, CHU Rennes, Institut NuMeCan (Nutrition, Metabolisms and Cancer), Rennes; <sup>2</sup>Laboratoire de toxicologie biologique et medico-légale, CHU Pontchaillou, Rennes, France

## Abstract

Unusual forms of hallucinogenic mushrooms are emerging, which may delay diagnosis and compromise optimal management. Here, we discuss clinical and biological findings in a case of “magic mushroom” intoxication in a 20-year-old man who was brought to hospital emergency department in a state of euphoria, disorientation, intense visual hallucinations, episodic amnesia and agitation requiring physical restraint. The patient’s family brought intact specimens of the consumed product, without any health professional being able to identify it. Toxicological screening detected

psilocin in urine and in the unknown mushrooms, allowing guiding the mushroom identification towards the *Psilocybes* genus. Ten hours post-ingestion, the patient was discharged asymptomatic. We believe that recognition of the unusual form of hallucinogenic mushroom presented here by emergency physicians might contribute to better diagnosis and subsequent optimal management, especially since hallucinogenic substances are not routinely tested in toxicological analyses.

## Introduction

Intoxications by hallucinogenic compounds of natural origin may require emergency care.<sup>1</sup> Although many sources of these natural psychoactive substances are already well described, the related compounds may be found under different aspects and mixed with other substances, which might complicate the diagnosis in case of an atypical presentation. Here, we aim to describe clinical and biological findings in an unusual mushroom intoxication involving “magic truffles” leading to emergency department admission. The case report was approved by the research ethic committee of Rennes University Hospital and patient signed informed written consent.

## Case Report

The patient was a 20-year-old male subject with a history of frequent hallucinogenic mushroom consumption and no other associated substance abuse nor specific medical or surgical history. He referred of having consumed an unknown quantity of hallucinogenic natural product resembling truffles purchased on the internet. Four hours postingestion, he was brought to hospital emergency department in a state of euphoria, disorientation, intense visual hallucinations, episodic amnesia and agitation requiring physical restraint and the administration of an alprazolam 0.25 mg tablet. The patient’s family brought intact specimens of the consumed product (“magic mushroom”), without any health professional being able to identify it (Figure 1). Initial evaluation revealed a temperature of 37.6°C, blood pressure of 155/99 mmHg and heart rate of 106 beats per minute. The pupils were reactive in bilateral mydriasis. His Glasgow Coma Scale score was 15. Due to stable cardiopulmonary (including an electrocardiogram showing normal QRS complex, no repolarization disorder, no conduction disorder) and neurological examinations, the patient was only rehydrated and monitored, and biological samples were collected. Routine chemistry performed on blood sample found normal ionogram except for hypokalaemia at 3.3 mM (3.4-4.5 mM), bicarbonates at 21 mM (22-31 mM) and hypophosphoremia at 0.53 mM (0.8-1.6 mM). Renal and hepatic function were normal. No significant alterations were detected on blood count except for increased leukocytes at 12.4 G/L (4-10 G/L) and increased neutrophils at 10.6 G/L (1.8 - 7.5 G/L). Coagulation markers were normal.

Correspondence: Thomas Gicquel, Laboratoire de toxicologie biologique et medico-légale, CHU Pontchaillou, 2 Rue Henri Le Guilloux, 35000 Rennes, France.  
E-mail: thomas.gicquel@chu-rennes.fr

Key words: Psilocybes; psilocybin; sclerotia; poisoning

Contribution: All authors participated in the conception and design of the work, drafted the work, or critically reviewed it. All authors approved the final version for publication.

Conflict of interest: The authors declare no conflict of interest.

Availability of data and materials: All data underlying the findings are fully available.

Ethics approval and consent to participate: The case report was approved by the research ethic committee of Rennes University Hospital. Informed consent was obtained from the patient included in this study.

Consent for publication: The patient gave his written consent to use his personal data for the publication of this case report and any accompanying images.

Received for publication: 28 December 2021.

Revision received: 4 April 2021.

Accepted for publication: 4 April 2021.

This work is licensed under a Creative Commons Attribution 4.0 License (by-nc 4.0).

©Copyright: the Author(s), 2022

Licensee PAGEPress, Italy

Emergency Care Journal 2022; 18:10347

doi:10.4081/ecj.2022.10347

*Publisher's note: All claims expressed in this article are solely those of the authors and do not necessarily represent those of their affiliated organizations, or those of the publisher, the editors and the reviewers. Any product that may be evaluated in this article or claim that may be made by its manufacturer is not guaranteed or endorsed by the publisher.*

Neither alcohol nor drugs of abuse (LSD, tricyclic antidepressant, buprenorphine, methadone, benzodiazepines, barbiturates, cannabis, cocaine, opiates, and amphetamines) were detected using standard toxicological screening. Toxicological screening detected psilocin (the pharmacologically active agent resulting from psilocybin metabolism) using liquid chromatography coupled with tandem mass spectrometry in urine and in the unknown mushrooms provided to the emergency department. These findings allowed guiding the identification of the mushroom towards the *Psilocybes* genus. Ten hours post-ingestion, the patient was discharged asymptomatic with normal biochemical test and electrocardiogram.

## Discussion

Intact mushroom specimens were sent for identification in a specialized laboratory but the exact species could not be precisely identified (Figure 1). Among Psilocybin and/or psilocin alkaloids containing mushrooms, numerous varieties of *Psilocybe sp.* can form, under established conditions, brownish sclerotia (*i.e.* mass of hyphal threads, capable of remaining dormant for long periods) that are commonly named “magic truffles” or “Philosopher’s stone”.<sup>2,3</sup> Legislation of most countries, especially in the United States of America and Europe, ban the sale, the possession and the use of psilocybin and/or psilocin alkaloids and therefore mushrooms containing it by extension. However, in some countries including the Netherlands the ban is not consensual, leading to a legal loophole where the mushroom is banned but not the sclerotia.<sup>4</sup> This legal vacuum currently allows the emergence of a new trend in the supply of psychoactive alkaloids of *Psilocybes*, easily available *via* numerous websites called “smartshop”.<sup>5</sup>

Since the psychodysleptic composition of the “magic truffles”, *i.e.* mostly psilocybin and/or psilocin, in their sclerotia form is close to most forms of hallucinogenic *Psilocybes*,<sup>5</sup> clinical findings of hallucinogenic effect are similar. The interaction of psilocybin on serotonergic transmission through its agonist activity of 5-HT<sub>2A</sub> and 5-HT<sub>1A</sub> receptors is thought to explain the psychodysleptic effects of *Psilocybes* mushrooms.<sup>6</sup> Recently, both psilocin plasma levels and 5-HT<sub>2AR</sub> occupancy have been closely associated with subjective intensity of psychedelic effects, which confirms that the stimulation of 5-HT<sub>2AR</sub> receptors is a determining factor of the psychedelic experience.<sup>7</sup> Also, psilocin is known to induce cardiotoxic effects due to its ability to block potassium cardiac channels, prolonging QTc in susceptible persons and thus increasing the risk of ventricular tachycardia “torsade de pointes” and cardiac arrest.<sup>8-10</sup> This cardiotoxicity could explain the tachycardia observed in the patient. Considering that hypokalemia is a

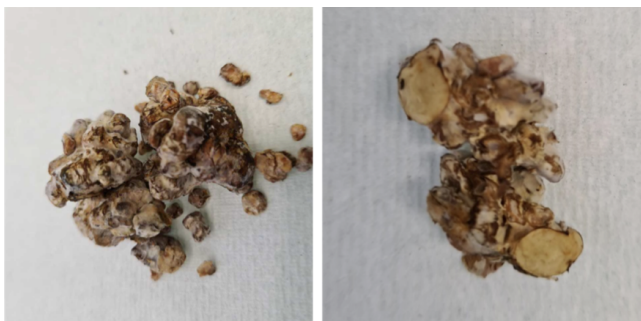


Figure 1. Magic truffles brought by the patient.

risk factor for cardiac arrhythmias in the context of QTc prolongation<sup>11</sup> and potentially associated with these intoxications as shown here, particular attention should be paid to cardiological monitoring in the context of intoxication with psilocybin or psilocin-containing mushrooms. As a timely laboratory identification of psilocin or other hallucinatory substances is unlikely to be available in Emergency setting, the recognition of the clinical pattern of *Psilocybes* poisoning by Emergency physicians can help to perform a rapid correct diagnosis in order to apply the best management. Therefore, beyond the issue of hallucinogenic mushroom intoxication in its classical forms,<sup>6</sup> the mycological considerations reported in this unusual case of hospitalization due to “magic truffles” take on their full importance here for the emergency physicians. Most importantly, these points highlight that a patient with a history and clinical picture suggestive of drug abuse and a “negative” urgent standard toxicology screen in the emergency department could guide the emergency physician to hallucinogenic or New Psychoactive Substance (NPS) use. Second, a second-level analysis (as presented here) should evaluate or rule out the presence of NPS. Third, it is important to assess the patient’s history as well; most patients who use hallucinogens do so for recreational purposes, but some patients also do so in an attempt to self-medicate anxiety and depression. This is important to consider upon arrival in the emergency department, as it may be the starting point for a specific patient management pathway after the acute phase (*e.g.*, evaluation in a mental health and substance abuse service).

## Conclusions

The emerging use of *Psilocybes* sclerotia (*i.e.* “magic truffles”) is likely to lead to an increase in cases of poisoning resulting in hospitalization. We believe that recognition of this unusual form of hallucinogenic mushroom by emergency physicians might contribute to better diagnosis and subsequent optimal management, especially since hallucinogenic substances are not routinely tested in toxicological analyses.

## References

1. Björnstad K, Hultén P, Beck O, Helander A. Bioanalytical and clinical evaluation of 103 suspected cases of intoxications with psychoactive plant materials. *Clin Toxicol* 2009;47:566-72.
2. Malaca S, Lo Faro AF, Tamborra A, et al. Toxicology and Analysis of Psychoactive Tryptamines. *Int J Mol Sci* 2020;21:9279.
3. Laussmann T, Meier-Giebing S. Forensic analysis of hallucinogenic mushrooms and khat (*Catha edulis*Forsk) using cation-exchange liquid chromatography. *Forensic Sci Int* 2010;195:160-4.
4. Lo Faro AF, Di Trana A, La Maida N, et al. Biomedical analysis of New Psychoactive Substances (NPS) of natural origin. *J Pharm Biomed Anal* 2020;179:112945.
5. Pellegrini M, Rotolo MC, Marchei E, et al. Magic truffles or Philosopher’s stones: a legal way to sell psilocybin?: Psilocybin in *Psilocybe Sclerotia*. *Drug Test Anal* 2013;5:182-5.
6. Passie T, Seifert J, Schneider U, Emrich HM. The pharmacology of psilocybin. *Addict Biol* 2002;7:357-64.
7. Madsen MK, Fisher PM, Burmester D, et al. Psychedelic effects of psilocybin correlate with serotonin 2A receptor occupancy and plasma psilocin levels. *Neuropsychopharmacology*

- 2019;44:1328-34.
8. Becker AM, Holze F, Grandinetti T, et al. Acute Effects of psilocybin after escitalopram or placebo pretreatment in a randomized, double-blind, placebo-controlled, crossover study in healthy subjects. *Clin Pharmacol Ther* 2021;cpt.2487.
  9. Dahmane E, Hutson PR, Gobburu JVS. Exposure-response analysis to assess the concentration-QTc relationship of psilocybin/psilocin. *Clin Pharmacol Drug Dev* 2021;10:78-85.
  10. Li S, Ma Q-B, Tian C, et al. Cardiac arrhythmias and cardiac arrest related to mushroom poisoning: A case report. *World J Clin Cases* 2019;7:2330-5.
  11. Vandael E, Vandenberg B, Vandenberghe J, et al. Risk factors for QTc-prolongation: systematic review of the evidence. *Int J Clin Pharm* 2017;39:16-25.

Non-commercial use only