



**HAL**  
open science

## [18F]FDG brain PET findings in CLIPPERS at diagnosis and therapeutic follow-up

Tatiana Horowitz, Elsa Kaphan, Eric Guedj

### ► To cite this version:

Tatiana Horowitz, Elsa Kaphan, Eric Guedj. [18F]FDG brain PET findings in CLIPPERS at diagnosis and therapeutic follow-up. *European Journal of Nuclear Medicine and Molecular Imaging*, In press, 10.1007/s00259-022-05939-x . hal-03770599

**HAL Id: hal-03770599**

**<https://hal.science/hal-03770599v1>**

Submitted on 27 Oct 2022

**HAL** is a multi-disciplinary open access archive for the deposit and dissemination of scientific research documents, whether they are published or not. The documents may come from teaching and research institutions in France or abroad, or from public or private research centers.

L'archive ouverte pluridisciplinaire **HAL**, est destinée au dépôt et à la diffusion de documents scientifiques de niveau recherche, publiés ou non, émanant des établissements d'enseignement et de recherche français ou étrangers, des laboratoires publics ou privés.

# [<sup>18</sup>F]FDG brain PET findings in CLIPPERS at diagnosis and therapeutic follow-up

Tatiana Horowitz<sup>1</sup> · Elsa Kaphan<sup>2</sup> · Eric Guedj<sup>1</sup>

Diagnosis of chronic lymphocytic inflammation with pontine perivascular enhancement responsive to steroids (CLIPPERS) relies on histopathological findings showing lymphocytic infiltration and MRI typical supportive features: punctuate pontocerebellar predominant gadolinium enhancement on corresponding T2 hyperintense lesions [1]. Treatment consists of steroid therapy or immunotherapy, with possible relapses [1].

A 70-year-old man was referred for the metabolic characterization of undefined spot-like lesions of brainstem, thalamus, and internal temporal cortices enhanced lesions on MRI T1-weighted (1) axial (a) and frontal images (b).

[<sup>18</sup>F]FDG fused PET/MRI (2) revealed an intense radiotracer uptake of lesions and striatum. Cortex/lesion ratio was 1.9, with relative decrease of the rest of the brain metabolism (2). Stereotaxic biopsy revealed CLIPPERS, and pretherapeutic PET consequently served as baseline (2). Follow-up with [<sup>18</sup>F]FDG PET identified first a partial metabolic response 12 months later (3) and then relapses with internal temporal, pons, and thalamic hypermetabolism 24 months later, permitting treatment modification under the guidance of PET results, whereas MRI was poorly modified. Clinically, he presented with fluctuating ataxia and binocular diplopia.

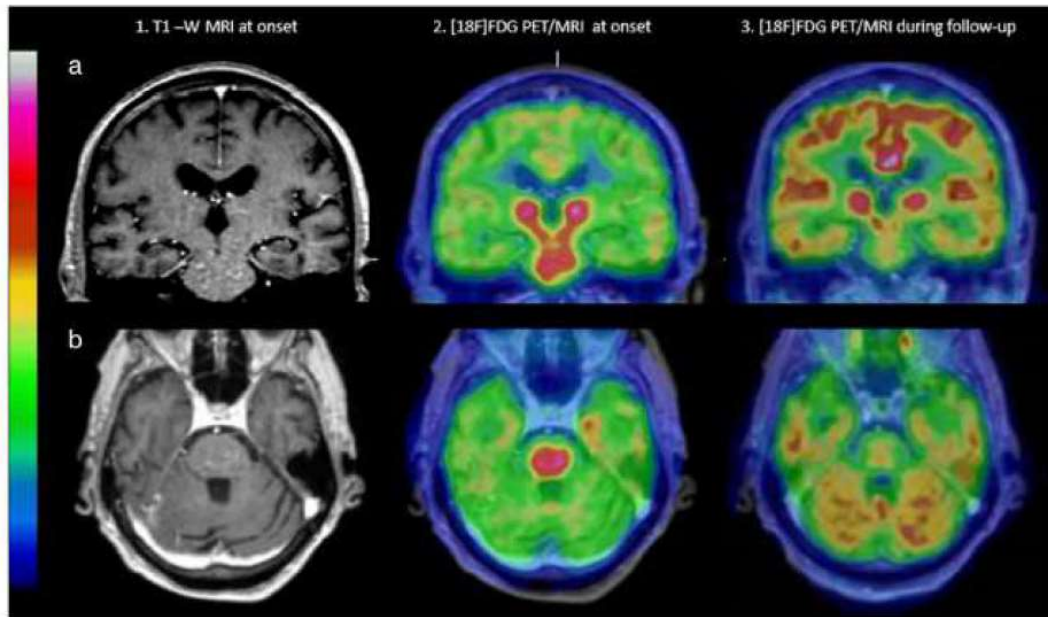
---

This article is part of the Topical Collection on Image of the month.

✉ Tatiana Horowitz  
Tatiana.horowitz@ap-hm.fr

<sup>1</sup> Institut Fresnel, Nuclear Medicine Department, Service Central de Biophysique Et Médecine Nucléaire, APHM, CNRS, Timone Hospital, CERIMED, Aix Marseille Univ, Centrale Marseille 264 rue Saint Pierre, 13005 Marseille, France

<sup>2</sup> Service de Médecine Interne, CHU Conception, APHM, Marseille, France



While [ $^{18}\text{F}$ ]FDG PET is used in routine for brain lesion characterization [2], it has gained an increasing role in the diagnosis and monitoring of inflammatory disorders [3]. To our knowledge, this is the first image of [ $^{18}\text{F}$ ]FDG brain PET CLIPPERS in the literature, showing that CLIPPERS lesions may have a high glucose uptake mimicking primary cerebral lymphoma [4] and that [ $^{18}\text{F}$ ]FDG PET may be a useful tool for disease monitoring and featuring relapses and metabolic response.

## References

1. Tobin WO, Guo Y, Krecke KN, Parisi JE, Lucchinetti CF, Pittock SJ, et al. Diagnostic criteria for chronic lymphocytic inflammation with pontine perivascular enhancement responsive to steroids (CLIPPERS). *Brain*. 2017;140(9):2415–25.
2. Chen W. Clinical applications of PET in brain tumors. *J Nucl Med*. 2007;48(9):1468–81.
3. Chen X, Chen G, Fu Z, Li Q. 18F-FDG PET/CT findings in a patient with neurosarcoidosis. *Clin Nucl Med*. 2020;45(8):640–1.
4. Kawai N, Miyake K, Yamamoto Y, Nishiyama Y, Tamiya T. 18F-FDG PET in the diagnosis and treatment of primary central nervous system lymphoma. *Biomed Res Int*. 2013;17(2013):e247152.

## Declarations

**Conflict of Interest** The authors declare no competing interests.