



HAL
open science

Primary progressive aphasia associated with C9orf72 expansions: Another side of the story

Dario Saracino, Amandine Géraudie, Anne Remes, Sophie Ferrieux, Marie Noguès-Lassiaille, Simona Bottani, Lorenzo Cipriano, Marion Houot, Aurélie Funkiewiez, Agnès Camuzat, et al.

► To cite this version:

Dario Saracino, Amandine Géraudie, Anne Remes, Sophie Ferrieux, Marie Noguès-Lassiaille, et al.. Primary progressive aphasia associated with C9orf72 expansions: Another side of the story. *Cortex*, 2021, 145, pp.145-159. 10.1016/j.cortex.2021.09.005 . hal-03769616

HAL Id: hal-03769616

<https://hal.science/hal-03769616v1>

Submitted on 5 Jan 2024

HAL is a multi-disciplinary open access archive for the deposit and dissemination of scientific research documents, whether they are published or not. The documents may come from teaching and research institutions in France or abroad, or from public or private research centers.

L'archive ouverte pluridisciplinaire **HAL**, est destinée au dépôt et à la diffusion de documents scientifiques de niveau recherche, publiés ou non, émanant des établissements d'enseignement et de recherche français ou étrangers, des laboratoires publics ou privés.



Distributed under a Creative Commons Attribution - NonCommercial 4.0 International License

Primary progressive aphasia associated with *C9orf72* expansions:

Another side of the story

AUTHORS

Dario Saracino, MD^{1,2,3}; Amandine Géraudie, MSc^{4,5}; Anne M Remes, MD, PhD^{6,7}; Sophie Ferrieux²; Marie Noguès-Lassialle²; Simona Bottani, MSc^{1,3}; Lorenzo Cipriano, MD^{1,8}; Marion Houot, MSc^{1,2,9}; Aurélie Funkiewiez, PhD^{2,10}; Agnès Camuzat, BSc^{1,11}; Daisy Rinaldi, PhD^{1,2}; Marc Teichmann, MD, PhD^{1,2,10}; Jérémie Pariente, MD, PhD^{4,5}; Philippe Couratier, MD, PhD¹²; Claire Boutoleau-Bretonnière, MD, PhD¹³; Sophie Auriacombe, MD¹⁴; Frédérique Etcharry-Bouyx, MD, PhD¹⁵; The French research network on FTD/FTD-ALS and PREV-DEMALS study groups*; Richard Levy, MD, PhD^{1,2,10}; Raffaella Migliaccio, MD, PhD^{1,2,10}; Eino Solje, MD, PhD^{16,17}; Isabelle Le Ber, MD, PhD^{1,2,10}

AFFILIATIONS

¹Sorbonne Université, Paris Brain Institute – Institut du Cerveau – ICM, Inserm U1127, CNRS UMR 7225, AP-HP - Hôpital Pitié-Salpêtrière, Paris, France.

²Reference Centre for Rare or Early-Onset Dementias, IM2A, Département de Neurologie, AP-HP - Hôpital Pitié-Salpêtrière, Paris, France

³Aramis Project Team, Inria Research Center of Paris, Paris, France

⁴Department of Neurology, Toulouse University Hospital, Toulouse, France

⁵ToNIC, Toulouse NeuroImaging Centre, Inserm, UPS, University of Toulouse, Toulouse, France

⁶Research Unit of Clinical Neuroscience, Neurology, University of Oulu, Oulu, Finland

⁷MRC Oulu, Oulu University Hospital, Oulu, Finland

⁸Department of Advanced Medical and Surgical Sciences, University of Campania “L. Vanvitelli” – Naples, Italy

⁹Center of Excellence of Neurodegenerative Disease (CoEN), ICM, CIC Neurosciences, Département de Neurologie, AP-HP - Hôpital Pitié-Salpêtrière, Sorbonne Université, Paris, France

¹⁰Paris Brain Institute – Institut du Cerveau (ICM), FrontLab, Paris, France

¹¹EPHE, PSL Research University, Paris, France

¹²CMRR Service de Neurologie, CHU de Limoges, 2 avenue Martin Luther King, 87 000 Limoges, France

¹³CHU Nantes, Inserm CIC04, Department of Neurology, Centre Mémoire de Ressources et Recherche, Nantes, France

¹⁴CMRR Nouvelle Aquitaine / Institut des Maladies Neurodégénératives clinique (IMNc), CHU de Bordeaux Hôpital Pellegrin, Bordeaux, France

¹⁵Department of Neurology, CMRR Angers University Hospital, Angers, France

¹⁶Institute of Clinical Medicine - Neurology, University of Eastern Finland, Kuopio, Finland

¹⁷Neuro Center, Neurology, Kuopio University Hospital, Kuopio, Finland

***The French clinical and genetic research network on FTD/FTD-ALS and the PREV-DEMALS**

study group include: Sophie Auriacombe (CHU Pellegrin, Bordeaux), Serge Belliard (CHU Rennes), Frédéric Blanc (Hôpitaux Civils, Strasbourg), Eve Benchetrit (Hôpital Pitié-Salpêtrière, Paris), Hugo Bertin (Hôpital Pitié-Salpêtrière, Paris), Claire Boutoleau-Bretonnière (CHU Laennec, Nantes), Anne Bertrand (Hôpital Pitié-Salpêtrière, Paris), Anne Bissery (Hôpital Pitié-Salpêtrière, Paris), Stéphanie Bombois (CHU Roger Salengro, Lille), Marie-Paule Boncoeur (CHU Limoges), Alexis Brice (Hôpital Pitié-Salpêtrière, Paris), Mathieu Ceccaldi (CHU La Timone, Marseille), Mathieu Chastan (CHU Charles Nicolle, Rouen), Yaohua Chen (CHU Roger Salengro, Lille), Marie Chupin (ICM, Paris), Olivier Colliot (ICM, Paris), Philippe Couratier (CHU Limoges), Xavier Delbeuck (CHU Roger Salengro, Lille), Christine Delmaire (CHU Roger Salengro, Lille), Vincent Deramecourt (CHU Roger Salengro, Lille), Mira Didic (CHU La Timone, Marseille), Charles Duyckaerts (Hôpital Pitié-Salpêtrière, Paris), Frédérique Etcharry-Bouyx (CHU Angers), Maïté Formaglio (CHU Lyon), Emmanuel Gerardin (CHU Charles Nicolle, Rouen),

Véronique Golfier (CHU Rennes), Marie-Odile Habert (Hôpital Pitié-Salpêtrière, Paris), Didier Hannequin (CHU Charles Nicolle, Rouen), Lucette Lacomblez (Hôpital Pitié-Salpêtrière, Paris), Julien Lagarde (CHU Sainte Anne, Paris), Géraldine Lautrette (CHU Limoges), Isabelle Le Ber (Hôpital de la Salpêtrière, Paris), Benjamin Le Toullec (ICM, Paris), Marie-Anne Mackowiak (CHU Roger Salengro, Lille), Olivier Martinaud (CHU Charles Nicolle, Rouen), Bernard-François Michel (CH Sainte-Marguerite, Marseille), Jacques Monteil (CHU Limoges), Assi-Hervé Oya (Hôpital Pitié-Salpêtrière, Paris), Jérémie Pariente (CHU Rangueil, Toulouse), Florence Pasquier (CHU Roger Salengro, Lille), Grégory Petyt (CHU Roger Salengro, Lille), Daisy Rinaldi (Hôpital Pitié-Salpêtrière, Paris), Adeline Rollin-Sillaire (CHU Roger Salengro, Lille), Carole Roué-Jagot (CHU Sainte Anne, Paris), Sabrina Sayah (Hôpital Pitié-Salpêtrière, Paris), Marie Sarazin (CHU Sainte Anne, Paris), Christel Thauvin-Robinet (CHU Dijon), Catherine Thomas-Anterion (Plein-Ciel, Lyon), François Sellal (CH Colmar), Martine Vercelletto (CHU Laennec, Nantes), and David Wallon (CHU Charles Nicolle, Rouen).

CORRESPONDING AUTHOR

Dr Isabelle Le Ber, Institut du Cerveau (ICM) – Paris Brain Institute, AP-HP - Hôpital Pitié-Salpêtrière, Paris, France. Email: isabelle.leber@upmc.fr. Phone number: +33 01 57 27 46 77

Word count

Title: 12 words (79 characters without spaces); Abstract: 235 words; Text: 4692 words; References: 73; Figures: 2; Tables: 2; Supplementary Figures: 3; Supplementary tables: 3.

Running Head Title

Primary progressive aphasia with *C9orf72* mutations.

ABSTRACT

C9orf72 repeat expansions are rarely associated with primary progressive aphasia (PPA). In-depth characterization of the linguistic deficits, and the underlying patterns of grey-matter atrophy in PPA associated with the *C9orf72* expansions (PPA-*C9orf72*) are currently lacking. In this study, we comprehensively analyzed a unique series of 16 patients affected by PPA-*C9orf72*. Eleven patients were issued from two independent French and Finnish cohorts, and five were identified by means of literature review. Voxel-based morphometry (VBM) studies were performed on three of them.

This study depicts the spectrum of *C9orf72*-related aphasic phenotypes, and illustrates their linguistic presentation. The non-fluent/agrammatic variant was the most frequent phenotype in our series (9/16 patients, 56%), with apraxia of speech being the main defining feature. Left frontal lobe atrophy was present in these subjects, peaking in inferior frontal gyrus. Three patients (19%) showed the semantic variant, with progression of atrophy in temporo-polar regions, later involving orbitofrontal cortex. Anterior temporal lobe dysfunction was also particularly relevant in two patients (12.5%) with mixed forms of PPA. Lastly, two patients (12.5%) had unclassifiable PPA with predominating word-finding difficulties. No PPA-*C9orf72* patients in our series fulfilled the criteria of the logopenic variant.

Importantly, this study underlines the role of *C9orf72* mutation in the disruption of the most anterior parts of the language network, including prefrontal and temporo-polar areas. It provides guidelines for *C9orf72* testing in PPA patients, with important clinical impact as gene-specific therapies are upcoming.

Keywords

Primary progressive aphasia, frontotemporal dementia, frontotemporal lobar degeneration, *C9orf72*, progranulin (*GRN*).

1. INTRODUCTION

Primary progressive aphasia (PPAs) are rare neurodegenerative diseases initially presenting with speech and language disorders (Gorno-Tempini et al., 2011). The non-fluent/agrammatic variant (nfvPPA) is associated with effortful language production, agrammatism and apraxia of speech, related to involvement of inferior frontal gyrus of the dominant hemisphere. The semantic variant (svPPA) is dominated by conceptual knowledge and language comprehension deficits, associated with anterior temporal lobe atrophy. The logopenic variant (lvPPA) is characterized by phonological working memory impairment with single-word retrieval and sentence repetition deficits, and predominant temporal-parietal junction involvement in the hemisphere specialized into language. However, this classification may not be applied to all cases, some of them not meeting criteria for any of the abovementioned variants (unclassifiable PPA, uPPA), or fulfilling criteria for more than one variant (mixed PPA, mPPA) (Bergeron et al., 2018).

In some patients, PPA phenotypes are caused by mutations in genes responsible for autosomal dominant frontotemporal dementias (FTD). Gene-specific lesion tropism leads to the neuroanatomical profile of cortical atrophy and, hence, in some cases to the resulting predominant linguistic deficits. As such, PPAs are associated with *GRN* mutations in ~15-20% of carriers (Moore et al., 2020; Saracino et al., 2021) and their phenotypes are dominated by non-amyloid lvPPA and nfvPPA linguistic variants (Le Ber et al., 2008; Moore et al., 2020; Saracino et al., 2021). Conversely, *MAPT* (Henz et al., 2015), *TARDBP* (Caroppo et al., 2015; Gelpi et al., 2014; González-Sánchez et al., 2018; Mol et al., 2021), and *TBKI* mutations (Caroppo et al., 2015; Pottier et al., 2015; van der Zee et al., 2017; Hirsch-Reinshagen et al., 2019; Swift et al., 2021) much more rarely cause a PPA syndrome; in those rare instances, linguistic impairment usually meets criteria of svPPA, and less frequently nfvPPA.

C9orf72 repeat expansions are the most frequent genetic cause of FTD and amyotrophic lateral sclerosis (ALS). PPA variants are rather exceptional *C9orf72*-associated phenotypes (Boeve et al., 2012; Majounie et al., 2012; Moore et al., 2020). Therefore, their main linguistic deficits, and the underlying patterns of

grey-matter atrophy are not well characterized. To fill this gap, we analyzed the linguistic and neuroanatomical profiles of a unique series of 16 PPA patients carrying *C9orf72* expansions (PPA-*C9orf72*), including 11 patients coming from two independent French and Finnish study cohorts, and five additional patients with in-depth clinical descriptions identified in the literature.

2. MATERIALS AND METHODS

2.1. Study design and patients

The patients analyzed in the French cohort of this study were prospectively included in the context of a national clinical and research network on FTD and ALS between 1996 and 2020 (Research project RBM02-59), as well as PREV-DEMALS study (ClinicalTrials.gov Identifier: NCT02590276). All participating centers employed comparable diagnostic protocols and clinical evaluations (Le Ber et al., 2006; Saracino et al., 2021). Molecular analyses were performed in all patients to search for FTD disease-causing mutations. The ethics committee of Paris-Necker Hospital approved the study. All patients provided written informed consent. No part of the study procedures and analyses was pre-registered prior to the research being conducted. We report how we determined our sample size, all data exclusions, all inclusion/exclusion criteria, whether inclusion/exclusion criteria were established prior to data analysis, all manipulations, and all measures in the study. During this time interval, 330 patients carrying *C9orf72* expansions (at least >30 repeats) were included, 11 (3.3%) of whom received an initial diagnosis of PPA (PPA-*C9orf72*). Five were excluded because of severely compromised language/cognitive functions at first evaluation (n=3), or CSF biomarkers consistent with Alzheimer disease (AD) co-pathology (n=2, one with svPPA and one with lvPPA phenotype).

Here, we report the linguistic and clinical characteristics of the remaining six PPA-*C9orf72* patients, among which CSF biomarkers were negative in four (not analyzed in two: #2 and #3). They did not carry mutations in all known FTD-causative genes, and had plasma progranulin levels within normal limits. The standardized speech/language evaluation protocol was carried out with the Boston Diagnostic Aphasia

Examination–French version (BDAE/HDAE-F) (Mazaux and Orgogozo, 1982) (n = 5) and/or the Montreal-Toulouse protocol for examination of aphasia (MT86) (Nespolous et al., 1992) (n= 3). Two patients were tested with both batteries. All underwent more extensive language evaluations also including oral confrontation naming (Deloche and Hannequin, 1997), buccofacial praxis (Teichmann et al., 2013), phonological and semantic fluencies (Godefroy and GREFEX, 2008), the Pyramid and Palm-Tree Test (PPTT) (Howard and Patterson, 1992) or the BECS-GRECO semantic battery (Merck et al., 2011). Other cognitive domains were evaluated with a semi-standardized battery (Saracino et al., 2021).

Additionally, five patients belonging to a Finnish cohort, that have been partially described in a prior study (Haapanen et al., 2020), were included for a more detailed linguistic analysis in the current work. They were diagnosed at the Kuopio University Hospital between 1996 and 2016. They were all of Finnish descent and were not tested for other FTD-causative mutations, which are, however, extremely rare in the Finnish population, likely due to genetic isolation (Haapanen et al., 2020). Their speech/language evaluation relied on the Western Aphasia Battery (WAB) (Shewan and Kertesz, 1980), whereas the other cognitive domains were tested in neuropsychological assessment including the Consortium to Establish a Registry for Alzheimer’s disease neuropsychological battery (CERAD-NB). Legal copyright restrictions prevent public archiving of the various assessment instruments and test batteries used in this study, which can be obtained from the copyright holders in the cited references.

The diagnosis of PPA variant was based on international criteria (Gorno-Tempini et al., 2011). Patients were labelled as mPPA when criteria for more than one variant co-occurred in a relatively early disease stage (Bergeron et al., 2018), and as uPPA when their linguistic impairment did not meet the criteria for any of the variants.

After the first evaluation, patients were periodically evaluated for usual clinical care. The median disease duration at the last follow-up was 4.0 years [IQR: 2.6, 5.0]. Some patients secondarily developed additional neurological or cognitive symptoms leading to secondary diagnoses (Table 1).

2.2. Voxel-based morphometry (VBM) analysis

We performed VBM analyses to characterize the neuroanatomical features in two PPA-*C9orf72* patients with the nfvPPA phenotype (nfvPPA-*C9orf72*), and in a third patient with the svPPA phenotype (svPPA-*C9orf72*). This latter individual was evaluated multiple times. Their 3D T1-weighted MRI scans were all performed ≤ 6 months before or after clinical evaluation. They were compared with 35 controls selected to match each patient based on their demographic characteristics.

We employed a VBM-based approach with the *T1-volume* pipeline of Clinica (<http://www.clinica.run>), a wrapper of the segmentation, run Dartel, and normalize to Montreal Neurological Institute (MNI) space routines implemented in Statistical Parametrical Mapping (SPM). After the unified segmentation procedure, a group template was created using Dartel, and the Dartel-to-MNI method was then applied, incorporating the native space images into the MNI space.

We used two-sample t-tests for the group analysis, applying the contrast PPA-*C9orf72* vs controls, with age at MRI and gender as nuisance covariates. In order to capture the full extent of brain atrophy, we generated false discovery rate (FDR)-corrected maps at cluster level, because of the well-known limited statistical power of single-subject VBM. We used the AAL3.1 atlas to label cortical and subcortical regions harboring significant differences (Rolls et al., 2020).

2.3. Literature review

We performed an extensive literature review to get deeper insights in linguistic characteristics of previously reported PPA-*C9orf72* patients (AG, DS). A PubMed search employed the following search terms: ((*C9orf72*) OR (chromosome 9 open reading frame 72) OR (c9)) AND ((primary progressive aphasia) OR (PPA)) OR frontotemporal* from 2011 (year of *C9orf72* identification) to 2021. A total of 874 articles were found, 53 of which were initially selected for full-text review after a first screening of research studies on PPA and *C9orf72* written in English. We subsequently reviewed the 31 more relevant

papers specifically focusing on genetic screening in PPA cohorts, or on phenotypic characterization of *C9orf72* cohorts or cases, to eventually focus only on those dealing with PPA-*C9orf72* patients. We excluded the papers without detailed clinical/linguistic descriptions (n=26) or in which the causative role of *C9orf72* expansion was not unequivocal (e.g., CSF biomarker profile in favor of AD pathology or presence of a second FTD or AD-disease causing mutation, n=2) (Supplementary Table 1). Finally, only five PPA-*C9orf72* patients had in-depth linguistic evaluation and could be kept in the study (Hsiung et al., 2012; Snowden et al., 2012; Cerami et al., 2013).

3. RESULTS

3.1. Clinical phenotypes

Overall, 16 PPA-*C9orf72* patients including our six novel French patients, five Finnish patients and five cases from the literature, were described and analyzed in this study. Their median age at onset was 63 (range: 39-78). Patients were at an early stage of the disease, as reflected by the short median disease duration (DD) (2.0 years; interquartile range, IQR: 1.5, 2.5). Their demographic, clinical and linguistic features are summarized in Table 1. In order to better illustrate the heterogeneity of clinical phenotypes, we described in detail the clinical histories and the linguistic characteristics of three paradigmatic cases, each presenting a different PPA variant. The conditions of our ethics approval do not permit public archiving of the individual patient clinical, behavioral and linguistic data supporting this study. Readers seeking access to the data should contact the corresponding author (Dr. Isabelle Le Ber). Data will be shared with named individuals following completion of a data sharing agreement and approval by the local ethics committee.

3.1.1. Patient #01: svPPA

At the age of 39, this right-handed patient with high-grade education (20 years of formal education) started to complain of insidious language difficulties. They mainly consisted of loss of word meaning, anomia, and difficulties in oral comprehension, especially with some idiomatic expressions. Notably, he had difficulties

with his professional vocabulary (he worked as a veterinarian but could not define words such as “hippopotamus” or “chick”), mistook the names of his colleagues, and became unable to completely understand scientific articles.

Speech/language evaluation (BDAE) at 3 years from onset showed fluent, moderately informative language, with anomia, semantic/verbal paraphasias, and circumlocutions. The severity of aphasia was rated 3/5. Naming was impaired (DO80: 52/80, below 2.5 SD), as well as single-word comprehension (56/72 for the BDAE subtest, normal value (n.v.) >68/72) and object knowledge (visual version of the PPTT: 33/52; n.v. >47/52). At the sentence level, comprehension was mildly affected in both the oral (14/15 for the BDAE commands subtest, n.v. >12/15) and written modalities (8/10 for the BDAE sentences and paragraphs comprehension subtest, n.v. >8/10). Surface dyslexia and dysgraphia were present. Repetition, motor speech and syntactic skills were unaffected. The Mini-Mental State Examination (MMSE) was 27/30. There was no evidence of dysexecutive disorders, episodic memory impairment, or visuo-spatial or visuo-constructive dysfunction (forward and backward digit span: 7 and 7, Rey-Osterrieth Complex Figure copy and recall: 36/36 and 22.5/36). Brain MRI at age 43 showed left temporal pole atrophy (Figure 1A), with corresponding hypometabolism on cerebral ¹⁸FDG-PET (Figure 1B).

At 4.5 years from onset, the patient presented further deterioration of naming (DO80: 47/80) and semantic skills (PPTT: 25/52), along with increasing difficulties in reading and writing irregular words. Global cognitive efficiency remained stable and there was no evidence of additional cognitive deficits. After six years of follow-up (45 years), the patient manifested severe difficulties in understanding conversational speech, while his verbal output was almost not understandable due to word-finding difficulties and circumlocutions. He also displayed some repetitive, ritualistic-obsessive behaviors and behavioral disinhibition. Initial impairment in executive functions was noticed at cognitive testing (Frontal Assessment Battery, FAB: 15/18). Left temporal atrophy became more extensive in a follow-up brain MRI performed at age 46, along with subtle prefrontal atrophy (Figure 1C).

Comprehension difficulties became so severe as to no longer allow oral or written communication by the age of 47, eight years from onset. There was a family history of psychosis in one of the patient's cousins.

3.1.2. Patient #04: nfvPPA

Patient #04, a right-handed person with 9 years of formal education, complained of difficulties in speech production with articulatory troubles at age 57, progressively leading to reduction of speech output. Moreover, he displayed mild personality changes with impulsiveness, reduced initiative and unawareness of risks. Speech/language evaluation (MT86) at age 58 revealed apraxia of speech, reduced fluency and loss of prosody, with moderately affected intelligibility (aphasia severity score 4/5). Syntactic difficulties were evident in speech production and perception, with impaired comprehension of complex sentences (30/38 for the syntactic MT86 subtest, n.v. >34/38). Morphosyntactic troubles were present also in sentence writing tasks (18/34 for the MT86 word and sentence writing subtest, n.v. >29/34). Phonological and semantic fluencies were reduced (13 words in 2 minutes for both: between 2.5 and 1.5 SD for phonological, and below 2.5 SD for semantic fluency). Repetition and semantic knowledge were unaffected. His MMSE was 27/30. Some elements of executive dysfunction were evident at neuropsychological testing (FAB 12/18; forward digit span: 5; backward digit span: 3). Episodic memory, praxis and visuospatial functions were unimpaired. Neurological examination did not reveal bulbar or pseudobulbar signs, and there was no dysphagia; muscle atrophy and fasciculations were absent, and there were no pyramidal signs. At age 58 brain MRI revealed bilateral cortico-subcortical fronto-temporal atrophy, prevailing in left peri-sylvian areas (Figure 2A). Bilateral prefrontal, left fronto-opercular and anterior temporal hypometabolism was found in ¹⁸FDG-PET (Figure 2B). CSF biomarkers were not in favor of AD.

At 2.5 years from onset, a mild right-predominant akinetic-rigid syndrome was present at neurological examination; pyramidal or motor neuron signs did not appear during follow-up, and EMG testing was

persistently negative. The family history was positive for dementia in the patient's mother, who deceased at 72 years.

3.1.3. Patient #06: mPPA

This right-handed patient with 11 years of education complained of initial difficulties in language production at age 68, with reduced fluency and troubles in word-finding, without comprehension impairment. His first speech/language evaluation at age 70, two years from onset, revealed non-fluent, slowed utterances with apraxia of speech (aphasia severity rating 3/5). Buccofacial apraxia was noticed too, with major impact on tongue movements. Aside from his articulatory disorder, he presented impairment in naming (DO80:54/80, below 2.5 SD), due to a combination of semantic and phonemic paraphasias. Occasional paragraphic errors (inversion or substitution of syllables) were noticed in writing tasks. His MMSE was 27/30 and Mattis Dementia Rating Scale (MDRS) 122/144, with prevailing deficit in the initiation subtask (23/37), which is a proxy of categorial verbal fluency. Executive impairment was present (FAB 14/18; TMT below 10th percentile), whereas episodic memory was relatively spared. Brain MRI evidenced bilateral fronto-temporal atrophy, with slight predominance on the left perisylvian areas (Figure 2C). Cerebral ¹⁸FDG-PET showed a discrete left-predominant temporal hypometabolism (Figure 2D). Notably, EMG excluded motor neuron involvement. CSF biomarkers were not in favor of AD.

During disease evolution his communication skills further worsened, mainly because of increasing anomia. Evaluation at 3 years from onset evidenced markedly impaired naming (Boston naming test: 9/34, <1st percentile) and semantics skills (PPTT, verbal version: 36/52). His motor speech difficulties remained quite stable. The other cognitive domains did not get significantly worse, with except for initial ideo-motor apraxia for intransitive limb gestures. His motor testing was persistently normal. His mother was affected by ALS, one sibling had bvFTD and another had both FTD and ALS.

3.2. Characteristics of PPA-*C9orf72* patients in this study and the literature

The most prevalent PPA variant among *C9orf72* patients was nfvPPA in our series (5/11, 45%), and even more so when considering the overall dataset including this series and previously reported cases diagnosed as “PNFA” (9/16, 56%) (Table 1).

Notably, the defining feature was apraxia of speech in 80% of our nfvPPA cases, isolated agrammatism being present in only one patient. The other main features were slowed, hypofluent speech (4/5), impairment in naming (4/5), and difficulties in comprehension of (mainly complex) sentences (4/5); evidence of clear phonological disruption was seldom present (1/5). These characteristics were also common in PNFA cases from the literature, with the only remarkable exception of agrammatism prevailing over apraxia of speech among the core clinical features.

All reported svPPA patients (2/11 in our series, 18%; 3/16 in the overall dataset, 19%) had fluent, logorrheic speech, with massive impairment in naming and in comprehension in conversational speech. The two svPPA we reported had the longest disease course (10 years at last follow-up in both cases). Behavioral changes reminiscent of anterior temporal disruption (ritualistic, stereotyped or compulsive behaviors, loss of mental flexibility) appeared during disease course. Earlier and more severe frontal behavioral impairments were described in the previously reported svPPA patient (Cerami et al., 2013).

The two mixed PPA-*C9orf72* patients (#05 and #06) showed a similar profile, with grammar-syntactical deficits and reduced fluency prevailing during the first year of the disease (apraxia of speech was clearly present in #06), associated with moderate verbal and visual semantic deficits at onset (comprehension and object-knowledge difficulties). The syndromic progression followed a similar time-course in both patients, semantic deficit becoming predominant after three years from onset.

Lastly, the linguistic profile of the two patients diagnosed as uPPA included word-finding difficulties and impairment in the comprehension of syntactically complex sentences, without frank agrammatism, motor speech disturbances, repetition impairment, phonological or semantic disruption. They showed discrete asymmetric, left-predominant frontotemporal atrophy, peaking in the perisylvian areas (Supplementary

Figure 1). Both developed mutism relatively quickly after the diagnosis. Notably, no patients from our cohort showed a linguistic profile compatible with lvPPA.

Overall, the majority of PPA-*C9orf72* patients eventually displayed at least a moderate degree of impairment in executive functions during follow-up (12/16, 75%), whereas clinically relevant behavioral troubles were reported in 6/16 cases (38%). In three patients (2 nfvPPA and 1 svPPA) the final diagnosis was PPA associated with bvFTD.

Concerning the intercurrent motor features, only one patient from the overall series (#03) developed (bulbar-onset) ALS, between 1 and 2 years from the onset of linguistic deficits. Atypical parkinsonism was more frequent during the disease course (6/16, 38%).

3.3. Grey matter atrophy profile in PPA-*C9orf72* patients

VBM analysis in the svPPA-*C9orf72* patient (#01) initially showed isolated left superior temporal pole atrophy at age 43, 4 years after disease onset. At 47 years, 7 years from disease onset, there was progression of left anterior temporal lobe atrophy, along with right temporo-polar and orbitofrontal involvement (Supplementary Figure 2, Supplementary Table 2).

VBM study in nfvPPA-*C9orf72* patients compared with controls displayed a cluster of significant frontal atrophy in the left frontal lobe, peaking at the level of inferior and middle frontal gyri (Supplementary Figure 3, Supplementary Table 3).

4. DISCUSSION

A first contribution of the present study is the definition of a remarkably low frequency of PPA with *C9orf72* expansions, representing only 3% of carriers. This frequency is fairly concordant with those estimated in the largest cohorts of *C9orf72* carriers, PPA being the presenting phenotype in only 1-3% of *C9orf72* carriers (Majounie et al., 2012; Le Ber et al., 2013; Moore et al., 2020) (Table 2). On the other hand, the prevalence of *C9orf72* repeat expansion in cohorts of PPA patients ranges from 1% to 8% (Table

2), with the remarkable exception of small Finnish cohorts where it reaches ~28% (Kaivorinne et al., 2013; Haapanen et al., 2020). This finding, stemming from observations conducted on a limited number of PPA patients (<30 cases), is possibly related to the founder effect and high prevalence of *C9orf72* repeat expansion in Finland, making it a very relevant genetic cause of FTD in this country (Majounie et al., 2012; Haapanen et al., 2020). Aside from that, due to the rarity of PPA-*C9orf72* patients, only single cases or small series have been described in detail (Hsiung et al., 2012; Snowden et al., 2012; Cerami et al., 2013), and comprehensive characterization of their linguistic and cognitive profiles is currently lacking. Our study describes the linguistic features and the neuroimaging profiles of a series of 16 PPA-*C9orf72* patients, including cases issued from French and Finnish cohorts, and five additional individuals described in detail in the literature.

In this cohort, 56% (9/16) of PPA-*C9orf72* patients presented the nfvPPA phenotype, before svPPA (3/16, 19%), mPPA (2/16, 12.5%) and uPPA (2/16, 12.5%). Interestingly, the most prominent linguistic feature in the majority of nfvPPA-*C9orf72* cases was apraxia of speech, whereas patients in our series less frequently presented with progressive agrammatic aphasia. Prior neuroimaging studies in nfvPPA patients supported the duality of its clinical presentation. Apraxia of speech is associated with bilateral, left-predominant superior frontal atrophy, including premotor and supplementary motor areas, while agrammatic PPA with more widespread prefrontal involvement, extending to middle and inferior frontal gyri, clearly lateralized on the left (Botha et al., 2015; Cordella et al., 2019; Tetzloff et al., 2019). These phenotypes are not unexpected in *C9orf72* carriers, in which prefrontal atrophy has been reported long before symptom onset (Rohrer et al., 2015; Lee et al., 2017; Bertrand et al., 2018; Le Blanc et al., 2020; Bocchetta et al., 2021). A selective lesion tropism predominating on the left side, mainly centered on inferior frontal gyrus and/or fronto-opercular cortices may potentially drive the clinical presentation to nfvPPA in some patients, as observed in our cohort. From the neuropathological point of view, apraxia of speech and, more largely, nfvPPA are usually associated with tau protein deposition when occurring sporadically (Bergeron et al., 2018). The presence of the *C9orf72* expansion thus qualifies as one of the causes of nfvPPA with

underlying frontotemporal lobar degeneration (FTLD) with TAR DNA-binding protein of 43 kDa (FTLD-TDP) pathological substrate, as in the case of *GRN* mutations.

This study also highlights that svPPA could be a possible clinical phenotype in the *C9orf72* expansion carriers, although with lesser frequency than nvPPA. Interestingly, both the svPPA-*C9orf72* patients from our series presented with an isolated, progressive disruption of the semantic system, and both showed a particularly long disease course, with 10 years of disease duration at last follow-up. Notably, slowly progressive FTD cases could be occasionally due to *C9orf72* repeat expansions, and they reflect the major clinical heterogeneity associated with this genetic cause in terms of disease phenotype and progression (Khan et al., 2012; Suhonen et al., 2015). These patients during their disease course exhibited behavioral changes which were mainly characterized by ritualistic, compulsive and stereotyped actions with loss of mental flexibility, rather than prevailing disinhibited or apathetic conducts, consistent with bilateral anterior temporal pathology. Accordingly, the progression of atrophy seen in one case study was greater in anterior temporal lobe, with later and less relevant involvement of orbitofrontal cortex.

Additional evidence for anterior temporal lobe disruption in the *C9orf72* patients is provided by the two mPPA cases described in this study, in whom semantic disturbances took over the predominantly non-fluent/agrammatic disturbances shortly after disease onset. Similarly, semantic disturbances have been already reported in association with frontal behavioral disturbances in previous *C9orf72* cases (Snowden et al., 2012). Furthermore, the relevance of anterior temporal lobe dysfunction in the *C9orf72* expansion carriers has been recently highlighted in two patients presenting temporal-variant FTD (tv-FTD), with object recognition and language difficulties being part of the clinical picture during disease evolution (Caso et al., 2020). Altogether, besides the svPPA phenotype, the *C9orf72* expansion can trigger anterior temporal lobe degeneration, producing semantic deficits also in patients initially presenting with different linguistic variants or behavioral syndromes.

The linguistic spectrum of the *C9orf72* repeat expansion appears in striking contrast with those observed in other FTD-causing mutations. The main presentations of PPA associated with *GRN* mutations (PPA-*GRN*) are logopenic variants, followed by nfvPPA syndrome in which agrammatism clearly predominates over apraxia of speech (Moore et al., 2020; Saracino et al., 2021). Semantic deficits rarely occur in isolation, though they can add up to logopenic or agrammatic impairment in the mixed forms. Overall, sentence-level processing deficits, naming difficulties, and phonological disturbances are the main linguistic features of *GRN*-associated PPA (Rohrer et al., 2010a; Saracino et al., 2021). On the other hand, lvPPA has been exceptionally if ever reported in the *C9orf72* repeat expansion carriers (Moore et al., 2020). This phenotype requires the coexistence of word-finding difficulties and sentence repetition deficits to be diagnosed (Gorno-Tempini et al., 2011), and this latter impairment is remarkably rare in PPA-*C9orf72* (Table 1). Therefore, it is not surprising that the atrophy pattern involves quite distinct, more posterior regions within the language network in PPA-*GRN*, namely posterior temporal lobe, temporo-parietal junction and posterior frontal areas (Rohrer et al., 2010b; Whitwell et al., 2015; Saracino et al., 2021).

Less common FTD/ALS genes may also produce PPA phenotypes, and the available information stems from the description of single cases or very small series. *MAPT* mutations may produce both nfvPPA and svPPA phenotypes, in association with underlying FTLT with tau pathology (FTLT-tau) (Moore et al., 2020). However, pure svPPA cases are rather rare, whereas bvFTD associated with anomia and profound semantic deficits is a more common occurrence (Pickering-Brown et al., 2002; Henz et al., 2015; Roncero et al., 2021). *TARDBP* carriers may also display important bilateral temporal atrophy, and the corresponding linguistic phenotype is more commonly svPPA (Gelpi et al., 2014; Caroppo et al., 2016; González-Sánchez et al., 2018; Mol et al., 2021). Somatic mutations of *TARDBP* in the lateral and medial temporal cortices of patients with sporadic svPPA also highlight the role of *TARDBP* in temporal lobe pathology (van Rooij et al., 2020). Linguistic presentations associated with *TBKI* mutations are more heterogeneous and almost equally represented by nfvPPA and svPPA (Caroppo et al., 2015; Pottier et al., 2015; van der Zee et al., 2017; Hirsch-Reinshagen et al., 2019; Swift et al., 2021). Overall, these findings

suggest that the degenerative process resulting from distinct FTD gene mutations displays a differential lesional tropism in patients with PPA phenotypes. Involvement of frontal areas among the *C9orf72* carriers is quite heterogeneous in terms of lateralization and peak of atrophy, thus giving rise to different nfvPPA sub-phenotypes. The temporo-polar cortex is predominantly involved in the context of *C9orf72*, as well as *MAPT*, *TARDBP* and *TBK1* mutations, whereas it is rather atypical in the *GRN* carriers, who frequently display a quite distinct pattern involving the posterior language areas.

Anyway, the rarity of PPA-*C9orf72*, and more largely of genetic PPA, may preclude the generalizability of our findings and the resulting genotype-phenotype correlations. Moreover, the speech/language batteries we used, though allowing a homogeneous description of patients observed across a wide time span, did not undergo validation studies in the PPA population and are not based on a cognitive approach to language dysfunction, thus lacking diagnostic accuracy to capture the most subtle linguistic deficits, especially for unclassifiable and mixed cases (Ivanova and Hallowell, 2013; Macoir et al., 2021). A more exhaustive linguistic evaluation based on the most recently validated tests would represent an added value for future works in this field. Additionally, the limited number of patients available in our series (even if rather important for such a rare phenotype in a rare genetic form) may have led to statistically underpowered VBM studies. Nevertheless, cluster-level corrected VBM analyses have proven their usefulness in elucidating significant patterns of atrophy even in single subjects or small-sized groups (Khan et al., 2012; Josephs et al., 2014). Furthermore, our neuroimaging results are well concordant with the linguistic and clinical phenotypes, and closely mirror the profiles of cortical involvement seen in the native acquisitions (Supplementary Figures 2 and 3).

In spite of the abovementioned limitations, this study offers an overview on the clinical progression of a relatively large series of PPA-*C9orf72* cases. Interestingly, the frequency of patients developing ALS (6%, 1/16) was far below what it is expected in the *C9orf72* carriers, approximately half of whom presenting motor neuron dysfunction during the disease course (Majounie et al., 2012; Snowden et al., 2012; Le Ber et al., 2013). Therefore, ALS seems a less common occurrence in patients initially displaying a PPA, rather

than a bvFTD phenotype. Even if behavioral and executive disturbances were quite common during progression, the frequency of bvFTD as secondary diagnosis was indeed low, and specifically lower than what observed in a series of PPA-GRN recently reported (Saracino et al., 2021).

In conclusion, the current findings provide some important information for genetic testing in clinical practice, showing that *C9orf72* gene should be analyzed in PPA patients with nvPPA phenotype, notably when manifesting with apraxia of speech, and in those with predominant semantic impairment, especially when family history is positive for FTD/ALS. Non-amyloid lvPPA variants are not associated with the *C9orf72* expansion in our series, even if some exceptions may occur. Finally, this study comprehensively describes the linguistic spectrum in a large cohort of patients with PPA related to *C9orf72* expansion, and to refine the indications for molecular analyses in PPA patients, according to their phenotypes, with major clinical impact as targeted disease-modifying therapies are upcoming.

ACKNOWLEDGMENTS

We are grateful to the DNA and cell bank of the ICM for the technical assistance (DNA and cell bank, ICM, Pitié-Salpêtrière hospital, Paris, France). We also thank Fabienne Clot for carrying out the genetic analyses. The study was partially conducted with the support of the Centre d'Investigation Clinique Neuroscience (CIC 1422), Pitié-Salpêtrière Hospital, Paris. This work is generated within the European Reference Network for Rare Neurological Diseases - Project ID No 739510.

COMPETING INTERESTS

Disclosure of interests related to the present article: The authors declare no conflicts of interest.

Disclosure of interests unrelated to the present article: ILB served as a member of advisory boards for Prevail Therapeutic and Alector, and received research grants from ANR, DGOS, Vaincre Alzheimer Association, ARSla Association, Fondation Plan Alzheimer, JPND outside of the present work.

FUNDING

The research leading to these results received funding from the “Investissements d’avenir” ANR-11-INBS-0011, the Academy of Finland (no315460), and the University of Oulu Scholarship Foundation. This work was partially funded by the PHRC FTLD-exome (to ILB, promotion by Assistance Publique – Hôpitaux de Paris), the ANR-PRTS PREV-DEMALS project (to ILB, grant number ANR-14-CE15-0016-07, promotion by Assistance Publique – Hôpitaux de Paris), the Finnish Brain Foundation (to ES), the Orion Research Foundation (to ES), the Instrumentarium Science Foundation (to ES), and the Sigrid Jusélius Foundation (to ES). The funding source had no role in study design, data analysis or interpretation, writing or decision to submit the report for publication.

REFERENCES

- Benussi, L., Rossi, G., Glionna, M., Tonoli, E., Piccoli, E., Fostinelli, S., Paterlini, A., Flocco, R., Albani, D., Pantieri, R., Cereda, C., Forloni, G., Tagliavini, F., Binetti, G., Ghidoni, R., 2014. C9ORF72 Hexanucleotide Repeat Number in Frontotemporal Lobar Degeneration: A Genotype-Phenotype Correlation Study. *J Alzheimers Dis* 38, 799–808. <https://doi.org/10.3233/JAD-131028>
- Bergeron, D., Gorno-Tempini, M.L., Rabinovici, G.D., Santos-Santos, M.A., Seeley, W., Miller, B.L., Pijnenburg, Y., Keulen, M.A., Groot, C., van Berckel, B.N.M., van der Flier, W.M., Scheltens, P., Rohrer, J.D., Warren, J.D., Schott, J.M., Fox, N.C., Sanchez-Valle, R., Grau-Rivera, O., Gelpi, E., Seelaar, H., Papma, J.M., van Swieten, J.C., Hodges, J.R., Leyton, C.E., Piguet, O., Rogalski, E.J., Mesulam, M.M., Koric, L., Nora, K., Pariente, J., Dickerson, B., Mackenzie, I.R., Hsiung, G.-Y.R., Belliard, S., Irwin, D.J., Wolk, D.A., Grossman, M., Jones, M., Harris, J., Mann, D., Snowden, J.S., Chrem-Mendez, P., Calandri, I.L., Amengual, A.A., Miguët-Alfonsi, C., Magnin, E., Magnani, G., Santangelo, R., Deramecourt, V., Pasquier, F., Mattsson, N., Nilsson, C., Hansson, O., Keith, J., Masellis, M., Black, S.E., Matías-Guiu, J.A., Cabrera-Martin, M.-N., Paquet, C., Dumurgier, J., Teichmann, M., Sarazin, M., Bottlaender, M., Dubois, B., Rowe, C.C., Villemagne, V.L., Vandenberghe, R., Granadillo, E., Teng, E., Mendez, M., Meyer, P.T., Frings, L., Lleó, A., Blesa, R., Fortea, J., Seo, S.W., Diehl-Schmid, J., Grimmer, T., Frederiksen, K.S., Sánchez-Juan, P., Chételat, G., Jansen, W., Bouchard, R.W., Laforce, R.Jr., Visser, P.J., Ossenkoppele, R., 2018. Prevalence of amyloid- β pathology in distinct variants of primary progressive aphasia. *Annals of Neurology* 84, 729–740. <https://doi.org/10.1002/ana.25333>
- Bertrand, A., Wen, J., Rinaldi, D., Houot, M., Sayah, S., Camuzat, A., Fournier, C., Fontanella, S., Routier, A., Couratier, P., Pasquier, F., Habert, M.-O., Hannequin, D., Martinaud, O., Caroppo, P., Levy, R., Dubois, B., Brice, A., Durrleman, S., Colliot, O., Le Ber, I., for the Predict to Prevent Frontotemporal Lobar Degeneration and Amyotrophic Lateral Sclerosis (PREV-DEMALS) Study Group, 2018. Early Cognitive, Structural, and Microstructural Changes in Presymptomatic C9orf72 Carriers Younger Than 40 Years. *JAMA Neurol* 75, 236. <https://doi.org/10.1001/jamaneurol.2017.4266>
- Bocchetta, M., Gordon, E., Cardoso, M.J., Modat, M., Ourselin, S., Warren, J.D., Rohrer, J.D., 2018. Thalamic atrophy in frontotemporal dementia — Not just a C9orf72 problem. *NeuroImage: Clinical* 18, 675–681. <https://doi.org/10.1016/j.nicl.2018.02.019>
- Bocchetta, M., Todd, E.G., Peakman, G., Cash, D.M., Convery, R.S., Russell, L.L., Thomas, D.L., Iglesias, J.E., van Swieten, J.C., Jiskoot, L.C., Seelaar, H., Borroni, B., Galimberti, D., Sanchez-Valle, R., Laforce Jr, R., Moreno, F., Synofzik, M., Graff, C., Masellis, M., Tartaglia, M.C., Rowe, J.B., Vandenberghe, R., Finger, E., Tagliavini, F., de Mendonça, A., Santana, I., Butler, C.R., Ducharme, S., Gerhard, A., Danek, A., Levin, J., Otto, M., Sorbi, S., Le Ber, I., Pasquier, F., Rohrer, J.D., Afonso, S., Rosario Almeida, M., Anderl-Straub, S., Andersson, C., Antonell, A., Archetti, S., Arighi, A., Balasa, M., Barandiaran, M., Bargalló, N., Bartha, R., Bender, B., Benussi, A., Bertoux, M., Bertrand, A., Bessi, V., Black, S., Borrego-Ecija, S., Bras, J., Brice, A., Bruffaerts, R., Camuzat, A., Cañada, M., Cantoni, V., Caroppo, P., Castelo-Branco, M., Colliot, O., Cope, T., Deramecourt, V., de Arriba, M., Di Fede, G., Díez, A., Duro, D., Fenoglio, C., Ferrari, C., Ferreira, C.B., Fox, N., Freedman, M., Fumagalli, G., Funkiewiez, A., Gabilondo, A., Gasparotti, R., Gauthier, S., Gazzina, S., Giaccone, G., Gorostidi, A., Greaves, C., Guerreiro, R., Heller, C., Hoegen, T., Indakoetxea, B., Jelic, V., Karnath, H.-O., Keren, R., Kuchcinski, G., Langheinrich, T., Lebouvier, T., João Leitão, M., Lladó, A., Lombardi, G., Loosli, S., Maruta, C., Mead, S., Meeter, L., Miltenberger, G., van Minkelen, R., Mitchell, S., Moore, K., Nacmias, B., Nelson, A., Nicholas, J., Öijerstedt, L., Olives, J., Ourselin, S., Padovani, A., Panman, J., Papma, J.M., Pijnenburg, Y., Polito, C., Premi, E., Prioni, S., Prix, C., Rademakers, R., Redaelli, V., Rinaldi, D., Rittman, T., Rogaeva, E., Rollin, A., Rosa-Neto, P., Rossi, G., Rossor, M., Santiago, B., Saracino, D., Sayah, S., Scarpini, E., Schönecker, S., Semler, E., Shafei, R., Shoesmith, C., Swift, I., Tábuas-Pereira, M., Tainta, M., Taipa, R., Tang-Wai, D., Thompson, P., Thonberg, H., Timberlake, C., Tiraboschi, P., Van Damme, P., Vandenbulcke, M.,

Veldsman, M., Verdelho, A., Villanua, J., Warren, J., Wilke, C., Woollacott, I., Wlasich, E., Zetterberg, H., Zulaica, M., 2021. Differential early subcortical involvement in genetic FTD within the GENFI cohort. *Neuroimage Clin* 30, 102646. <https://doi.org/10.1016/j.nicl.2021.102646>

Boeve, B.F., Boylan, K.B., Graff-Radford, N.R., DeJesus-Hernandez, M., Knopman, D.S., Pedraza, O., Vemuri, P., Jones, D., Lowe, V., Murray, M.E., Dickson, D.W., Josephs, K.A., Rush, B.K., Machulda, M.M., Fields, J.A., Ferman, T.J., Baker, M., Rutherford, N.J., Adamson, J., Wszolek, Z.K., Adeli, A., Savica, R., Boot, B., Kuntz, K.M., Gavrilo, R., Reeves, A., Whitwell, J., Kantarci, K., Jack, C.R., Parisi, J.E., Lucas, J.A., Petersen, R.C., Rademakers, R., 2012. Characterization of frontotemporal dementia and/or amyotrophic lateral sclerosis associated with the GGGGCC repeat expansion in C9ORF72. *Brain* 135, 765–783. <https://doi.org/10.1093/brain/aws004>

Botha, H., Duffy, J.R., Whitwell, J.L., Strand, E.A., Machulda, M.M., Schwarz, C.G., Reid, R.I., Sychalla, A.J., Senjem, M.L., Jones, D.T., Lowe, V., Jack, C.R., Josephs, K.A., 2015. Classification and clinicoradiologic features of primary progressive aphasia (PPA) and apraxia of speech. *Cortex* 69, 220–236. <https://doi.org/10.1016/j.cortex.2015.05.013>

Cajanus, A., Katisko, K., Kontkanen, A., Ja, O., Haapasalo, A., Herukka, S.-K., Vanninen, R., Solje, E., Hall, A., Remes, A.M., 2020. Serum neurofilament light chain in FTLD: association with C9orf72, clinical phenotype, and prognosis. *Ann Clin Transl Neurol* 7, 903–910. <https://doi.org/10.1002/acn3.51041>

Caroppo, P., Camuzat, A., De Septenville, A., Couratier, P., Lacomblez, L., Auriacombe, S., Flabeau, O., Jornéa, L., Blanc, F., Sellal, F., Cretin, B., Meininger, V., Fleury, M.-C., Couarch, P., Dubois, B., Brice, A., Le Ber, I., 2015. Semantic and nonfluent aphasic variants, secondarily associated with amyotrophic lateral sclerosis, are predominant frontotemporal lobar degeneration phenotypes in TBK1 carriers. *Alzheimer's & Dementia: Diagnosis, Assessment & Disease Monitoring* 1, 481–486. <https://doi.org/10.1016/j.dadm.2015.10.002>

Caroppo, P., Camuzat, A., Guillot-Noel, L., Thomas-Antérion, C., Couratier, P., Wong, T.H., Teichmann, M., Golfier, V., Auriacombe, S., Belliard, S., Laurent, B., Lattante, S., Millecamps, S., Clot, F., Dubois, B., van Swieten, J.C., Brice, A., Le Ber, I., 2016. Defining the spectrum of frontotemporal dementias associated with TARDBP mutations. *Neurology Genetics* 2, e80. <https://doi.org/10.1212/NXG.0000000000000080>

Caso, F., Agosta, F., Magnani, G., Cardamone, R., Borghesani, V., Miller, Z., Riva, N., La Joie, R., Coppola, G., Grinberg, L.T., Seeley, W.W., Miller, B.L., Gorno-Tempini, M.L., Filippi, M., 2020. Temporal variant of frontotemporal dementia in C9orf72 repeat expansion carriers: two case studies. *Brain Imaging Behav* 14, 336–345. <https://doi.org/10.1007/s11682-019-00253-x>

Cerami, C., Marcone, A., Galimberti, D., Zamboni, M., Fenoglio, C., Serpente, M., Scarpini, E., Cappa, S.F., 2013. Novel Evidence of Phenotypical Variability in the Hexanucleotide Repeat Expansion in Chromosome 9. *J Alzheimers Dis* 35, 455–462. <https://doi.org/10.3233/JAD-122302>

Cordella, C., Quimby, M., Touroutoglou, A., Brickhouse, M., Dickerson, B.C., Green, J.R., 2019. Quantification of motor speech impairment and its anatomic basis in primary progressive aphasia. *Neurology* 92, e1992–e2004. <https://doi.org/10.1212/WNL.00000000000007367>

Costa, B., Manzoni, C., Bernal-Quiros, M., Kia, D.A., Aguilar, M., Alvarez, I., Alvarez, V., Andreassen, O., Anfossi, M., Bagnoli, S., Benussi, L., Bernardi, L., Binetti, G., Blackburn, D., Boada, M., Borroni, B., Bowns, L., Bräthen, G., Bruni, A.C., Chiang, H.-H., Clarimon, J., Colville, S., Conidi, M.E., Cope, T.E., Cruchaga, C., Cupidi, C., Di Battista, M.E., Diehl-Schmid, J., Diez-Fairen, M., Dols-Icardo, O., Durante, E., Flisar, D., Frangipane, F., Galimberti, D., Gallo, M., Gallucci, M., Ghidoni, R., Graff, C., Grafman, J.H., Grossman, M., Hardy, J., Hernández, I., Holloway, G.J.T., Huey, E.D., Illán-Gala, I., Karydas, A., Khoshnood, B., Kramberger, M.G., Kristiansen, M., Lewis, P.A., Lleó, A., Madhan, G.K., Maletta, R., Maver, A., Menendez-Gonzalez, M., Milan, G., Miller, B., Mol, M.O., Momeni, P.,

Moreno-Grau, S., Morris, C.M., Nacmias, B., Nilsson, C., Novelli, V., Öijerstedt, L., Padovani, A., Pal, S., Panchbhaya, Y., Pastor, P., Peterlin, B., Piaceri, I., Pickering-Brown, S., Pijnenburg, Y.A.L., Puca, A.A., Rainero, I., Rendina, A., Richardson, A.M.T., Rogaeva, E., Rogelj, B., Rollinson, S., Rossi, G., Rossmeier, C., Rowe, J.B., Rubino, E., Ruiz, A., Sanchez-Valle, R., Sando, S.B., Santillo, A.F., Saxon, J., Scarpini, E., Serpente, M., Smirne, N., Sorbi, S., Suh, E., Tagliavini, F., Thompson, J.C., Trojanowski, J.Q., Van Deerlin, V.M., Van der Zee, J., Van Broeckhoven, C., van Rooij, J., Van Swieten, J.C., Veronesi, A., Vitale, E., Waldö, M.L., Woodward, C., Yokoyama, J., Escott-Price, V., Polke, J.M., Ferrari, R., for the International FTD-Genetics Consortium, 2020. C9orf72, age at onset, and ancestry help discriminate behavioral from language variants in FTLD cohorts. *Neurology* 95, e3288–e3302. <https://doi.org/10.1212/WNL.0000000000010914>

Deloche, G., Hannequin, D., 1997. DO 80: Epreuve de dénomination orale d'image. ECPA (Editions du Centre de Psychologie Appliquée), Paris.

Flanagan, E.P., Baker, M.C., Perkerson, R.B., Duffy, J.R., Strand, E.A., Whitwell, J.L., Machulda, M.M., Rademakers, R., Josephs, K.A., 2015. Dominant Frontotemporal Dementia Mutations in 140 Cases of Primary Progressive Aphasia and Speech Apraxia. *Dementia and Geriatric Cognitive Disorders* 39, 281–286. <https://doi.org/10.1159/000375299>

Fletcher, P.D., Downey, L.E., Golden, H.L., Clark, C.N., Slattery, C.F., Paterson, R.W., Rohrer, J.D., Schott, J.M., Rossor, M.N., Warren, J.D., 2015a. Pain and temperature processing in dementia: a clinical and neuroanatomical analysis. *Brain* 138, 3360–3372. <https://doi.org/10.1093/brain/awv276>

Fletcher, P.D., Downey, L.E., Golden, H.L., Clark, C.N., Slattery, C.F., Paterson, R.W., Schott, J.M., Rohrer, J.D., Rossor, M.N., Warren, J.D., 2015b. Auditory hedonic phenotypes in dementia: A behavioural and neuroanatomical analysis. *Cortex* 67, 95–105. <https://doi.org/10.1016/j.cortex.2015.03.021>

Galimberti, D., Fenoglio, C., Serpente, M., Villa, C., Bonsi, R., Arighi, A., Fumagalli, G.G., Del Bo, R., Bruni, A.C., Anfossi, M., Clodomiro, A., Cupidi, C., Nacmias, B., Sorbi, S., Piaceri, I., Bagnoli, S., Bessi, V., Marcone, A., Cerami, C., Cappa, S.F., Filippi, M., Agosta, F., Magnani, G., Comi, G., Franceschi, M., Rainero, I., Giordana, M.T., Rubino, E., Ferrero, P., Rogaeva, E., Xi, Z., Confaloni, A., Piscopo, P., Bruno, G., Talarico, G., Cagnin, A., Clerici, F., Dell'Osso, B., Comi, G.P., Altamura, A.C., Mariani, C., Scarpini, E., 2013. Autosomal Dominant Frontotemporal Lobar Degeneration Due to the C9ORF72 Hexanucleotide Repeat Expansion: Late-Onset Psychotic Clinical Presentation. *Biol Psychiatry* 74, 384–391. <https://doi.org/10.1016/j.biopsych.2013.01.031>

Gelpi, E., van der Zee, J., Turon Estrada, A., Van Broeckhoven, C., Sanchez-Valle, R., 2014. TARDBP mutation p.Ile383Val associated with semantic dementia and complex proteinopathy. *Neuropathol Appl Neurobiol* 40, 225–230. <https://doi.org/10.1111/nan.12063>

Gil-Navarro, S., Lladó, A., Rami, L., Castellví, M., Bosch, B., Bargalló, N., Lomeña, F., Reñé, R., Montagut, N., Antonell, A., Molinuevo, J.L., Sánchez-Valle, R., 2013. Neuroimaging and Biochemical Markers in the Three Variants of Primary Progressive Aphasia. *Dementia and Geriatric Cognitive Disorders* 35, 106–117. <https://doi.org/10.1159/000346289>

Godefroy, O., GREFEX, 2008. Fonctions exécutives et pathologies neurologiques et psychiatriques. Evaluation en pratique clinique. Solal, Marseille.

González-Sánchez, M., Puertas-Martín, V., Esteban-Pérez, J., García-Redondo, A., Borrego-Hernández, D., Méndez-Guerrero, A., Llamas-Velasco, S., Herrero-San Martín, A., Cordero-Vázquez, P., Herrero-Manso, M.C., Pérez-Martínez, D.A., Villarejo-Galende, A., 2018. TARDBP mutation associated with semantic variant primary progressive aphasia, case report and review of the literature. *Neurocase* 24, 301–305. <https://doi.org/10.1080/13554794.2019.1581225>

- Gorno-Tempini, M.L., Hillis, A.E., Weintraub, S., Kertesz, A., Mendez, M., Cappa, S.F., Ogar, J.M., Rohrer, J.D., Black, S., Boeve, B.F., Manes, F., Dronkers, N.F., Vandenberghe, R., Rascovsky, K., Patterson, K., Miller, B.L., Knopman, D.S., Hodges, J.R., Mesulam, M.M., Grossman, M., 2011. Classification of primary progressive aphasia and its variants. *Neurology* 76, 1006–1014. <https://doi.org/10.1212/WNL.0b013e31821103e6>
- Haapanen, M., Katisko, K., Hänninen, T., Krüger, J., Hartikainen, P., Haapasalo, A., Remes, A.M., Solje, E., 2020. C9orf72 Repeat Expansion Does Not Affect the Phenotype in Primary Progressive Aphasia. *J Alzheimers Dis* 78, 919–925. <https://doi.org/10.3233/JAD-200795>
- Hardy, C.J.D., Buckley, A.H., Downey, L.E., Lehmann, M., Zimmerer, V.C., Varley, R.A., Crutch, S.J., Rohrer, J.D., Warrington, E.K., Warren, J.D., 2016. The Language Profile of Behavioral Variant Frontotemporal Dementia. *J Alzheimers Dis* 50, 359–371. <https://doi.org/10.3233/JAD-150806>
- Henz, S., Ackl, N., Knels, C., Rominger, A., Flatz, W., Teipel, S., Huppertz, H., Roeber, S., Neumann, M., Danek, A., 2015. A Pair of Siblings with a rare R5H-Mutation in Exon 1 of the MAPT-Gene. *Fortschr Neurol Psychiatr* 83, 397–401. <https://doi.org/10.1055/s-0035-1553236>
- Hirsch-Reinshagen, V., Alfaify, O.A., Hsiung, G.-Y.R., Pottier, C., Baker, M., Perkerson, R.B., Rademakers, R., Briemberg, H., Foti, D.J., Mackenzie, I.R., 2019. Clinicopathologic correlations in a family with a TBK1 mutation presenting as primary progressive aphasia and primary lateral sclerosis. *Amyotrophic Lateral Sclerosis and Frontotemporal Degeneration* 20, 568–575. <https://doi.org/10.1080/21678421.2019.1632347>
- Howard, D., Patterson, K., 1992. The pyramids and palm trees test: a test of semantic access from words and pictures. Thames Valley Test Company, Bury St Edmunds.
- Hsiung, G.-Y.R., DeJesus-Hernandez, M., Feldman, H.H., Sengdy, P., Bouchard-Kerr, P., Dwosh, E., Butler, R., Leung, B., Fok, A., Rutherford, N.J., Baker, M., Rademakers, R., Mackenzie, I.R.A., 2012. Clinical and pathological features of familial frontotemporal dementia caused by C9ORF72 mutation on chromosome 9p. *Brain* 135, 709–722. <https://doi.org/10.1093/brain/awr354>
- Irwin, D.J., McMillan, C.T., Brettschneider, J., Libon, D.J., Powers, J., Rascovsky, K., Toledo, J.B., Boller, A., Bekisz, J., Chandrasekaran, K., Wood, E.M., Shaw, L.M., Woo, J.H., Cook, P.A., Wolk, D.A., Arnold, S.E., Van Deerlin, V.M., McCluskey, L.F., Elman, L., Lee, V.M.-Y., Trojanowski, J.Q., Grossman, M., 2013. Cognitive decline and reduced survival in C9orf72 expansion frontotemporal degeneration and amyotrophic lateral sclerosis. *J Neurol Neurosurg Psychiatry* 84, 163–169. <https://doi.org/10.1136/jnnp-2012-303507>
- Ivanova, M.V., Hallowell, B., 2013. A tutorial on aphasia test development in any language: Key substantive and psychometric considerations. *Aphasiology* 27, 891–920. <https://doi.org/10.1080/02687038.2013.805728>
- Josephs, K.A., Duffy, J.R., Strand, E.A., Machulda, M.M., Vemuri, P., Senjem, M.L., Perkerson, R.B., Baker, M.C., Lowe, V., Jack, C.R., Rademakers, R., Whitwell, J.L., 2014. Progranulin-associated PiB-negative logopenic primary progressive aphasia. *Journal of Neurology* 261, 604–614. <https://doi.org/10.1007/s00415-014-7243-9>
- Kaivorinne, A.-L., Bode, M.K., Paavola, L., Tuominen, H., Kallio, M., Renton, A.E., Traynor, B.J., Moilanen, V., Remes, A.M., 2013. Clinical Characteristics of C9ORF72-Linked Frontotemporal Lobar Degeneration. *Dement Geriatr Cogn Disord Extra* 3, 251–262. <https://doi.org/10.1159/000351859>
- Khan, B.K., Yokoyama, J.S., Takada, L.T., Sha, S.J., Rutherford, N.J., Fong, J.C., Karydas, A.M., Wu, T., Ketelle, R.S., Baker, M.C., Hernandez, M.-D., Coppola, G., Geschwind, D.H., Rademakers, R., Lee, S.E., Rosen, H.J., Rabinovici, G.D., Seeley, W.W., Rankin, K.P., Boxer, A.L., Miller, B.L., 2012. Atypical, slowly progressive behavioural variant frontotemporal dementia associated with C9ORF72 hexanucleotide expansion. *J Neurol Neurosurg Psychiatry* 83, 358–

364. <https://doi.org/10.1136/jnnp-2011-301883>

Le Ber, Guedj, E., Verpillat, P., Volteau, M., Thomas-Anterion, C., Decousus, M., Hannequin, D., Vera, P., Lacomblez, L., Camuzat, A., Didic, M., Puel, M., Lotterie, J.-A., Golfier, V., Bernard, A.-M., Vercelletto, M., Magne, C., Sellal, F., Namer, I., Michel, B.-F., Pasquier, J., Salachas, F., Bochet, J., Brice, A., Habert, M.-O., Dubois, B., 2006.

Demographic, neurological and behavioural characteristics and brain perfusion SPECT in frontal variant of frontotemporal dementia. *Brain* 129, 3051–3065. <https://doi.org/10.1093/brain/awl288>

Le Ber, Guillot-Noel, L., Hannequin, D., Lacomblez, L., Golfier, V., Puel, M., Martinaud, O., Deramecourt, V., Rivaud-Pechoux, S., Millecamps, S., Vercelletto, M., Couratier, P., Sellal, F., Pasquier, F., Salachas, F., Thomas-Anterion, C., Didic, M., Pariente, J., Seilhean, D., Ruberg, M., Wargon, I., Blanc, F., Camu, W., Michel, B.-F., Berger, E., Sauvée, M., Thauvin-Robinet, C., Mondon, K., Tournier-Lasserre, E., Goizet, C., Fleury, M., Viennet, G., Verpillat, P., Meininger, V., Duyckaerts, C., Dubois, B., Brice, A., The French research network on FTL/FTLD-ALS, 2013. C9ORF72 Repeat Expansions in the Frontotemporal Dementias Spectrum of Diseases: A Flow-chart for Genetic Testing. *JAD* 34, 485–499. <https://doi.org/10.3233/JAD-121456>

Le Ber, I., Camuzat, A., Hannequin, D., Pasquier, F., Guedj, E., Rovelet-Lecrux, A., Hahn-Barma, V., van der Zee, J., Clot, F., Bakchine, S., Puel, M., Ghanim, M., Lacomblez, L., Mikol, J., Deramecourt, V., Lejeune, P., de la Sayette, V., Belliard, S., Vercelletto, M., Meyrignac, C., Van Broeckhoven, C., Lambert, J.-C., Verpillat, P., Campion, D., Habert, M.-O., Dubois, B., Brice, A., 2008. Phenotype variability in progranulin mutation carriers: a clinical, neuropsychological, imaging and genetic study. *Brain* 131, 732–746. <https://doi.org/10.1093/brain/awn012>

Le Blanc, G., Jetté Pomerleau, V., McCarthy, J., Borroni, B., van Swieten, J., Galimberti, D., Sanchez-Valle, R., LaForce, R., Moreno, F., Synofzik, M., Graff, C., Masellis, M., Tartaglia, M.C., Rowe, J.B., Vandenberghe, R., Finger, E., Tagliavini, F., Mendonça, A., Santana, I., Butler, C., Gerhard, A., Danek, A., Levin, J., Otto, M., Frisoni, G., Sorbi, S., Rohrer, J.D., Ducharme, S., the Genetic Frontotemporal Dementia Initiative (GENFI), 2020. Faster Cortical Thinning and Surface Area Loss in Presymptomatic and Symptomatic C9orf72 Repeat Expansion Adult Carriers. *Ann Neurol* 88, 113–122. <https://doi.org/10.1002/ana.25748>

Lee, S.E., Sias, A.C., Mandelli, M.L., Brown, J.A., Brown, A.B., Khazenzon, A.M., Vidovszky, A.A., Zanto, T.P., Karydas, A.M., Pribadi, M., Dokuru, D., Coppola, G., Geschwind, D.H., Rademakers, R., Gorno-Tempini, M.L., Rosen, H.J., Miller, B.L., Seeley, W.W., 2017. Network degeneration and dysfunction in presymptomatic C9ORF72 expansion carriers. *Neuroimage Clin* 14, 286–297. <https://doi.org/10.1016/j.nicl.2016.12.006>

Macoir, J., Légaré, A., Lavoie, M., 2021. Contribution of the Cognitive Approach to Language Assessment to the Differential Diagnosis of Primary Progressive Aphasia. *Brain Sciences* 11, 815. <https://doi.org/10.3390/brainsci11060815>

Mahoney, C.J., Beck, J., Rohrer, J.D., Lashley, T., Mok, K., Shakespeare, T., Yeatman, T., Warrington, E.K., Schott, J.M., Fox, N.C., Rossor, M.N., Hardy, J., Collinge, J., Revesz, T., Mead, S., Warren, J.D., 2012. Frontotemporal dementia with the C9ORF72 hexanucleotide repeat expansion: clinical, neuroanatomical and neuropathological features. *Brain* 135, 736–750. <https://doi.org/10.1093/brain/awr361>

Majounie, E., Renton, A.E., Mok, K., Dopper, E.G., Waite, A., Rollinson, S., Chiò, A., Restagno, G., Nicolaou, N., Simon-Sanchez, J., van Swieten, J.C., Abramzon, Y., Johnson, J.O., Sendtner, M., Pamphlett, R., Orrell, R.W., Mead, S., Sidle, K.C., Houlden, H., Rohrer, J.D., Morrison, K.E., Pall, H., Talbot, K., Ansorge, O., Hernandez, D.G., Arepalli, S., Sabatelli, M., Mora, G., Corbo, M., Giannini, F., Calvo, A., Englund, E., Borghero, G., Floris, G.L., Remes, A.M., Laaksovirta, H., McCluskey, L., Trojanowski, J.Q., Van Deerlin, V.M., Schellenberg, G.D., Nalls, M.A., Drory, V.E., Lu, C.-S., Yeh, T.-H., Ishiura, H., Takahashi, Y., Tsuji, S., Le Ber, I., Brice, A., Drepper, C., Williams, N., Kirby, J., Shaw, P., Hardy, J., Tienari, P.J., Heutink, P., Morris, H.R., Pickering-Brown, S., Traynor, B.J., 2012. Frequency of the

C9orf72 hexanucleotide repeat expansion in patients with amyotrophic lateral sclerosis and frontotemporal dementia: a cross-sectional study. *The Lancet Neurology* 11, 323–330. [https://doi.org/10.1016/S1474-4422\(12\)70043-1](https://doi.org/10.1016/S1474-4422(12)70043-1)

Mazaux, J., Orgogozo, J., 1982. HDAE (BDAE): Echelle d'évaluation de l'aphasie. ECPA (Editions du Centre de Psychologie Appliquée), Paris.

Merck, C., Charnallet, A., Auriacombe, S., Belliard, S., Hahn-Barma, V., Kremin, H., Lemesle, B., Mahieux, F., Moreaud, O., Palisson, D.P., Roussel, M., Sellal, F., Siegwart, H., 2011. La batterie d'évaluation des connaissances sémantiques du GRECO (BECS-GRECO) : validation et données normatives. *Revue de neuropsychologie* 3, 235. <https://doi.org/10.3917/rne.034.0235>

Mol, M.O., Nijmeijer, S.W.R., van Rooij, J.G.J., van Spaendonk, R.M.L., Pijnenburg, Y.A.L., van der Lee, S.J., van Minkelen, R., Donker Kaat, L., Rozemuller, A.J.M., Janse van Mantgem, M.R., van Rheeën, W., van Es, M.A., Veldink, J.H., Hennekam, F.A.M., Vernooij, M., van Swieten, J.C., Cohn-Hokke, P.E., Seelaar, H., Dopper, E.G.P., 2021. Distinctive pattern of temporal atrophy in patients with frontotemporal dementia and the I383V variant in TARDBP. *J Neurol Neurosurg Psychiatry* jnnp-2020-325150. <https://doi.org/10.1136/jnnp-2020-325150>

Moore, K.M., Nicholas, J., Grossman, M., McMillan, C.T., Irwin, D.J., Massimo, L., Van Deerlin, V.M., Warren, J.D., Fox, N.C., Rossor, M.N., Mead, S., Bocchetta, M., Boeve, B.F., Knopman, D.S., Graff-Radford, N.R., Forsberg, L.K., Rademakers, R., Wszolek, Z.K., van Swieten, J.C., Jiskoot, L.C., Meeter, L.H., Dopper, E.G., Papma, J.M., Snowden, J.S., Saxon, J., Jones, M., Pickering-Brown, S., Le Ber, I., Camuzat, A., Brice, A., Caroppo, P., Ghidoni, R., Pievani, M., Benussi, L., Binetti, G., Dickerson, B.C., Lucente, D., Krivensky, S., Graff, C., Öijerstedt, L., Fallström, M., Thonberg, H., Ghoshal, N., Morris, J.C., Borroni, B., Benussi, A., Padovani, A., Galimberti, D., Scarpini, E., Fumagalli, G.G., Mackenzie, I.R., Hsiung, G.-Y.R., Sengdy, P., Boxer, A.L., Rosen, H., Taylor, J.B., Synofzik, M., Wilke, C., Sulzer, P., Hodges, J.R., Halliday, G., Kwok, J., Sanchez-Valle, R., Lladó, A., Borrego-Ecija, S., Santana, I., Almeida, M.R., Tábuas-Pereira, M., Moreno, F., Barandiaran, M., Indakoetxea, B., Levin, J., Danek, A., Rowe, J.B., Cope, T.E., Otto, M., Anderl-Straub, S., de Mendonça, A., Maruta, C., Masellis, M., Black, S.E., Couratier, P., Lautrette, G., Huey, E.D., Sorbi, S., Nacmias, B., Laforce, R., Tremblay, M.-P.L., Vandenberghe, R., Damme, P.V., Rogalski, E.J., Weintraub, S., Gerhard, A., Onyike, C.U., Ducharme, S., Papageorgiou, S.G., Lyn, A.S., Brodtmann, A., Finger, E., Guerreiro, R., Bras, J., Rohrer, J.D., Heller, C., Convery, R.S., Woollacott, I.O., Shafei, R.M., Graff-Radford, J., Jones, D.T., Dheel, C.M., Savica, R., Lapid, M.I., Baker, M., Fields, J.A., Gavrilo, R., Domoto-Reilly, K., Poos, J.M., Van der Ende, E.L., Panman, J.L., Donker Kaat, L., Seelaar, H., Richardson, A., Frisoni, G., Mega, A., Fostinelli, S., Chiang, H.-H., Alberici, A., Arighi, A., Fenoglio, C., Heuer, H., Miller, B., Karydas, A., Fong, J., João Leitão, M., Santiago, B., Duro, D., Ferreira, Carlos, Gabilondo, A., De Arriba, M., Tainta, M., Zulaica, M., Ferreira, Catarina, Semler, E., Ludolph, A., Landwehrmeyer, B., Volk, A.E., Miltenberger, G., Verdelho, A., Afonso, S., Tartaglia, M.C., Freedman, M., Rogaeva, E., Ferrari, C., Piaceri, I., Bessi, V., Lombardi, G., St-Onge, F., Doré, M.-C., Bruffaerts, R., Vandenberghe, M., Van den Stock, J., Mesulam, M.M., Bigio, E., Koros, C., Papatriantafyllou, J., Kroupis, C., Stefanis, L., Shoesmith, C., Robertson, E., Coppola, G., Da Silva Ramos, E.M., Geschwind, D., 2020. Age at symptom onset and death and disease duration in genetic frontotemporal dementia: an international retrospective cohort study. *Lancet Neurol* 19, 145–156. [https://doi.org/10.1016/S1474-4422\(19\)30394-1](https://doi.org/10.1016/S1474-4422(19)30394-1)

Nespolous, J., Lecours, A., Lafond, D., Lemay, M., Puel, M., Joannette, Y., Cot, F., Rascol, A., 1992. Protocole Montréal-Toulouse d'examen linguistique de l'aphasie MT-86. Ortho Edition, Isbergues.

Öijerstedt, L., Chiang, H.-H., Björkström, J., Forsell, C., Lilius, L., Lindström, A.-K., Thonberg, H., Graff, C., 2019. Confirmation of high frequency of C9orf72 mutations in patients with frontotemporal dementia from Sweden. *Neurobiol Aging* 84, 241.e21-241.e25. <https://doi.org/10.1016/j.neurobiolaging.2019.03.009>

Pickering-Brown, S.M., Richardson, A.M.T., Snowden, J.S., McDonagh, A.M., Burns, A., Braude, W., Baker, M., Liu, W.-K., Yen, S.-H., Hardy, J., Hutton, M., Davies, Y., Allsop, D., Craufurd, D., Neary, D., Mann, D.M.A., 2002.

Inherited frontotemporal dementia in nine British families associated with intronic mutations in the tau gene. *Brain* 125, 732–751. <https://doi.org/10.1093/brain/awf069>

Pottier, C., Bieniek, K.F., Finch, N., van de Vorst, M., Baker, M., Perkersen, R., Brown, P., Ravenscroft, T., van Blitterswijk, M., Nicholson, A.M., DeTure, M., Knopman, D.S., Josephs, K.A., Parisi, J.E., Petersen, R.C., Boylan, K.B., Boeve, B.F., Graff-Radford, N.R., Veltman, J.A., Gilissen, C., Murray, M.E., Dickson, D.W., Rademakers, R., 2015. Whole-genome sequencing reveals important role for TBK1 and OPTN mutations in frontotemporal lobar degeneration without motor neuron disease. *Acta Neuropathol* 130, 77–92. <https://doi.org/10.1007/s00401-015-1436-x>

Ramos, E.M., Dokuru, D.R., Van Berlo, V., Wojta, K., Wang, Q., Huang, A.Y., DeVerasetty, S., Qin, Y., van Blitterswijk, M., Jackson, J., Appleby, B., Bordelon, Y., Brannelly, P., Brushaber, D.E., Dickerson, B., Dickinson, S., Domoto-Reilly, K., Faber, K., Fields, J., Fong, J., Foroud, T., Forsberg, L.K., Gavrilova, R., Ghoshal, N., Goldman, J., Graff-Radford, J., Graff-Radford, N., Grant, I., Grossman, M., Heuer, H.W., Hsiung, G.-Y.R., Huey, E., Irwin, D., Kantarci, K., Karydas, A., Kaufer, D., Kerwin, D., Knopman, D., Kornak, J., Kramer, J.H., Kremers, W., Kukull, W., Litvan, I., Ljubenkova, P., Lungu, C., Mackenzie, I., Mendez, M.F., Miller, B.L., Onyike, C., Pantelyat, A., Pearlman, R., Petrucelli, L., Potter, M., Rankin, K.P., Rascovsky, K., Roberson, E.D., Rogalski, E., Shaw, L., Syrjanen, J., Tartaglia, M.C., Tatton, N., Taylor, J., Toga, A., Trojanowski, J.Q., Weintraub, S., Wong, B., Wszolek, Z., Rademakers, R., Boeve, B.F., Rosen, H.J., Boxer, A.L., on behalf of the ARTFL/LEFFTDS consortium, Coppola, G., 2020. Genetic screening of a large series of North American sporadic and familial frontotemporal dementia cases. *Alzheimer's Dement.* 16, 118–130. <https://doi.org/10.1002/alz.12011>

Ramos, E.M., Dokuru, D.R., Van Berlo, V., Wojta, K., Wang, Q., Huang, A.Y., Miller, Z.A., Karydas, A.M., Bigio, E.H., Rogalski, E., Weintraub, S., Rader, B., Miller, B.L., Gorno-Tempini, M.L., Mesulam, M.-M., Coppola, G., 2019. Genetic screen in a large series of patients with primary progressive aphasia. *Alzheimer's & Dementia* 15, 553–560. <https://doi.org/10.1016/j.jalz.2018.10.009>

Rohrer, J.D., Crutch, S.J., Warrington, E.K., Warren, J.D., 2010a. Progranulin-associated primary progressive aphasia: A distinct phenotype? *Neuropsychologia* 48, 288–297. <https://doi.org/10.1016/j.neuropsychologia.2009.09.017>

Rohrer, J.D., Nicholas, J.M., Cash, D.M., van Swieten, J., Dopper, E., Jiskoot, L., van Minkelen, R., Rombouts, S.A., Cardoso, M.J., Clegg, S., Espak, M., Mead, S., Thomas, D.L., De Vita, E., Masellis, M., Black, S.E., Freedman, M., Keren, R., MacIntosh, B.J., Rogava, E., Tang-Wai, D., Tartaglia, M.C., Laforce, R., Tagliavini, F., Tiraboschi, P., Redaelli, V., Prioni, S., Grisoli, M., Borroni, B., Padovani, A., Galimberti, D., Scarpini, E., Arighi, A., Fumagalli, G., Rowe, J.B., Coyle-Gilchrist, I., Graff, C., Fallström, M., Jelic, V., Ståhlbom, A.K., Andersson, C., Thonberg, H., Lilius, L., Frisoni, G.B., Binetti, G., Pievani, M., Bocchetta, M., Benussi, L., Ghidoni, R., Finger, E., Sorbi, S., Nacmias, B., Lombardi, G., Polito, C., Warren, J.D., Ourselin, S., Fox, N.C., Rossor, M.N., 2015. Presymptomatic cognitive and neuroanatomical changes in genetic frontotemporal dementia in the Genetic Frontotemporal dementia Initiative (GENFI) study: a cross-sectional analysis. *Lancet Neurol* 14, 253–262. [https://doi.org/10.1016/S1474-4422\(14\)70324-2](https://doi.org/10.1016/S1474-4422(14)70324-2)

Rohrer, J.D., Ridgway, G.R., Crutch, S.J., Hailstone, J., Goll, J.C., Clarkson, M.J., Mead, S., Beck, J., Mummery, C., Ourselin, S., Warrington, E.K., Rossor, M.N., Warren, J.D., 2010b. Progressive logopenic/phonological aphasia: Erosion of the language network. *NeuroImage* 49, 984–993. <https://doi.org/10.1016/j.neuroimage.2009.08.002>

Rohrer, J.D., Woollacott, I.O.C., Dick, K.M., Brotherhood, E., Gordon, E., Fellows, A., Toombs, J., Drueyeh, R., Cardoso, M.J., Ourselin, S., Nicholas, J.M., Norgren, N., Mead, S., Andreasson, U., Blennow, K., Schott, J.M., Fox, N.C., Warren, J.D., Zetterberg, H., 2016. Serum neurofilament light chain protein is a measure of disease intensity in frontotemporal dementia. *Neurology* 87, 1329–1336. <https://doi.org/10.1212/WNL.0000000000003154>

Rolls, E.T., Huang, C.-C., Lin, C.-P., Feng, J., Joliot, M., 2020. Automated anatomical labelling atlas 3. *NeuroImage* 206, 116189. <https://doi.org/10.1016/j.neuroimage.2019.116189>

- Roncero, C., Popov, A., Chertkow, H., 2021. Multiple high dose tDCS sessions produces perceived improvement and stabilisation in a person with a MAPT gene, presenting clinically as semantic variant primary progressive aphasia with severe cognitive impairment. *Brain Stimul* 14, 358–360. <https://doi.org/10.1016/j.brs.2021.02.001>
- Saracino, D., Ferrieux, S., Noguès-Lassiaille, M., Houot, M., Funkiewiez, A., Sellami, L., Deramecourt, V., Pasquier, F., Couratier, P., Pariente, J., Géraudie, A., Epelbaum, S., Wallon, D., Hannequin, D., Martinaud, O., Clot, F., Camuzat, A., Bottani, S., Rinaldi, D., Auriacombe, S., Sarazin, M., Didic, M., Claire, B.-B., Thauvin-Robinet, C., Lagarde, J., Roué-Jagot, C., Sellal, F., Gabelle, A., Etcharry-Bouyx, F., Morin, A., Coppola, C., Levy, R., Dubois, B., Brice, A., Colliot, O., Gorno-Tempini, M.L., Teichmann, M., Migliaccio, R., Le Ber, I., French research network on FTD/FTD-ALS, 2021. Primary Progressive Aphasia Associated With GRN Mutations: New Insights Into the Non-amyloid Logopenic Variant. *Neurology* 10.1212/WNL.0000000000012174. <https://doi.org/10.1212/WNL.0000000000012174>
- Shewan, C.M., Kertesz, A., 1980. Reliability and Validity Characteristics of the Western Aphasia Battery (WAB). *J Speech Hear Disord* 45, 308–324. <https://doi.org/10.1044/jshd.4503.308>
- Simón-Sánchez, J., Dopper, E.G.P., Cohn-Hokke, P.E., Hukema, R.K., Nicolaou, N., Seelaar, H., de Graaf, J.R.A., de Koning, I., van Schoor, N.M., Deeg, D.J.H., Smits, M., Raaphorst, J., van den Berg, L.H., Schelhaas, H.J., De Die-Smulders, C.E.M., Majoor-Krakauer, D., Rozemuller, A.J.M., Willemsen, R., Pijnenburg, Y.A.L., Heutink, P., van Swieten, J.C., 2012. The clinical and pathological phenotype of C9ORF72 hexanucleotide repeat expansions. *Brain* 135, 723–735. <https://doi.org/10.1093/brain/awr353>
- Snowden, Adams, J., Harris, J., Thompson, J.C., Rollinson, S., Richardson, A., Jones, M., Neary, D., Mann, D.M., Pickering-Brown, S., 2015. Distinct clinical and pathological phenotypes in frontotemporal dementia associated with MAPT, PGRN and C9orf72 mutations. *Amyotroph Lateral Scler Frontotemporal Degener* 16, 497–505. <https://doi.org/10.3109/21678421.2015.1074700>
- Snowden, J.S., Rollinson, S., Thompson, J.C., Harris, J.M., Stopford, C.L., Richardson, A.M.T., Jones, M., Gerhard, A., Davidson, Y.S., Robinson, A., Gibbons, L., Hu, Q., DuPlessis, D., Neary, D., Mann, D.M.A., Pickering-Brown, S.M., 2012. Distinct clinical and pathological characteristics of frontotemporal dementia associated with C9ORF72 mutations. *Brain* 135, 693–708. <https://doi.org/10.1093/brain/awr355>
- Suhonen, N.-M., Kaivorinne, A.-L., Moilanen, V., Bode, M., Takalo, R., Hänninen, T., Remes, A.M., 2015. Slowly progressive frontotemporal lobar degeneration caused by the C9ORF72 repeat expansion: a 20-year follow-up study. *Neurocase* 21, 85–89. <https://doi.org/10.1080/13554794.2013.873057>
- Swift, I.J., Bocchetta, M., Benotmane, H., Woollacott, I.O.C., Shafei, R., Rohrer, J.D., 2021. Variable clinical phenotype in TBK1 mutations: case report of a novel mutation causing primary progressive aphasia and review of the literature. *Neurobiol Aging* 99, 100.e9-100.e15. <https://doi.org/10.1016/j.neurobiolaging.2020.08.014>
- Teichmann, M., Kas, A., Boutet, C., Ferrieux, S., Nogues, M., Samri, D., Rogan, C., Dormont, D., Dubois, B., Migliaccio, R., 2013. Deciphering logopenic primary progressive aphasia: a clinical, imaging and biomarker investigation. *Brain* 136, 3474–3488. <https://doi.org/10.1093/brain/awt266>
- Tetzloff, K.A., Duffy, J.R., Clark, H.M., Utianski, R.L., Strand, E.A., Machulda, M.M., Botha, H., Martin, P.R., Schwarz, C.G., Senjem, M.L., Reid, R.I., Gunter, J.L., Spychalla, A.J., Knopman, D.S., Petersen, R.C., Jack, C.R., Lowe, V.J., Josephs, K.A., Whitwell, J.L., 2019. Progressive agrammatic aphasia without apraxia of speech as a distinct syndrome. *Brain* 142, 2466–2482. <https://doi.org/10.1093/brain/awz157>
- van der Zee, J., Gijssels, I., Van Mossevelde, S., Perrone, F., Dillen, L., Heeman, B., Bäumer, V., Engelborghs, S., De Bleecker, J., Baets, J., Gelpi, E., Rojas-García, R., Clarimón, J., Lleó, A., Diehl-Schmid, J., Alexopoulos, P., Pernecky, R., Synofzik, M., Just, J., Schöls, L., Graff, C., Thonberg, H., Borroni, B., Padovani, A., Jordanova, A., Sarafov, S.,

Tournev, I., de Mendonça, A., Miltenberger-Miltényi, G., Simões do Couto, F., Ramirez, A., Jessen, F., Heneka, M.T., Gómez-Tortosa, E., Danek, A., Cras, P., Vandenberghe, R., De Jonghe, P., De Deyn, P.P., Slegers, K., Cruts, M., Van Broeckhoven, C., Goeman, J., Nuytten, D., Smets, K., Robberecht, W., Damme, P.V., Bleecker, J.D., Santens, P., Dermaut, B., Versijpt, J., Michotte, A., Ivanoiu, A., Deryck, O., Bergmans, B., Delbeck, J., Bruyland, M., Willems, C., Salmon, E., Pastor, P., Ortega-Cubero, S., Benussi, L., Ghidoni, R., Binetti, G., Hernández, I., Boada, M., Ruiz, A., Sorbi, S., Nacmias, B., Bagnoli, S., Sorbi, S., Sanchez-Valle, R., Llado, A., Santana, I., Rosário Almeida, M., Frisoni, G.B., Maetzler, W., Matej, R., Fraidakis, M.J., Kovacs, G.G., Fabrizi, G.M., Testi, S., 2017. TBK1 Mutation Spectrum in an Extended European Patient Cohort with Frontotemporal Dementia and Amyotrophic Lateral Sclerosis. *Hum Mutat* 38, 297–309. <https://doi.org/10.1002/humu.23161>

Van Langenhove, T., van der Zee, J., Gijssels, I., Engelborghs, S., Vandenberghe, R., Vandenbulcke, M., De Bleecker, J., Sieben, A., Versijpt, J., Ivanoiu, A., Deryck, O., Willems, C., Dillen, L., Philtjens, S., Maes, G., Bäumer, V., Van Den Broeck, M., Mattheijssens, M., Peeters, K., Martin, J.-J., Michotte, A., Santens, P., De Jonghe, P., Cras, P., De Deyn, P.P., Cruts, M., Van Broeckhoven, C., 2013. Distinct Clinical Characteristics of C9orf72 Expansion Carriers Compared With GRN, MAPT, and Nonmutation Carriers in a Flanders-Belgian FTLD Cohort. *JAMA Neurol* 70, 365. <https://doi.org/10.1001/2013.jamaneurol.181>

Van Mossevelde, S., van der Zee, J., Gijssels, I., Engelborghs, S., Sieben, A., Van Langenhove, T., De Bleecker, J., Baets, J., Vandenbulcke, M., Van Laere, K., Ceysens, S., Van den Broeck, M., Peeters, K., Mattheijssens, M., Cras, P., Vandenberghe, R., De Jonghe, P., Martin, J.-J., De Deyn, P.P., Cruts, M., Van Broeckhoven, C., 2016. Clinical features of TBK1 carriers compared with C9orf72, GRN and non-mutation carriers in a Belgian cohort. *Brain* 139, 452–467. <https://doi.org/10.1093/brain/awv358>

van Rooij, J., Mol, M.O., Melhem, S., van der Wal, P., Arp, P., Paron, F., Donker Kaat, L., Seelaar, H., Netherlands Brain Bank, Miedema, S.S.M., Oshima, T., Eggen, B.J.L., Uitterlinden, A., van Meurs, J., van Kesteren, R.E., Smit, A.B., Buratti, E., van Swieten, J.C., 2020. Somatic TARDBP variants as a cause of semantic dementia. *Brain* 143, 3827–3841. <https://doi.org/10.1093/brain/awaa317>

Whitwell, J.L., Duffy, J.R., Strand, E.A., Machulda, M.M., Senjem, M.L., Schwarz, C.G., Reid, R., Baker, M.C., Perkerson, R.B., Lowe, V.J., Rademakers, R., Jack, C.R., Josephs, K.A., 2015. Clinical and neuroimaging biomarkers of amyloid-negative logopenic primary progressive aphasia. *Brain and Language* 142, 45–53. <https://doi.org/10.1016/j.bandl.2015.01.009>

	This study											Snowden et al., 2012			Cerami et al., 2013	Hsiung et al., 2012
	French cohort						Finnish cohort					Case 30	Case 31	Case 32	Case 2	C2
Patient	#01	#02	#03	#04	#05	#06	Case 1	Case 2	Case 3	Case 4	Case 5	Case 30	Case 31	Case 32	Case 2	C2
Diagnosis	svPPA	svPPA	nfvPPA	nfvPPA	mPPA	mPPA	uPPA	uPPA	nfvPPA	nfvPPA	nfvPPA	PNFA	PNFA	PNFA	svPPA	PNFA
AAO (y)	39	55	63	57	74	68	63	65	70	78	62	52	62	58	68	67
DD at evaluation (y)	3	4	1	1	2	2	0.5	2	2	2	3	1	2	4	4	1
Reduced speech output	-	-	+	+	+	+	-	-	-	+	+	+	+	+	-	+
Impaired naming	+	+	-	+	+	+	-	+	+	+	+	+	+	+	+	+
Word-retrieval difficulties	-	+	-	+	+	+	+	+	+	+	+	NA	NA	NA	+	+
Impaired word repetition	-	-	-	-	-	-	-	-	-	-	-	NA	NA	NA	-	NA
Impaired sentences repetition	-	-	-	-	-	-	-	-	-	-	-	NA	NA	NA	-	NA
Phonological paraphasias	-	-	+	-	-	+	-	-	-	-	-	+	-	+	-	NA
Agrammatism	-	-	-	(+)	+	(+)	-	-	-	-	+	+	+	+	-	-
AOS	-	-	+	+	-	+	-	-	+	+	-	-	-	-	-	+
Impaired sentences comprehension	+	+	-	+	+	+	+	+	+	+	+	-	-	-	+	+
	(CS)	(SS, CS)		(CS)	(CS)	(CS)	(CS)	(CS)								
Impaired word comprehension	+	+	-	-	+§	+§	-	-	-	-	-	-	-	-	+	-
Impaired object knowledge	+	+	-	-	+§	+§	-	-	-	-	-	-	-	-	+	-
Impaired reading	+	NA	-	-	-	NA	-	-	-	-	+	NA	NA	NA	NA	+
Verbal/semantic paraphasias	+	+	-	-	-	+	-	-	-	-	-	-	-	-	NA	NA

Duration at last follow-up	10	10	2	2.5	4	5	4	4†	1	3†	5†	4	4	NA	5	2
Other relevant impairments at follow-up	BD, FCSd	BD, FCSd, PLD	ALS	BD, FCSd, Park	FCSd	FCSd, (PLD)	FCSd, BD, Park	FCSd	FCSd, Park	FCSd, Park	FCSd	FCSd, Park	-	FCSd, Park	BD	BD
Diagnosis at last follow up	svPPA	svPPA	PPA/ALS	PPA/bvFTD	mPPA	mPPA	uPPA	uPPA	nfvPPA	nfvPPA	nfvPPA	PNFA	PNFA	PNFA	svPPA/bvFTD	PNFA/bvFTD

Table 1. Clinical and linguistic features of the 16 PPA-*C9orf72* patients. + indicates presence, - absence, and (+) partial or mild difficulties. §: appeared during disease evolution; †: disease duration at death. AAO: age at onset; ALS: amyotrophic lateral sclerosis; AOS: apraxia of speech; BD: Behavioral disorders; bvFTD: behavioral variant of frontotemporal dementia; CS: complex sentences; DD: disease duration; FCSd: frontal cognitive syndrome; mPPA: mixed primary progressive aphasia; NA: not available; nfvPPA: non-fluent/agrammatic variant of PPA; Park: parkinsonism; PLD: parietal lobe dysfunction; PNFA: progressive non-fluent aphasia; PPA: primary progressive aphasia; SS: simple sentences; svPPA: semantic variant of PPA; uPPA: unclassifiable PPA; y: years. An overall description of the Finnish cohort without detail on individual phenotypes was provided in Haapanen et al., 2020.

Reference (origin of the cohort)	Cohort of PPA patients	Cohort of <i>C9orf72</i> carriers	Frequency of <i>C9orf72</i> carriers in PPA cohort (%)	Frequency of PPA patients in <i>C9orf72</i> cohort (%)	PPA variants
Largest <i>C9orf72</i> cohorts					
(Boeve et al., 2012) (USA)	141 PPA 76 <i>nfvPPA</i> 65 <i>svPPA</i>	103 <i>C9orf72</i>	0%	0%	-
(Majounie et al., 2012)* (Europe, USA)	378 PPA 176 <i>PNFA</i> 202 <i>SD</i>	625 <i>C9orf72</i>	5%	3%	18 PPA-<i>C9orf72</i>* : 11 <i>PNFA</i> 7 <i>SD</i>
(Le Ber et al., 2013) (France)	73 PPA 62 <i>PNFA</i> 11 <i>SD</i>	202 <i>C9orf72</i>	7%	2%	5 PPA-<i>C9orf72</i>: 3 <i>PNFA</i> 2 <i>SD</i>
(Ramos et al., 2020) (USA)	85 PPA 36 <i>nfvPPA</i> 45 <i>svPPA</i> 4 <i>lvPPA</i>	95 <i>C9orf72</i>	1%	1%	1 PPA-<i>C9orf72</i> 1 <i>svPPA</i>
(Moore et al., 2020)* (International)	-	1433 <i>C9orf72</i>	-	3%	46 PPA-<i>C9orf72</i>* 26 <i>nfvPPA</i> 13 <i>svPPA</i> 3 <i>lvPPA</i> 4 <i>PPA-NOS</i>
Largest PPA cohorts					
(Mahoney et al., 2012) (UK)	102 PPA 49 <i>PNFA</i> 53 <i>SD</i>	19 <i>C9orf72</i>	1%	5%	1 PPA-<i>C9orf72</i>: 1 <i>PNFA</i>
(Simón-Sánchez et al., 2012) (The Netherlands)	101 PPA	42 <i>C9orf72</i>	8%	19%	8 PPA-<i>C9orf72</i>: 2 <i>svPPA</i> 6 <i>PPA-NOS</i>
(Snowden et al., 2012) (UK)	118 PPA 66 <i>PNFA</i> 53 <i>SD</i>	32 <i>C9orf72</i>	3%	10%	3 PPA-<i>C9orf72</i>: 3 <i>nfvPPA</i>
(Galimberti et al., 2013) (Italy)	98 PPA 64 <i>PNFA</i> 34 <i>SD</i>	39 <i>C9orf72</i>	2%	5%	2 PPA-<i>C9orf72</i>: 2 <i>SD</i>
(Flanagan et al., 2015) (USA)	100 PPA 17 <i>nfvPPA</i> 16 <i>svPPA</i> 54 <i>lvPPA</i> 13 <i>uPPA</i>	-	2%	-	2 PPA-<i>C9orf72</i>: 1 <i>svPPA</i> 1 <i>uPPA</i>
(Bocchetta et al., 2018) (UK)	193 PPA 103 <i>PNFA</i> 76 <i>SD</i>	28 <i>C9orf72</i>	1%	7%	2 PPA-<i>C9orf72</i> 2 <i>nfvPPA</i>

	<i>14 PPA-NOS</i>				
(Ramos et al., 2019) (USA)	403 PPA <i>125 nfvPPA</i> <i>122 svPPA</i> <i>89 lvPPA</i> <i>5 mPPA</i> <i>18 uPPA</i> <i>44 PPA-NOS</i>	-	1%	-	4 PPA-C9orf72 <i>3 nfvPPA</i> <i>1 svPPA</i>
(Costa et al., 2020) (International)	495 PPA	<i>56 C9orf72</i>	1%	2%	4 PPA-C9orf72
Additional study cohorts					
(Hsiung et al., 2012) (Canada)	-	<i>30 C9orf72</i>	-	17%	5 PPA-C9orf72: <i>5 PNFA</i>
(Cerami et al., 2013) (Italy)	86 FTLD	-	-	-	1 PPA-C9orf72: <i>1 svPPA</i>
(Gil-Navarro et al., 2013) (Spain)	32 PPA <i>15 nfvPPA</i> <i>5 svPPA</i> <i>7 lvPPA</i> <i>5 uPPA</i>	-	6%	-	2 PPA-C9orf72: <i>2 nfvPPA</i>
(Irwin et al., 2013) (USA)	-	<i>64 C9orf72</i>	-	8%	5 PPA-C9orf72: <i>4 nfvPPA</i> <i>1 svPPA</i>
(Kaivorinne et al., 2013) (Finland)	27 PPA <i>20 PNFA</i> <i>7 SD</i>	<i>22 C9orf72</i>	22%	27%	6 PPA-C9orf72: <i>6 PNFA</i>
(Van Langenhove et al., 2013) (Belgium)	-	<i>26 C9orf72</i>	-	12%	3 PPA-C9orf72: <i>2 PNFA</i> <i>1 SD</i>
(Benussi et al., 2014) (Italy)	82 PPA	<i>26 C9orf72</i>	1%	4%	1 PPA-C9orf72
(Fletcher et al., 2015a)* (UK)	37 PPA <i>20 PNFA</i> <i>17 SD</i>	-	3%	-	1 PPA-C9orf72*: <i>1 PNFA</i>
(Fletcher et al., 2015b)* (UK)	34 PPA <i>15 PNFA</i> <i>19 SD</i>	-	3%	-	1 PPA-C9orf72*: <i>1 PNFA</i>
(Snowden et al., 2015) (UK)	-	<i>42 C9orf72</i>	-	10%	4 PPA-C9orf72: <i>4 PNFA</i>

(Hardy et al., 2016)* (UK)	32 PPA 18 <i>nfvPPA</i> 14 <i>svPPA</i>	-	3%	-	1 PPA-C9orf72*: 1 <i>nfvPPA</i>
(Rohrer et al., 2016) (UK)	37 PPA 13 <i>nfvPPA</i> 10 <i>svPPA</i> 7 <i>lvPPA</i> 7 <i>uPPA</i>	-	3%	-	1 PPA-C9orf72 1 <i>nfvPPA</i>
(Van Mossevelde et al., 2016) (Belgium)	79 PPA 43 <i>PNFA</i> 33 <i>SD</i> 2 <i>lvPPA</i> 1 <i>uPPA</i>	65 <i>C9orf72</i>	10%	12%	8 PPA-C9orf72: 5 <i>PNFA</i> 3 <i>SD</i>
(Öijerstedt et al., 2019) (Sweden)	132 FTLD	35 <i>C9orf72</i>	-	3%	1 PPA-C9orf72 1 <i>PPA-NOS</i>
(Cajanus et al., 2020) (Finland)	-	26 <i>C9orf72</i>	-	19%	5 PPA-C9orf72
(Haapanen et al., 2020) (Finland)	18 PPA: 16 <i>nfvPPA</i> 2 <i>PPA-NOS</i>	-	28%	-	5 PPA-C9orf72 3 <i>nfvPPA</i> 2 <i>PPA-NOS</i>

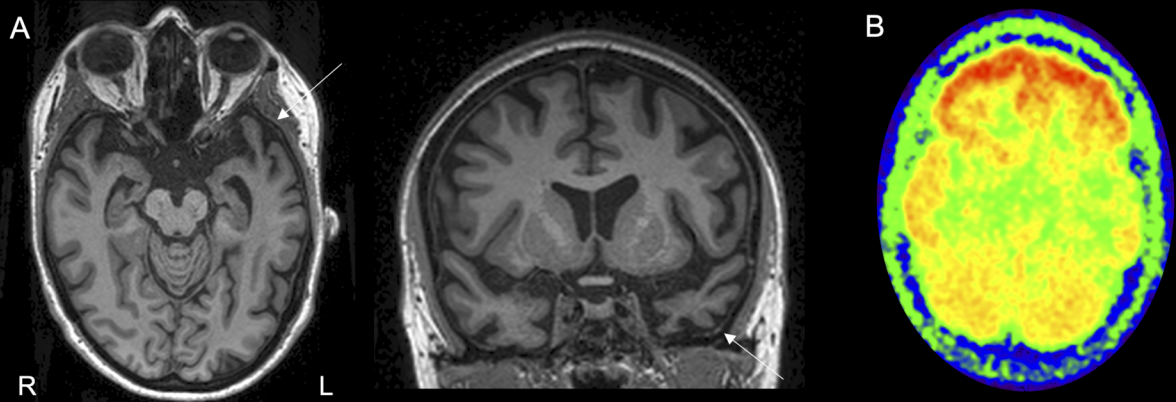
Table 2. Summary of the most important revised papers contributing to determine the frequency of PPA in *C9orf72* cohorts, and of *C9orf72* expansion in PPA cohorts. The largest study cohorts, contributing to a better estimation of frequencies, are shown first. FTLD: frontotemporal lobar degeneration; *lvPPA*: logopenic variant of PPA; *mPPA*: mixed PPA; *na*: not available; *nfvPPA*: non-fluent/agrammatic variant of PPA; *NOS*: not otherwise specified; *PPA*: primary progressive aphasia; *PNFA*: progressive non-fluent aphasia; *SD*: semantic dementia; *svPPA*: semantic variant of PPA. *Some patients may be duplicated among two or more cohorts.

FIGURE LEGENDS

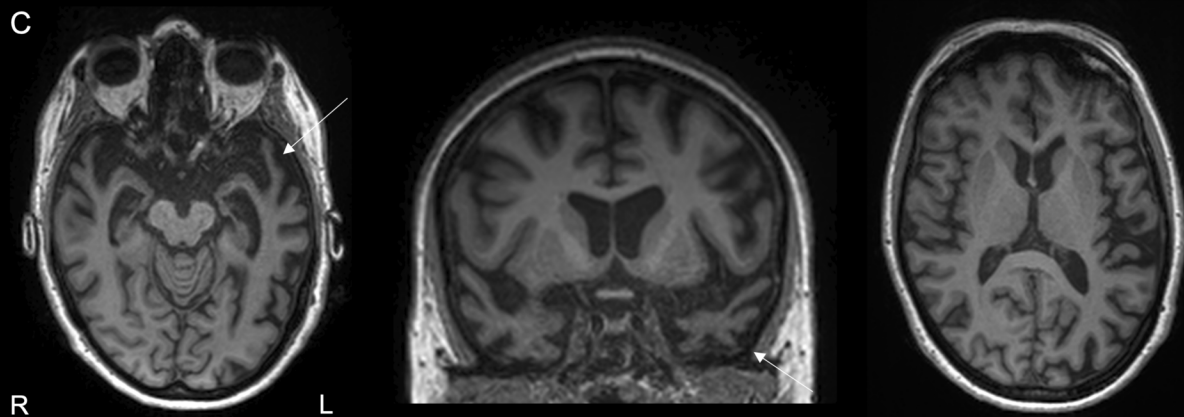
Figure 1. MRI and ¹⁸FDG-PET studies in patient #01. A: cortical atrophy prevailing in the left anterior temporal lobe (arrows) at age 43, 4 years after onset. B: asymmetric temporo-polar hypometabolism, prevailing on the left side, at the same age. C: progression of atrophy in left temporal regions (arrows), and extension to the contralateral side and frontal cortex at age 46, 7 years after onset.

Figure 2. MRI and ¹⁸FDG-PET studies in patients #04 and #06. A: bilateral fronto-temporal atrophy prevailing in left peri-sylvian areas. B: asymmetric left-predominant fronto-temporal hypometabolism with involvement of fronto-opercular cortex. C: bilateral peri-sylvian atrophy with slight predominance on the left side. D: bitemporal hypometabolism, prevailing in the left temporal pole.

Patient #01 at 4 years from onset

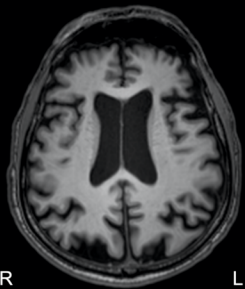


Patient #01 at 7 years from onset

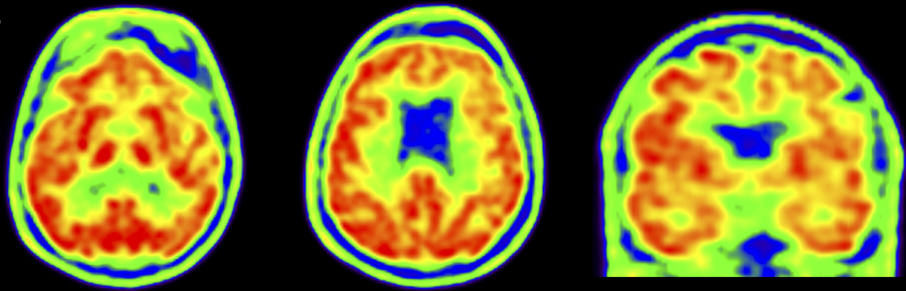


Patient #04 at 1 year from onset

A



B

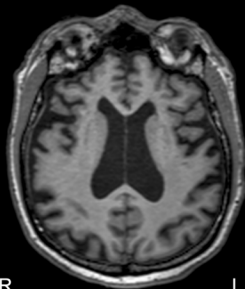


R

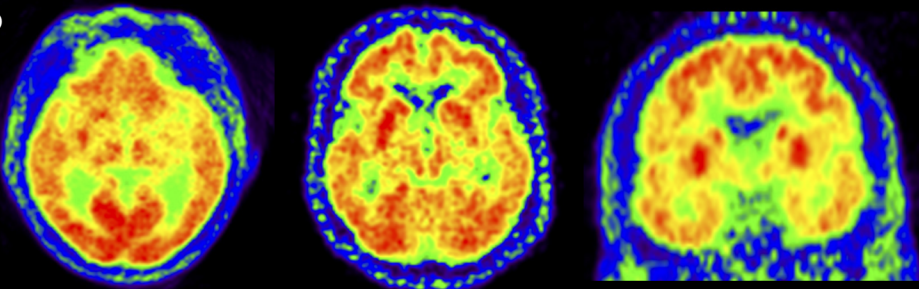
L

Patient #06 at 2 years from onset

C



D



R

L