



**HAL**  
open science

## Variant Creutzfeldt–Jakob Disease Diagnosed 7.5 Years after Occupational Exposure

Jean-Philippe Brandel, M. Bustuchina Vlaicu, Audrey Culeux, Maxime Belondrade, Daisy Bougard, Katarina Grznarova, Angeline Denouel, Isabelle Plu, Elodie Bouaziz-Amar, Danielle Seilhean, et al.

► **To cite this version:**

Jean-Philippe Brandel, M. Bustuchina Vlaicu, Audrey Culeux, Maxime Belondrade, Daisy Bougard, et al.. Variant Creutzfeldt–Jakob Disease Diagnosed 7.5 Years after Occupational Exposure. *New England Journal of Medicine*, 2020, 383 (1), pp.83-85. 10.1056/NEJMc2000687 . hal-03758486

**HAL Id: hal-03758486**

**<https://hal.science/hal-03758486>**

Submitted on 23 Aug 2022

**HAL** is a multi-disciplinary open access archive for the deposit and dissemination of scientific research documents, whether they are published or not. The documents may come from teaching and research institutions in France or abroad, or from public or private research centers.

L'archive ouverte pluridisciplinaire **HAL**, est destinée au dépôt et à la diffusion de documents scientifiques de niveau recherche, publiés ou non, émanant des établissements d'enseignement et de recherche français ou étrangers, des laboratoires publics ou privés.

## CORRESPONDENCE



## Variant Creutzfeldt–Jakob Disease Diagnosed 7.5 Years after Occupational Exposure

**TO THE EDITOR:** We report a case of variant Creutzfeldt–Jakob disease (CJD) that was plausibly related to accidental occupational exposure in a technician who had handled murine samples contaminated with the agent that causes bovine spongiform encephalopathy (BSE) 7.5 years earlier.

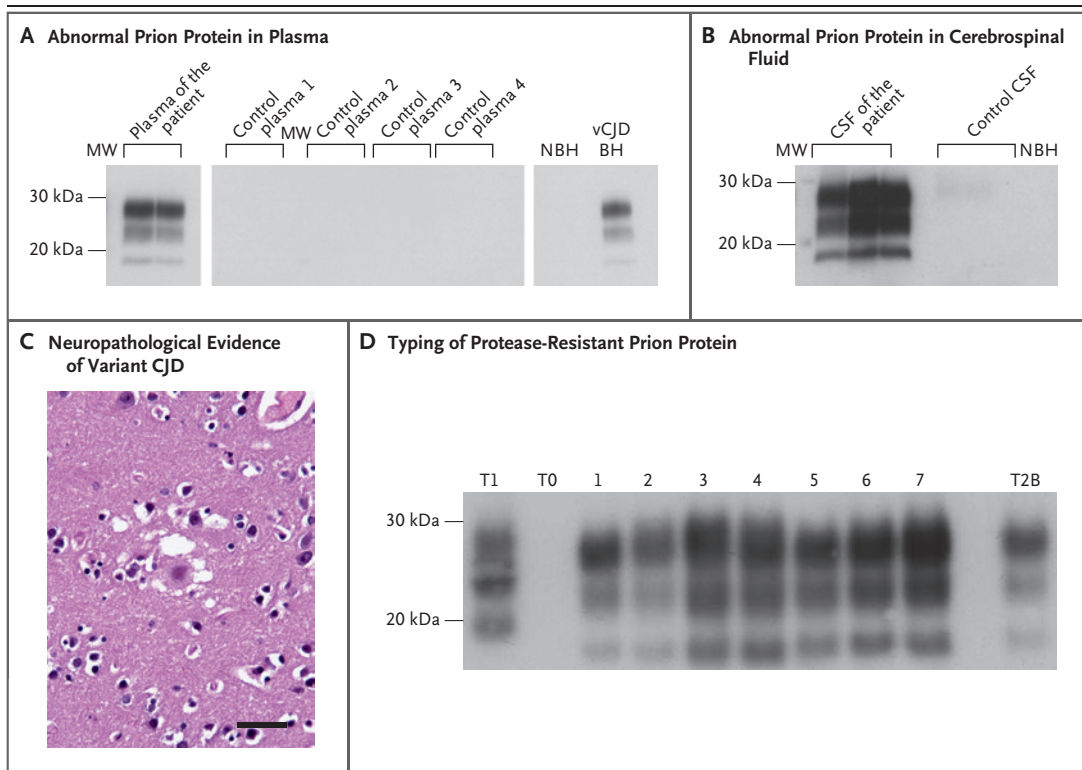
In May 2010, when the patient was 24 years of age, she worked in a prion research laboratory, where she handled frozen sections of brain of transgenic mice that overexpressed the human prion protein with methionine at codon 129. The mice had been infected with a sheep-adapted form of BSE. During this process, she stabbed her thumb through a double pair of latex gloves with the sharp ends of a curved forceps used to handle the samples. Bleeding was noted at the puncture site.

In November 2017, she began having burning pain in the right shoulder and neck. The pain worsened and spread to the right half of her body during the following 6 months. In November 2018, an examination of a sample of cerebrospinal fluid (CSF) obtained from the patient was normal. Magnetic resonance imaging (MRI) of the brain showed a slight increase in the fluid-attenuated inversion recovery (FLAIR) signal in the caudates and thalami (Fig. S1A and S1B in the Supplementary Appendix, available with the full text of this letter at NEJM.org). In January 2019, she became depressed and anxious and had memory impairment and visual hallucinations. There was hypertonia on the right side of her body. At that time, an analysis of CSF for 14-3-3 protein was negative. In March 2019, MRI showed an increased FLAIR signal in pulvinar and dorsomedial nuclei of thalami (Fig. S1C through S1E).

The patient was found to be homozygous for methionine at codon 129 of the prion protein gene without mutation. An analysis of a sample of CSF on real-time quaking-induced conversion analysis was negative for a diagnosis of sporadic CJD. However, an analysis of plasma and CSF by means of protein misfolding cyclic amplification was positive for the diagnosis of variant CJD (Fig. 1A and 1B). The patient died 19 months after the onset of symptoms. Neuropathological examination confirmed the diagnosis of variant CJD (Fig. 1C and 1D). Western blot analysis showed the presence of type 2B protease-resistant prion protein in all sampled brain areas. The clinical characteristics of the patient and the postmortem neuropathological features were similar to those observed in 27 patients with

### THIS WEEK'S LETTERS

- 83 Variant Creutzfeldt–Jakob Disease Diagnosed 7.5 Years after Occupational Exposure
- 85 Covid-19 in Immune-Mediated Inflammatory Diseases — Case Series from New York
- 88 Reduced Rate of Hospital Admissions for ACS during Covid-19 Outbreak in Northern Italy
- 90 Surgery vs. Conservative Care for Persistent Sciatica
- 91 Early Surgery or Conservative Care for Asymptomatic Aortic Stenosis
- 93 Multidrug-Resistant Infections in U.S. Hospitals
- e3 Roxadustat for Anemia in Patients with CKD



**Figure 1. Detection of Abnormal Prion Protein in Biologic Fluid Samples and Postmortem Findings.**

Panel A shows the results of protein misfolding cyclic amplification (PMCA) of prion protein in plasma samples obtained from the study patient. In this analysis, a  $10^{-8}$  dilution of brain homogenate (BH) of variant Creutzfeldt–Jakob disease (vCJD) (British National Institute for Biological Standards and Control number, NHBYO/0003) was used as positive control and submitted to one round of PMCA. NBH denotes a nonseeded PMCA substrate used as a negative control and submitted to four rounds of PMCA. Plasma samples ( $450\ \mu\text{l}$ ) obtained from the study patient were submitted to two rounds of PMCA, and negative control samples were submitted to four rounds after the capture of prion protein with the use of magnetic nanobeads coated with plasminogen. Amplification of plasma samples was performed in duplicate. MW denotes molecular weight. Panel B shows samples of cerebrospinal fluid (CSF) obtained from the patient, a negative control, and an NBH sample, which were all submitted to three rounds of PMCA. Amplification of CSF samples was performed in triplicate. Each round of PMCA consisted of 80 cycles of 30 minutes of incubation per 20-second sonication. Proteinase K–resistant prion protein was detected on Western blot analysis with the use of 3F4 monoclonal anti–prion protein antibody. Panel C shows postmortem findings of florid plaque typical of variant CJD (hematoxylin and eosin staining). The scale bar indicates  $50\ \mu\text{m}$ . Panel D shows Western blot typing of protease-resistant prion protein detected in several brain samples obtained from the patient. Type 2B of this protein was detected in all studied brain areas, including the frontal (lane 1) and occipital (lane 5) isocortexes, thalamus (lane 2), cerebellum (lane 3), pulvinar (lane 4), hippocampus (lane 6), and caudate nucleus (lane 7). T1 indicates type 1 protease-resistant prion protein obtained from a patient with sporadic CJD, T2B denotes type 2B protease-resistant prion protein from a patient with variant CJD, and T0 denotes a negative control sample.

variant CJD who had previously been reported in France.<sup>1</sup> (Additional details are provided in the Supplementary Appendix.)

There are two potential explanations for this patient's condition. Oral transmission from contaminated cattle products cannot be ruled out because the patient was born at the beginning of the French BSE outbreak in cattle. However, the last two patients who had confirmed variant CJD

with methionine homozygosity at codon 129 in France and the United Kingdom died in 2014 and 2013, respectively, which makes oral transmission unlikely. In France, the risk of variant CJD in 2019 was negligible or nonexistent in the post-1969 birth cohort.<sup>2</sup>

Percutaneous exposure to prion-contaminated material is plausible in this patient, since the prion strain that she had handled was consistent

with the development of variant CJD.<sup>3</sup> The 7.5-year delay between the laboratory accident and her clinical symptoms is congruent with the incubation period in the transfusion-transmitted form of the disease. The ability of this strain to propagate through the peripheral route has been documented, and experimental studies with scrapie strains have shown that scarification and subcutaneous inoculation are effective routes.<sup>4,5</sup> The last known Italian patient with variant CJD, who died in 2016, had had occupational contact with BSE-infected brain tissues, although subsequent investigation did not disclose a laboratory accident (Pocchiari M, Italian Registry of CJD: personal communication). Thus, the last two cases of variant CJD outside the United Kingdom have been associated with potential occupational exposure. Such cases highlight the need for improvements in the prevention of transmission of variant CJD and other prions that can affect humans in the laboratory and neurosurgery settings, as outlined in the Supplementary Appendix.

Jean-Philippe Brandel, M.D.

Assistance Publique–Hôpitaux de Paris  
Paris, France

M. Bustuchina Vlaicu, M.D.

Groupe Hospitalier Nord-Essonne  
Orsay, France

Audrey Culeux, B.Sc.

INSERM Unité 1127  
Paris, France

Maxime Belondrade, M.Sc.

Daisy Bougard, Ph.D.

Etablissement Français du Sang  
Montpellier, France

Katarina Grznarova, Ph.D.

Angeline Denouel, M.Sc.

INSERM Unité 1127  
Paris, France

Isabelle Plu, M.D.

Elodie Bouaziz-Amar, Pharm.D., Ph.D.

Danielle Seilhean, M.D., Ph.D.

Assistance Publique–Hôpitaux de Paris  
Paris, France

Michèle Levasseur, M.D.

Groupe Hospitalier Nord-Essonne  
Orsay, France

Stéphane Haïk, M.D., Ph.D.

INSERM Unité 1127  
Paris, France  
stephane.haik@upmc.fr

Supported by a grant (ANR-10-IAIHU-06) from Programme d'Investissements d'Avenir and Santé Publique France.

Disclosure forms provided by the authors are available with the full text of this letter at NEJM.org.

1. Brandel JP, Heath CA, Head MW, et al. Variant Creutzfeldt-Jakob disease in France and the United Kingdom: evidence for the same agent strain. *Ann Neurol* 2009;65:249-56.
2. Chadeau-Hyam M, Alperovitch A. Risk of variant Creutzfeldt-Jakob disease in France. *Int J Epidemiol* 2005;34:46-52.
3. Padilla D, Béringue V, Espinosa JC, et al. Sheep and goat BSE propagate more efficiently than cattle BSE in human PrP transgenic mice. *PLoS Pathog* 2011;7(3):e1001319.
4. Taylor DM, McConnell I, Fraser H. Scrapie infection can be established readily through skin scarification in immunocompetent but not immunodeficient mice. *J Gen Virol* 1996;77:1595-9.
5. Kimberlin RH, Walker CA. Pathogenesis of mouse scrapie: dynamics of agent replication in spleen, spinal cord and brain after infection by different routes. *J Comp Pathol* 1979;89:551-62.

DOI: 10.1056/NEJMc2000687

---

## Covid-19 in Immune-Mediated Inflammatory Diseases — Case Series from New York

**TO THE EDITOR:** Data on Covid-19 in patients with immune-mediated inflammatory disease who have received anticytokine biologics, other immunomodulatory therapies, or both on a long-term basis are scarce. Trials to assess the efficacy of antirheumatic therapies such as hydroxychloroquine<sup>1</sup> and anticytokine therapies such as interleukin-6 inhibitors<sup>2</sup> to improve outcomes in patients with Covid-19 are ongoing. The rationale for their use is that worse outcomes (i.e., hospi-

talization, ventilation, or death) may be related to a proinflammatory cytokine storm.<sup>3,4</sup>

Here, we report a prospective case series involving patients with known immune-mediated inflammatory disease (rheumatoid arthritis, psoriatic arthritis, ankylosing spondylitis, psoriasis, inflammatory bowel disease, or related conditions) who were receiving anticytokine biologics, other immunomodulatory therapies, or both when confirmed or highly suspected symptom-