

Investigation of Left-Atrial flows using a 3D radial based self-gated respiratory motion corrected 4D Flow MRI sequence

S. Boccalini¹, M. Mousseaux², P. Chevalier², L. Bousset^{1,3}, P. Douek^{1,3}, M. Sigovan³

¹ Department of Radiology, HCL, Lyon, France

² Department of Cardiac Rythm, HCL, Lyon, France

³ University of Lyon, CREATIS Laboratory, Lyon, France

Introduction: Atrial fibrillation (AF) is a strong risk factor for embolic stroke likely due to prothrombotic alterations in left atrium (LA) blood flow. Four-dimensional velocity mapping MRI (4D Flow) allows quantification of LA and pulmonary veins (PV) flows. However, in the context of AF, standard 4D Flow leads to quantification errors from the inherent averaging of MRI [1].

Our goal was to develop a respiratory motion corrected free-running 3D radial based 4D Flow sequence and to investigate the AF related variability of LA blood flows.

Methods: We implemented a free-running interleaved 3D radial velocity mapping sequence on a 1.5T Philips Ingenia (Philips, Best, The Netherlands), based on a spiral phyllotaxis pattern [2]. Imaging was performed in 6 paroxysmal AF patients, 2 permanent AF, and 5 age matched volunteers as follows: TE/TR 3.5/7.5 ms, FA=6°, VENC=70-96 cm/s, 2.2-2.8 mm isotropic voxel for an acquisition time of 8 – 12 minutes.

The respiratory self-gated signal was obtained from the k-space center as previously proposed [3], and used to bin the data in 5 respiratory phases. The 3D translation motion of the heart between end-expiration and all other phases was estimated and used to correct the phase of the k-space data. Finally, the corrected data was binned into cardiac phases using the ECG signal and a fixed temporal resolution. This strategy reduces the velocity errors related to averaging over variable RR durations.

Images were reconstructed offline using a compressed sensing algorithm implemented in Matlab (The Mathworks, Inc, Natick, MA). 4D Flow data analysis was performed with PIE Medical (The Netherlands).

Results: Qualitatively, respiratory motion correction improved the sharpness of the PVs and modified slightly the flow pattern in the LA (Figure 1). Streamline visualization demonstrated significant differences in flow patterns, specifically a physiological vortex for healthy subjects, and absence of vortex and lower overall LA velocities for AF patients (Figure 2).

Discussion: We present here preliminary results demonstrating the feasibility of intra-atrial flow assessment using a 3D radial based 4D Flow MRI with respiratory motion correction. The initial results will be completed by an ongoing quantitative analysis of the LA flows (vorticity, vortex size). Particular interest will be paid to the impact of respiratory motion correction on these quantitative descriptors.

LA flows are related to the entire cardiac circulation. Thus an added advantage of the 3D radial 4D Flow is the capability to measure the hemodynamic parameters of the entire heart in the same amount of time as a standard Cartesian 4D Flow covering only the LA, albeit with stronger under-sampling.

Funding: ANR-18-CE19-0025-01

References:

1. Markl M, et al (2016) *Int J Cardiovasc Imaging* 32:807–815.
2. Ma LE, et al (2020) *Radiol Cardiothorac Imaging* 2:e200219.
3. Qi H, et al (2019) *Magn Reson Med* 82:1331–1342.

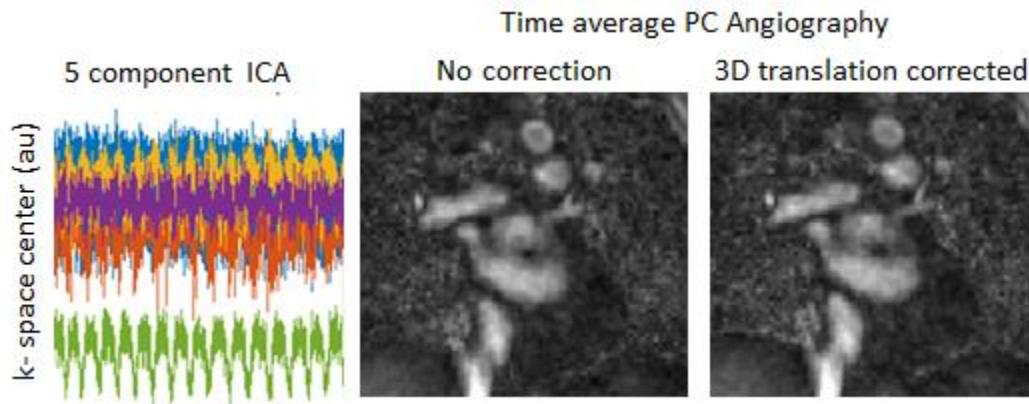


Figure 1. Representative result of ICA analysis of the central point of k-space for respiratory self-gating signal derivation (left) and time averaged phase contrast angiography (PCA) of no motion correction (center) and 3D heart translational motion correction (right). One can appreciate the improvement in the sharpness of pulmonary veins and a change in the intra-atrial flow pattern.

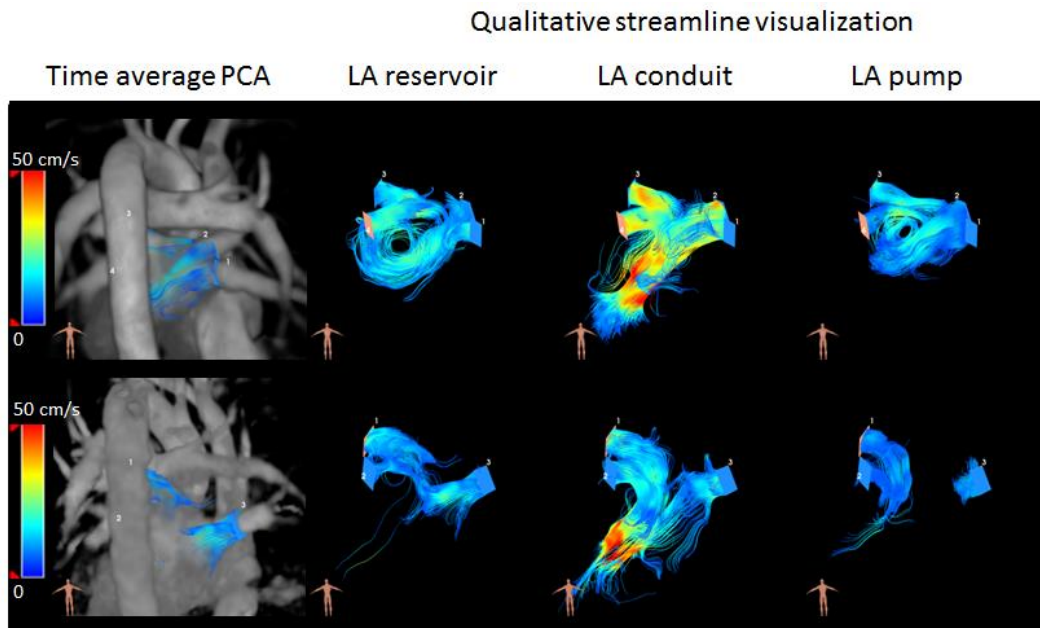


Figure 2. Representative examples of a healthy volunteer (top) and persistent AF patient (bottom). Volume rendering of the time average PCA demonstrates the vascular anatomy. Streamline visualization at three different cardiac phases demonstrate significant differences in flow patterns, specifically the physiological vortex of the healthy subject, and the absence of vortex and lower overall LA velocities for the AF patient.