



HAL
open science

Monocentric retrospective clinical outcome in a group of 13 patients with opsoclonus myoclonus syndrome, proposal of diagnostic algorithm and review of the literature

Sarai Urtiaga Valle, Sarah Souvannanorath, Nicolas Leboucq, Stephanie Haouy, Francois Rivier, Agathe Roubertie, Pierre Meyer

► **To cite this version:**

Sarai Urtiaga Valle, Sarah Souvannanorath, Nicolas Leboucq, Stephanie Haouy, Francois Rivier, et al.. Monocentric retrospective clinical outcome in a group of 13 patients with opsoclonus myoclonus syndrome, proposal of diagnostic algorithm and review of the literature. *European Journal of Paediatric Neurology*, 2022, <10.1016/j.ejpn.2022.07.002>. <hal-03727224>

HAL Id: hal-03727224

<https://hal.science/hal-03727224v1>

Submitted on 14 Aug 2022

HAL is a multi-disciplinary open access archive for the deposit and dissemination of scientific research documents, whether they are published or not. The documents may come from teaching and research institutions in France or abroad, or from public or private research centers.

L'archive ouverte pluridisciplinaire HAL, est destinée au dépôt et à la diffusion de documents scientifiques de niveau recherche, publiés ou non, émanant des établissements d'enseignement et de recherche français ou étrangers, des laboratoires publics ou privés.



HAL Authorization

Monocentric retrospective clinical outcome in a group of 13 patients with opsoclonus myoclonus syndrome, proposal of diagnostic algorithm and review of the literature

Sarai Urtiaga Valle^{a,*}, Sarah Souvannanorath^a, Nicolas Leboucq^b, Stephanie Haouy^c, François Rivier^{a,d}, Agathe Roubertie^{a,e}, Pierre Meyer^{a,d}

^a Neuropaediatrics Department, CHU of Montpellier, Montpellier University, France

^b Neuroradiology Department, CHU of Montpellier, Montpellier University, France

^c Oncology Department, CHU of Montpellier, Montpellier University, France

^d Phymedexp, Montpellier University, Inserm, CNRS, Montpellier, France

^e INSERM U 1051, Institut des Neurosciences de Montpellier, Montpellier University, Montpellier, France

ARTICLE INFO

Keywords:

Opsoclonus
Myoclonus
Autoimmune
Encephalopathy
Ataxia
Behavioural troubles
OMS
Neuroblastoma

ABSTRACT

Background: Dancing eye syndrome or opsoclonus-myoclonus syndrome (OMS) is a very rare disease (incidence <1/5,000,000 per year), which is more prevalent in young children. Although it is not usually a cause of mortality, the aftermaths are not rare.

Methods: We performed an observational retrospective review of children diagnosed with OMS in our neuro-pediatric department from 1996 to 2020, with the objective of assessing the prognostic value of initial clinical features. All medical data from diagnosis to last follow-up were reviewed. We defined unfavorable evolution of OMS as persistence or worsening of symptoms. Subsequently, based on a literature review, our results and experience, a diagnostic algorithm was developed.

Results: A total of 13 OMS patients were included: 61.5% were male (n = 8), median age at diagnosis was 18 months (IR = 76), median treatment delay was 14 days (IR = 146) and OMS score at onset was 8 (IR = 11). The most frequent etiologies were neuroblastoma-associated and idiopathic OMS (38.46%; n = 5) of the patients, followed by post-infectious OMS (n = 3). All the patients were treated with corticosteroids, five required a surgical intervention (neuroblastoma group), and three required adjunctive immune therapy (immunoglobulins, cyclophosphamide and/or rituximab). We detected neurodevelopmental disorders in 38.46% (n = 5) of the patients, mainly attention deficit (n = 4), and persistent sleep disturbances (n = 4). The median OMS score at the end of follow-up was 1 (IR = 3).

An important diagnostic delay, OMS score of ≥ 10 and age >1 year at onset may correlate with a higher risk of aftermaths. We detected a better prognosis in the post-infectious OMS, with full recovery occurring in 2/3 of patients.

Conclusions: Early clinical suspicion is key to guarantee maximum response of treatment.

1. Introduction

The Opsoclonus-Myoclonus Syndrome (OMS) was described for the first time by Kinsbourne in 1962 [1]. Six children aged 9–20 months with an initial normal development (except one) debuted presented with acute incoordination of limb movements, flickering muscular contractions and ‘dancing eyes’, which were unassociated with

electroencephalogram discharges. The estimated incidence is 0.27–0.4 cases per million children [2–5].

The contemporary diagnosis of the disease is established by fulfilling three out of four criteria [2]:

1. Abnormal eye movements (opsoclonus): involuntary chaotic saccadic disturbance with omnidirectional, irregular oscillations

* Corresponding author. Present Address: CHU de Montpellier, Gui de Chauliac. Neuropaediatrics Department, 80 Avenue Augustin Fliche, 34295, Montpellier, France.

E-mail address: sarai.urtiaga@gmail.com (S. Urtiaga Valle).

with a frequency between 6 and 15 Hz that persists during sleep. There is an increase with fixation of gaze and light, which may not be constant.

2. Myoclonus or Ataxia: the myoclonus are irregular muscle jerks that can be observed predominantly in trunk muscles. They can occasionally be present exclusively during the sleep or not appear until several days or weeks after the onset of the first symptoms. The ataxia can be axial or affect the limbs. It can become very disabling, altering the manipulation of objects or the gait with falls.
3. Sleep disturbances or behavioural changes, most often irritability.
4. Presence of neuroblastoma.

The OMS severity score (Fig. 1) is based on a 5-item scale which evaluated from 0 to 3 points the grading of opsoclonus, myoclonus/arm and hand function, gait ataxia, stance ataxia and mood or sleep disturbance. The higher the score, the greater the severity. Today, the diagnosis of this entity is facilitated by modern biological and imaging techniques, making nuclear magnetic resonance imaging (MRI) a useful tool. On the other hand, the immunomodulatory treatment, especially corticosteroids, play a key role in resolving the illness.

We performed this study with the objective of assessing the prognostic value of initial clinical features. Secondly, based on our results and experience, we developed a proposal of diagnostic algorithm.

2. Materials and methods

We performed an observational retrospective review of patients diagnosed with OMS in the Montpellier University Hospital neuro-pediatric department from 1996 to 2020. We elaborated a database to register sex, age of onset, etiology, OMS scale at onset, delay in treatment, type of treatment, MRI and cerebral spinal fluid (CSF) results, duration of follow-up and aftermaths.

We classified as post-infectious those cases with OMS in less than four weeks following an infectious process (even without finding a causal germ), as autoimmune those in which we identified an antibody as a cause without the presence of a tumour, as paraneoplastic those cases in which a tumour is identified, and as idiopathic those in which those in which no etiology is found despite imaging (cranial and body) and biochemical study (blood and/or CSF analysis).

In terms of prognosis, we considered a complete improvement when the patient achieved total remission of symptoms (OMS score = 0 and no other sequelae); a very good evolution when the patient achieved an OMS score ≤ 2 with no other troubles associated or 0 but with other troubles; a good evolution when the patient achieved an OMS score ≤ 2 in association with other neuropsychological sequelae; regular evolution when the OMS score was 2–6 in association or not with other neuropsychological troubles, and as a bad evolution when the OMS score was > 6 .

We defined as relapse those cases in which after achieving a score of

GRADING OF OPSOCLONUS	0	None	No abnormal eye movements
	1	Mild	Abnormal eye movements present but child can focus on an object, no interference with function
	2	Moderate	Abnormal eye movements present unable to focus with mild functional impairment
	3	Severe	Abnormal eye movements present unable to focus on an object, severe functional impairment
GRADING OF MYOCLONUS/ARM AND HAND FUNCTION	0	None	No myoclonus
	1	Mild	Rarely seen, 1-2 per day
	2	Moderate	Several times per day
	3	Severe	Several times per hour, interfering with function
GRADING OF ATAXIA/GAIT	0	None	Walking normal for age
	1	Mild	Mildly wide-based gait for age but able to walk independently
	2	Moderate	Walks with support from person or equipment
	3	Severe	Unable to walk even with support from person or equipment
GRADING OF ATAXIA/STANCE	0	None	No ataxia
	1	Mild	Mildly unstable standing for age, slightly wide-based
	2	Moderate	Unable to stand without support but can sit without support
	3	Severe	Unable to sit without support
GRADING OF MODO/SLEEP DISTURBANCE	0		Normal
	1		Wakes during the night, occasional outbursts
	2		Poor sleeping and/or irritability or anger/behavioral problems that interfere with daily life
	3		Severe impairment of function by sleep/mood problems

Fig. 1. OMS evaluation criteria (from Krug P. et al. [39]).

0 on the OMS severity score, it scored >0 again, and as clinical aggravation those cases with a worsening of ≥ 1 on the OMS score during more than a month.

The patients with suspicion of neurodevelopment troubles passed a neuropsychological test (WISC-IV or WISC-V) and if they had associated attentional problems, a DSM-IV for attention deficit hyperactivity disorder (ADHD).

We then performed a review of the literature and proposed a diagnostic algorithm based in our experience. Descriptive statistics were used to analysed our results and compared it with previously published data.

This study received approval from our local ethics committee.

3. Results

We identified 13 patients with OMS (Tables 1 and 2): 61.5% were male (n = 8), median age at diagnosis was 18 months (interquartile range (IR) = 76). The median time of treatment delay was 14 days (IR = 146) and median OMS score at onset was 8 (IR = 11). The median duration of follow-up was 1.33 years (IR = 9.08).

The two most frequent aetiologies (Fig. 2) were neuroblastoma (Patient 1, 3, 7, 10 and 11) and idiopathic OMS (Patient 2, 4, 6, 9 and 13) in 38.46% of the patients in either cause, followed by post-infectious (Patient 5, 8 and 12).

None of the patients from the tumour related OMS had metastasized neuroblastoma (stage IV) at diagnosis; 80% were located at the abdominal level; the diameters of the tumour masses varied between 9 and 57 mm, with only one patient having a tumour that exceeded 50 mm in diameter.

Three of the patients developed the OMS after an infectious process (acute otitis media, pharyngitis and gastroenteritis). However, the organism was only isolated in one of them (*Mycoplasma pneumoniae*).

A diabetic patient from the idiopathic group had anti-IA₂ antibodies, whose causal relationship with OMS is not clear, as it has not been previously described in the literature.

Ataxia was the most frequent initial symptom (10/13), and the only initial symptom in one of the patients (Fig. 3). Opsoclonus and behavioural disorders were the other two most frequent symptoms at onset (5/13), followed by myoclonus (4/13) and sleep disorders (3/13). In all the patients with a tumour, this one was diagnosed after the initiation of OMS.

In our series, the cervical-thoracic-abdominal CT-scan allowed the diagnosis of 4/5 neuroblastomas. While, the last one another one was diagnosed with a combination of abdominal ultrasound, mIBG-scintigraphy (metaiodobenzylguanidine-scintigraphy) and cervical MRI-scan. All the patients with neuroblastoma in our series had a pathologic mIBG, while four out of five had altered ultrasounds.

One patient exhibited a nonspecific frontal white matter subcortical lesion on brain MRI, and only two patients (one from the neuroblastoma group and another one from the post-infectious OMS group) presented altered CSF with pleocytosis without elevation of the proteins or oligoclonal bands.

One of the patients with neuroblastoma had urinary catecholamine (homovanilic and vanilmandelic acid) alterations, with pathologic mIBG. The other patient who presented with catecholamine elevation had a post-infectious etiology and his mIBG was normal.

All the patients received intravenous corticoids (mainly dexamethasone). Three refractory cases required adjuvant immunological treatment with rituximab (3/13), cyclophosphamide (1/13) and/or iv Ig (1/13). The five patients with neuroblastoma were operated and three of them (two with stage II [Patient 1 and 7] and one with stage III [Patient 3]) received chemotherapy with etoposide and carboplatin postsurgery. The patient 3 (stage III) also required treatment with adriamycin and vincristine pre-and post-surgery.

The median OMS score at the end of follow-up was 1 (IR = 3), and the most prevalent sequelae was ataxia (7/13), followed by new onset of

sleep disturbances (3/13), attention disorders (4/13), behavioural disorders (3/13), tremor (2/13) and visuocognitive apraxia (1/13). Of the eight patients who presented sequelae, all but one presented more than one symptom. Of these, five combined neurological and neuropsychological symptoms, while two had only neurological signs and another only had neuropsychological alterations.

We detected neurodevelopmental disorders in 38.46% (n = 5), mainly attention deficit disorder (n = 4) (DSM-IV criteria's). All of them except one passed neuropsychological studies (WISC-IV or WISC-V, Table 3), and attention deficit was the more frequent disorder (n = 4). Another patient did not meet criteria for ADHD but had an alteration at work memory and impulsivity. Intelligence quotient ranged from 72 to 80, with a mean of 77. It was not possible to interpret it in two of the patients due to attention problems. Four patients required school adaptation as well as adjuvant therapies (physical therapy, orthophony, orthoptist and/or psychomotor sessions).

Six of the patients, two from each group, achieved total remission (OMS score 0/15). Four of them were diagnosed in less than a week after the onset of symptoms, supporting the current data that early diagnosis and treatment are linked to a better prognosis [6]. Four cases (30.77%) had recurrence or clinical aggravation: three from the neuroblastoma group and one from the idiopathic OMS group. Two of them (patients with stage III neuroblastoma) had already reached an OMS score of 0 when their OMS relapsed. The other patient, with neuroblastoma related OMS, presented an aggravation of symptoms just one week after the surgical intervention. None of the patients developed tumour recurrence.

The two youngest patients of our series (8 and 11 months old) achieved complete remission.

The most refractory patient, who was diagnosed with idiopathic OMS, had no relevant variation from the initial OMS score, despite extensive work-up and complementary treatment.

4. Discussion

4.1. Pathophysiology and etiology

The pathophysiology of OMS is yet to be established; however, the involvement of the brain stem and cerebellum becomes increasingly evident. It has been hypothesized that omnipause neurons, burst neurons and the cerebellar fastigial nucleus are involved in the development of OMS [7,8].

Approximately 38% of our patients had neuroblastoma associated OMS, which is similar to the proportions described in the literature. The percentages of the rest of aetiologies (autoimmune, para-infectious or idiopathic) were more variable [2,4,6,9]. Refer to Table 4 for an overview of the main aetiologies per study.

a) Tumour

In this series, neuroblastoma was the only oncologic diagnosis, which is undoubtedly the most frequently related tumour to this syndrome in children [4,9]. In other case series, it is also the predominant tumour (up to 73%) related to OMS [9]. However, other neuroblastic-type tumours, such as ganglioneuroblastoma, have also been described, especially in the younger patients [6]. Other tumours that have been linked to OMS include Hodgkin lymphoma and rhabdoid skin tumour [6].

In rare cases OMS can also be diagnosed up to a month after the surgery of the neuroblastoma [6]. Contrary to this, in some cases the tumour can be diagnosed months or even years after the onset of the neurological symptomatology [4]. Therefore, in the absence of a clear etiology, some sources advise continuing to screen for neoplasia at least bi-annually for five years [4].

The proportion of patients diagnosed of neuroblastoma with associated OMS is between 1 and 4% [9–11], although in some series it rises to

Table 1

Characteristics of the patients. US: ultrasound; NA: not available; Blood: include ionogram; autoimmune profile, vitamin E, vitamin B₁₂, vitamin B₉, thyroid profile, hepatic profile, blood count, toxics, PCR virus multiplex and serologies.

	PATIENT 1	PATIENT 2	PATIENT 3	PATIENT 4	PATIENT 5	PATIENT 6
SEX	Female	Male	Male	Male	Male	Male
AGE AT DIAGNOSIS	18 months	8 months	18 months	18 months	35 months	21 months
OMS SCORE AT ONSET	6	9	8	7	12	15
EXAMENS	- Brain and spinal cord MRI: syringomyelia C4/5-T10/11.	- Brain and spinal cord MRI: frontal subcortical lesion in white substance.	- Brain and spinal cord MRI: normals.	- Brain CT: normal.	- Brain and spinal cord MRI: normals.	- Brain and spinal cord MRI: normal.
COMPLEMENTARYS	- Blood: normal. Ac N/A.	- Blood: normal.	- Blood: normal.	- Blood: normal. Ac N/A.	- Blood: normal.	- Blood: normal. Ac N/A.
	- CSF: normal	- CSF: normal.	- CSF: 20 cells/ μ l; prot N.	- CSF: N/A.	- CSF: 14 cells/ μ l; prot 0'5 mg/dl.	- CSF: N/A.
	- CT thoraco-abdominal: left supra-renal ganglioneuroblastoma.	- CT thoraco-abdominal: normal.	- CT thoraco-abdominal: left renal neuroblastoma.	- CT thoraco-abdominal: normal.	- CT thoraco-abdominal: normal.	- CT thoraco-abdominal: normal.
	- MIBG: pathologic.	- MIBG: normal.	- MIBG: pathologic.	- MIBG: normal.	- MIBG: normal.	- Catecholamines (urine): normal.
	- Catecholamines (urine): normetanephrine 0,869 μ mol	- Catecholamines (urine): normal.	- Catecholamines (urine): normal.	- Abdominal US: normal.	- Catecholamines (urine): normals.	- Catecholamines (urine): normal.
	- Abdominal US: pathologic.	- Abdominal US: normal.	- Abdominal US: normal.	- Abdominal US: normal.	- Abdominal US: normal.	- Abdominal US: normal.
NEUROBLASTOMA	Yes	No	Yes	No	No	No
ETIOLOGY	Neuroblastoma	Idiopathic	Neuroblastoma	Idiopathic	Post-infectious	Idiopathic
TREATMENT DELAY TIME	37 days	7 days	16 days	6 days	10 days	NA (<14d)
TYPE OF TREATMENT	- Dexamethasone 20mg/m ² x 3 days monthly during 1 year. Recurrence: reintroduction.	- Dexamethasone 20mg/m ² x 3 days monthly during 1 year	- Dexamethasone 20mg/m ² x 3 days monthly during 1 year.	- Dexamethasone 20mg/m ² x 3 days monthly during 1 year	- Dexamethasone 20mg/m ² x 3 days monthly during 1 year	- Dexamethasone 20 mg/m ² + Immunoglobulin iv 1 g/kg/d x 3 days monthly during 3 months then ...
	- Surgical intervention	- Surgical intervention	- Surgical intervention	- Surgical intervention	- Surgical intervention	- Cyclophosphamide 750 mg/m ² 6 months
	- Chemotherapy: 5 months	- Chemotherapy: 5 months	- Chemotherapy: 5 months	- Chemotherapy: 5 months	- Chemotherapy: 5 months	- Rituximab 375 mg/m ² : 2 doses weekly
	- Rituximab 375 mg/m ² : 2 doses weekly					
EVOLUTION	Good , behaviour disorder and attentional deficit	Complete improvement	Good , language development delay	Good , attentional deficit and sleep disorder	Good , attentional deficit.	Good , language delay, attentional deficit, behaviour and sleep disorder
OMS SCORE AT THE END	2	0	2	0	1	2
DURATION FOLLOW-UP	9.25 years	2.6 years	1.08 years	7.83 years	7.25 years	8.42 years
RECURRENCE	Relapse	No	Relapse	No	No	No
PATIENT 7	PATIENT 8	PATIENT 9	PATIENT 10	PATIENT 11	PATIENT 12	PATIENT 13
Female	Male	Male	Female	Female	Male	Female
18 months	11 months	84 months	18 months	33 months	72 months	23 months
10	8	4	12	9	6	8
- Brain and spinal cord MRI: right paravertebral cervical neuroblastoma.	- Brain and spinal cord MRI: normal.	- Brain and spinal cord MRI: normal.	- Brain and spinal cord MRI: normal.	- Brain and spinal cord MRI: normal.	- Brain and spinal cord MRI: normal.	- Brain, spinal cord and total body MRI: normal.
- Blood: normal. Ac N/A.	- Blood: normal.	- Blood: Ac anti IA2+.	- Blood: normal.	- Blood: normal.	- Blood: mycoplasma pneumoniae PCR and serology positives.	- CT thoraco-abdominal: doubtful right diaphragmatic mass.
- CSF: normal	- CSF: normal.	- CSF: normal.	- CSF: NA.	- CSF: NA.	- CSF: 19 cells/ μ l; prot N.	- Blood: normal.
- CT thoraco-abdominal: normal.	- CT thoraco-abdominal: normal.	- CT thoraco-abdominal: normal.	- CT thoraco-abdominal: right supra-renal neuroblastoma.	- CT thoraco-abdominal: pathologic.	- CSF: normal.	- CT thoraco-abdominal: normal.
- MIBG: pathologic.	- MIBG: normal.	- MIBG: normal.	- MIBG: pathologic.	- MIBG: pathologic.	- Catecholamines (urine): normal.	- MIBG: normal.
- Catecholamines (urine): normal.	- Catecholamines (urine): pathologic.	- Catecholamines (urine): normal.	- Catecholamines (urine): normal.	- Catecholamines (urine): normal.	- Catecholamines (urine): normal.	- Catecholamines (urine): normal.
- Cervical and abdominal US: pathologic.		- Abdominal US: normal.	- Abdominal US: pathologic.	- Abdominal US: pathologic.	- Abdominal US: normal.	- Abdominal US: normal.
Yes	No	No	Yes	Yes	No	No
Neuroblastoma	Post-infectious	Idiopathic	Neuroblastoma	Neuroblastoma	Post-infectious	Idiopathic
30 days	37 days	45 days	7 days	150 days	4 days	16 days
- Dexamethasone 20mg/m ² x 3 days monthly during 1 year.	- Dexamethasone 20mg/m ² x 3 days monthly during 1 year.	- Dexamethasone 20mg/m ² x 3 days: 7 cures	- Dexamethasone 20mg/m ² x 3 days monthly during 1 year.	- Dexamethasone 20mg/m ² x 3 days monthly during 1 year	- Dexamethasone 20mg/m ² x 3 days monthly during 3 months	- Dexamethasone 20mg/m ² x 3 days monthly during 3 months
- Surgical intervention		- Rituximab 375 mg/m ² 2 doses weekly: 2 times	- Surgical intervention	- Surgical intervention	- Prednisolone 100 mg/day x 3 days monthly during 9 months	
- Chemotherapy: 5 months		- Immunoglobulin iv 1 g/kg/d x 2 days: 6 cures				
Complete improvement	Complete improvement	Regular , ataxia and opsoclonus	Very good , ataxia and behavioural troubles	Complete improvement	Complete improvement	Very good , ataxia
0	0	3	2	0	0	1
6.5 years	1.30 years	1.04 years	1 years	1.33 years	0.66 years	0.17 years
No	No	Aggravation symptoms	Aggravation symptoms	No	No	No

Table 2
Summary of patient characteristics (n = 13).

CHARACTERISTICS	N = 13
SEX	
Female	61.5% (n = 8)
Male	38.5% (n = 5)
MEDIAN AGE AT DIAGNOSIS	18 months
INITIAL SYMPTOM	Ataxia (n = 10) Opsoclonus (n = 5) Behavioural disorders (n = 5) Myoclonus (n = 4) Sleep disorders (n = 3)
ETIOLOGY	-Neuroblastoma-associated OMS 38.46% (n = 5) -Idiopathic 38.46% (n = 5) -Post-infectious OMS (n = 3)
TREATMENT	-Corticosteroids (n = 13) -Surgical intervention (n = 5) -Adjunctive immune therapy (n = 3)
MEDIAN OMS SCORE AT THE END	1 (IR = 3)
PROGNOSIS	38.46% full recovery

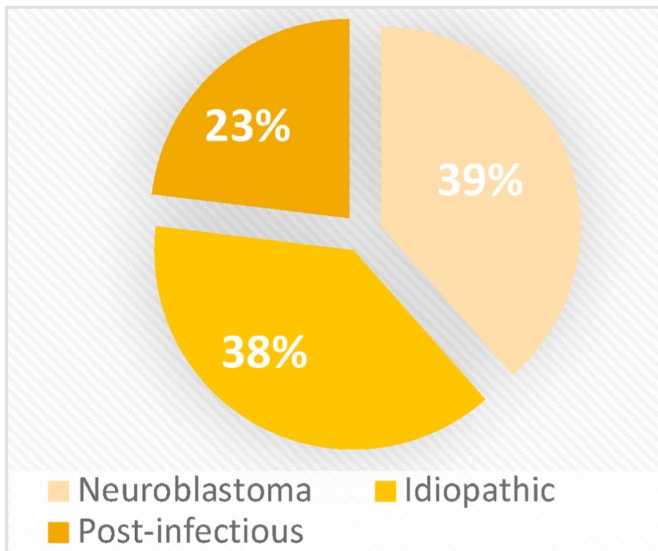


Fig. 2. OMS etiology in patients enrolled in the study.

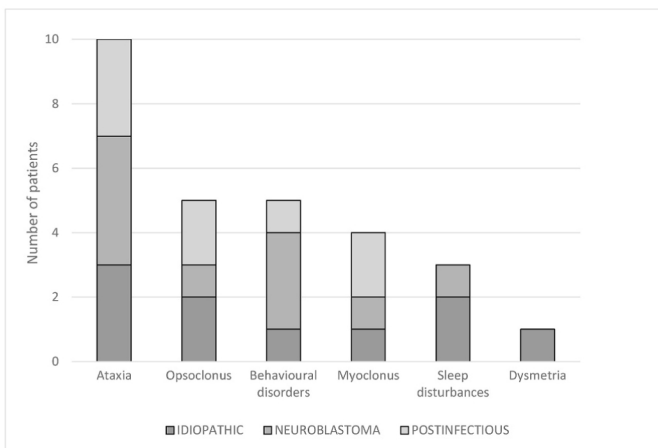


Fig. 3. Symptoms at onset in patients enrolled in the study in function of their etiology.

Table 3

Results of neuropsychological studies. VCI: verbal comprehension index; VSI: visual spatial index; FRI: fluid reasoning index; WMI: working memory index; PSI: processing speed index; IQ: intelligence quotient. NI: not interpretable ; NA : not available.

	VCI	VSI	FRI	WMI	PSI	IQ
PATIENT 1 (WISC-V)	84	72	74	82	86	72
PATIENT 4 (WISC-V)	70	67	67	82	83	NI
PATIENT 5 (WISC-IV)	86	84	82	91	103	NI
PATIENT 6 (WISC-IV)	NA	NA	NA	NA	NA	NA

6,8% [12]. Aligning with our results, >90% are diagnosed in early stage [9,10,13,14], being rare to diagnose at stage III or IV. Interestingly, Rudnick et al. [14] described that metastatic disease occurred in 10% of patients with neuroblastoma associated OMS, compared 35% of patients with neuroblastoma without OMS, which is probably related to an earlier diagnosis of the tumour facilitated by the neurological symptom onset.

The neuroblastomas associated with OMS are usually characterized by smaller size, potentially given the early diagnosis, with a diameter of less than 50 mm in 62% of cases [10]. Similarly, in our series 80% of cases had <50 mm tumour diameter.

The neuroblastoma is typically located at the abdominal level (66%) [10], specifically at the paravertebral or para-aortic level. None of the cases in our series had *N-myc* gene amplification, which is associated with a poor prognosis, advanced stage and aggressive behaviour. In fact, the prognosis of neuroblastomas associated with OMS is generally good [13,14].

The National Cancer Institute (NCI) established that the 5-year survival of neuroblastoma is inversely correlated with the age of onset, such that in children under 1 year it is 90% while in the age group from 5 to 9 years is 62% [15].

In the case of adults with OMS, the tumours are more varied, and may include ovarian teratoma [16,17], small cell lung cancer [18], breast cancer [19], serous ovarian cancer [20], among others.

b) Infectious

Although many viral and bacterial infectious agents linked to OMS have been identified (falciparum malaria [21], HIV [22], Epstein Barr virus [23], VVH6 [24], rotavirus [25], adenovirus [26], enterovirus 71²⁷, hepatitis C virus [28], mycoplasma [29], chikungunya virus [alone or in coinfection with dengue virus] [30], borrelia burgdorferi, rubella virus [6] ...), many times the germ is not isolated [4].

c) Autoimmune

The intracellular and surface antibodies directed against dendritic neuronal surface antigens of cerebellar granular neurons and brain stem neurons have been identified, without being always associated to a tumour, turning the OMS in a "cell surface autoantibody syndrome". In the literature, several cases of OMS and antiMa [3,31] antibodies have been described. Other antibodies identified in this syndrome include antiNMDA [32], anti-GAD/anti-GAD65 [9], anti γ -aminobutyric acid type B receptor (GABA_B R), anti-neuronal VG potassium channel [9] and anti α_3 -AChR Ab positivity nicotinic ganglionic acetylcholine autoantibody receptor [33]. The glutamate δ_2 -receptor (GluD₂) and the antiHu require a separate mention, since they are also described in patients with neuroblastoma without neurological symptoms. The antiHu antibodies have also been described in association with others tumours, such as lung cancer [34,35].

The presence of antibodies against the GABA receptor, and the

Table 4
Recap of principal studies. NA: not available.

STUDY	NUMBER OF PATIENTS (n)	FEATURES
Hasegawa et al. [3], <i>Brain and Development</i> (2015)	23	<u>Median onset age:</u> 16.5 months <u>Principal etiology:</u> tumour (43.5%) <u>Outcome:</u> sequelaes in 70%.
Muthusamy et al. [4], <i>Annals of Indian Academy of Neurology</i> (2019)	22	<u>Median onset age:</u> 20.9 months <u>Principal etiology:</u> tumour (50%) <u>Outcome:</u> sequelaes in 13.64%.
Achour N. et al. [6], <i>Brain and Development</i> (2017)	15	<u>Median onset age:</u> 51.84 months <u>Principal etiology:</u> tumour (46.67%) <u>Outcome:</u> sequelaes in 20%.
Pranzatelli et al. [9], <i>Frontiers in Neurology</i> (2017)	389	<u>Median onset age:</u> 18 months <u>Principal etiology:</u> tumour (50%) <u>Outcome:</u> NA
Plantaz et al. [10], <i>Archives de pédiatrie</i> (2000)	21	<u>Median onset age:</u> 18 months <u>Principal etiology:</u> tumour (100%) <u>Outcome:</u> sequelaes in 47.62%.
Koh et al. [13], <i>The Journal of Pediatrics</i> (1994)	10	<u>Median onset age:</u> 17.3 months <u>Principal etiology:</u> tumour (100%) <u>Outcome:</u> sequelaes in 90%.
Rudnick et al. [14], <i>Medicine Pediatric Oncology</i> (2001)	21	<u>Median onset age:</u> NA <u>Principal etiology:</u> tumour (100%) <u>Outcome:</u> sequelaes in 66.67%.
Krug et al. [38], <i>European Journal Paediatric Neurology</i> (2010)	34	<u>Median onset age:</u> 20.8 months <u>Principal etiology:</u> tumour (64.7%) <u>Outcome:</u> sequelaes in 52.9%.
Dale et al. [39], <i>Neurology</i> (2014)	32	<u>Median onset age:</u> 21.6 months <u>Principal etiology:</u> NA <u>Outcome:</u> sequelaes in 68.75%.
Tate et al. [43], <i>Journal of Pediatric Oncology Nursing</i> (2005)	105	<u>Median onset age:</u> 20.4 months <u>Principal etiology:</u> tumour (42%) <u>Outcome:</u> 77% sleep problems.
Tate et al. [45], <i>Proceedings of the 13th International Child Neurology Congress</i> (2014)	389	<u>Median onset age:</u> NA <u>Principal etiology:</u> NA <u>Outcome:</u> NA
Wilbur et al. [59], <i>Pediatric Blood Cancer</i> (2019)	15	<u>Median onset age:</u> 22 months <u>Principal etiology:</u> tumour (73.3%) <u>Outcome:</u> troubles of language in 46.67%.
Pranzatelli et al. [61], <i>Pediatrics Neurology</i> (2018)	32	<u>Median onset age:</u> NA <u>Principal etiology:</u> NA <u>Outcome:</u> NA
Pranzatelli et al. [62], <i>Neuropediatrics</i> (2018)	12	<u>Median onset age:</u> 40.8 months <u>Principal etiology:</u> tumour (83.3%)

Table 4 (continued)

STUDY	NUMBER OF PATIENTS (n)	FEATURES
Takama et al. [67], <i>European Journal Paediatric Surgery</i> (2016)	5	<u>Outcome:</u> 41.67% with learning problems <u>Median onset age:</u> 22 months <u>Principal etiology:</u> tumour (100%) <u>Outcome:</u> sequelaes in 40%.
Brunklaus et al. [69], <i>Pediatrics</i> (2011)	101	<u>Median onset age:</u> 18 months <u>Principal etiology:</u> 56% postinfectious <u>Outcome:</u> sequelaes in 66%.
Pranzatelli et al. [70], <i>Journal of Neuroimmunology</i> (2018)	208	<u>Median onset age:</u> NA <u>Principal etiology:</u> NA <u>Outcome:</u> NA
Pranzatelli et al. [71], <i>Pediatric Blood and Cancer</i> (2018)	356	<u>Median onset age:</u> 20.4 and 25.2 months <u>Principal etiology:</u> tumour (48.59%) <u>Outcome:</u> NA

improvement observed in certain patients after the use of GABAergic substances such as benzodiazepines, suggests a possible implication of this pathway in the pathophysiology of OMS [36,37].

4.2. Symptoms and OMS scale at onset

Similar to what is reported in the literature [4,6,9], ataxia was the principal symptom at onset in this series, detected in 76.9% of patients at onset (in one of them it was the only symptom at onset). In fact, the principal differential diagnosis of OMS in the initial stages includes cerebellitis, especially if an infection precedes.

Although opsoclonus is one of the characteristic and frequent symptoms (up to 86.67% according to certain series [6]), it was absent at onset in 61.53% of our patients. Despite this, it was still the second most frequent symptom along with the behavioural disorders (38.46%). In some series, language disorders were detected in 100% and 73% in young children and young adults, respectively, as well as vocabulary problems in 89% and 33%, respectively [9], during the acute phase.

Myoclonus was only present at diagnosis in 30.8% of our patients. The interval time of appearance varied from the beginning to six months [6,39] and not all the patients present with all the symptoms.

According to one study [4], time lapse between onset of opsoclonus and the other symptoms, seems be shorter in patients with tumour associated OMS. Many parents reported prodromal symptoms in the weeks prior to OMS diagnosis, of which irritability is the most prevalent (60%) [9]. Other symptoms such as dysarthria, hypersialorrhea, dyspnoea or dysphagia for liquids may appear in later stages around 20% of the times [9].

The OMS onset varied from 3 to 12 (median 8, IR = 11) in this series, while in the other series it ranges between 9 and 12 [4,6,21].

4.3. Diagnostic delay

The median time to diagnosis was 14 days (IR= IR=146) in this series, which is in line (or improved) with other recent studies [6,40–42]. Pranzatelli et al. made a comparison of the delay of the diagnostic time of his series in 2005 [43] versus 2017, demonstrating that the average time decreased from 2.8 months to 1.2 months [9], probably due to an improvement in diagnostic techniques and a greater knowledge of pathology.

4.4. Relapses

The percentage of relapses varies according to the publications, ranging from 41% to 90% [13,43–46]. In the study by Tate et al. [45], the risk of recurrence after a first or second relapse was estimated at 47% and 35% after a third relapse. Logically, more than three relapses seem to have a worse prognosis and a lower probability of complete resolution than the others [4].

The published studies that used ACTH [13,46] as treatment had the highest recurrence rates, reaching up to 91%.

4.5. Diagnosis (see Table 5)

A) Imaging

A patient in our series required a combination of abdominal ultrasound, mIBG-scintigraphy and cervical MRI-scan for the diagnosis of a tumour, which highlights the importance of multimodal imaging techniques for tumour detection.

Due to its sensitivity and specificity, mIBG scintigraphy is used as a screening technique for the detection of the primary tumour, as well as possible lymph node or metastatic involvement in patients with suspected neuroblastic tumours [47–50]. mIBG is labelled with iodine radioisotopes, most commonly with ¹²³I, which is also used in our hospital. The sensitivity of the test has been described to be between 69 and 90⁴,^{47,51}. Higher risk of false negative is linked to the presence of low-grade, non-secreting small neuroblastomas [52], those located at the hepatic level (due to the relatively high and heterogeneous physiological uptake of mIBG), basal lung (close to the diaphragm due to the breathing artefact) or brain. The use of chemotherapy may cause necrosis in areas of the neuroblastoma and transform lesions that were previously mIBG-positive to mIBG-negative [53]. False positives have also been

reported, which can lead to unnecessary surgeries [9].

The most sensitive techniques for detecting neuroblastoma in children with OMS are the CT and MRI. In some cases, ultrasound and scintigraphy did not allow the diagnosis, whereas MRI of whole body was able to detect millimetric neuroblastic lesions [52,54] and define the tumour characteristics and degree of malignancy (the neuroblastoma frequently demonstrates diffusion restriction given its high cellular density) [52,55].

In one study [51], a sensitivity of 86% and 99%, and a specificity of 85% and 95% was detected for full-body MRI and for combined MRI and scintigraphy, respectively. A study carried out in 2014 [56] showed the non-inferiority of (18)-F-FDG PET/MRI compared to whole-body (18)-F-FDG PET/CT for paediatric tumour detection, providing the benefit of less radiation.

On the other hand, similar to what we have reported in our series, the brain image is usually normal. However, a particularly marked atrophy at the level of the vermis and the focculonodular lobes or at the cerebral cortex, may be linked to symptom persistence [4,57,58].

B) Urinary catecholamines and blood analytics

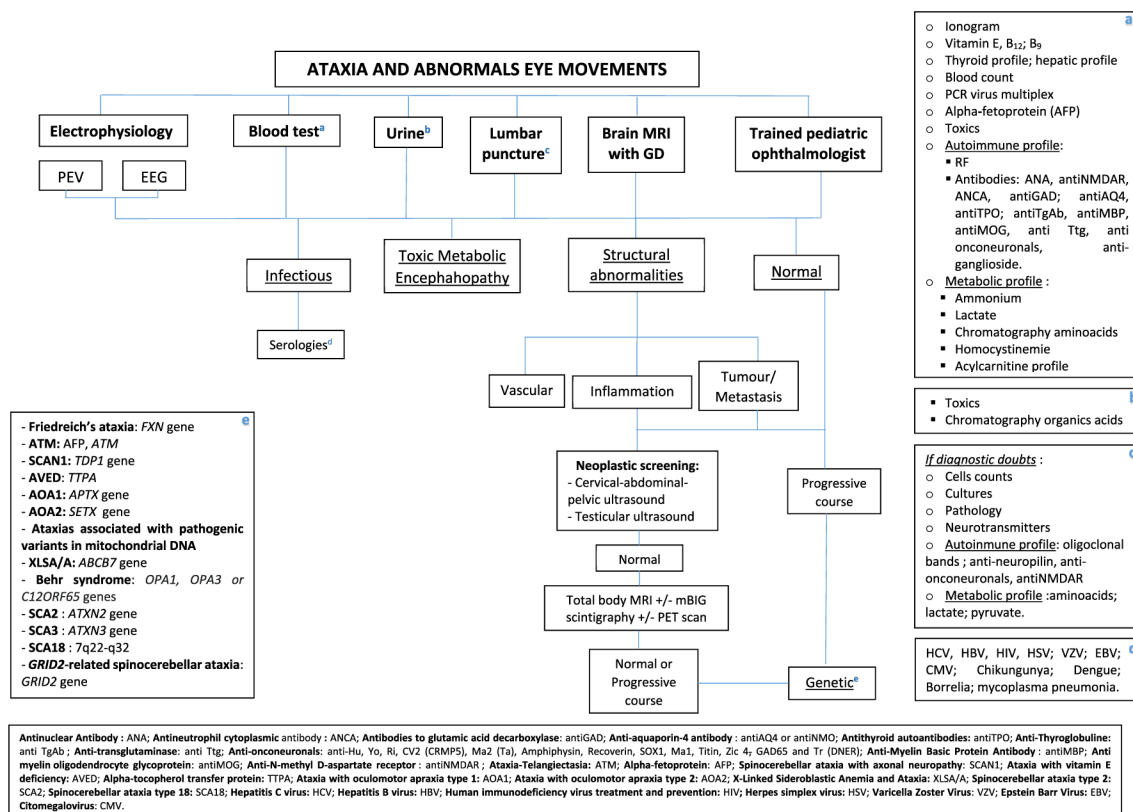
Catecholamines can be elevated in secretory tumours; however, similar to what has been described in this series, their values are often normal (positive below 43%) [4,10].

The neuron specific enolase can serve as a marker. Its levels are correlated with the stage of the tumour and with its remission [6].

C) Lumbar puncture and CSF analysis

CSF analysis did not provide any useful information in this series (it was inflammatory in two cases). Patients with OMS will frequently present with a normal CSF or lymphocyte-predominant pleocytosis [9].

Table 5
Proposal of diagnostic algorithm.



These findings raise the question of the utility of performing a lumbar puncture if there is no other diagnostic doubt (i.e. infection).

4.6. Treatment

In our centre the combination of dexamethasone, cyclophosphamide and/or rituximab is standard of care depending on the clinical response, following the protocol of a phase III single arm clinical trial (Multinational European Trial for Children with the Opsoclonus Myoclonus Syndrome/Dancing Eye Syndrome; NCT01868269). In this series all the patients diagnosed with tumours received at least corticosteroids, given that only on rare occasions surgery for tumour excision by itself is sufficient to resolve the paraneoplastic syndrome [10,16]. None of the patients that underwent surgery developed permanent postsurgical damage, but Claude Bernard Horner syndrome, reflex sympathetic dystrophy of one leg, and scoliosis have been described [9].

To date, the treatments used to treat OMS are diverse, and although there are different proposed protocols [3,4,6,27], there is unanimity regarding the early and incisive use of drugs directed against the immune system. The therapeutic strategies described in the literature include ACTH, iv immunoglobulins, methylprednisolone, oral prednisolone, dexamethasone, rituximab, azathioprine, mycophenolate mofetil, cyclophosphamide, autologous hematopoietic transplantation and/or plasmapheresis [9,31,59–64].

A study from the National Pediatric Myoclonus Center and National Pediatric Neuroinflammation Organization, compared the efficiency of Rituximab at low-dose (300 mg/m²) versus standard dose (375 mg/m²). They demonstrated a comparable clinical effectiveness and tolerability, with fewer expected long-term adverse events in the low-dose group. The benefit that ACTH seems to provide with respect to oral corticosteroids is the elevation of cortisol levels in CSF. In fact, methylprednisolone can be less effective (even pulsed) for OMS than pulsed dexamethasone. A retrospective study conducted by the Pediatric Oncology Group institutions raised the possibility that adjuvant treatment with chemotherapy may decrease the probability of developing long-term neurological damage. Plasmapheresis has also been reported as a successful treatment option in a refractory case.

There is currently an active study that seeks to evaluate the response and duration of autologous peripheral blood stem cell transplant for neurologic autoimmune diseases (NCT00716066). Other studies propose new therapeutic targets, such as the use of insulin-like growth factor 1 (IGF-1)/phosphoinositide 3-kinase (PI3K) [65] or of Ofatumumab, a monoclonal anti-CD20 antibody, which in combination with methotrexate, has been useful in a refractory patient with neuroblastoma-associated OMS and anti-Hu [66].

4.7. Outcome

Five of the patients from our series exhibited neurodevelopmental disorders on follow-up, a sequelae that has been described in 34–70% according to other series [3,6,10]. A study comparing the group of tumour associated OMS versus non-tumour associated OMS, detected that behavioural disturbances and sleep disorders were more frequent in the non-tumour group [68].

5. Conclusions

In our series, an OMS score of ≥ 10 and age > 1 year at onset were apparently correlated with a higher risk of aftermaths: the patients younger than 12 months didn't developed long-term sequelae, while the three patients with an OMS score > 10 at the onset did. These findings are similar to what has been reported in other studies. We detected a probable better prognosis in the post-infectious OMS, with full recovery in 2/3 of patients.

A significant delay in diagnosis has also been described as a poor prognostic factor. Although there is controversy to establish a critical

time-line delay, other studies have suggested a range of two to 12 months^{3,4,74}.

In our series, we detected a shorter time to initial diagnosis and the beginning of the treatment, as well as a low recurrence rate (30.77%), compared to other case series. The proportion of patients with developmental disorders in our series ranged between the 34–70% [3,6,10], similar to what is described in the literature. However, we detected a higher incidence of attention deficit (30.8%), without clear correlation with the OMS etiology. An early clinical suspicion seems key to maximize response of treatment and clinical improvement. The use of aggressive immunomodulatory therapies not only allows the syndrome to be controlled more effectively and quickly, but may also prevent the development of long-term neurological damage^{9,38,40,42,75}.

One of the main limitations of our case series is the small sample size and its mainly descriptive nature. A strength of our study is the fact that all the patients have been treated in the same centre, having applied the same criteria and protocols, with minimal changes.

Based on our experience and literature review, we propose a diagnostic algorithm for those patients presenting with eye movements and ataxia (Table 5).

Declaration of competing interest

No one.

References

- [1] M. Kinsbourne, Myoclonic encephalopathy of infants, *J. Neurol. Neurosurg. Psychiatry* 25 (3) (1962) 271–276, <https://doi.org/10.1136/jnnp.25.3.271>.
- [2] F. Blaes, B. Dharmalingam, Childhood opsoclonus-myoclonus syndrome: diagnosis and treatment, *Expert Rev. Neurother.* 16 (6) (2016) 641–648, <https://doi.org/10.1080/14737175.2016.1176914>.
- [3] S. Hasegawa, T. Matsushige, M. Kajimoto, H. Inoue, H. Momonaka, M. Oka, et al., A nationwide survey of opsoclonus-myoclonus syndrome in Japanese children, *Brain Dev.* 37 (2015) 656–660, <https://doi.org/10.1016/j.braindev.2014.10.010>.
- [4] K. Muthusamy, M. Thomas, S. Yoganathan, S.V. Sudhakar, Clinical profile, prognostic indicators, and therapeutic outcomes of pediatric opsoclonus-myoclonus-ataxia syndrome: a single-center experience from South India, *Ann. Indian Acad. Neurol.* 22 (3) (2019) 295–301, https://doi.org/10.4103/aian.AIAN_101_18.
- [5] K. Ki Pang, C. de Sousa, B. Lang, M.G. Pike, A prospective study of the presentation and management of dancing eye syndrome/opsoclonus-myoclonus syndrome in the United Kingdom, *Eur. J. Paediatr. Neurol.* 14 (2010) 156–161, <https://doi.org/10.1016/j.ejpn.2009.03.002>.
- [6] N. Achour, S. Mrabet, I. Rebai, I. Abid, H. Benrhouma, H. Klaa, A. Rouissi, I. Kraoua, I. Turki, Childhood Opsoclonus–Myoclonus Syndrome: A Case Series from Tunisia, *Brain and Development*, 2017, p. 39, <https://doi.org/10.1016/j.braindev.2017.05.001>.
- [7] A.M. Wong, S. Musallam, R.D. Tomlinson, P. Shannon, J.A. Sharpe, Opsoclonus in three dimensions: oculo-graphic, neuropathologic and modelling correlates, *J. Neurol. Sci.* 189 (1–2) (2001 Aug 15) 71–81.
- [8] S. Ramat, R.J. Leigh, D.S. Zee, L.M. Optican, What clinical disorders tell us about the neural control of saccadic eye movements, *Brain* 130 (Pt 1) (2007 Jan) 10–35.
- [9] M.R. Pranzatelli, E.D. Tate, N.R. McGee, Demographic, clinical, and immunologic features of 389 children with opsoclonus-myoclonus syndrome: a cross-sectional study, *Front. Neurol.* 8 (2017) 468, <https://doi.org/10.3389/fneur.2017.00468>. Published 2017 Sep. 11.
- [10] D. Plantaz, J. Michon, D. Valteau-Couanet, C. Coze, et al., Opsoclonus-myoclonus syndrome associated with non-metastatic neuroblastoma. Long term survival, *Study French Soc. Pediatric Oncologists Arch Pediatr* 7 (2000) 621–628.
- [11] H. Rubie, O Hartmann, J. Michon, D. Frappaz, C. Coze, P. Chastagner, et al., N-Myc gene amplification is a major prognostic factor in localized neuroblastoma: results of the French NBL 90 study, *J. Clin. Oncol.* 15 (1997) 1171–1182.
- [12] Y. Takama, A. Yoneda, T. Nakamura, et al., Early detection and treatment of neuroblastic tumor with opsoclonus-myoclonus syndrome improve neurological outcome: a review of five cases at a single institution in Japan, *Eur. J. Pediatr. Surg.* 26 (1) (2016) 54–59, <https://doi.org/10.1055/s-0035-1564714>.
- [13] P.S. Koh, J.G. Raffensperger, S. Berry, M.B. Larsen, H.S. Johnstone, P. Chou, S. R. Luck, M. Hammer, S.L. Cohn, Long-term outcome in children with opsoclonus-myoclonus and ataxia and coincident neuroblastoma, *J. Pediatr.* 125 (5) (1994) 712–716.
- [14] E. Rudnick, Y. Khakoo, N.L. Antunes, et al., Opsoclonus-myoclonus ataxia syndrome in neuroblastoma: clinical outcome and anti-neuronal antibodies—a report from the Children's Cancer Group Study, *Med. Pediatr. Oncol.* 36 (2001) 612–622.
- [15] PDQ Pediatric Treatment Editorial Board, Neuroblastoma treatment (PDQ®): health professional version, in: PDQ Cancer Information Summaries, National Cancer Institute (US), Bethesda (MD), 2002–2017.

- [16] C. Park, I. Aljabban, J.C. Fanburg-Smith, C. Grant, M. Moore, Pediatric whole body MRI detects causative ovarian teratoma in opsoclonus myoclonus syndrome, *Radiol. Case Rep.* 15 (3) (2019) 204–209, <https://doi.org/10.1016/j.radcr.2019.11.010>. Published 2019 Dec 19.
- [17] Michael R. Pranzatelli Elizabeth D. Tate Nathan R. McGee Multifactorial Analysis of Opsoclonus-Myoclonus Syndrome Etiology (“Tumor” vs. “No Tumor”) in a Cohort of 356 US Children DOI: 10.1002/pbc.27097.
- [18] S. Ohara, N. Iijima, K. Hayashida, T. Oide, S. Katai, Autopsy case of opsoclonus-myoclonus-ataxia and cerebellar cognitive affective syndrome associated with small cell carcinoma of the lung, *Mov. Disord.* 22 (9) (2007) 1320–1324, <https://doi.org/10.1002/mds.21326>.
- [19] L. Martins, D. Galvão, A. Silva, et al., Paraneoplastic opsoclonus-myoclonus syndrome as a rare presentation of breast cancer, *J. Surg. Case Rep.* 2019 (2) (2019) rjy365, <https://doi.org/10.1093/jscr/rjy365>. Published 2019 Feb 8.
- [20] K.T. Stewart, J.S. Lee, G. Stuart, Paraneoplastic opsoclonus-myoclonus syndrome as a presentation of high grade serous ovarian cancer, *Gynecol. Oncol. Rep.* 30 (2019), 100511, <https://doi.org/10.1016/j.gore.2019.100511>. Published 2019 Nov 21.
- [21] K. Bose, S. Saha, M.R. Islam, C. Chakraborty, M. Laskar, Opsoclonus myoclonus ataxia syndrome due to falciparum malaria in two Indian children, *Indian J. Ophthalmol.* 64 (11) (2016) 852–854, <https://doi.org/10.4103/0301-4738.195611>.
- [22] N.M. Pereira, I. Shah, S. Kulkarni, Opsoclonus-myoclonus-ataxia syndrome in an HIV-infected child, *Oxf. Med. Case Rep.* 2016 (10) (2016), <https://doi.org/10.1093/omcr/omw077>. Published 2016 Oct 1.
- [23] T.M. Cardesa-Salzmann, J. Mora, M.A. Garcia Cazorla, O. Cruz, C. Munoz, J. Campistol, Epstein-Barr virus related opsoclonus-myoclonus-ataxia does not rule out the presence of occult neuroblastoma, *Pediatr. Blood Cancer* 47 (7) (2006) 964–967, <https://doi.org/10.1002/pbc.20573>.
- [24] T. Simon, E. Cheuret, L. Fiedler, C. Mengelle, E. Baudou, K. Deiva, Acute transverse myelitis following an opsoclonus-myoclonus syndrome: an unusual presentation, *Eur. J. Paediatr. Neurol.* 22 (5) (2018) 878–881, <https://doi.org/10.1016/j.ejpn.2018.05.002>.
- [25] E. Gurkas, K. Gucuyener, Y. Yilmaz, C. Havalı, E. Demir, Opsoclonus-myoclonus syndrome following rotavirus gastroenteritis, *Pediatr. Int.* 56 (6) (2014) e86–e87, <https://doi.org/10.1111/ped.12433>.
- [26] S. Syrbe, A. Merckenschlager, M.K. Bernhard, J. Grosche, U.G. Liebert, W. Hirsch, et al., Opsoclonus-myoclonus syndrome after adenovirus infection, *SpringerPlus* 4 (2015) 636, <https://doi.org/10.1186/s40064-015-1429-1>.
- [27] A. Sahly, L. Gauquelin, G. Sèbire, Rapid resolution of enterovirus 71-associated opsoclonus myoclonus syndrome on intravenous immunoglobulin, *Child Neurol. Open* 4 (2017), 2329048X17733215.
- [28] V. Ertekin, H. Tan, Opsoclonus-myoclonus syndrome attributable to hepatitis C infection, *Pediatr. Neurol.* 42 (6) (2010) 441–442, <https://doi.org/10.1016/j.pediatrneurol.2010.02.009>.
- [29] J. Chemli, S. Ketata, A. Dalhoumi, H. Ajmi, S. Hassayoun, I. Fodha, et al., Opsoclonus-myoclonus syndrome associated with *Mycoplasma pneumoniae* infection], *Arch. Pediatr.* 14 (8) (2007) 1003–1006, <https://doi.org/10.1016/j.arcped.2007.04.010>.
- [30] M.S. Do Rosário, M. Giovanetti, P.A.P. de Jesus, et al., Opsoclonus-myoclonus-ataxia syndrome associated with chikungunya and dengue virus co-infection, *Int. J. Infect. Dis.* 75 (2018) 11–14, <https://doi.org/10.1016/j.ijid.2018.07.019>.
- [31] S. Mrabet, N.B. Achour, I. Kraoua, et al., Anti-Ma2-encephalitis in a 2 year old child: a newly diagnosed case and literature review, *Eur. J. Paediatr. Neurol.* 19 (2015) 737–742.
- [32] B. Player, M. Harmelink, B. Bordini, M. Weisgerber, M. Girolami, M. Croix, Pediatric opsoclonus-myoclonus-ataxia syndrome associated with anti-N-methyl-D-aspartate receptor encephalitis, *Pediatr. Neurol.* 53 (5) (2015) 456–458, <https://doi.org/10.1016/j.pediatrneurol.2015.07.010>.
- [33] J.R. Galli, S.L. Clardy, M.M. Paz Soldán, Adult-onset opsoclonus-myoclonus syndrome associated with ganglionic acetylcholine receptor autoantibody, *Neurol.* 21 (6) (2016) 99–100, <https://doi.org/10.1097/NRL.0000000000000098>.
- [34] G. Berridge, D.A. Menassa, T. Moloney, et al., Glutamate receptor $\delta 2$ serum antibodies in pediatric opsoclonus myoclonus ataxia syndrome, *Neurology* 91 (8) (2018) e714–e723, <https://doi.org/10.1212/WNL.0000000000006035>.
- [35] J.A. Panzer, R. Anand, J. Dalmau, D.R. Lynch, Antibodies to dendritic neuronal surface antigens in opsoclonus myoclonus ataxia syndrome, *J. Neuroimmunol.* 286 (2015 Sep 15) 86–92.
- [36] P.G. Blain, S. Nightingale, J.C. Stoddart, Strychnine poisoning: abnormal eye movements, *J. Toxicol. Clin. Toxicol.* 19 (2) (1982 Apr) 215–217.
- [37] V.K. Paliwal, S. Chandra, R. Verma, J. Kalita, U.K. Misra, Clonazepam responsive opsoclonus myoclonus syndrome: additional evidence in favour of fastigial nucleus disinhibition hypothesis? *J. Neural. Transm.* 117 (5) (2010 May) 613–615.
- [38] P. Krug, G. Schleiermacher, J. Michon, D. Valteau-Couanet, H. Brise, M. Peuchmaur, et al., Opsoclonus-myoclonus in children associated or not with neuroblastoma, *Eur. J. Paediatr. Neurol.* 14 (5) (2010), <https://doi.org/10.1016/j.ejpn.2009.12.005>, 400–9.
- [39] R.C. Dale, F. Brilot, L.V. Duffy, M. Twilt, A.T. Waldman, S. Narula, et al., Utility and safety of rituximab in pediatric autoimmune and inflammatory CNS disease, *Neurology* 83 (2) (2014) 142–150, <https://doi.org/10.1212/WNL.0000000000000570>.
- [40] A. Galstyan, C. Wilbur, K. Selby, J. Hukin, Opsoclonus-myoclonus syndrome: a new era of improved prognosis? *Pediatr. Neurol.* 72 (2017) 65–69, <https://doi.org/10.1016/j.pediatrneurol.2017.03.011>.
- [41] Y. Takama, A. Yoneda, T. Nakamura, T. Nakaoka, A. Higashio, K. Santo, et al., Early detection and treatment of neuroblastic tumor with opsoclonus myoclonus syndrome improve neurological outcome: a review of five cases at a single institution in Japan, *Eur. J. Pediatr. Surg.* 26 (1) (2016) 54–59, <https://doi.org/10.1055/s-0035-1564714>.
- [42] W.G. Mitchell, A.A. Wooten, S.H. O’Neil, J.G. Rodriguez, R.E. Cruz, R. Wittner, Effect of increased immunosuppression on developmental outcome of opsoclonus myoclonus syndrome (OMS), *J. Child Neurol.* 30 (8) (2015) 976–982, <https://doi.org/10.1177/0883073814549581>.
- [43] E.D. Tate, T.J. Allison, M.R. Pranzatelli, S.J. Verhulst, Neuroepidemiologic trends in 105 cases of pediatric opsoclonus-myoclonus syndrome, *J. Pediatr. Oncol. Nurs.* 22 (1) (2005) 8–19, <https://doi.org/10.1177/1043454204272560>.
- [44] M.R. Pranzatelli, E.D. Tate, Corrigendum to “dexamethasone, intravenous immunoglobulin, and rituximab combination immunotherapy for pediatric opsoclonus-myoclonus syndrome”, *Pediatr. Neurol.* 73 (2017) 48–56, <https://doi.org/10.1016/j.pediatrneurol.2017.10.002>. *Pediatr. Neurol.* 2018; 78:84.
- [45] E.D. Tate, N.M. McGee, M.R. Pranzatelli, Clinical and demographic features of 389 children with OMS: an International Cohort, in: *Proceedings of the 13th International Child Neurology Congress, Iguazu Falls, Brazil, May 4–9, 2014. JICNA 1(Suppl. 1):27 (FP79), 2014.*
- [46] K.R. Pohl, J. Pritchard, J. Wilson, Neurological sequelae of the dancing eye syndrome, *Eur. J. Pediatr.* 155 (1996) 237–244.
- [47] G. Bleeker, G.A. Tytgat, J.A. Adam, H.N. Caron, L.C. Kremer, L. Hoof, et al., 123IMIBG scintigraphy and 18F-FDG-PET imaging for diagnosing neuroblastoma, *Cochrane Database Syst. Rev.* (9) (2015). CD009263. 10.
- [48] M.T. Parisi, R.S. Hattner, K.K. Matthay, B.O. Berg, E.D. Sandler, Optimized diagnostic strategy for neuroblastoma in opsoclonus-myoclonus, *J. Nucl. Med.* 34 (11) (1993) 1922–1926. 11.
- [49] S.E. Sharp, A.T. Trout, B.D. Weiss, M.J. Gelfand, MIBG in neuroblastoma diagnostic imaging and therapy, *Radiographics* 36 (1) (2016) 258–278. 12.
- [50] T.A. Vik, T. Pfluger, R. Kadota, V. Castel, M. Tulchinsky, J.C. Farto, et al., 123I-mIBG scintigraphy in patients with known or suspected neuroblastoma: results from a prospective multicenter trial, *Pediatr. Blood Cancer* 52 (7) (2009) 784–790.
- [51] T. Pfluger, C. Schmied, U. Porn, G. Leinsinger, C. Vollmar, S. Dresel, et al., Integrated imaging using MRI and 123I metaiodobenzylguanidine scintigraphy to improve sensitivity and specificity in the diagnosis of pediatric neuroblastoma, *AJR Am. J. Roentgenol.* 181 (4) (2003) 1115–1124.
- [52] C. Storz, R. Bares, M. Ebinger, R. Handgretinger, I. Tsiglikas, J.F. Schäfer, Diagnostic value of whole-body MRI in Opsoclonus-myoclonus syndrome: a clinical case series (3 case reports), *BMC Med. Imag.* 19 (1) (2019) 70, <https://doi.org/10.1186/s12880-019-0372-y>. Published 2019 Aug 20.
- [53] Z. Bar-Sever, L. Blassoni, B. Shulkun, et al., Guidelines on nuclear medicine imaging in neuroblastoma, *Eur. J. Nucl. Med. Mol. Imag.* 45 (11) (2018) 2009–2024, <https://doi.org/10.1007/s00259-018-4070-8>.
- [54] A. Brunklaus, K. Pohl, S.M. Zuberi, C. de Sousa, Investigating neuroblastoma in childhood opsoclonus myoclonus syndrome, *Arch. Dis. Child.* 97 (2012) 461–463.
- [55] M. C. Althoefer, U. Kontny, K. Il’yasov, M. Buchert, M. Langer, MRI diffusion imaging of neuroblastomas: first results and correlation to histology, *Eur. Radiol.* 12 (9) (2002) 2335–2338.
- [56] J.F. Schäfer, S. Gattidis, H. Schmidt, B. Guckel, I. Bezrukov, C.A. Pfannenberger, et al., Simultaneous whole-body PET/MR imaging in comparison to PET/CT in pediatric oncology: initial results, *Radiology* 273 (1) (2014) 220–231.
- [57] A.M. Chekroud, G. Anand, J. Yong, M. Pike, H. Bridge, Altered functional brain connectivity in children and young people with opsoclonus myoclonus syndrome, *Dev. Med. Child Neurol.* 59 (2017) 98–104.
- [58] G. Anand, H. Bridge, P. Rackstraw, A.M. Chekroud, J. Yong, C.J. Stagg, et al., Cerebellar and cortical abnormalities in paediatric opsoclonus myoclonus syndrome, *Dev. Med. Child Neurol.* 57 (2015) 265–272.
- [59] C. Wilbur, C. Yea, C. Licht, M.S. Irwin, E.A. Yeh, An upfront immunomodulatory therapy protocol for pediatric opsoclonus-myoclonus syndrome, *Pediatr. Blood Cancer* 66 (8) (2019), e27776, <https://doi.org/10.1002/pbc.27776>.
- [60] J.E. Greensher, J. Louie, J.D. Fish, Therapeutic plasma exchange for a case of refractory opsoclonus myoclonus ataxia syndrome, *Pediatr. Blood Cancer* 65 (2) (2018 Feb), <https://doi.org/10.1002/pbc.26819>.
- [61] M.R. Pranzatelli, E.D. Tate, N.R. McGee, C.A. MacArthur, Evaluation of responsiveness to reduced-dose rituximab in corticotropin/intravenous immunoglobulin/rituximab combination immunotherapy for opsoclonus-myoclonus syndrome, *Pediatr. Neurol.* 85 (2018) 71–75, <https://doi.org/10.1016/j.pediatrneurol.2018.05.003>.
- [62] M.R. Pranzatelli, E.D. Tate, M. Alber, et al., Rituximab, IVIg, and tetracosactide (ACTH1–24) combination immunotherapy (“RITE-CT”) for pediatric opsoclonus-myoclonus syndrome: immunomarkers and clinical observations, *Neuropediatrics* 49 (2) (2018) 123–134, <https://doi.org/10.1055/s-0037-1609038>.
- [63] M.R. Pranzatelli, E.D. Tate, Trends and tenets in relapsing and progressive opsoclonus-myoclonus syndrome, *Brain Dev.* 38 (5) (2016) 439–448, <https://doi.org/10.1016/j.braindev.2015.11.007>.
- [64] D.L. Johnston, S. Murray, M.S. Irwin, J. Doyle, T. Schechter, Autologous stem cell transplantation for refractory opsoclonus myoclonus ataxia syndrome, *Pediatr. Blood Cancer* 65 (8) (2018), e27110, <https://doi.org/10.1002/pbc.27110>.
- [65] X. Ding, W. Han, J. Wang, et al., IGF-1 alleviates serum IgG-induced neuronal cytolysis through PI3K signaling in children with opsoclonus-myoclonus syndrome and neuroblastoma, *Pediatr. Res.* 85 (6) (2019 May) 885–894, <https://doi.org/10.1038/s41390-018-0251-1>.
- [66] T.G. Ketterl, Y.H. Messinger, D.R. Niess, E. Gilles, W.K. Engel, J.L. Perkins, Ofatumumab for refractory opsoclonus-myoclonus syndrome following treatment of neuroblastoma, *Pediatr. Blood Cancer* 60 (12) (2013 Dec) E163–E165.
- [67] Y. Takama, A. Yoneda, T. Nakamura, et al., Early detection and treatment of neuroblastic tumor with opsoclonus-myoclonus syndrome improve neurological

outcome: a review of five cases at a single institution in Japan, *Eur. J. Pediatr. Surg.* 26 (1) (2016) 54-59, <https://doi.org/10.1055/s-0035-1564714>.

- [68] C. Russo, S.L. Cohn, M.J. Petruzzi, P.A. de Alarcon, Long-term neurologic outcome in children with opsoclonus-myoclonus associated with neuroblastoma: a report from the Pediatric Oncology Group, *Med. Pediatr. Oncol.* 28 (4) (1997) 284-288, [https://doi.org/10.1002/\(sici\)1096-911x\(199704\)28:4<284::aid-mpo7>3.0.co;2-e](https://doi.org/10.1002/(sici)1096-911x(199704)28:4<284::aid-mpo7>3.0.co;2-e).
- [69] A. Brunklaus, K. Pohl, S.M. Zuberi, C. de Sousa, Outcome and prognostic features in opsoclonus-myoclonus syndrome from infancy to adult life, *Pediatrics* 128 (2) (2011) e388–e394, <https://doi.org/10.1542/peds.2010-3114>.

[70] Michael Pranzatelli, Nathan McGee, Elizabeth Tate, Relation of intrathecal oligoclonal band production to inflammatory mediator and immunotherapy response in 208 children with OMS, *J. Neuroimmunol.* 321 (2018), <https://doi.org/10.1016/j.jneuroim.2018.04.007>.

[71] M.R. Pranzatelli, E.D. Tate, N.R. McGee, Multifactorial analysis of opsoclonus-myoclonus syndrome etiology ("Tumor" vs. "No tumor") in a cohort of 356 US children, *Pediatr. Blood Cancer* 65 (8) (2018), e27097, <https://doi.org/10.1002/pbc.27097>.