



HAL
open science

Trachelectomy: How is it actually done? A review from FRANCOGYN group

A Lefebvre, Emilie Raimond, Pauline Chauvet, Cyril Touboul, Geoffroy Canlorbe, Vincent Lavoué, Lobna Ouldamer, Pierre Collinet, Sofiane Bendifallah, Xavier Carcopino, et al.

► **To cite this version:**

A Lefebvre, Emilie Raimond, Pauline Chauvet, Cyril Touboul, Geoffroy Canlorbe, et al.. Trachelectomy: How is it actually done? A review from FRANCOGYN group. *Journal of Gynecology Obstetrics and Human Reproduction*, 2022, 51 (7), pp.102407. 10.1016/j.jogoh.2022.102407 . hal-03717184

HAL Id: hal-03717184

<https://hal.science/hal-03717184>

Submitted on 21 Jul 2022

HAL is a multi-disciplinary open access archive for the deposit and dissemination of scientific research documents, whether they are published or not. The documents may come from teaching and research institutions in France or abroad, or from public or private research centers.

L'archive ouverte pluridisciplinaire **HAL**, est destinée au dépôt et à la diffusion de documents scientifiques de niveau recherche, publiés ou non, émanant des établissements d'enseignement et de recherche français ou étrangers, des laboratoires publics ou privés.

Title: Trachelectomy: How is it actually done? A review from FRANCOGYN group

Titre : Trachélectomie : comment faire en pratique ? Revue de la littérature par le groupe FRANCOGYN.

Alice Lefebvre MD, PhD 1,2; Emilie Raimond MD 3 ; Pauline Chauvet MD 4 ; Cyril Touboul MD, PhD 5; Geoffroy Canlorbe MD, PhD 6; Vincent Lavoué MD, PhD 7 ; Lobna Ouldamer MD, PhD, 8 ; Pierre Collinet MD, PhD 1,2; Sofiane Bendifallah MD, PhD 5; Xavier Carcopino MD, PhD 9; Lise Lecointre MD 10; Yohan Kerbage MD, PhD 1,2

1. CHU Lille, Service de chirurgie gynécologique F-59000 Lille, France
 2. Univ. Lille, CHU Lille, F-59000 Lille, France
 3. Department of Obstetrics and Gynaecology, Alix de Champagne Institute, Centre Hospitalier Universitaire, 45 rue Cognacq-Jay, 51092, Reims, France
 4. Department of Gynaecology and Obstetrics, CHU de Clermont Ferrand, France
 5. Department of Gynaecology and Obstetrics, Tenon University Hospital, Assistance Publique des Hôpitaux de Paris (AP-HP), Faculté de Médecine Sorbonne Université, Institut Universitaire de Cancérologie (IUC), France
 6. Department of Gynecologic and Breast Surgery and Oncology, Hôpital la Pitié Salpêtrière, AP-HP, Paris, France
 7. Department of Gynaecology, CHU de Rennes, France. INSERM, 1242, COSS, Rennes, Université de Rennes 1, France
 8. Department of Gynaecology. CHRU de Tours. Hôpital Bretonneau. INSERM Unit, 1069, 2 boulevard Tonnellé 37044 TOURS, France
 9. Department of Obstetrics and Gynaecology, Hôpital Nord, APHM, Aix-Marseille University (AMU), Univ Avignon, CNRS, IRD, IMBE UMR 7263, 13397, Marseille, France
 10. Department of Gynecologic Surgery, Hôpitaux Universitaires de Strasbourg, IHU Strasbourg, Strasbourg, France
- Corresponding author:

Alice Lefebvre,

Department of gynaecology, Jeanne de Flandre University Hospital, Lille, France

07 81 95 41 51

lefebvre.alice20@gmail.com

RESUME

En raison du pic d'incidence du cancer du col de l'utérus entre 35 et 44 ans et du recul de l'âge de la première grossesse, la problématique de préservation de la fertilité en cas de cancer du col utérin débutant chez ces femmes en âge de procréer se pose. Les stades précoces du cancer du col utérin sont de bon pronostic et traités par chirurgie, dans le cas de type histologique peu agressif lié au papillomavirus (carcinome épidermoïde, adénocarcinome), de stade FIGO IA à IB1 (soit < 2 cm), avec une invasion stromale peu profonde (< 10 mm), sans présence d'embolies lymphovasculaires, ni d'envahissement ganglionnaire ou régional. Dans ces conditions, un traitement conservateur par trachélectomie peut être envisagé, avec une survie sans récurrence ou globale équivalente à celle de l'hystérectomie. Après un bilan pré-thérapeutique complet, incluant la lymphadénectomie pelvienne, éliminant toutes contre-indications au traitement conservateur, une trachélectomie simple ou élargie, peut être décidée. Selon certains auteurs, différentes voies d'abord peuvent être utilisées (vaginale, laparoscopie simple ou robot-assistée, laparotomie), sans différence significative en termes de survie et de fertilité avec cependant une littérature limitée sur le sujet. La trachélectomie offre de bons résultats en termes de fertilité, avec un taux de grossesse estimé entre 23 et 55%, dont 70% de naissances vivantes. Cependant, la nette réduction du col utérin liée à l'intervention augmente le risque de prématurité, pouvant être prévenu par la mise en place d'un cerclage définitif. Une surveillance rapprochée de ces patientes est indispensable pour une durée minimale de 5 ans, afin de dépister une éventuelle récurrence ou complication post opératoire.

Mots clés : cancer du col utérin, trachélectomie, fertilité, cerclage

ABSTRACT

Because of the peak incidence of cervical cancer between the ages of 35 and 44 and the increasing age of first pregnancy, the issue of fertility preservation in cases of early-stage cervical cancer in women in this reproductive age category arises. Early-stage cervical cancer patients have a good prognosis and are surgically treated in cases of mildly aggressive human papillomavirus-related histological type (squamous cell carcinoma, adenocarcinoma), FIGO stage IA to IB1 (i.e., <2 cm), with shallow stromal invasion (<10 mm) and without the presence of lymph-vascular space invasion or lymph node or regional involvement. Under these conditions, conservative treatment by trachelectomy, which has recurrence-free and overall survival rates equivalent to that of hysterectomy, may be considered. After a complete pre-therapeutic assessment, including pelvic lymphadenectomy, to eliminate all contraindications to conservative treatment, a simple or enlarged trachelectomy can be chosen. According to some authors, the route of entry (vaginal, simple or robot-assisted laparoscopy, laparotomy) has no significant effect on survival or fertility, although the literature on the subject is limited. Trachelectomy offers good results in terms of fertility, with an estimated pregnancy rate of between 23% and 55% and a live birth rate of 70%. The significant reduction of the cervix associated with the procedure increases the risk of prematurity. However, this can be prevented by the use of a permanent cerclage. Close follow-up of these patients is essential for a minimum period of 5 years in order to detect any recurrence or postoperative complications.

Keywords: *cervical cancer, trachelectomy, fertility, cerclage*

INTRODUCTION

Cervical cancer is the 12th most common cancer in women in France, with around 3,000 new cases each year and 3% mortality (1,000 deaths per year). Its peak incidence is between the ages of 35 and 44 [1]. As a result of screening, more and more cervical cancers are diagnosed early. Early-stage cervical cancers represent approximately 1,700 new cases per year in France. They are mainly characterized by human papillomavirus (HPV)-related squamous cell carcinomas or adenocarcinomas, ranging from stage IA to IB1 of the FIGO classification scale [2] and measuring less than 2 cm with a stromal invasion of less than 10 mm, with no pelvic lymph node metastasis or lymphovascular space invasion (LVSI). The prognosis is good, with an estimated 5-year recurrence-free survival rate of 91–97%. The treatment is usually surgical, based on radical hysterectomy with bilateral pelvic lymphadenectomy [3,4]. However, the increase in the age of the first pregnancy in France raises the question of resorting to a more conservative treatment [5]. Trachelectomy appears to be an appropriate and effective therapeutic option for the management of early cervical cancer in patients wishing to preserve fertility. Numerous studies have shown that there is no significant difference between trachelectomy and hysterectomy in terms of risk of recurrence or overall survival [6,7,8,9,10]. Described by Dargent in 1987, enlarged vaginal trachelectomy consists of resection of the cervix, the upper third of the vagina, and the proximal part of the parameters and preservation of the upper part of the endocervix, the uterine body, and the appendages [7,11]. It is preceded by a bilateral pelvic lymphadenectomy by laparoscopy to ensure the absence of lymph node involvement [12].

ANATOMY

In order to best approach the different operative steps of each surgical procedure, rigorous knowledge of the anatomical structures of the pelvis is necessary. The pelvis can be delimited by several anatomical spaces on either side of the pelvic viscera. Anteriorly, the paravesical fossa, located between the bladder and the pelvic wall, is divided by the umbilical artery into two parts, lateral and medial. The lateral limits of this fossa are the obturator vessels and nerve, which runs along the pelvic wall to the obturator canal; and the corona mortis vein, an anastomosis between the obturator vein and the external iliac vein. The bladder pillars and the paracervix are the medial landmarks of the paravesical fossa. Its inferior limit is composed of the obturator internus muscle, the ilio-coccygeus muscle, and the tendinous arch of the levator ani muscle. Posteriorly, the pararectal fossa is separated by the ureter into two spaces: the Latzko space laterally and the Okabayashi space medially. The first space is located between the internal iliac vessels, from which the uterine vessels arise, and the ureter. The Latzko space includes the splanchnic nerves, which join the hypogastric nerve medially. The median structures of the Okabayashi space are the rectum, the uterosacral ligament, and the paracervix anteriorly. This space is crossed by the middle rectal vessels and the hypogastric nerve. The lower limit of the pararectal fossa consists of the muscles of the pelvic floor (levator ani, ilio-coccygeal, piriformis). (Figure 1)

During trachelectomy and associated pelvic lymphadenectomy, special attention should be paid to the preservation of the ureter, uterine artery, and nerves, including the inferior hypogastric plexus. The uterine artery, which originates from the hypogastric artery, a branch of the internal iliac artery, runs medially and forward at the base of the broad ligament to the cervix. During its course, the uterine artery

crosses over the ureter and the lateral vaginal fornix from which its cervico-vaginal branches arise and then ascends along the lateral border of the uterus to anastomose with the ovarian artery [13]. After crossing the iliac vessels, the pelvic ureter is divided into three segments: parietal, visceral, and vesical. The parietal part of the ureter runs along the internal iliac vessels forward and inward. Its visceral portion is located in the parametrium to the lateral vaginal fornix, where it is crossed by the uterine artery. The ureter, along with the hypogastric nerves, then enters the Yakubi space between the pillars of the bladder, before joining the bladder in its vesical portion. The hypogastric nerve is joined by the pelvic splanchnic parasympathetic nerves, forming the inferior hypogastric plexus. Innervating the pelvic viscera, this plexus plays a major role in urinary, digestive, and sexual function. These anatomical structures are closely related to the parametrium, lamina of celluloglandular tissue located in the lateral region of the uterine cervix. The parametrium is crossed by the ureter and the vascular nerve structures of the uterus and vagina and constitutes one of the two routes of direct lymphatic dissemination of cervical cancer. The other route is downward and direct to the vagina. This explains the importance of accuracy when performing a parametrectomy, a surgical procedure with a high risk of functional complications (urinary, sexual, and digestive) due to its proximity to the lower hypogastric plexus [7,14].

INDICATIONS

For localized stages, FIGO IA to IB1, conservative treatment by trachelectomy can be considered for women of childbearing age who desire fertility. Without a formally established age limit (although an age limit of <40 years is generally accepted), the decision must be discussed in a multidisciplinary meeting based on all the clinical and histological data [11]. The absolute contraindications to conservative treatment are aggressive histological types (neuroendocrine, clear cells, non-HPV-related adenocarcinomas), lymph node metastasis, and invasion of the upper isthmic margin [4,15]. A pre-therapeutic assessment will determine whether conservative treatment should be considered. The diagnosis of carcinoma must be confirmed by conization. This examination provides information on the histological type of the tumor, the tumor size, the depth of stromal invasion, the positive surgical margins, and the presence of tumor vascular space invasion (LVSI) [16]. These criteria are prognostic risk factors for lymph node involvement and recurrence [12]. Lymph node assessment by pelvic lymphadenectomy or sentinel node assessment, usually by laparoscopy with intraoperative assessment (frozen section), is required except in FIGO stage IA1 without LVSI [3]. The assessment of loco-regional extension is based on pelvic and lumbar-aortic MRI to specify the tumor size; the depth of stromal invasion; the parametrial, vaginal, bladder, and rectal extension; the distance between the tumor and the internal os of the cervix; and the presence of paraaortic lymphadenopathy [7,16,17]. An oncofertility consultation is recommended to assess the ovarian reserve and the partner's fertility [3,4,7,15].

Conservative treatment by conization or trachelectomy is possible in cases of localized squamous cell carcinomas or adenocarcinomas of less than 2 cm in the

longest axis, without lymph node or regional invasion (parametrium, vagina, endocervix). Pelvic lymph node involvement contraindicates surgical treatment and requires concomitant radiochemotherapy treatment after paraaortic lymph node dissection [3,7]. Another prognostic factor for recurrence is a short distance between the upper margin of the surgical specimen and the internal os of the cervix. Therefore, a margin greater than 8–10 mm is recommended for trachelectomy [12,18,19]. The pelvic lymph node sample and the edges of the surgical specimen should be analyzed by intraoperative assessment (by frozen section) to ensure that there is no contraindication to conservative treatment [4,11]. Lymph node dissection may also take place beforehand (by definitive analysis) in order to validate the conservative management secondly [11]. Therefore, it is important to inform the patient that a hysterectomy may be necessary in case of positive margins or the presence of lymph node metastasis.

The choice of which type of conservative treatment is most appropriate will depend on the tumor size (FIGO stage) and the presence of LVSI (Figure 1). For tumors measuring less than 2 cm with a stromal invasion of less than 10 mm, studies by Covens et al. and the FRANCOGYN group found parametrial involvement of 0.6% in the absence of LVSI versus 25% in its presence [20,21]. Consequently, in the absence of LVSI, a less radical treatment by “simple” trachelectomy (without parametrectomy) can be considered, with a recurrence rate of lower than 1% in the case of negative margins and a decrease in postoperative morbidity (e.g., urinary dysfunction) [22,23]. In the presence of LVSI or for stages IA2 and IB1, the choice of “enlarged” trachelectomy (with parametrectomy), associated with pelvic lymph node

staging, with an estimated recurrence rate of 6%, should be favored [3,12]. For stage IA1, conization may be sufficient in the case of negative margins.

According to several reviews, the average recurrence rate after conservative treatment is 3.3%, and the 5-year overall survival rate is 97%. In terms of fertility, the pregnancy rate is estimated at between 23% and 55%, with approximately 70% of live births and a premature birth rate of 35% [24]. No surgical approach resulted in a significant difference in the number of live births [25]. Although no increase in the number of early miscarriages compared to the general population has been observed, there is nevertheless an increased risk of late fetal loss and prematurity. This can be explained by two factors : one mechanical by the reduction of the length of the cervix, and the other by the loss of the cervical glands secreting mucus, a protective agent against ascending infections of vaginal origin [18,19]. The most common postoperative complications are bleeding, infection, lymphocele related to lymphadenectomy, ureteral and bladder injuries, and functional urinary disorders (urinary retention or dysuria). It is sometimes necessary to perform a reoperation. It should be noted that other complications, such as cervical stenosis – the most frequent (in 10% of cases) – or cervical erosion may have repercussions for fertility [25,26].

Although experimental and controversial, neoadjuvant chemotherapy (NAC) may prove to be an alternative for stage IB2 tumors of between 2 and 4 cm, for which the risk of recurrence is not negligible (between 10% and 24%) [11,27]. Treatment with NAC would allow downstaging, making conservative treatment accessible. It is preferable to ensure the absence of lymph node involvement by lymphadenectomy

before starting the chemotherapy [28]. A review by Bentivegna et al. found a identical recurrence rate between NAC and first surgery, but the rate of positive margins remains higher in the case of NAC [12,29]. Then, conservative treatment might be considered in the case of a tumor residue of less than 3 mm. Due to the small number of cases reported in the literature, there is no recommendation on which type of conservative surgery is preferable after NAC.

Journal Pre-proof

DIFFERENT APPROACHES

Despite the rise of minimally invasive routes (laparoscopy and robot-assisted surgery), vaginal trachelectomy remains the most widely used procedure (58% vaginal versus 42% abdominal) [24,30]. According to Smith et al., it is the fastest route and achieves higher pregnancy rates, although the approaches do not differ in terms of the rate of live births, rate of recurrence, or overall survival. However, laparoscopy has a lower rate of operative blood loss [24]. Consequently, the choice of intervention must take into account the experience of the surgical team and the patient's wishes [12,25].

The vaginal, laparotomy, and conventional and robot-assisted laparoscopy routes are explained below. They differ in terms of parametrial resection: the supra-ureteral lateral parametrium is removed in cases of abdominal entry (laparotomy, laparoscopy, or robot-assisted surgery) and the infra-ureteral parametrium is removed during vaginal surgery.

The transvaginal approach, described by Dargent, is the most common procedure and offers good results in terms of fertility [10]. The first operative stage consists of lymphadenectomy by laparoscopy (by pre- or transperitoneal entry). A vaginal trachelectomy is similar to an enlarged vaginal hysterectomy (or Stoëckel's variant of Schauta's operation). The first step is the creation of a vaginal collar about 1.5 cm from the cervix, separating the upper third from the middle third of the vagina. The fold, grasped by forceps, is infiltrated by an adrenaline anesthetic solution and then incised circularly and pulled downwards (with the collar closed by forceps). The bladder is then detached from the median part of the vesico-uterine space. The

bilateral opening of the paravesical spaces, between the 1 and 3 o'clock positions on the left and the 9 and 11 o'clock positions on the right, allows the individualization of the bladder pillars on each side. The ureter and uterine artery, located between the pillars, are preserved and pushed upward before the section of the external and internal pillars. The next step is to open Douglas's pouch and section the utero-sacral ligaments. Once the uterus can be mobilized, the parametria are clamped and then sectioned 2 cm from the cervix. (Figure 2) In conservative treatment, this intervention is followed by ligation of the cervico-vaginal vessels, arising from the loop of the uterine artery. Section of the uterus at the level of the isthmus precedes the definitive cerclage. (Figure 3) The pouch of Douglas is anchored to the uterus at the parametrial stumps over the cerclage. Finally, the isthmo-vaginal anastomosis is performed via two anterior and posterior Sturmdorf points and two angle points. The patency of the uterine orifice is monitored, and a catheter may be left in place temporarily [29]. Removal of the urinary catheter is followed by monitoring of mictional recovery.

Over the past decade, several authors have demonstrated the feasibility of radical resection by laparoscopy [24]. The morbidity rate appears to be equivalent to that of the laparotomic route, but the laparoscopic route has the undeniable advantage of reducing postoperative bleeding and pain, duration of hospitalization and convalescence and shows a higher pregnancy rate [25]. According to some retrospective studies, early-stage cervical cancers can be treated laparoscopically, with efficacy and recurrence rates similar to those of the laparotomic route [31].

In practice, the patient is installed in a gynecological position. After the installation of the pneumoperitoneum and the trocars (one umbilical 10-mm trocar and three 5-mm trocars in the suprapubic region and the right and left iliac fossa), the paravesical fossa is opened by detaching the anterior layer of the broad ligament after sectioning the round ligament about 4 cm from the uterine horn. External, primary internal, interarteriovenous, and subvenous iliac lymphadenectomy is then performed. The opening of the pararectal fossa then allows the identification of the hypogastric artery and the ureter, which is pushed back toward the latero-rectal peritoneum. The ureter is released to the bladder before proceeding to the vesico-uterine detachment, facilitated by the traction of the bladder toward the anterior abdominal wall. The vesico-uterine ligaments or bladder pillars, stretched on each side of the vesico-uterine detachment, are then coagulated and cut halfway between the bladder and the uterus, directly above the ureter, preserving the uterine artery. Next, posterior dissection is performed, which involves opening the rectovaginal space and then cutting the uterosacral ligaments about 2 cm from their uterine insertion. This step improves the mobilization of the uterus and will facilitate the posterior peritonization time. The ureter is thus completely freed and separated laterally, revealing the section zone of the parametria about 15 mm from their cervical insertions. The uterine artery is pediculized from the medial border of the internal iliac artery to the level of the uterine isthmus to allow placement of the cerclage. After section of the paracervix in line with the ureter, the cervical branch of the uterine artery is coagulated. The cervix is cut approximately 5 mm below the uterine isthmus and the monopolar hook is used to make a vaginal incision at the appropriate height to form the vaginal collar, or 2–3 cm below the cervix. Finally, the isthmovaginal suture by separate No. 0 Monocryl stitches precedes the cerclage. As described by Benson,

the prosthesis is placed inside the uterine arteries and 5 mm from the isthmovaginal suture, a Monarc® type band fixed by helical staples (e.g., Protack® type). Finally, peritonization is performed to cover the prosthesis with a No. 2-0 Monocryl thread at the front of the uterus and a V-Lock® thread at the back in order to limit the risks of adhesions and occlusion [32].

Since 2008, robotic surgery has been increasingly used in gynecological cancer surgery. In addition to the advantages of laparoscopy, the robot-assisted approach offers fine dissection precision with three-dimensional vision, which is particularly helpful for parametrectomy and nerve and ureteral preservation [7,33,34]. In practical terms, only the placement of the trocars differs from the laparoscopic route. The 12 mm trocar for the optics is placed transumbilically, and three trocars of 8 mm in length dedicated to the robot and one trocar for the assistant (in the right iliac fossa) are positioned in an arc under the umbilicus, with a distance of at least 8 cm between each trocar to avoid conflicts between the robot arms [35]. Despite its advantages, robot-assisted trachelectomy remains understudied in the literature, due to the small number of cases, linked to its accessibility and cost.

The abdominal approach has the advantage of better accessibility compared to minimally invasive routes (laparoscopy or robot) and is an easier procedure than vaginal surgery. In addition, the upper route allows a wider resection of the parametria and is therefore frequently indicated for larger tumors of over 2 cm. However, this approach presents greater morbidity risks (deep abscesses, nerve damage) and poorer results regarding fertility [12,19,26]. The recent prospective LACC study showed that hysterectomy by laparotomy had a higher survival rate

(disease-free and overall survival) than minimally invasive routes [31,36]. However, the SUCCOR study found no significant difference in survival for these different routes of entry in the absence of the use of a uterine manipulator and the closure of the vaginal collar during laparoscopy [37]. Recently, Salvo et al. published a retrospective study comparing open vs minimally invasive trachelectomy. The 4.5 year disease-free survival rate did not differ between both groups, but recurrence rates in each group were low [38].

Journal Pre-proof

PERMANENT CERCLAGE

Numerous studies have recommended the placement of a permanent cerclage at the same operative time as a simple or enlarged trachelectomy [3,4]. Positioned around the uterine isthmus, medial to the loop of the uterine artery, it is tied subperitoneally on the posterior surface of the isthmus. As there is no recommendation in the literature regarding the material to be used, the surgeon may choose between a non-absorbable thread (such as Prolene, Nylon, Ethibond, or Flexidene® dec5) or a 4 mm braided polypropylene strip [18,26,29]. Cerclage decreases the risk of fetal loss by 50% to 22% [18]. On the other hand, it increases by 8% (versus 3% in its absence) the risk of cervical stenosis, a source of infertility or symptoms such as cycle disorders and dysmenorrhea [26]. According to some authors, this complication can be prevented by placing a catheter or an intrauterine device in the neocervix for a period ranging from a few days to several months [25,26].

FOLLOW-UP

The two main goals of follow-up after conservative treatment for cervical cancer are detection of recurrence and detection of fertility complications. According to the 2018 European Society of Gynaecological Oncology (ESGO) recommendations [4], postoperative follow-up should be adapted and individualized according to prognostic factors, the risk of recurrence, and the risk of complications secondary to treatments. The recommended regimen is based on a physical examination every 3 to 4 months for the first 2 years and then every 6 months for 3 years. Since the majority of recurrences occur during the first 2 years, a 5-year follow-up seems sufficient, with

an annual follow-up comparable to that of the general population [39]. Clinical surveillance is combined with the HPV test (with or without cervico-vaginal smear) at 6, 12, and 24 months and then every 3 to 5 years if negative. In parallel, colposcopy may be an option. Pelvic MRI may be indicated annually or if there are suspected recurrence symptoms. During follow-up, it is important to screen for complications that may affect the patient's fertility. Menstrual cycle disorders may occur in cases of cervical stenosis, synechiae, or ovarian failure. These complications must be treated in order to promote pregnancy and improve quality of life [25,26,40]. Post-trachelectomy pregnancies are considered high-risk pregnancies and should be monitored in a specialized perinatal center. To prevent the risk of fetal loss, closing of the cervix by the Saling technique can be associated with cerclage at the end of the first trimester of pregnancy. This surgical procedure isolates the membranes from vaginal germs and reduces the risk of ovular infection. Caesarean section is the recommended mode of delivery after conservative treatment to avoid damage to the permanent cerclage for subsequent pregnancies and the risk of vaginal hemorrhage. It can be scheduled at 37–38 weeks with amenorrhea [3,4,7,25]. Once the parental plan is completed, additional treatment by hysterectomy remains debated and not be performed necessarily [3,4,7].

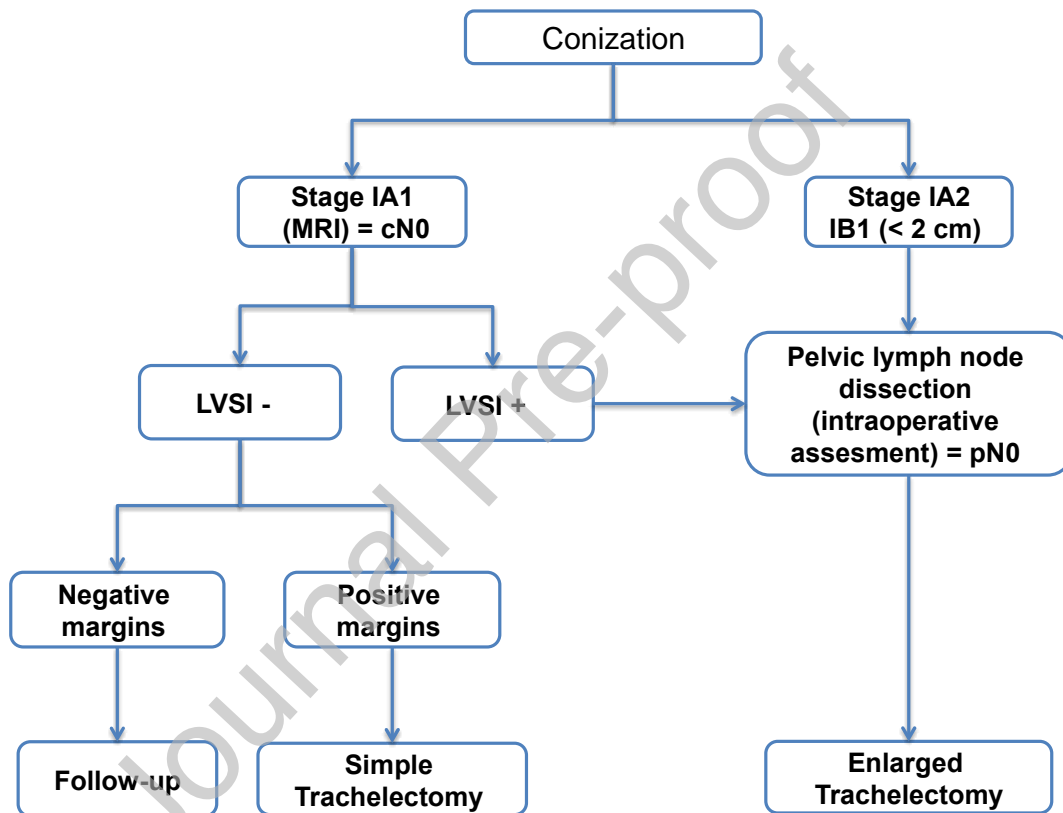
CONCLUSION

Although not widely performed, trachelectomy is a validated conservative treatment, with no significant difference from radical treatment by hysterectomy in terms of recurrence and survival, and offers good results in terms of pregnancy and live birth [11,24]. Its indication remains limited to women with early-stage cervical cancer and a good prognosis (FIGO IA to IB1, size less than 2 cm and stromal invasion less than 1 cm, without vascular emboli) wishing to preserve their fertility. It is imperative to confirm the absence of pelvic lymph node involvement or affected margins of the surgical specimen to validate conservative management. The choice of surgery should be discussed with the patient or the couple, taking into account clinical elements, prognostic factors, and the experience of the operator.

DECLARATION OF INTEREST

The authors declared no conflicts of interest.

Figure 1: Decision-making algorithm for conservative treatments
based on current recommendations [4,15,16]



REFERENCES

1. Projection de l'incidence et de la mortalité par cancer en France métropolitaine en 2017. Rapport technique. :80.
2. Matsuo K, Machida H, Mandelbaum RS, Konishi I, Mikami M. Validation of the 2018 FIGO cervical cancer staging system. *Gynecologic Oncology*. janv 2019;152(1):87-93.
3. Cibula D, Pötter R, Planchamp F, Avall-Lundqvist E, Fischerova D, Haie-Meder C, et al. The European Society of Gynaecological Oncology/European Society for Radiotherapy and Oncology/European Society of Pathology Guidelines for the Management of Patients with Cervical Cancer. *Virchows Arch*. juin 2018;472(6):919-36.
4. ESGO guidelines. Cervical Cancer [Internet]. Disponible sur: https://www.esgo.org/media/2015/12/ESGO_Cervical-Cancer_A6.pdf
5. Insee, estimations de population et statistiques de l'état civil. Âge moyen de la mère à l'accouchement. Données annuelles de 1994 à 2020. [Internet]. Disponible sur: <https://www.insee.fr/fr/statistiques/2381390#graphique-figure1>
6. Cui RR, Chen L, Tergas AI, Hou JY, St Clair CM, Neugut AI, et al. Trends in Use and Survival Associated With Fertility-Sparing Trachelectomy for Young Women With Early-Stage Cervical Cancer. *Obstet Gynecol*. juin 2018;131(6):1085-94.
7. Azaïs H. Traitement des cancers du col utérin de stade précoce. :16.
8. Beiner ME, Hauspy J, Rosen B, Murphy J, Laframboise S, Nofech-Mozes S, et al. Radical vaginal trachelectomy vs. radical hysterectomy for small early stage cervical cancer: a matched case-control study. *Gynecol Oncol*. août 2008;110(2):168-71.
9. Xu L, Sun F-Q, Wang Z-H. Radical trachelectomy versus radical hysterectomy for the treatment of early cervical cancer: a systematic review. *Acta Obstet Gynecol Scand*. nov 2011;90(11):1200-9.
10. Reade CJ, Eiriksson LR, Covens A. Surgery for early stage cervical cancer: how radical should it be? *Gynecol Oncol*. oct 2013;131(1):222-30.
11. Dargent D, Martin X, Sacchetoni A, Mathevet P. Laparoscopic vaginal radical trachelectomy: a treatment to preserve the fertility of cervical carcinoma patients. *Cancer*. 15 avr 2000;88(8):1877-82.
12. Bentivegna E, Gouy S, Maulard A, Chargari C, Leary A, Morice P. Oncological outcomes after fertility-sparing surgery for cervical cancer: a systematic review. *Lancet Oncol*. juin 2016;17(6):e240-53.
13. Muller J-M. Pelvis et périnée. In: Drake RL PhD, FAAA, Vogl AW PhD, FAAA, Mitchell AWM MB BS, FRCS, FRCR, éditeurs. *Gray's Anatomie - Le Manuel pour les*

étudiants [Internet]. 2020. p. 403-510. Disponible sur:

<https://www.clinicalkey.com/student/content/book/3-s2.0-B9782294762239000058>

14. Benedetti-Panici P, Maneschi F, D'Andrea G, Cutillo G, Rabitti C, Congiu M, et al. Early cervical carcinoma: the natural history of lymph node involvement redefined on the basis of thorough parametrectomy and giant section study. *Cancer*. 15 mai 2000;88(10):2267-74.

15. Koh W-J, Abu-Rustum NR, Bean S, Bradley K, Campos SM, Cho KR, et al. Cervical Cancer, Version 3.2019, NCCN Clinical Practice Guidelines in Oncology. *J Natl Compr Canc Netw*. janv 2019;17(1):64-84.

16. APHP_referentiel_cancers_du_col_uterin_-_juin_2016_0.pdf.

17. Woo S, Atun R, Ward ZJ, Scott AM, Hricak H, Vargas HA. Diagnostic performance of conventional and advanced imaging modalities for assessing newly diagnosed cervical cancer: systematic review and meta-analysis. *Eur Radiol*. oct 2020;30(10):5560-77.

18. Mathevet P, Laszlo de Kaszon E, Dargent D. La préservation de la fertilité dans les cancers du col utérin de stade précoce. *Gynécologie Obstétrique & Fertilité*. sept 2003;31(9):706-12.

19. Rob L, Skapa P, Robova H. Fertility-sparing surgery in patients with cervical cancer. *Lancet Oncol*. févr 2011;12(2):192-200.

20. Dabi Y, Willecocq C, Ballester M, Carcopino X, Bendifallah S, Ouldamer L, et al. Identification of a low risk population for parametrial invasion in patients with early-stage cervical cancer. *J Transl Med*. 14 juin 2018;16(1):163.

21. Covens A, Rosen B, Murphy J, Laframboise S, DePetrillo AD, Lickrish G, et al. How important is removal of the parametrium at surgery for carcinoma of the cervix? *Gynecol Oncol*. janv 2002;84(1):145-9.

22. Ramirez PT, Pareja R, Rendón GJ, Millan C, Frumovitz M, Schmeler KM. Management of low-risk early-stage cervical cancer: should conization, simple trachelectomy, or simple hysterectomy replace radical surgery as the new standard of care? *Gynecol Oncol*. janv 2014;132(1):254-9.

23. Schmeler KM, Frumovitz M, Ramirez PT. Conservative management of early stage cervical cancer: is there a role for less radical surgery? *Gynecol Oncol*. mars 2011;120(3):321-5.

24. Smith ES, Moon AS, O'Hanlon R, Leitao MM, Sonoda Y, Abu-Rustum NR, et al. Radical Trachelectomy for the Treatment of Early-Stage Cervical Cancer: A Systematic Review. *Obstet Gynecol*. sept 2020;136(3):533-42.

25. Bentivegna E, Maulard A, Pautier P, Chargari C, Gouy S, Morice P. Fertility results and pregnancy outcomes after conservative treatment of cervical cancer: a systematic review of the literature. *Fertil Steril*. oct 2016;106(5):1195-1211.e5.

26. Li X, Li J, Wu X. Incidence, risk factors and treatment of cervical stenosis after radical trachelectomy: A systematic review. *Eur J Cancer*. sept 2015;51(13):1751-9.

27. Marchiole P, Tigaud J-D, Costantini S, Mammoliti S, Buenerd A, Moran E, et al. Neoadjuvant chemotherapy and vaginal radical trachelectomy for fertility-sparing treatment in women affected by cervical cancer (FIGO stage IB–IIA1). *Gynecologic Oncology*. sept 2011;122(3):484-90.

28. Robova H, Halaska MJ, Pluta M, Skapa P, Matecha J, Lisy J, et al. Oncological and pregnancy outcomes after high-dose density neoadjuvant chemotherapy and fertility-sparing surgery in cervical cancer. *Gynecologic Oncology*. nov 2014;135(2):213-6.

29. P Mathevet MD-PhD. Techniques chirurgicales de la prise en charge du

cancer du col utérin par voie laparoscopicovaginale. :10.

30. Salvo G, Pareja R, Ramirez PT. Minimally invasive radical trachelectomy: Considerations on surgical approach. *Best Practice & Research Clinical Obstetrics & Gynaecology*. sept 2021;75:113-22.
31. Matsuo K, Chen L, Mandelbaum RS, Melamed A, Roman LD, Wright JD. Trachelectomy for reproductive-aged women with early-stage cervical cancer: minimally invasive surgery versus laparotomy. *Am J Obstet Gynecol*. mai 2019;220(5):469.e1-469.e13.
32. Lu Q, Zhang Y, Liu C, Wang S, Guo S, Zhang Z. Total laparoscopic radical trachelectomy in the treatment of early squamous cell cervical cancer: a retrospective study with 8-year follow-up. *Gynecol Oncol*. août 2013;130(2):275-9.
33. Bougherara L, Blache G, Arsène E, Jauffret C, Azaïs H, Laplane C, et al. La chirurgie robotique en oncogynécologie. *Oncologie*. mai 2016;18(5):287-97.
34. Johansen SL, Lerma K, Shaw KA. Contraceptive counseling in reproductive-aged women treated for breast cancer at a tertiary care institution: a retrospective analysis. *Contraception*. oct 2017;96(4):248-53.
35. Lambaudie E. Procédures chirurgicales assistées par robot en chirurgie gynécologique oncologique – Surgical procedures by robot in oncologic gynaecological surgery. *Mise au point*. 2008;3.
36. Ramirez PT, Frumovitz M, Pareja R, Lopez A, Vieira M, Ribeiro R, et al. Minimally Invasive versus Abdominal Radical Hysterectomy for Cervical Cancer. *N Engl J Med*. 15 nov 2018;379(20):1895-904.
37. Chiva L, Zanagnolo V, Querleu D, Martin-Calvo N, Arévalo-Serrano J, Căpîlna ME, et al. SUCCOR study: an international European cohort observational study comparing minimally invasive surgery versus open abdominal radical hysterectomy in patients with stage IB1 cervical cancer. *Int J Gynecol Cancer*. sept 2020;30(9):1269-77.
38. Salvo G, Ramirez PT, Leitao MM, Cibula D, Wu X, Falconer H, et al. Open vs minimally invasive radical trachelectomy in early-stage cervical cancer: International Radical Trachelectomy Assessment Study. *Am J Obstet Gynecol*. 27 août 2021;S0002-9378(21)00963-7.
39. Elit L, Fyles AW, Devries MC, Oliver TK, Fung-Kee-Fung M. Follow-up for women after treatment for cervical cancer: A systematic review. *Gynecologic Oncology*. sept 2009;114(3):528-35.
40. Li X, Li J, Ju X, Jiang Z, Chen X, Wu X. Menstrual pattern after abdominal radical trachelectomy. :8.

Figure 2. Spaces of the female pelvis involved during trachelectomy procedure

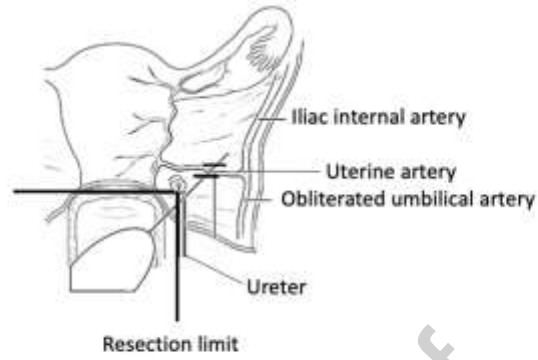


Figure 2 : Spaces of the female pelvis involved during trachelectomy procedure

Journal Pre-proof

Figure 3. Specimen of trachelectomy

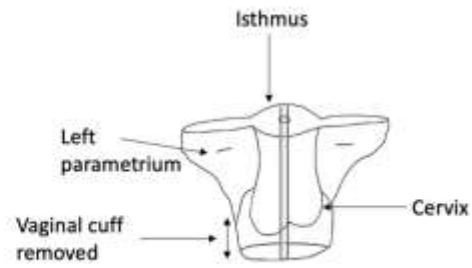


Figure 3 : Specimen of trachelectomy

Journal Pre-proof