



Sclerosing tenosynovitis in a patient with pan-sclerotic morphea

L Caillault, Guillaume Coiffier, François Robin, Catherine Droitcourt, Alain Lescoat

► To cite this version:

L Caillault, Guillaume Coiffier, François Robin, Catherine Droitcourt, Alain Lescoat. Sclerosing tenosynovitis in a patient with pan-sclerotic morphea. *Joint Bone Spine*, 2022, 89 (6), pp.105421. 10.1016/j.jbspin.2022.105421 . hal-03716686

HAL Id: hal-03716686

<https://hal.science/hal-03716686>

Submitted on 15 Sep 2022

HAL is a multi-disciplinary open access archive for the deposit and dissemination of scientific research documents, whether they are published or not. The documents may come from teaching and research institutions in France or abroad, or from public or private research centers.

L'archive ouverte pluridisciplinaire **HAL**, est destinée au dépôt et à la diffusion de documents scientifiques de niveau recherche, publiés ou non, émanant des établissements d'enseignement et de recherche français ou étrangers, des laboratoires publics ou privés.

Sclerosing tenosynovitis in a patient with pan-sclerotic morphea

Leïla Caillault¹ ; Guillaume Coiffier^{1,2} ; François Robin³ ;
Catherine Droitcourt^{4*} ; Alain Lescoat^{1, 5*}

1 : Department of Internal Medicine and Clinical Immunology, CHU Rennes, University of Rennes 1, Rennes, France.

2 : Department of Rheumatology, CH Dinan, Dinan, France

3: Department of Rheumatology, CHU Rennes, INSERM, INRA, Institut NUMECAN (Nutrition Metabolism and Cancer), 35000, Rennes, France

4 : Department of Dermatology, CHU Rennes, University of Rennes 1, INSERM CIC1414, UPRES EA 7449 REPERES (Pharmacoepidemiology and access to health care), University Rennes 1 and French School of Public Health, Rennes, France.

5 : University of Rennes, CHU Rennes, Inserm, EHESP, Irset (Institut de recherche en santé, environnement et travail) - UMR_S 1085, F-35000, Rennes, France.

*equal contribution

Corresponding author : Leïla Caillault ; leila.caillault@chu-rennes.fr ; Department of internal medicine and Clinical Immunology, Rennes South hospital, 16 boulevard de Bulgarie, 35 200 Rennes ; +33607274878

A 57-year-old woman was admitted to outpatient clinic for arthralgia and joint stiffness of fingers and wrists. She presented with isolated cutaneous fibrosis of extremities, without other cutaneous or systemic manifestations, including no Raynaud's phenomenon. Ultrasound showed sclerosing tenosynovitis characterized by hypertrophy of finger flexor tendon sheaths with concentric alternating hyperechoic and iso-echoic layers (* on **Figure 1A, B representing flexor tendons**) without synovial inflammation, as suggested by power-doppler signal. There was no fascia or aponeurosis involvement. Complete blood count and thyroid hormone levels were normal. There was no systemic sclerosis (SSc)-associated autoantibody on DOT-blot. HRCT-chest scan and echocardiography showed no sign of interstitial lung disease or pulmonary hypertension. Nailfold capillaroscopy was normal. The final diagnosis was pan-sclerotic morphea with tenosynovial involvement. Oral steroids and methotrexate were initiated, with improvement of skin fibrosis and regression of sclerosing tenosynovitis (**Figure 1C, D**).

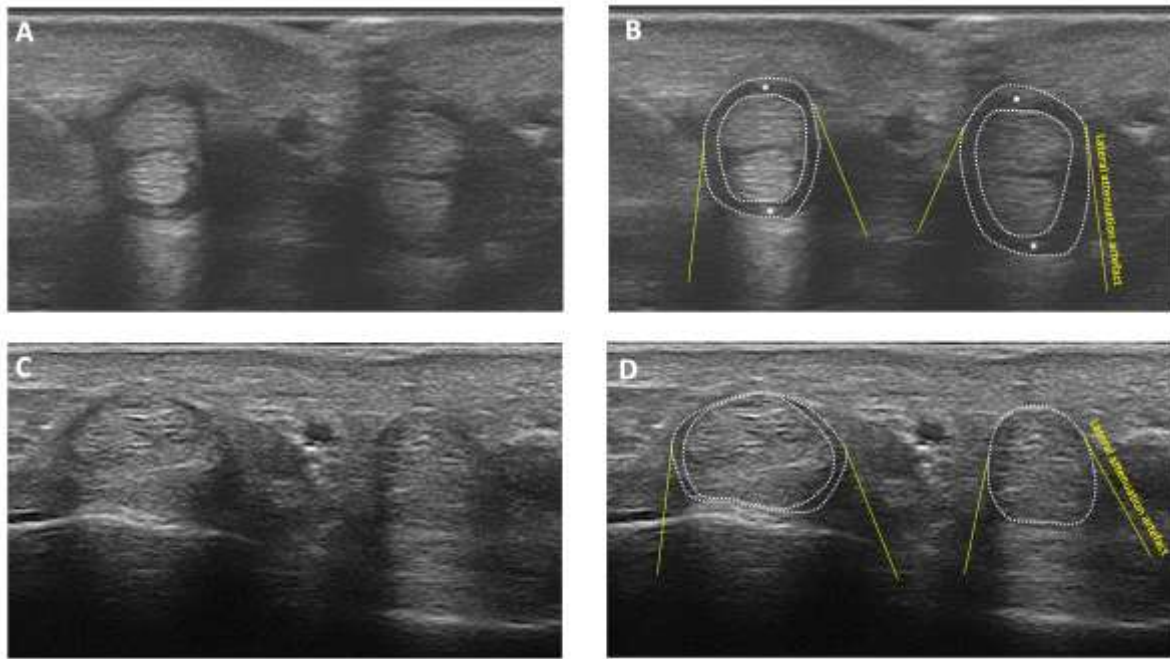
As recently discussed in this journal, morphea, also called localized scleroderma are classified as circumscribed, linear, generalized (including pan-sclerotic in some classifications), or mixed morphea (1). Morphea notably differs from SSc, through the absence of vascular involvement, absence of SSc specific autoantibody (such as anti-centromere or anti-topoisomerase I, although positivity for antinuclear antibody is common), and sparing of visceral organ such as heart, lung and digestive system. Sclerosing tenosynovitis is a recently characterized entity, classically described as the multilayered artichoke heart or onion bulb sclerosing pattern in ultrasound (2). It is supposed to be the result of the fibrosis of the tendon sheath. Such pattern show similarities with tendon friction rubs, classically described in patients with early diffuse SSc (1). Although mostly considered specific to SSc, sclerosing tenosynovitis has been recently described in linear morphea in children, with good response to methotrexate (3). Such joint involvement could be a neglected issue in morphea. Sclerosing tenosynovitis has never been described in an adult with morphea so far. After 3 years of follow-up our patient has still no sign of SSc or autoimmunity, confirming the diagnosis of pan-sclerotic morphea. Our case illustrates that fibrotic tenosynovial involvement is not specific to SSc and can be observed in adult with morphea, with potential good response to immunosuppressive therapy.

Conflicts of interests : Dr Catherine Droitcourt : Honoria from Sanofi-Genzyme

REFERENCES :

- (1) Prasad S, Zhu JL, Schollaert-Fitch K, Torok KS, Jacobe HT. An Evaluation of the Performance of Current Morphea Subtype Classifications. *JAMA Dermatol.* 2021 1;157:1-8.
- (2) Elhai M, Guerini H, Bazeli R, et al. Ultrasonographic hand features in systemic sclerosis and correlates with clinical, biologic, and radiographic findings. *Arthritis Care Res (Hoboken).* 2012;64:1244-9.
- (3) Merlin E, Breton S, Fraitag S, et al. Fibrous arthropathy associated with morphea: a new cause of diffuse acquired joint contracture. *Pediatrics.* 2017;140:e20161899

Figure 1 : Sclerosing tenosynovitis of finger flexor tendon. A, B : before oral steroids and methotrexate treatment. C, D : after oral steroids and methotrexate treatment. * Flexor tendons



Journal Pre-proof