



Unpredicted failure of deep brain stimulation by the impedance measures in a child with severe PANK2-gene related generalized dystonia

Matthieu Villessot, Diane Demailly, Emilie Chan-Seng, Gaëtan Poulen, Sophie Huby, Thomas Roujeau, Morgan Dornadic, Marc Vérin, Audrey Riou, Philippe Coubes, et al.

► To cite this version:

Matthieu Villessot, Diane Demailly, Emilie Chan-Seng, Gaëtan Poulen, Sophie Huby, et al.. Unpredicted failure of deep brain stimulation by the impedance measures in a child with severe PANK2-gene related generalized dystonia. *Brain Stimulation*, 2022, 15 (4), pp.921-923. 10.1016/j.brs.2022.06.002 . hal-03716678

HAL Id: hal-03716678

<https://hal.science/hal-03716678>

Submitted on 1 Jun 2023

HAL is a multi-disciplinary open access archive for the deposit and dissemination of scientific research documents, whether they are published or not. The documents may come from teaching and research institutions in France or abroad, or from public or private research centers.

L'archive ouverte pluridisciplinaire **HAL**, est destinée au dépôt et à la diffusion de documents scientifiques de niveau recherche, publiés ou non, émanant des établissements d'enseignement et de recherche français ou étrangers, des laboratoires publics ou privés.



Distributed under a Creative Commons Attribution - NonCommercial - NoDerivatives 4.0 International License



Unpredicted failure of deep brain stimulation by the impedance measures in a child with severe *PANK2*- gene related generalized dystonia



Keywords:
 DYT-PANK2
 DBS failure
 Impedance measures

1. Introduction

Deep brain stimulation (DBS) therapy is exploratory in pediatric dystonia related to progressive, degenerative disorders with ethical issues together with benefit to risk ratio for a given child to be considered. *PANK2* gene mutations are responsible of pediatric onset complex, severe generalized dystonia. Despite recent physio-pathological based approaches with iron chelation [1,2], there are no approved efficient available therapies for pantothenate kinase-associated neurodegeneration (PKAN) leading to lasting symptom improvement and stabilization of disease progression. DBS remains the most reported useful therapy in alleviating severe dystonia in PKAN [3]. DBS interruption may relate to DBS system failure and be responsible for severe dystonic crisis [4].

Here we report on a child who presented, nine months following initial DBS surgery with bilateral extension cable fracture, *without* documentation of consecutive DBS system impedance abnormalities, leading to delayed surgical replacement and consequently, to 'pre-status dystonicus' [5].

2. Case report

An 8-year-old female with PKAN came to our attention because of worsening dystonia. Delay in achievement of milestones and learning impairment were followed by onset of dystonia and swallowing difficulties at 5 years of age. She was admitted to local hospital because of rapid symptom progression with medication refractory frequent opisthotonic spasms and transferred to our neurosurgery department for bilateral globus pallidus internus (GPi) DBS. Stimulation was administered on Boston Scientific Verice Gevia system, in monopolar ring mode bilaterally with the segmented level 2 (contacts 2, 3 and 4), followed by progressive clinical improvement with suppression of opisthotonic spasms and dystonia involving upper extremities; the child was more comfortable, able to sit, to help during transfer and could eat

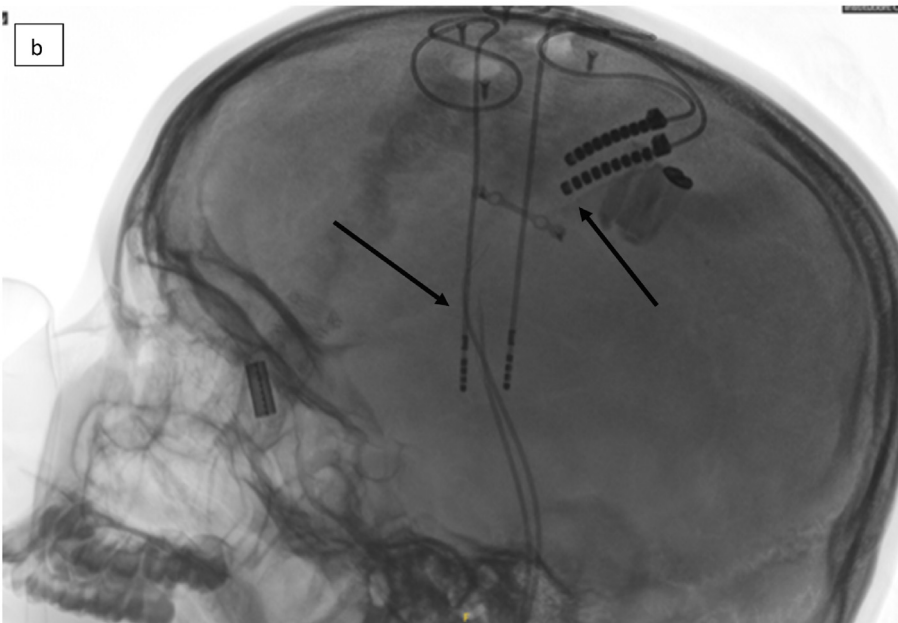
autonomously. Deferiprone [1] was initiated three months post-DBS but discontinued because of digestive adverse events. DBS settings were adjusted six months post-DBS with bilateral ring mode monopolar stimulation shared between levels 2 (contacts 2, 3 and 4) (70%) and 3 (contacts 5,6 and 7) (30%), leading to further improvement of residual symptoms in the lower limbs. One month later, in the context of recurrence of intermittent axial dystonia and blepharospasm, child was closely monitored, and battery reload controlled. Since clinical aggravation continued with the patient bedridden, she was admitted to our hospital to explore eventual triggering factors, to assess DBS functioning and adjust it.

Several hypotheses were raised for the dystonia worsening; i) DBS therapy/system related; ii) triggering factors related (infection, medication alterations); iii) related to disease progression with ongoing symptom worsening. i) We first controlled DBS system impedances to rule out system dysfunction, with measures within normal range bilaterally, except for contact 3 and contact 8 (not activated) on the right electrode. These mild unilateral impedance increase (one segment out of the six active contacts) was not sufficient for explaining such a major, bilateral and progressive (over several weeks) clinical worsening. X-ray studies performed in emergency were not contributive due to motion artefacts. ii) Because of chronological inconsistency, deferiprone cessation responsibility was ruled out together with other triggering factors. iii) The main hypothesis remained disease progression. Multiple DBS and medication adjustments did not lead to significant clinical improvement. A second X-ray using MEOPA® to release relentless dystonic spasms during exploration documented bilateral full extension cable fracture in their cranial segment (Figure, part b.), despite persistent unaltered impedance measurements. Surgical replacement of the two extension cables was followed within 4 days, by a progressive improvement of the permanent and painful dystonic spasms, sweating, sleep time, and feeding allowing discharge at day 16 post-revision.

3. Discussion

Our case highlights the good initial effect of GPi DBS on dystonia in a child with PKAN, and worsening following fracture of extension cables, that surprisingly did not affect impedances. Lead fracture occurs in 1–5% of DBS patients [6], usually in the craniocervical junction, related to repetitive involuntary neck movements. System fracture results in an open circuit, leading to high electrode impedances (>10.000 Ω) and low current measures in all or some of the electrodes. One should distinguish between the electrode impedance (or lead integrity impedance) and the therapeutic impedance.

a	RIGHT LEAD			
	Time	At admission (Day 1)	Before revision (Day 37)	After revision (Day 42)
	E1	2709	3051	1218
	E2	2562	2768	2111
	E3	9999	9999	2885
	E4	3867	2816	2526
	E5	2598	2903	2665
	E6	2842	2210	3151
	E7	4198	3213	3177
	E8	7951	8237	1423
	LEFT LEAD			
	Time	At admission (Day 1)	Before revision (Day 37)	After revision (Day 42)
	E1	2579	2323	1455
	E2	2683	3091	2379
	E3	1745	1924	2269
	E4	1842	1872	2420
	E5	1735	1714	2619
	E6	1422	1379	2474
	E7	1385	1313	2874
	E8	1342	1199	1224



b

FIGURE 1. Progression of lead impedance measures and X rays documenting DBS system dysfunction

a. Lead integrity impedances evolution at the time of the clinical worsening and following DBS system integrity restoration. Impedances measured in ohms. b. X-rays documenting bilateral extension cable fracture. Breakage of extensions underneath connection of extension (gap between the two arrows).

The electrode impedance provides information regarding the integrity of the implanted system, and refers to impedance measured automatically for each electrode configuration in both monopolar and bipolar polarity, with a low error risk <4% [7]. The therapeutic impedance refers to impedance measurements of the active contacts with the patient's actual stimulation parameters. Impedance values vary typically between 500 and 1500 Ω , with high values measured up to 40 000 Ω for electrode impedances and 4000 Ω for therapeutical impedances. Complete fractures of leads or extension cables are usually seen on X-rays; however they may be visible only with microscopic inspection. In our patient, the apparent normality of the system integrity upon measuring impedances

together with expected progression of disease symptoms in a degenerative disorder delayed the surgical revision. Initially, neither X-rays (motion artefacts) nor impedance measurements could help documenting the DBS system fracture. It could also be hypothesized that the cable fracture was progressively completed over weeks, with consequent full dysfunction of the system due to increasing opisthotonic spasms. Only two publications reported on the absence of generalized impedance abnormalities despite complete DBS lead fracture, as documented in one of these cases through the open wound [8,9]. Elongation instead of firm fracture, still allowing interaction between the environmental tissues and DBS system, appears to be responsible for normal (or seemingly

normal) impedances in both cases. Manufacturer's information related to device architecture may provide further tools in assessing eventual DBS system dysfunction. For the Vercise system, there are two (one distal and one proximal) larger non-segmented, non-directional contacts, with lower values for normal impedances when compared to the segments of the two directional contacts in between. This could help to suspect DBS system dysfunction if the specific impedance “signature” according to the electrode size is lost, even if impedance values still fit within normal range (Figure, part a).

The most frequently used internal pulse generators (IPG) employ constant voltage stimulation. Technological developments progressed with constant current use instead of constant voltage, as in our case. Constant current IPGs offer a constant current density delivery by automatically adjusting the voltage to impedance change. Boston Scientific system does not provide therapy impedance measurement facilities.

Impedance checking is mandatory at each follow-up visit in DBS treated patients, even in the absence of symptom worsening. This ensures the maintain of an efficient therapy and may prevent further complications. Ongoing abnormal stretching of extension cables may lead to progressive increase of impedance values. Even if X-rays and impedances look normal, some authors propose surgical exploration in case of loss of the clinical effect [10], especially in severe, potentially fatal clinical conditions, such as pre-status or status dystonicus [5].

In conclusion, DBS therapy may be efficient to treat severe symptoms in pediatric movement disorders related to *PANK2* gene, as repeatedly documented in our patient: i. clinical improvement at therapy initiation, ii. clinical worsening following DBS discontinuation due to the implanted system dysfunction and, iii. clinical improvement at therapy restoration, following surgical revision. The validity of impedances measurements, even if normal, should be systematically questioned in case of clinical worsening, especially in systems applying a constant current therapy in which the automated calculation of impedance values is not provided.

References

- [1] Klopstock T, Tricta F, Neumayr L, Karin I, Zorzi G, Fradette C, et al. Safety and efficacy of deferiprone for pantothenate kinase-associated neurodegeneration: a randomised, double-blind, controlled trial and an open-label extension study. *Lancet Neurol*. juill 2019;18(7):631–42.
- [2] Klopstock T, Videnovic A, Bischoff AT, Bonnet C, Cif L, Comella C, et al. Fosmet-pantotenat randomized controlled trial in pantothenate kinase-associated neurodegeneration. *Mov Disord* 2021;36(6):1342–52.
- [3] Castelnau P, Cif L, Valente EM, Vayssiere N, Hemm S, Gannau A, et al. Pallidal stimulation improves pantothenate kinase-associated neurodegeneration. *Ann Neurol* 2005;57(5):738–41. Disponible sur, <https://movementdisorders.onlinelibrary.wiley.com/doi/abs/10.1002/mds.27563>.
- [4] Nerrant E, Gonzalez V, Milesi C, Vasques X, Ruge D, Roujeau T, et al. Deep brain stimulation treated dystonia-trajectory via status dystonicus. *Mov Disord Off J Mov Disord Soc*. juill 2018;33(7):1168–73.
- [5] Allen NM, Lin J-P, Lynch T, King MD. Status dystonicus: a practice guide. *Dev Med Child Neurol*. févr 2014;56(2):105–12.
- [6] Jitkrisadikul O, Bhidayasiri R, Kalia SK, Hodaie M, Lozano AM, Fasano A. Systematic review of hardware-related complications of Deep Brain Stimulation: do new indications pose an increased risk? *Brain Stimul Basic Transl Clin Res Neuromodulation* 1 sept 2017;10(5):967–76.
- [7] Bronstein JM, Tagliati M, McIntyre C, Chen R, Cheung T, Hargreaves EL, et al. The rationale driving the evolution of deep brain stimulation to constant-current devices. *Neuromodulation Technol Neural Interface* 2015;18(2):85–9.
- [8] Vloot PD, Vermeulen L, Vandenberghe W, Nuttin B. Open fracture of deep brain stimulation leads with normal electrical impedances. *Brain Stimul Basic Transl Clin Res Neuromodulation* 1 nov 2020;13(6):1639–41.
- [9] Kiss ZHT, Bruno VA. Letter to editor in response to De vloot et al.: open fracture of DBS leads with normal electrical impedance. *Brain Stimulat*. déc 2020;13(6):1687–8.
- [10] Carvallo JFB, Simpson R, Jankovic J. Diagnosis and treatment of complications related to deep brain stimulation hardware. *Mov Disord* 2011;26(8):1398–406.

Matthieu Villessot

Département de Neurochirurgie, Centre Hospitalier Universitaire
Montpellier, Montpellier, France

Département de Neurologie, Centre Hospitalier Universitaire
Montpellier, Montpellier, France

Diane Demailly, Emilie Chan-Seng, Gaëtan Poulen

Département de Neurochirurgie, Centre Hospitalier Universitaire
Montpellier, Montpellier, France

Sophie Huby

Département de Neurochirurgie, Centre Hospitalier Universitaire
Montpellier, Montpellier, France

Département de Neurologie, Centre Hospitalier Universitaire
Montpellier, Montpellier, France

Thomas Roujeau

Département de Neurochirurgie, Centre Hospitalier Universitaire
Montpellier, Montpellier, France

Morgan Dornadic

Département de Neurochirurgie, Centre Hospitalier Universitaire
Montpellier, Montpellier, France

Département de Neurologie, Centre Hospitalier Universitaire
Montpellier, Montpellier, France

Marc Vérin, Audrey Riou

Department of Neurology and Reference Center for Rare Intellectual
Disability Medical Genetics Department, Rennes University Hospital,
Behaviour and Basal Ganglia Research Unit, University of Rennes,
Rennes, France

Philippe Coubes¹, Laura Cif^{*1}

Département de Neurochirurgie, Centre Hospitalier Universitaire
Montpellier, Montpellier, France

* Corresponding author.

E-mail address: a-cif@chu-montpellier.fr (L. Cif).

27 March 2022

Available online 9 June 2022

¹ shared contribution.