



HAL
open science

Cerebral sinovenous thrombosis associated with head/neck infection in children: Clues for improved management

Lucie Narcy, Sabine Durand, Marion Grimaud, Nicolas Leboucq, David Grevent, Gilles Cambonie, Vincent Couloigner, Francois Rivier, Pierre Meyer, Manoelle Kossorotoff

► To cite this version:

Lucie Narcy, Sabine Durand, Marion Grimaud, Nicolas Leboucq, David Grevent, et al.. Cerebral sinovenous thrombosis associated with head/neck infection in children: Clues for improved management. *Developmental Medicine and Child Neurology*, In press, 10.1111/dmcn.15331 . hal-03711579

HAL Id: hal-03711579

<https://hal.science/hal-03711579>

Submitted on 1 Jul 2022

HAL is a multi-disciplinary open access archive for the deposit and dissemination of scientific research documents, whether they are published or not. The documents may come from teaching and research institutions in France or abroad, or from public or private research centers.

L'archive ouverte pluridisciplinaire **HAL**, est destinée au dépôt et à la diffusion de documents scientifiques de niveau recherche, publiés ou non, émanant des établissements d'enseignement et de recherche français ou étrangers, des laboratoires publics ou privés.

Cerebral sinovenous thrombosis associated with head/neck infection in children: Clues for improved management

Lucie Narcy^{1,2,†} | Sabine Durand^{3,†} | Marion Grimaud⁴ | Nicolas Leboucq⁵ |
David Grevent⁶ | Gilles Cambonie³ | Vincent Couloigner⁷ | François Rivier⁸ |
Pierre Meyer^{8,§} | Manuelle Kossorotoff^{1,9,§} 

¹Paediatric Neurology Department, APHP, University Hospital Necker-Enfants Malades, Paris, France

²Sorbonne Université, Paris, France

³Paediatric and Neonatal Intensive Care Unit, CHU Arnaud de Villeneuve, Montpellier, France

⁴Paediatric Intensive Care Unit, APHP, University Hospital Necker-Enfants Malades, Paris, France

⁵Paediatric Imaging Department, CHU Arnaud de Villeneuve, Montpellier, France

⁶Paediatric Imaging Department, APHP, University Hospital Necker-Enfants Malades, Paris, France

⁷Paediatric Otorhinolaryngology Department, APHP, University Hospital Necker-Enfants Malades, Paris, France

⁸Paediatric Neurology Department, Phymedexp, Montpellier University, Inserm, CNRS, University Hospital Montpellier, Montpellier, France

⁹French Centre for Paediatric Stroke, APHP, University Hospital Necker-Enfants Malades, Paris, France

Correspondence

Manuelle Kossorotoff, Paediatric Neurology Department, University Hospital Necker-Enfants Malades, 149 rue de Sevres, 75015 Paris, France.
Email: manuelle.kossorotoff@aphp.fr

Abstract

Aim: To compare paediatric patients with cerebral sinovenous thrombosis (CSVT) with and without head/neck infection to improve management of the condition.

Method: We conducted a bicentric retrospective study of consecutive children (neonates excluded) with radiologically confirmed CSVT, comparing children with a concurrent head/neck infection and children with other causes.

Results: A total of 84 consecutive patients (46 males and 38 females) with a median age of 4 years 6 months (range 3 months–17 years 5 months) were included. Associated head/neck infection was identified in 65.4% of cases and represented the main identified CSVT aetiology. Children in the head/neck infection group displayed a milder clinical presentation and less extensive CSVT. Median time to complete recanalization was significantly shorter in this group (89 days [interquartile range 35–101] vs 112.5 days [interquartile range 83–177], $p = 0.005$). These findings were even more pronounced in the subgroup of patients with otogenic infection and no neurological sign.

Interpretation: As CSVT in the setting of an otogenic infection and no neurological sign seems to represent a milder condition with a shorter course, these results suggest adapting current recommendations: consider earlier control imaging in paediatric otogenic CSVT, and shorter anticoagulant treatment if recanalization is obtained.

Cerebral sinovenous thrombosis (CSVT) occurrence is rare in children, with an incidence of about 0.67 cases per 100 000 children per year. This is probably underestimated as diagnosis is often delayed or missed.^{1,2} It is a potentially severe condition, as children with CSVT are at risk for complications in the acute phase, such as intracranial hypertension, seizures, ischemic and/or haemorrhagic venous stroke, and for long-term sequelae, such as visual

impairment, and motor or cognitive disabilities.¹ Despite recent advances, diagnostic and therapeutic strategies for CSVT in children still suffer from lack of evidence, and consequent heterogeneity.^{1–3} Paediatric management recommendations are mostly adapted from adult literature.^{3,4} Treatment in adults relies on anticoagulation therapy, initially with unfractionated heparin or low-molecular-weight heparin, followed by vitamin K antagonists or

Abbreviations: CSVT, cerebral sinovenous thrombosis; INF–, no head/neck infection; INF+, head/neck infection.

†joint first authors.

§joint last authors.

direct oral anticoagulants, regardless of the presence of intracranial haemorrhage if secondary to the thrombosis.² Therapeutic studies are lacking in paediatric CSV T, especially randomized controlled trials. Despite concerns about age-related differences in the coagulation and neurological systems, a consensus has formed in favour of anticoagulation therapy in older children (i.e. excluding neonates) with CSV T.^{3,5} A 3- to 6-month treatment has been proposed as the standard duration in most studies,³ and may be adapted to each situation and risk factor. While CSV T symptoms are quite similar in children and adults,⁶ the clinical context in which they appear may be different. Infection-related CSV T, mainly in the head and neck (ear, sinus, mouth, face, and neck), explains only 8.2% of adult cases, while it is much more common in paediatric cases (23%–49%).^{1,2,7–9} Although data from a few studies suggest a 'less severe' condition, with a lower risk of spontaneous recurrence,^{3,10,11} paediatric CSV T occurring in an infectious setting has not been compared to CSV T occurring in other settings. The present study focused on a comparison between paediatric patients with CSV T with and without head/neck infection to identify potential adaptations of management between groups.

METHOD

Patients

We conducted a bicentric retrospective study of consecutive paediatric patients with CSV T in two academic centres. Newly diagnosed CSV T cases aged from 1 month to 18 years who were admitted to the Arnaud de Villeneuve University Regional Hospital (Centre A), Montpellier, France or the University Hospital Necker-Enfants Malades (Centre B), Paris, France, during a 11 year and 6 year 4 month inclusion period respectively, were identified from electronic health records using adequate International Classification of Diseases, 10th Revision diagnostic codes. Patients were eligible if they had a radiologically confirmed CSV T affecting at least one of the following vessels: transverse sinus, sigmoid sinus, internal jugular vein, superior sagittal sinus, inferior sagittal sinus, straight sinus, cavernous sinus, and/or petrosal sinus during the inclusion period. Patients with either isolated cortical vein thrombosis, isolated jugular vein thrombosis in the presence of a central line, or thrombosis in the presence of a cardiopulmonary bypass were excluded. Imaging data were reviewed by paediatric neuroradiologists (NL, DG). Patients were included in the head/neck infection (INF+) group if they presented a concurrent otogenic (mastoiditis, otitis media) or non-otogenic (sinusitis, cervical infection, meningitis, etc.) head/neck infection at the time of CSV T diagnosis; they were included in the no head/neck infection (INF-) group if otherwise. Clinical, biological, and radiological data at presentation, and long-term clinical and radiological follow-up data were obtained from medical records.

- Children with cerebral sinovenous thrombosis related to head/neck infections have a milder clinical presentation.
- They also have a shorter recanalization time, especially if there is otogenic infection without neurological symptoms.

Acute phase

Sex, age, and clinical presentation were recorded. CSV T-related neurological signs at diagnosis were defined as the presence of seizures, decreased level of consciousness (defined as Glasgow Coma Scale <12), focal symptoms including cranial nerve abnormalities, or intracranial hypertension (defined as headache associated with vomiting, elevated cerebrospinal fluid pressure if measured during a lumbar puncture, papilledema on fundoscopy, and/or elevated intracranial pressure observed by invasive intracranial pressure monitoring). Focal neurological signs, coma, and acute seizures were considered as potential markers of a parenchymal brain lesion, whereas diplopia or acute strabismus with sixth cranial nerve palsy were considered as intracranial hypertension symptoms. Imaging procedures performed at the acute phase, including computerized tomography (CT), magnetic resonance imaging (MRI), computerized tomography venography, and magnetic resonance venography were analysed. Extensive CSV T was defined as a CSV T affecting more than one venous segment. Parenchymal brain lesions on CT or MRI were recorded, including abscess, infarction, haemorrhage, and white matter anomalies. Other concurrent acute (notably anaemia, dehydration, head trauma, systemic infection) or chronic (notably sickle cell disease, nephrotic syndrome, systemic inflammatory disorder, neoplasia) conditions which are known as potential CSV T risk factors were also noted. The use of anticoagulant or antithrombotic therapy, type of drug (aspirin, low-molecular-weight heparin, unfractionated heparin, vitamin K antagonists), and treatment duration were recorded.

Thrombophilia workup

Results from biological screening for prothrombotic risk factors performed in the acute phase (first week after diagnosis) were analysed. The following results were considered as prothrombotic risk factors (positive thrombophilia workup): protein C activity less than 50%, protein S activity less than 60%, antithrombin activity less than 75%, presence of the prothrombin *G20210A* mutation, presence of the Factor V *R506Q* mutation, presence of a homozygous methylene-tetrahydrofolate-reductase gene mutation (*C677T* or *A1298C*) or plasma homocysteine dosage greater

than 15 µmol/L, or presence of antiphospholipid antibodies (lupus anticoagulant, anticardiolipin, anti-β2GPI).

Outcomes

Radiological outcome studied the delay from diagnosis to complete recanalization, defined as an uninterrupted flow signal with a residual luminal narrowing of less than 50% in the previously affected venous segment(s).¹⁷ Clinical outcome at last visit, including fatality, was evaluated using the modified Rankin Scale adjusted for children, retrospectively estimated through the patient's record data. Significant events during follow-up, such as symptomatic haemorrhage during anticoagulant treatment, occurrence of heparin-induced thrombocytopenia, CSVT relapse, or occurrence of another venous thrombotic event, were collected.

Analyses

Descriptive analyses were performed to study data distribution among the children in the INF+ and INF- groups. Comparison between the groups was performed using the Kruskal–Wallis test for continuous variables, and Fisher's exact test for categorical variables. A Kaplan–Meier analysis with a log-rank test was performed to compare recanalization rate over time between groups. A *p*-value of 0.05 or less was retained for significance. Statistical analyses were performed using the R software version 4.0.5 and the R Studio development interface version 1.3.1093 (R Foundation for Statistical Computing, Vienna, Austria).

Local institutional review boards (Comité de Protection des Personnes Ile-de-France & Occitanie) approved the study and waived patient consent for this retrospective analysis of anonymized data.

RESULTS

A total of 84 consecutive patients (36 patients in centre A, 48 in centre B) verified the inclusion criteria. There were 46 males and 38 females (sex ratio 1.2), with a median age of 4 years 6 months (range 3 months–17 years 5 months). Most patients (*n* = 80, 95.2%) had an identified aetiology of their CSVT episode. An associated head/neck infection was found in 65.4% of all cases (INF+; *n* = 55), a similar proportion in both centres (72.2% vs 60.4%, non-significant), and represented the main identified CSVT aetiology. Infections were mainly otogenic (oto-mastoiditis *n* = 36, isolated otitis media *n* = 1). Other infections were meningitis (*n* = 10), sinusitis (*n* = 5), cervical adenophlegmon or parapharyngeal abscess (*n* = 4), and facial cellulitis (*n* = 1). Only 53% of patients with mastoiditis had bacterial identification, the most frequent germ being fusobacterium. Potential risk factors for CSVT were identified in almost every patient without head/

neck infection (*n* = 27/29): 44.8% had a chronic or subacute prothrombotic condition, 27.5% had loco-regional non-infectious conditions, and 20.6% had a transient or acquired prothrombotic risk factor. Chronic or subacute prothrombotic condition included nephrotic syndrome (*n* = 4), Behcet disease (*n* = 4), systemic vasculitis (*n* = 1), sickle cell disease (*n* = 2), lupus associated with antiphospholipid syndrome and nephrotic syndrome (*n* = 1), and lymphoblastic acute leukaemia with L-asparaginase treatment (*n* = 1). Loco-regional non-infectious conditions included central nervous system tumour (*n* = 2), head trauma (*n* = 4), cerebrovascular malformation (*n* = 1), and acute disseminated encephalomyelitis (*n* = 1). Transient or acquired prothrombotic risk factors were anaemia (*n* = 2; iron deficiency and inflammatory anaemia), dehydration (*n* = 2), disseminated intravascular coagulation related to sepsis (*n* = 1), and recently introduced combined oestrogen/progestin oral contraception (*n* = 1). Of note, one patient with mastoiditis who also had sickle cell anaemia and one patient with meningitis occurring after a traumatic skull fracture were classified in the INF+ group as the infection was considered as the final trigger for CSVT.

Comparison between the INF+ and INF- groups

The INF+ group were significantly younger (median age 3 years 8 months vs 10 years 7 months old, *p* < 0.001), and more frequently had fever at presentation (96.4% vs 10.3%, *p* < 0.001) than the INF- group (Table 1). Patients in the INF+ group displayed a milder clinical presentation (no CSVT-related neurological signs in 30.9% vs 6.9%, *p* = 0.014) than the INF- group. They also had less frequent symptoms of intracranial hypertension (21.8% vs 64.3%, *p* < 0.001), or associated intracranial haemorrhage (1.8% vs 24.1%, *p* = 0.002). Diagnostic CT venography was performed in 82% of patients, magnetic resonance venography in 40%, and both modalities in 27%. CSVT associated with head/neck infection was less frequently extensive (27.3% vs 65.5%, *p* = 0.001) (Table 2, Figure 1). No patient required endovascular intervention. Anticoagulation treatment was comparable in the acute phase, with 81 out of 84 patients treated by unfractionated heparin or low-molecular-weight heparin. Of note, 76% of the INF+ patients (data available only for centre B) had surgical intervention; anticoagulation treatment was started shortly after surgery in these cases. Bridging to vitamin K antagonists was less frequent in the INF+ group (32.7% vs 58.6%, *p* = 0.034). Median anticoagulation treatment duration tended to be shorter in the INF+ group (3 vs 4 months, *p* = 0.08, non-significant). Most patients had a thrombophilia biological screening at the acute phase (78% and 96% in the INF+ and INF- groups respectively, non-significant). This workup was less frequently positive in the INF+ group (32% vs 44%, non-significant). In seven patients from the INF+ group with a positive antiphospholipid antibody result, a control test was performed several months later, which showed normalization of this parameter in all patients.

TABLE 1 Comparison between children with cerebral sinovenous thrombosis (CSVT) and head/neck infection (INF+) and no head/neck infection (INF-)

	INF+	INF-	<i>p</i>
<i>n</i>	55	29	
Median age, years:months (IQR)	3:8 (1:11–6:7)	10:7 (6:4–14:2)	<0.001
Males	32 (58.2)	14 (48.3)	0.490
Acute phase			
Fever	53 (96.4)	3 (10.3)	<0.001
Intracranial hypertension	12 (21.8)	18 (64.3)	<0.001
CSVT-related neurological symptoms	38 (69.1)	27 (93.1)	0.014
Associated intracranial haemorrhage	1 (1.8)	7 (24.1)	0.002
Associated ischaemic lesion	1 (1.8)	2 (6.9)	0.273
Outcomes			
Median follow-up, months (IQR)	7 (6–24)	30 (12–51.5)	0.002
Median time to complete recanalization, days (IQR)	89 (35–101)	112 (83–177)	0.005
Complete recanalization at 3 months	29 (65.9)	8 (36.4)	0.035
Complete recanalization at end of follow-up	44 (86.3)	21 (77.8)	0.355
Anticoagulant treatment	52 (96.3)	29 (100.0)	0.540
Median anticoagulant treatment duration, months (IQR)	3 (3–4)	4 (3–6)	0.080
mRS = 0 in survivors	45/52 (86.5)	15/26 (57.7)	0.009

Data are *n* (%) unless otherwise stated. Bold type indicates statistical significance. Abbreviations: IQR, interquartile range; mRS: modified Rankin Score.

TABLE 2 Cerebral sinovenous thrombosis (CSVT) location: comparison between children with CSVT and head/neck infection (INF+) and without regional infection (INF-)

	INF+	INF-	<i>p</i>
<i>n</i>	55	29	
Affected sinus			
Superficial venous system CSVT			
Transverse sinus	37 (67.3)	21 (75.0)	0.614
Sigmoid sinus	8 (14.5)	1 (3.6)	0.261
Internal jugular vein	17 (30.9)	9 (32.1)	1.000
Superior sagittal sinus	7 (12.7)	13 (46.4)	0.001
Deep venous system CSVT			
Inferior sagittal sinus	0 (0)	0 (0)	-
Straight sinus	0 (0)	0 (0)	-
Cavernous sinus	3 (5.5)	0 (0)	0.547
Petrosal sinus	0 (0)	0 (0)	-
Extensive CSVT			
CSVT affecting several venous segments	15 (27.3)	19 (65.5)	0.001

Data are *n* (%) unless otherwise stated. Bold type indicates statistical significance.

Outcomes

Two patients in the INF+ group died because of a bacterial meningitis complicated by massive intracranial hypertension. Median follow-up duration for survivors was 12 months. Median time to complete recanalization was significantly shorter in the INF+ group (89 days vs 112.5 days, $p = 0.005$). Taking into account censored patients and different follow-up durations, the difference in

the time to complete recanalization remained significant ($p = 0.031$, [Figure 2](#)). The rate of complete recanalization was significantly higher in the INF+ group at 3 months (65.9% vs 36.4%, $p = 0.035$) but not significantly different at the end of follow-up (86.3% vs 77.8%, $p = 0.35$). No heparin-induced thrombocytopenia or any symptomatic haemorrhage during anticoagulant treatment was reported. Three patients in the INF- group experienced a CSVT relapse during follow-up; two had Behcet disease

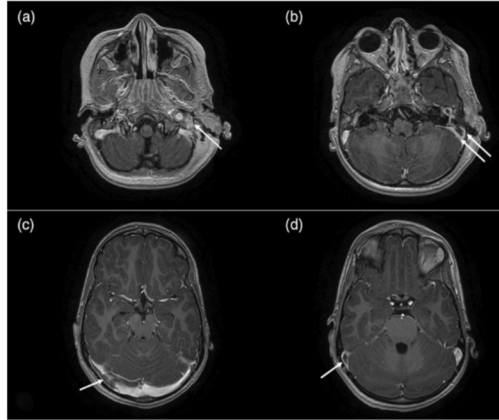


FIGURE 1 Magnetic resonance imaging (MRI) scan of a 3-year-old male with left mastoiditis (a; arrow) and cerebral sinovenous thrombosis (CSVT) in the left sigmoid sinus (b; double arrow), gadolinium enhanced T1 axial sequence. MRI of a 11-year-old male with Behcet disease and extensive CSVT in the right transverse (c) and sigmoid sinuses (d; arrows), gadolinium enhanced T1 axial sequence

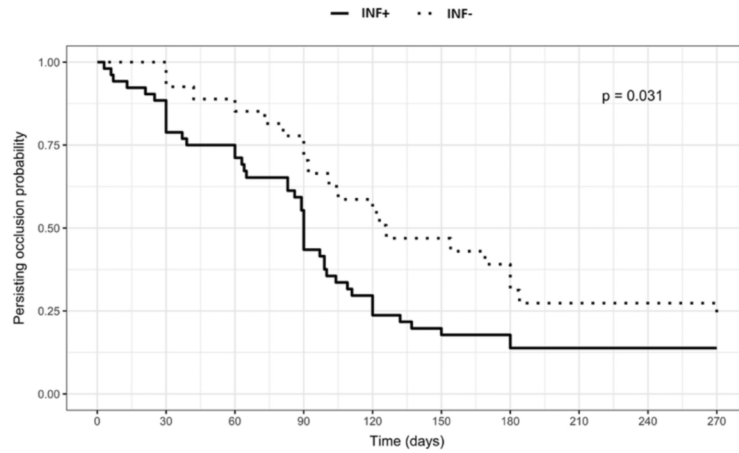


FIGURE 2 Time to recanalization in children with cerebral sinovenous thrombosis and head/neck infection (INF+) compared to children without locoregional infection (INF-), Kaplan–Meier analysis

and one had no identified condition. Clinical outcome in survivors was significantly better in the INF+ group, with an excellent outcome (modified Rankin Scale = 0) at last visit in 86.5% versus 57.7% in the INF- group ($p = 0.009$).

Patients with CSVT associated with otogenic infection and no neurological sign

Among the INF+ group, a subgroup of patients with otogenic infection (mastoiditis with or without otitis) without

any neurological sign at the acute phase was specified. It represented 13 out of 36 otogenic infections. Children in this subgroup displayed the above-mentioned specific features in an even more pronounced way: they were significantly younger than the other patients with CSVT (median age 2 years 5 months vs 6 years 4 months, $p = 0.003$) and had an even shorter time to complete recanalization compared to the INF- group and the rest of the INF+ group (median 64 days vs 90 days, $p = 0.026$) (Figure 3).

DISCUSSION

This study compared children with CSVT with and without concurrent head/neck infection. The children in the INF- group resembled adults in terms of aetiology, clinical presentation, and evolution under anticoagulant treatment. Thus, current paediatric recommendations for CSVT, which are largely adapted from adult guidelines, seem appropriate for this subgroup. On the contrary, our study delineated a specific subpopulation of children with regional infection (INF+) with clinical, radiological, and outcomes specificities, for whom slightly different management strategies could be considered.

This study included one of the largest samples of patients with paediatric CSVT ($n = 84$) over a limited period in only two centres. Patients with concurrent head/neck infection outnumbered previous reports, which allowed a comprehensive study of this subpopulation and its comparison with paediatric CSVT from other causes. In our sample, most CSVTs

(95.2%) were related to an underlying condition (previously diagnosed or revealed by the CSVT) or a precipitating event, as previously reported (95% in Dlamini et al.).¹³ Associated head/neck infection was the most frequent aetiology (65.5%), with a higher rate than reported in the years 2001 to 2005 (23%–49%).^{1,6} Increased diagnosis of asymptomatic CSVT since the implementation of systematic CT imaging in mastoiditis workup^{14,15} may account for this difference.

Children with CSVT associated with head/neck infection were younger and had milder clinical and radiological presentations than children with other causes. They also had better outcomes. In the literature, reported outcome in this setting is very heterogeneous, with variable measurement tools. A prevalence of 25% to 74% of long-term sequelae is reported,¹⁶ usually associated with a severe initial presentation and/or a persisting risk factor for recurrence.¹ In our study, the prevalence of sequelae (modified Rankin Scale ≥ 1) was 23.1% in the whole sample, and significantly lower in the INF+ group, although two patients from this group had early fatal outcome related to severe bacterial meningitis. These results were more significant in the subgroup of children with CSVT associated with otogenic infection without neurological symptoms, in which all patients had a modified Rankin Scale score of 0 at the end of their follow-up.

Interestingly, children with CSVT associated with a head/neck infection displayed a significantly higher rate of venous recanalization at 3 months follow-up and a global quicker recanalization. In guidelines, assessing recanalization to support the decision of anticoagulant treatment weaning is often recommended at 3 months post-CSVТ, and

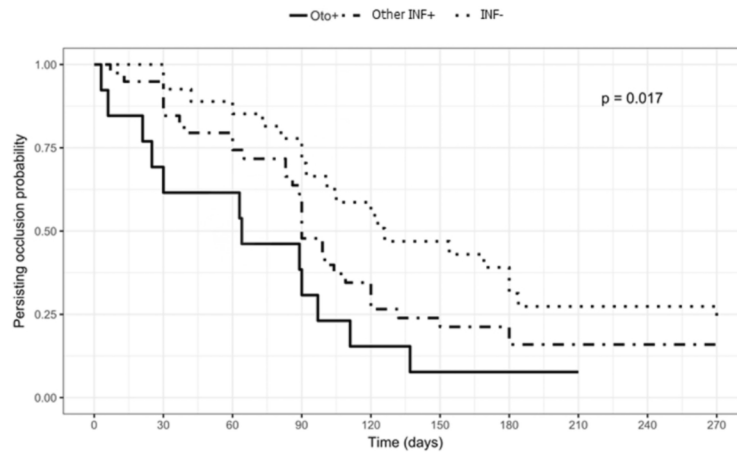


FIGURE 3 Comparison of times to recanalization between groups: children with cerebral sinovenous thrombosis (CSVТ) and otogenic infection with no neurological symptom (Oto+), children with CSVТ and other head/neck infection (Other INF+), and children without loco-regional infection (INF-), Kaplan-Meier analysis

at 6 months if recanalization was not complete at the first control.³ In our study, CSVT management focused on these recommendations as most patients had control imaging at these predetermined delays. Actual recanalization delays may be shorter: in half of the patients with otogenic infection and no neurological symptom recanalization was complete 65 days after CSVT onset (Figure 2), that is, nearly 1 month before first recommended imaging control. One could suggest re-imaging earlier in this setting, for example at 6 to 8 weeks from onset, and stopping anticoagulant treatment if recanalization was obtained and the initial infection cured. To our knowledge, some centres have already implemented this practical management, but no formal report or comparative study is available so far to estimate its efficiency (early patency diagnosis allowing shorter anticoagulation treatment vs no patency leading to supplemental re-imaging). The role of anticoagulation treatment in the recanalization rate has been debated.^{3,17} In this study most children in both groups had anticoagulation treatment – as recommended in Europe³ – suggesting that the observed difference in recanalization delay instead relates to the cause of CSVT. In our patients, anticoagulant therapy was well tolerated and no major treatment-related complication was reported, as suggested in previous paediatric reports.³

Concerning thrombophilia workup, we observed large variations in assessed parameters according to centres and over time. Globally, it was positive in 37% of patients, with a lower prevalence in the INF+ group. Previous studies reported positive thrombophilia screening in childhood CSVT in up to 60% of cases.¹⁶ It is currently unknown if these abnormalities are either causal, causal factors in association with other risk factors, or if they may be epiphenomena.^{16,18} In mastoiditis complicated by CSVT, Coudert et al.¹⁹ reported a significant predominance of *Fusobacterium necrophorum*, found in 53.8% in this setting. Similarly, in our study, *Fusobacterium necrophorum* was the most prevalent germ, found in 57% of patients with an identified germ. Indeed, *Fusobacterium necrophorum* is known to particularly induce an inflammatory state, which becomes a prothrombotic state.^{20,21} In our study, a late thrombophilia workup in a subgroup of patients with mastoiditis and positive initial workup showed the normalization of antiphospholipid antibody dosage after the infection episode, pointing to a risk of false-positive results at the acute phase of an infection. These findings suggest that the need for prolonged treatment may be infrequent in CSVT associated with head/neck infection and that thrombophilia workup could be delayed to 1 to 3 months after CSVT onset to avoid false-positives related to the acute inflammatory phase.

As mentioned above, specificities of children with CSVT and concurrent head/neck infection were even more pronounced in the subgroup of children with otogenic infection without neurological symptoms. As the number of patients in this subgroup was quite small ($n = 13$), we could not carry out further statistical analyses, but these results were consistent with a previous reported study on otogenic paediatric CSVT.¹⁰ These findings support the suggestion to adapt

current recommendations concerning CSVT management in children, with earlier control imaging and delayed thrombophilia workup.

The major limitation of our study is its retrospective nature, with associated intrinsic biases. Participating centres were academic tertiary centres with highly specialized paediatric departments, including paediatric ear nose and throat and paediatric neurosurgery departments, which may have modified the repartition of CSVT causes. To evaluate outcomes, limited available data precluded the use of the dedicated Pediatric Stroke Outcome Measure scale, and we used the modified Rankin Scale adjusted for children, although it is less precise in this setting. Another limitation is related to anticoagulant treatment. In this sample, nearly all patients were treated. The above-mentioned suggestions for adapted management of CSVT with regional infection are thus supported by data from treated patients only. This study does not address the issue of the anticoagulant treatment indication in paediatric otogenic CSVT, which is debated in the literature. Guidelines usually recommend anticoagulant treatment for non-neonatal paediatric CSVT,^{3,16,22} with a suggested individualized approach for some circumstances, including otogenic infection.¹⁶ Some authors suggest that adequate infection treatment (associating antibiotics and local surgery) may be sufficient,^{17,23} whereas others suggest that anticoagulant treatment may prevent CSVT extension during the inflammatory prothrombotic acute phase. The tolerance of anticoagulant treatments in children is satisfactory in this setting, including for recent drugs.^{22,24} But compliance may be difficult to obtain in case of repeated injections (low-molecular-weight heparin) or lab tests (vitamin K antagonists). Thus, alleviation of anticoagulant treatment burden, either by modifying galenic forms or by reducing treatment duration, remains an important goal to improve the patients' quality of life. Additional studies are encouraged to verify the relevance of the suggested measures.

CONCLUSION

The subgroup of children with CSVT associated with head/neck infection are younger patients, they have milder clinical presentations, a quicker venous recanalization, and better outcomes, especially in cases with otogenic infections. These findings suggest adapting current recommendations concerning CSVT management in children in the setting of otogenic infection without neurological symptoms. Under anticoagulant treatment, imaging control is suggested earlier than the usual 3 months delay, allowing anticoagulant treatment weaning if recanalization is obtained and the initial infection cured. Thrombophilia workup could be delayed after the CSVT acute phase because of the initial rate of false-positive results in the inflammatory period. These measures could help alleviate the burden of CSVT and anticoagulant treatment in these young children.

ACKNOWLEDGMENTS

The authors have stated that they had no interests that might be perceived as posing a conflict or bias.

DATA AVAILABILITY STATEMENT

The authors have full access to all of the data, which will be made available to any researcher for purposes of reproducing the results.

REFERENCES

1. deVeber G, Andrew M, Adams C, Bjornson B, Booth F, Buckley DJ, et al. Cerebral Sinovenous Thrombosis in Children. *The New England Journal of Medicine*. 2001 Aug 9;345(6):417–23.
2. Saposnik G, Barinagarrementeria F, Brown RD, Bushnell CD, Cucchiara B, Cushman M, et al. Diagnosis and Management of Cerebral Venous Thrombosis. *Stroke*. 2011 Apr 1;42(4):1158–92.
3. Lebas A, Chabrier S, Fluss J, Gordon K, Kossorotoff M, Nowak-Göttl U, et al. EPNS/SFNP guideline on the anticoagulant treatment of cerebral sinovenous thrombosis in children and neonates. *Eur J Paediatr Neurol*. 2012 May;16(3):219–28.
4. Shlobin NA, LoPresti MA, Beestrum M, Lam S. Treatment of pediatric cerebral venous sinus thromboses: the role of anticoagulation. *Childs Nerv Syst*. 2020 Nov;36(11):2621–33.
5. Moharir MD, Shroff M, Stephens D, Pontigon A-M, Chan A, MacGregor D, et al. Anticoagulants in pediatric cerebral sinovenous thrombosis: a safety and outcome study. *Ann Neurol*. 2010 May;67(5):590–9.
6. Sebire G, Tabarki B, Saunders DE, Leroy I, Liesner R, Saint-Martin C, et al. Cerebral venous sinus thrombosis in children: risk factors, presentation, diagnosis and outcome. *Brain*. 2005 Mar;128(Pt 3):477–89.
7. Stam J. Thrombosis of the Cerebral Veins and Sinuses. *New England Journal of Medicine*. 2005 Apr 28;352(17):1791–8.
8. Ichord RN, Benedict SL, Chan AK, Kirkham FJ, Nowak-Göttl U, International Paediatric Stroke Study Group. Paediatric cerebral sinovenous thrombosis: findings of the International Paediatric Stroke Study. *Arch Dis Child*. 2015 Feb;100(2):174–9.
9. Boncoraglio G, Carriero MR, Chiapparini L, Ciceri E, Ciusani E, Erbetta A, et al. Hyperhomocysteinemia and other thrombophilic risk factors in 26 patients with cerebral venous thrombosis. *Eur J Neurol*. 2004 Jun;11(6):405–9.
10. Bales CB, Sobol S, Wetmore R, Elden LM. Lateral Sinus Thrombosis as a Complication of Otitis Media: 10-Year Experience at the Children's Hospital of Philadelphia. *Pediatrics*. 2009 Feb 1;123(2):709–13.
11. Kenet G, Kirkham F, Niederstadt T, Heinecke A, Saunders D, Stoll M, et al. Risk factors for recurrent venous thromboembolism in the European collaborative paediatric database on cerebral venous thrombosis: a multicentre cohort study. *Lancet Neurol*. 2007 Jul;6(7):595–603.
12. Stolz E, Trittmacher S, Rahimi A, Gerriets T, Röttger C, Siekmann R, et al. Influence of Recanalization on Outcome in Dural Sinus Thrombosis. *Stroke*. 2004 Feb 1;35(2):544–7.
13. Dlamini N, Billingham L, Kirkham FJ. Cerebral venous sinus (sinovenous) thrombosis in children. *Neurosurg Clin N Am*. 2010 Jul;21(3):511–27.
14. Vazquez E, Castellote A, Piqueras J, Mauleon S, Creixell S, Pumarola F, et al. Imaging of Complications of Acute Mastoiditis in Children. *RadioGraphics*. 2003 Mar 1;23(2):359–72.
15. Luntz M, Bartal K, Brodsky A, Shihada R. Acute mastoiditis: the role of imaging for identifying intracranial complications. *Laryngoscope*. 2012 Dec;122(12):2813–7.
16. Ferrero DM, Fullerton HJ, Bernard TJ, Billingham L, Daniels SR, DeBaun MR, et al. Management of Stroke in Neonates and Children: A Scientific Statement From the American Heart Association/American Stroke Association. *Stroke*. 2019 Mar;50(3):e51–96.
17. Wong BYW, Hickman S, Richards M, Jassar P, Wilson T. Management of paediatric otogenic cerebral venous sinus thrombosis: a systematic review. *Clin Otolaryngol*. 2015 Dec;40(6):704–14.
18. Nowak-Göttl U, van Ommen H, Kenet G. Thrombophilia testing in children: What and when should be tested? *Thromb Res*. 2018 Apr;164:75–8.
19. Coudert A, Fanchette J, Regnier G, Delmas J, Truy E, Nicollas R, et al. *Fusobacterium necrophorum*, a major provider of sinus thrombosis in acute mastoiditis: A retrospective multicentre paediatric study. *Clinical Otolaryngology*. 2020;45(2):182–9.
20. Le Monnier A, Jamet A, Carbonnelle E, Barthod G, Moumille K, Lesage F, et al. *Fusobacterium necrophorum* middle ear infections in children and related complications: report of 25 cases and literature review. *Pediatr Infect Dis J*. 2008 Jul;27(7):613–7.
21. Gelbart M, Bilavsky E, Chodick G, Raveh E, Levy I, Ashkenazi-Hoffnung L. *Fusobacterium necrophorum* as an Emerging Pathogen of Acute Mastoiditis. *Pediatr Infect Dis J*. 2019 Jan;38(1):12–5.
22. Monagle P, Cuello CA, Augustine C, Bonduel M, Brandão LR, Capman T, et al. American Society of Hematology 2018 Guidelines for management of venous thromboembolism: treatment of pediatric venous thromboembolism. *Blood Advances*. 2018 Nov 27;2(22):3292–316.
23. Mather M, Powell S, Yates PD, Powell J. Acute mastoiditis in children: contemporary opportunities and challenges. *J Laryngol Otol*. 2020 May;134(5):434–9.
24. Male C, Lensing AWA, Palumbo JS, Kumar R, Nurmeev I, Hege K, et al. Rivaroxaban compared with standard anticoagulants for the treatment of acute venous thromboembolism in children: a randomised, controlled, phase 3 trial. *Lancet Haematol*. 2020 Jan;7(1):e18–27.