



**HAL**  
open science

## Recommendations for the pragmatic use of ultrasound in rheumatoid arthritis by the GEISPER French group

Gaël Mouterde, Frédérique Gandjbakhch, Benoît Le Goff, Philippe Gaudin,  
Maria-Antonietta D'agostino

### ► To cite this version:

Gaël Mouterde, Frédérique Gandjbakhch, Benoît Le Goff, Philippe Gaudin, Maria-Antonietta D'agostino. Recommendations for the pragmatic use of ultrasound in rheumatoid arthritis by the GEISPER French group. *Joint Bone Spine*, 2021, 88 (4), pp.105187. 10.1016/j.jbspin.2021.105187 . hal-03704361

**HAL Id: hal-03704361**

**<https://hal.science/hal-03704361>**

Submitted on 24 May 2023

**HAL** is a multi-disciplinary open access archive for the deposit and dissemination of scientific research documents, whether they are published or not. The documents may come from teaching and research institutions in France or abroad, or from public or private research centers.

L'archive ouverte pluridisciplinaire **HAL**, est destinée au dépôt et à la diffusion de documents scientifiques de niveau recherche, publiés ou non, émanant des établissements d'enseignement et de recherche français ou étrangers, des laboratoires publics ou privés.



Distributed under a Creative Commons Attribution - NonCommercial 4.0 International License

## **Recommendations for the pragmatic use of ultrasound in rheumatoid arthritis by the GEISPER French group**

Gaël Mouterde<sup>1</sup>, Frédérique Gandjbakhch<sup>2</sup>, Benoît Le Goff<sup>3</sup>, Philippe Gaudin<sup>4</sup>, Maria-Antonietta D'Agostino<sup>5</sup>

<sup>1</sup> Rheumatology Department, CHU Montpellier, Montpellier University, Montpellier, France

<sup>2</sup> Sorbonne Université, Paris France; Pitié Salpêtrière hospital, APHP, Rheumatology department, Paris, France.

<sup>3</sup> Rheumatology Department, Centre Hospitalier Universitaire de Nantes, Nantes, France ; INSERM UMR 1238, Faculty of Biology of Nantes, Nantes, France

<sup>4</sup> Rheumatology Department, CHU Grenoble Alpes Hôpital Sud, Echirolles, France ; GREPI - Université Grenoble Alpes, EA7408, St Martin d'Hères France

<sup>5</sup> Ambroise Paré Hospital, APHP, Université Versailles-Saint-Quentin en Yvelines - Rheumatology, Boulogne-Billancourt, France.

### **Auteur correspondant :**

Maria Antonietta D'Agostino

APHP, Hôpital Ambroise Paré, Département de Rhumatologie, FR-92100 Boulogne-Billancourt;

FRANCE

Email : [maria-antonietta.dagostino@aphp.fr](mailto:maria-antonietta.dagostino@aphp.fr)

Téléphone : +33149095687

Fax : +33149095865

### **Word count :**

**Abstract : 221**

**Full text : 3 433**

**ABSTRACT:**

**Objective:** To develop recommendations for the appropriate use of ultrasound in the management of rheumatoid arthritis (RA) in routine practice based on data from the literature and of experts opinion.

**Methods:** Based on a systematic literature review, a scientific committee decided on themes and relevant questions to draw up an initial draft of recommendations. These recommendations were submitted to a group of experts in ultrasound in rheumatic and musculoskeletal diseases using a Delphi method, which produced preliminary recommendations. These were submitted to an expanded group of ultrasound experts for relevance, comprehensibility and comprehensiveness. The level of agreement of the experts were recorded during a face-to-face meeting.

**Results:** Following two rounds of the Delphi, a consensus was reached on three overarching principles, including definitions of joints, tendons and articular sites to be examined, and 10 recommendations. These recommendations underline the benefit of ultrasound for the diagnosis of RA in cases of inflammatory arthralgia or undifferentiated arthritis as well as in assessing the extent of initial structural and inflammatory damage. They also define the role of ultrasound during follow-up or when considering treatment reduction once clinical remission has been achieved. Lastly, they illustrate the utility of ultrasound in facilitating technical procedures.

**Conclusion:** These 10 consensus-based recommendations should harmonize and optimize clinical practice and thus improve the management of RA patients.

**Keywords:** rheumatoid arthritis, ultrasound, recommendations.

## **INTRODUCTION**

Ultrasound has become an essential imaging modality in the management of patients with rheumatic and musculoskeletal diseases (RMDs). Since 2001, when the first university diploma specifically dedicated to the use of ultrasound for rheumatological diseases was proposed, this technique is now part of the training programme of the rheumatology specialty in France. Actively implicated in the European League Against Rheumatism (EULAR) Sonography courses and in the Outcome Measures in Rheumatology (OMERACT) ultrasound standardization studies, the French rheumatologists have greatly contributed to the widespread development of this technique for the clinical management of rheumatology patients. The GEISPER (Groupement des Echographistes Impliqués dans la Standardisation, les Publications et l'Éducation en Rhumatologie) is a group of sonographers developed to improve standardization and promote clinical research in ultrasound in France. In rheumatoid arthritis (RA), the most prevalent rheumatic disease evaluated by ultrasound, this technique has shown to be very effective to make an early diagnosis of inflammatory arthritis, to predict the development of RA in individuals at risk, to assess disease activity, structural damage, response to treatment, and clinical remission. Its numerous advantages have been highlighted in the EULAR recommendations for the use of imaging for the clinical management of RA [1] as well as in many other studies [2-8]. However the practice and use of ultrasound may change according to the difference in the management of these patients across countries. Yet these publications do not address all practical situations, and it would be important to compare these data against expert opinions to help practitioners to adapt general recommendations to their own daily practice. Recently, a group of European experts developed algorithms defining the role of ultrasound for the diagnosis, the evaluation of the treatment response and for the management of remission in patients with RA [9]. Although very comprehensive, these algorithms were thought as general proposals. Nevertheless, practice varies greatly from one country to the next because of differences in ultrasound training, availability of the machines, practitioners managing RA, so it appeared necessary to adapt these algorithms to the practice and draw up specific recommendations. The target population are rheumatologists involved in the management of RA, whatever their use of ultrasound or not in their practice. The aim of this paper was to present these recommendations for the pragmatic use of ultrasound in RA.

## METHODS

The recommendations were developed according to a multi step procedure carried out by a scientific committee of five rheumatologists, experts in ultrasound and being also involved in teaching this technique at national and international level (MADA, FG, PG, BLG, and GM) and a panel group of rheumatology experts coming from several university hospitals in France.

The overall procedure for developing these recommendations is shown in **Figure 1**.

### 1. Definition of themes and selection of scientific questions related to each theme by the scientific committee

The following questions were selected by the scientific committee during an initial preparatory meeting in July 2018 (**Figure 1**):

- 1) General principles: Which transducers and equipment should be used, which ultrasound modalities (B mode, Doppler mode) should be recommended, how should inflammatory and structural lesions be defined on ultrasound?
- 2) Sites to be examined: Where should inflammatory (i.e. synovitis, and tenosynovitis) and structural (i.e. erosions) ultrasound lesions be looked for?
- 3) Diagnosis: What is the role of ultrasound in the diagnosis of inflammatory arthralgia, early arthritis suggestive of RA and early RA?
- 4) Follow-up and response to treatment: What is the role of ultrasound in the follow-up and assessment response to treatment in RA?
- 5) Remission: What is the role of ultrasound for evaluating remission?
- 6) Treatment: What is the role of ultrasound in aiding guided interventions like joint aspirations and injections?

### 2. Systematic literature review

The Medline, Embase, and Cochrane Central databases were searched with the following criteria: no date limits, adult population, and English language. The query terms were those used in the systematic literature analysis for the EULAR recommendations for the use of imaging of the joints in the clinical management of RA as included in the supplementary material published in 2015 [1] and updated up to July 2018. The search was completed by consulting the bibliographic references lists of the selected articles.

The results of the systematic literature search were discussed during a face to face meeting, and completed with an analysis of the previously published algorithms [9]. If there was any uncertainty or any lack of evidence, a consensus was reached between the committee members, with 10 preliminary recommendations drawn up.

### 3. Validation of the proposed recommendations using a Delphi method

Thirty-five rheumatologists experts in ultrasound in RMDs and working in university hospital settings were emailed and asked to give their level of agreement with each recommendation on a Likert scale ranging from 1 to 5 (1 totally disagree, 5 totally agree). Each recommendation was validated if received at least 75% agreement (4 or 5 out of 5). In the event of disagreement ( $\leq 2$ ), the expert was asked to reformulate the recommendation. The results of the first Delphi round were presented to the same experts in a follow-up email and then a reformulated version of the recommendations that did not reach the required percentage of agreement was resubmitted for a second Delphi round.

### 4. Expert opinions and drawing up of recommendations

The agreed recommendations were then presented during a large face to face meeting in Montpellier in November 2018 attended by the members of the scientific committee, the panel of experts surveyed, and a selected group of French rheumatologists experts in the management of RA but not necessarily using ultrasound. The objectives of the meeting were to evaluate the relevance, comprehensiveness and comprehensibility of the proposed recommendations. The literature analysis used to build the preliminary recommendations was presented, and the recommendations were discussed during three workshops (1- diagnosis, 2- follow-up, and 3- remission and ultrasound-guided interventions). A final meeting to agree on the wording of the final recommendations was wrapped up.

### 5. Evaluation of the recommendations

All participants in a final plenary session voted on the final recommendations. Again the participants' level of agreement was evaluated on a Likert scale of 1 to 5. The applicability of each recommendation in practice was also evaluated in a second vote on a scale of 1 to 5 (1 = impossible, 5 = very easy).

## RESULTS

### 1. Delphi method

The response rate was 94.3% (33/35) for the first round and 100% (33/33) for the second. The demographic characteristics of the 33 experts are summarized in [Appendix A, Table S1; See the supplementary material associated with this article online]. After the first Delphi round, a consensus was achieved regarding two overarching principles and eight recommendations, the second round leading to a consensus on the third general principle (regarding definitions of joints, tendons and articular sites to be examined) as well as on the two remaining recommendations (**Table 1**).

### 2. Characteristics of participants at the Montpellier meeting

The demographic characteristics of the 76 participants are summarized in **Appendix A, Table S2**. They were mostly women (63.2%) of a median age of 41.5 years (extremes 29–68). Seventy-four of them were hospital-based, 11% worked in private practice only, and 16% combined private and hospital-based practice.

### 3. Drawing up of the recommendations

Three general principles and 10 recommendations were drawn up, and accompanied by the level of agreement among the experts (Percentage of participants with Likert scale  $\geq 4/5$ ) and the applicability of the recommendation in practice (**Table 2**).

## General principles

**1. Ultrasound examination in the management of chronic inflammatory arthritis such as RA requires:**

- **Assessment using an appropriate equipment with a high-frequency linear transducer and Doppler ultrasound suited to low-velocity flows;**
- **Bilateral assessment in B mode and Doppler mode;**
- **Semi-quantitative assessment of inflammatory lesions (synovitis and tenosynovitis) and screening for erosions according to OMERACT definitions and scores.**

*Level of agreement: 100%*

**2. Ultrasound findings indicating synovial or tenosynovial inflammation are hypoechoic synovial or tenosynovial hyperplasia including the presence of Doppler signal within the hypoechoic synovial or tenosynovial hyperplasia.**

*Level of agreement: 100%*

Since the anatomical structures of interest in RA are superficial and inflammation is associated with increased vascularization, a high-frequency linear transducer with suitable Doppler quality is required [10]. Consensus-based definitions of the main pathological lesions were formulated by the OMERACT Ultrasound Working Group [11, 12]. This group developed a standardized semi-quantitative scoring system (0–3) for synovitis [13] and tenosynovitis [12], which is adapted to any joint and tendon [14]. The experts highlighted the importance of interpreting the presence of grade 1 synovitis in B mode in the clinical context, since minimal synovitis may be found also in healthy subjects, especially in the feet, even if in a lower prevalence [15]. The experts discussed also the importance of considering other ultrasound elementary lesions such as osteophytes, or the presence of ultrasound findings indicating crystal arthropathies (e.g., double contour sign in the cartilage, hyperechoic deposits in the fibrocartilage ....), to help making the best diagnosis.

**3. The joints, tendons and bone sites most frequently involved in RA are listed in table 3. These sites should be always examined in priority when looking for ultrasound findings compatible with RA.**

*Level of agreement: 90.8% for joints, 97.4% for tendons and 100% for bone sites.*

Metatarsophalangeal joint 1 (MTP 1) was not chosen because it is frequently involved in degenerative diseases, gout, and even in healthy subjects [15]. The dorsal aspect examination of the joints was agreed since several studies have shown a better reliability and sensitivity of this approach to detect inflammatory and structural signs [16].

The choice of the tendons of the wrist was agreed because of the frequency of involvement [5, 17]. The decision to examine the tendons of the ankle was left at the discretion of the practitioner/sonographer.

A recent study comparing bone erosions in different rheumatic diseases showed that erosions detected at Metacarpophalangeal joints (MCPs) 2 and 5, MTP 5 joints and distal ulna are the most specific of RA [18]. The experts were keen to underline the relevance of examining not only the dorsal but also the lateral aspect of the MCP and MTP5 as part of a dynamic examination.

**Diagnosis**



**Recommendation 1: In patients with inflammatory arthralgia without clinical detected synovitis or tenosynovitis, ultrasound of the hands, wrists, feet, and symptomatic joints is recommended to screen for synovitis or tenosynovitis.**

*Level of agreement: 97.4%*

Recent data suggest that ultrasound can detect inflammatory lesions in patients at risk of developing RA who do not have clinical synovitis, independently of the presence of autoantibodies suggestive of RA [19-21]. The experts did not consider necessary to specify the duration of symptoms in this setting, but did deem it important to examine by ultrasound also symptomatic joints on top of the small joints of hands, wrists and feet listed in **Table 3**.

**Recommendation 2: In patients with early arthritis, it is worthwhile investigating the hands, wrists, feet and symptomatic joints on ultrasound to evaluate synovitis and tenosynovitis, to screen for erosion if erosion is not found on X-ray, or to inform possible differential diagnosis.**

*Level of agreement: 93.4%*

Ultrasound has shown its utility in addition to other clinical and laboratory findings to help diagnosing RA, particularly in seronegative patients [22]. Ultrasound can be used to increase the joint count required to fulfill the 2010 American College of Rheumatology (ACR)/EULAR criteria for RA [3, 23-26]. Recent data suggest that exploring tenosynovitis, particularly of finger flexor digitorum tendons, may have additional predictive value to diagnose RA [5]. Regarding structural damage, it was reiterated that this is useful only if erosion was not already detected on conventional radiography.

**Recommendation 3: In patients with early RA meeting 2010 ACR/EULAR criteria, ultrasound can be used to confirm the extent of inflammatory and structural involvement (i.e. erosions, hypervascularity with Doppler mode), or inform the differential diagnosis.**

*Level of agreement: 93.4%*

Ultrasound is valuable for confirming a diagnosis of RA as well as for avoiding overdiagnosis. Its utility has also been shown in discriminating between joint involvement and tendon or soft tissue involvement as well as in ruling out differential diagnoses such as psoriatic arthritis [27, 28] and polymyalgia rheumatica [29].

#### **Follow-up**

**Recommendation 4: Ultrasound is required when any disease-modifying anti-rheumatic drug (DMARD) is initiated or modified to evaluate inflammatory activity and establish a benchmark examination for any subsequent follow-up.**

*Level of agreement: 89.5%*

Several longitudinal studies have demonstrated the predictive value of ultrasound in terms of radiographic or functional outcome. In a population of subjects with early arthritis, the presence of Doppler synovitis was predictive of rapid radiographic progression at 1 year, as well as ultrasound-detected erosion was predictive of the occurrence of subsequent radiographic findings [2]. In established RA, Doppler synovitis was also predictive of subsequent radiographic progression [30]. Ultrasound has also shown good sensitivity to change, with improvement of ultrasound scoring systems one week after the initiation of a biologic agent [31]. US can also confirm the clinical suspect in order to avoid over-treatment and detect the presence of sub-clinical findings in patients with definite arthritis and pauci-symptomatic joints. Several experts expressed their concerns with this recommendation, since they did find always necessary to perform such examination in a so short time laps in patients initiating a biological treatment. It was therefore stipulated that the main value of ultrasound at the beginning of any treatment was to establish a benchmark examination for any subsequent follow-up.

**Recommendation 5: Systematic ultrasound follow-up of treated RA patients is not recommended except when patients and physicians disagree on activity, or when modification of treatment or a local injection procedure are being considered.**

**If an ultrasound follow-up is considered, it should be performed at least 3 months after initiation or modification of treatment.**

*Level of agreement: 100%*

Ultrasound is able to evaluate treatment response [31], however there is not enough data to suggest its use to guide treatment escalation in a treat to target approach. Two recent studies in early RA failed to show the superiority of an ultrasound tight control strategy targeting ultrasound remission over regular tight control strategy based on clinical evaluation to reach clinical remission at 18 and 24 months [32, 33]. Patients in the ultrasound tight control strategy group showed an increased tendency to be overtreated without no major improvement in clinical remission rate, although radiographic structural progression was reduced [33]. Therefore ultrasound might be useful for determining the presence or absence of inflammation when structural damage is a major concern. Efficacy of intraarticular glucocorticoid injections varies according to ultrasound findings at the time of injection, supporting the use of ultrasound as a tool to select joints that will benefit from intraarticular injections [34]. The time interval of 3 months between 2 ultrasound is based on the time interval suggested for clinical evaluation according to European and French guidelines on RA management [35, 36]. Hence, this time period was retained since no studies have been performed

on the utility of a shorter follow-up on patients' outcome in clinical practice except those on treat to target strategies.

**Recommendation 6: If ultrasound inflammation is accompanied by positive Doppler signal, a treatment modification should be considered.**

*Level of agreement: 98.7%*

The ability of ultrasound to predict clinical or radiographic outcomes has been shown in numerous studies [2, 6, 30, 37, 38]. At patient level, the presence of synovitis with a positive Doppler signal is predictive of an increase in the erosion radiographic score as well as rapid radiographic progression in recent RA at 1 or 2 years [2, 38]. The number of Doppler-positive synovitis, presence of rheumatoid factor, and elevation of the erythrocyte sedimentation rate are predictive of radiographic progression in established RA [30]. Ultrasound tenosynovitis of the extensor carpi ulnaris is predictive of MRI erosion score progression at 1 and 3 years [6]. At joint level, synovitis on B mode or Doppler mode is predictive of the appearance or aggravation of radiographic erosion in the same joint at 2 years [37]. The risk of radiographic progression was possibly even greater in joints that were clinically asymptomatic in that study. Even in the two recent tight control strategy studies, radiographic structural progression was reduced in the ultrasound tight control strategy group [32, 33].

**Recommendation 7: The periodic evaluation of pre-existing ultrasound erosions cannot be recommended because of lack of consensus in the literature.**

*Level of agreement: 98.7%*

In a longitudinal cohort of early arthritis, the presence of ultrasound erosion on B mode was predictive of the occurrence or aggravation of X-ray erosion in the same joint 1 year later, including in joints without initial radiographic lesions [2]. At patient level, ultrasound erosion is also predictive of radiographic progression at 2 years [2]. Ultrasound screening for erosion is therefore initially useful for diagnostic and prognostic purposes, but monitoring of erosion has not been reported in the literature.

## **Remission**

**Recommendation 8: In patients in clinical remission, if a treatment reduction is being considered, it would be helpful to perform an ultrasound examination to confirm that no subclinical synovitis or tenosynovitis is present.**

*Level of agreement: 100%*

Two recent longitudinal studies have investigated the utility of ultrasound before tapering treatment. A Spanish team demonstrated that the Doppler synovitis score and a high Disease Activity score 28 (DAS28) were the only baseline parameters predictive of failure at 1 year of tapering biologics [4]. A Japanese study also concluded that an initially high DAS28 score and synovitis scores on B mode and Doppler mode were the best predictors of clinical relapse at 6 months when biologic therapy was discontinued [39].

The experts stated that ultrasound examination was only useful if it might influence treatment, in other words before considering treatment reduction. It was not possible to recommend which joints or tendons should be examined in this setting.

**Recommendation 9: In patients in clinical remission, an absence of inflammatory activity on ultrasound confirm the possibility of treatment reduction. If Doppler-positive synovitis is detected, treatment reduction should be reconsidered based on the clinical context.**

*Level of agreement: 94.7%*

A meta-analysis of longitudinal studies has shown that at least one persistent Doppler-positive ultrasound synovitis grade  $\geq 1$  was predictive of clinical relapse and radiographic progression [40]. In such settings, consideration should be given to disease duration, since ultrasound synovitis is more prevalent in established RA [41], to the joint locations, particularly if concomitant osteoarthritic lesions are present, and to the damage of the joint. Concomitant tenosynovitis and synovitis was also a potential predictor of clinical relapse in an Italian longitudinal cohort [42]. Given the lack of literature data, it was impossible to suggest at what interval ultrasound should be repeated if a patient with clinical remission shows ultrasound signs of inflammation.

**Ultrasound-guided procedures:**

**Recommendation 10: Ultrasound guidance is recommended when performing joint aspiration or injections, particularly in some particular circumstances like moderate synovitis or effusion, hard-to-reach joints, and tendon sheaths.**

*Level of agreement: 97.4%*

Several studies have shown that ultrasound guidance of procedures such as aspiration and injections, improves their accuracy [43]. Ultrasound-guided injections seems to be less painful and more effective [43, 44, 45]. One study has shown that ultrasound-guided corticosteroid injections into tendon sheaths alleviate painful symptoms and decrease peritendinous Doppler inflammation for longer, while causing fewer local complications (particularly tendon rupture) compared with intramuscular corticosteroid injections [46].

However, the experts did wish to conditionally suggest this recommendation according to the joint location, since they believed that a local procedure could be performed without ultrasound guidance in superficial joints or in cases of abundant effusion. Other unusual situations were discussed, including joint changes which alter anatomic landmarks, administration of corticosteroid generating soft tissue atrophy, failure of previous clinical/anatomic landmarks injections, and bleeding risks.

Finally all participants were asked to evaluate the feasibility to implement these recommendations in clinical practice. The percentage of participants with level of agreement  $\geq 4/5$  is presented in **Table 2**.

#### **Funding:**

This research did not receive any specific grant from funding agencies in the public, commercial, or not-for-profit sectors.

#### **Conflicts of interest:**

This study was conducted as part of a project organized with the institutional support of AbbVie France. AbbVie had no other involvement in the project. The authors have no financial interest in the field discussed in the article. G. Mouterde, P. Gaudin, F. Ganjbakhch and MA. D'Agostino have no conflicts of interest to declare. B. Le Goff declares links of interest with Abbvie, MSD, BMS, Pfizer, Novartis, Roche-Chugai, AMGEN, Mylan (advisory boards, intermittent collaborations) and with Roche-Chugai, BMS, Pfizer, Novartis (research grants, subsidies).

#### **Acknowledgments:**

We wish to thank AbbVie for their logistical support, along with the 88 experts who took part in the Delphi process or who attended the meeting in Montpellier. Their contribution to formulating these recommendations was vital :

Marian Achiti, Stanley Ackah Miezian, Emilie Acquacalda, Jean-David Albert, Christine Albert Sabonnadiere, Adamah Amouzougan, Helene Bacquet Deschryver, Herve Bard, Catherine Beauvais, Aurélie Bisson Vaivre, Helene Boudinet Gascon, Karima Boussoualim, Salima Challal Tagri, Isabelle Charlot Lambrecht, Caroline Charpin, Emmanuel Chatelus, Gaëlle Clavel, Gregory Cohen, Guillaume Coiffier, Marion Couderc, Camille Deprouw, Emilie Ducourau Barbary, Carine Dufauret-Lombard, Géraldine Durand, Fabien Etchepare, Véronique Ferrazzi, Clémentine Fortunet, Aline Frazier Mironer, Nicole Garnier, Deborah Gensburger Lebhar, Dana Georgescu, Julia Goossens, Caroline Guillibert Karras, Cécile Guilyardi, Charlotte Hua, Clémentine Jacquier, Bénédicte Jamard, Sandrine Jousse Joulain, Baidy Sy Kane, Sandra Kossi Mavoungou, Macha Kozyreff Meurice, Marie-Christine Legouffe, Isabelle Legroux Gerot, Nathalie Leon, Daniel Liens, Damien Loeuille, Karine Louati, Géraldine Lupo Mattatia, Bernard Maillet, Jeremy Maillet, Saloua Mammou Mraghni, Pauline Manicki, Thierry

Marhadour, Frédéric Medina Ortiz, Florence Merle Vincent, Agnès Monnier Dutheil, Bertrand Moura, Aurélie Najm, Lauren Natella, Paul Ornetti, Sébastien Ottaviani, Muriel Piperno, Nicolas Poursac, Carole Rosenberg, Jean Michel Rouveix, Adeline Ruysen Witrand, Marcel Saguer, Nadia Salam, Jean Hugues Salmon, Luca Semerano, Maryse Simonati Roux, Solange Tang Hoang, Madjid Telmoun, Benoit Thomachot, Danielle Touzery, Sophie Trijau, Franck Verhoeven, Denis Verriere, Véronique Vesperini, François Vidal, Florence Vidal, Caroline Villoutreix, Eric Walser.

### **Appendix A. Supplementary data**

Supplementary data (Table S1-S2) associated with this article can be found in the online version at ...

## References

- [1]. Colebatch AN, Edwards CJ, Ostergaard M, van der Heijde D, Balint PV, D'Agostino MA, et al. EULAR recommendations for the use of imaging of the joints in the clinical management of rheumatoid arthritis. *Ann Rheum Dis*. 2013;72(6):804-14.
- [2]. Funck-Brentano T, Gandjbakhch F, Etchepare F, Jousse-Joulin S, Miquel A, Cyteval C, et al. Prediction of radiographic damage in early arthritis by sonographic erosions and power Doppler signal: a longitudinal observational study. *Arthritis Care Res (Hoboken)*. 2013;65(6):896-902.
- [3]. Nakagomi D, Ikeda K, Okubo A, Iwamoto T, Sanayama Y, Takahashi K, et al. Ultrasound can improve the accuracy of the 2010 American College of Rheumatology/European League against rheumatism classification criteria for rheumatoid arthritis to predict the requirement for methotrexate treatment. *Arthritis Rheum*. 2013;65(4):890-8.
- [4]. Naredo E, Valor L, De la Torre I, Montoro M, Bello N, Martinez-Barrio J, et al. Predictive value of Doppler ultrasound-detected synovitis in relation to failed tapering of biologic therapy in patients with rheumatoid arthritis. *Rheumatology (Oxford)*. 2015;54(8):1408-14.
- [5]. Sahbudin I, Pickup L, Nightingale P, Allen G, Cader Z, Singh R, et al. The role of ultrasound-defined tenosynovitis and synovitis in the prediction of rheumatoid arthritis development. *Rheumatology (Oxford)*. 2018.
- [6]. Lillegraven S, Boyesen P, Hammer HB, Ostergaard M, Uhlig T, Sesseng S, et al. Tenosynovitis of the extensor carpi ulnaris tendon predicts erosive progression in early rheumatoid arthritis. *Ann Rheum Dis*. 2011;70(11):2049-50.
- [7]. Mandl P, Naredo E, Wakefield RJ, Conaghan PG, D'Agostino MA, Force OUT. A systematic literature review analysis of ultrasound joint count and scoring systems to assess synovitis in rheumatoid arthritis according to the OMERACT filter. *J Rheumatol*. 2011;38(9):2055-62.
- [8]. Brown AK, Conaghan PG, Karim Z, Quinn MA, Ikeda K, Peterfy CG, et al. An explanation for the apparent dissociation between clinical remission and continued structural deterioration in rheumatoid arthritis. *Arthritis Rheum*. 2008;58(10):2958-67.
- [9]. D'Agostino MA, Terslev L, Wakefield R, Ostergaard M, Balint P, Naredo E, et al. Novel algorithms for the pragmatic use of ultrasound in the management of patients with rheumatoid arthritis: from diagnosis to remission. *Ann Rheum Dis*. 2016;75(11):1902-8.
- [10]. Torp-Pedersen S, Christensen R, Szkudlarek M, Ellegaard K, D'Agostino MA, Iagnocco A, et al. Power and color Doppler ultrasound settings for inflammatory flow: impact on scoring of disease activity in patients with rheumatoid arthritis. *Arthritis Rheumatol*. 2015;67(2):386-95.
- [11]. Wakefield RJ, Balint PV, Szkudlarek M, Filippucci E, Backhaus M, D'Agostino MA, et al. Musculoskeletal ultrasound including definitions for ultrasonographic pathology. *J Rheumatol*. 2005;32(12):2485-7.

- [12]. Naredo E, D'Agostino MA, Wakefield RJ, Moller I, Balint PV, Filippucci E, et al. Reliability of a consensus-based ultrasound score for tenosynovitis in rheumatoid arthritis. *Ann Rheum Dis*. 2013;72(8):1328-34.
- [13]. D'Agostino MA, Terslev L, Aegerter P, Backhaus M, Balint P, Bruyn GA, et al. Scoring ultrasound synovitis in rheumatoid arthritis: a EULAR-OMERACT ultrasound taskforce-Part 1: definition and development of a standardised, consensus-based scoring system. *RMD Open*. 2017;3(1):e000428.
- [14]. Terslev L, Naredo E, Aegerter P, Wakefield RJ, Backhaus M, Balint P, et al. Scoring ultrasound synovitis in rheumatoid arthritis: a EULAR-OMERACT ultrasound taskforce-Part 2: reliability and application to multiple joints of a standardised consensus-based scoring system. *RMD Open*. 2017;3(1):e000427.
- [15]. Padovano I, Costantino F, Breban M, D'Agostino MA. Prevalence of ultrasound synovial inflammatory findings in healthy subjects. *Ann Rheum Dis*. 2016;75(10):1819-23.
- [16]. Witt M, Frielinghausen J, Leipe J, Schulze-Koops K, Mueller R, Grunke M. Detection of Synovitis and Erosions with an Automated Ultrasound System: Data from a Prospective Cohort with Early and Established RA. *Arthritis & Rheumatology*. 2014;66:S56-S56.
- [17]. Bruyn GA, Moller I, Garrido J, Bong D, d'Agostino MA, Iagnocco A, et al. Reliability testing of tendon disease using two different scanning methods in patients with rheumatoid arthritis. *Rheumatology (Oxford)*. 2012;51(9):1655-61.
- [18]. Zayat AS, Ellegaard K, Conaghan PG, Terslev L, Hensor EM, Freeston JE, et al. The specificity of ultrasound-detected bone erosions for rheumatoid arthritis. *Ann Rheum Dis*. 2015;74(5):897-903.
- [19]. Nam JL, Hensor EM, Hunt L, Conaghan PG, Wakefield RJ, Emery P. Ultrasound findings predict progression to inflammatory arthritis in anti-CCP antibody-positive patients without clinical synovitis. *Ann Rheum Dis*. 2016;75(12):2060-7.
- [20]. Rakieh C, Nam JL, Hunt L, Hensor EM, Das S, Bissell LA, et al. Predicting the development of clinical arthritis in anti-CCP positive individuals with non-specific musculoskeletal symptoms: a prospective observational cohort study. *Ann Rheum Dis*. 2015;74(9):1659-66.
- [21]. Zufferey P, Rebell C, Benaim C, Ziswiler HR, Dumusc A, So A. Ultrasound can be useful to predict an evolution towards rheumatoid arthritis in patients with inflammatory polyarthralgia without anticitrullinated antibodies. *Joint Bone Spine*. 2017;84(3):299-303.
- [22]. Freeston JE, Wakefield RJ, Conaghan PG, Hensor EM, Stewart SP, Emery P. A diagnostic algorithm for persistence of very early inflammatory arthritis: the utility of power Doppler ultrasound when added to conventional assessment tools. *Ann Rheum Dis*. 2010;69(2):417-9.



- [23]. Filer A, de Pablo P, Allen G, Nightingale P, Jordan A, Jobanputra P, et al. Utility of ultrasound joint counts in the prediction of rheumatoid arthritis in patients with very early synovitis. *Ann Rheum Dis.* 2011;70(3):500-7.
- [24]. Horton SC, Tan AL, Wakefield RJ, Freeston JE, Buch MH, Emery P. Ultrasound-detectable grey scale synovitis predicts future fulfilment of the 2010 ACR/EULAR RA classification criteria in patients with new-onset undifferentiated arthritis. *RMD Open.* 2017;3(1):e000394.
- [25]. Wakefield RJ, Green MJ, Marzo-Ortega H, Conaghan PG, Gibbon WW, McGonagle D, et al. Should oligoarthritis be reclassified? Ultrasound reveals a high prevalence of subclinical disease. *Ann Rheum Dis.* 2004;63(4):382-5.
- [26]. Aletaha D, Neogi T, Silman AJ, Funovits J, Felson DT, Bingham CO, 3rd, et al. 2010 rheumatoid arthritis classification criteria: an American College of Rheumatology/European League Against Rheumatism collaborative initiative. *Annals of the rheumatic diseases.* 2010;69(9):1580-8.
- [27]. Gutierrez M, Filippucci E, Salaffi F, Di Geso L, Grassi W. Differential diagnosis between rheumatoid arthritis and psoriatic arthritis: the value of ultrasound findings at metacarpophalangeal joints level. *Ann Rheum Dis.* 2011;70(6):1111-4.
- [28]. Zabotti A, Salvin S, Quartuccio L, De Vita S. Differentiation between early rheumatoid and early psoriatic arthritis by the ultrasonographic study of the synovio-entheseal complex of the small joints of the hands. *Clin Exp Rheumatol.* 2016;34(3):459-65.
- [29]. Ruta S, Rosa J, Navarta DA, Saucedo C, Catoggio LJ, Monaco RG, et al. Ultrasound assessment of new onset bilateral painful shoulder in patients with polymyalgia rheumatica and rheumatoid arthritis. *Clin Rheumatol.* 2012;31(9):1383-7.
- [30]. Naredo E, Moller I, Cruz A, Carmona L, Garrido J. Power Doppler ultrasonographic monitoring of response to anti-tumor necrosis factor therapy in patients with rheumatoid arthritis. *Arthritis Rheum.* 2008;58(8):2248-56.
- [31]. D'Agostino MA, Wakefield RJ, Berner-Hammer H, Vittecoq O, Filippou G, Balint P, et al. Value of ultrasonography as a marker of early response to abatacept in patients with rheumatoid arthritis and an inadequate response to methotrexate: results from the APPRAISE study. *Ann Rheum Dis.* 2016;75(10):1763-9.
- [32]. Dale J, Stirling A, Zhang R, Purves D, Foley J, Sambrook M, et al. Targeting ultrasound remission in early rheumatoid arthritis: the results of the TaSER study, a randomised clinical trial. *Ann Rheum Dis.* 2016;75(6):1043-50.
- [33]. Haavardsholm EA, Aga AB, Olsen IC, Lillegraven S, Hammer HB, Uhlig T, et al. Ultrasound in management of rheumatoid arthritis: ARCTIC randomised controlled strategy trial. *BMJ.* 2016;354:i4205.

- [34]. Nordberg LB, Lillegraven S, Aga AB, Sexton J, Lie E, Hammer HB et al. The Impact of Ultrasound on the Use and Efficacy of Intraarticular Glucocorticoid Injections in Early Rheumatoid Arthritis: Secondary Analyses From a Randomized Trial Examining the Benefit of Ultrasound in a Clinical Tight Control Regimen. *Arthritis Rheumatol*. 2018 Aug;70(8):1192-1199.
- [35]. Daien C, Hua C, Gaujoux-Viala C, Cantagrel A, Dubremetz M, Dougados M, et al. Update of French society for rheumatology recommendations for managing rheumatoid arthritis. *Joint Bone Spine*. 2019;86(2):135-50.
- [36]. Smolen JS, Landewe R, Bijlsma J, Burmester G, Chatzidionysiou K, Dougados M, et al. EULAR recommendations for the management of rheumatoid arthritis with synthetic and biological disease-modifying antirheumatic drugs: 2016 update. *Ann Rheum Dis*. 2017;76(6):960-77.
- [37]. Dougados M, Devauchelle-Pensec V, Ferlet JF, Jousse-Joulin S, D'Agostino MA, Backhaus M, et al. The ability of synovitis to predict structural damage in rheumatoid arthritis: a comparative study between clinical examination and ultrasound. *Ann Rheum Dis*. 2013;72(5):665-71.
- [38]. Pascual-Ramos V, Contreras-Yanez I, Cabiedes-Contreras J, Rull-Gabayet M, Villa AR, Vazquez-Lamadrid J, et al. Hypervascular synovitis and American College of Rheumatology Classification Criteria as predictors of radiographic damage in early rheumatoid arthritis. *Ultrasound Q*. 2009;25(1):31-8.
- [39]. Iwamoto T, Ikeda K, Hosokawa J, Yamagata M, Tanaka S, Norimoto A, et al. Prediction of relapse after discontinuation of biologic agents by ultrasonographic assessment in patients with rheumatoid arthritis in clinical remission: high predictive values of total gray-scale and power Doppler scores that represent residual synovial inflammation before discontinuation. *Arthritis Care Res (Hoboken)*. 2014;66(10):1576-81.
- [40]. Nguyen H, Ruysse-Witrand A, Gandjbakhch F, Constantin A, Foltz V, Cantagrel A. Prevalence of ultrasound-detected residual synovitis and risk of relapse and structural progression in rheumatoid arthritis patients in clinical remission: a systematic review and meta-analysis. *Rheumatology (Oxford)*. 2014;53(11):2110-8.
- [41]. Peluso G, Michelutti A, Bosello S, Gremese E, Toluoso B, Ferraccioli G. Clinical and ultrasonographic remission determines different chances of relapse in early and long standing rheumatoid arthritis. *Ann Rheum Dis*. 2011;70(1):172-5.
- [42]. Filippou G, Sakellariou G, Scire CA, Carrara G, Rumi F, Bellis E, et al. The predictive role of ultrasound-detected tenosynovitis and joint synovitis for flare in patients with rheumatoid arthritis in stable remission. Results of an Italian multicentre study of the Italian Society for Rheumatology Group for Ultrasound: the STARTER study. *Ann Rheum Dis*. 2018.

- [43]. Cunnington J, Marshall N, Hide G, Bracewell C, Isaacs J, Platt P, et al. A randomized, double-blind, controlled study of ultrasound-guided corticosteroid injection into the joint of patients with inflammatory arthritis. *Arthritis Rheum.* 2010;62(7):1862-9.
- [44]. Sibbitt WL, Jr., Band PA, Chavez-Chiang NR, Delea SL, Norton HE, Bankhurst AD. A randomized controlled trial of the cost-effectiveness of ultrasound-guided intraarticular injection of inflammatory arthritis. *J Rheumatol.* 2011;38(2):252-63.
- [45]. Gutierrez M, Di Matteo A, Roseff M, Cazenave T, Rodriguez-Gil G, Diaz CH, Rios LV, Zamora N, Guzman Mdel C, Carrillo I, Okano T, Salaffi F, Pineda C; Pan-American League against Rheumatism (PANLAR) Ultrasound Study Group. Short-term efficacy to conventional blind injection versus ultrasound-guided injection of local corticosteroids in tenosynovitis in patients with inflammatory chronic arthritis: A randomized comparative study. *Joint Bone Spine.* 2016 Mar;83(2):161-6.
- [46]. Ammitzboll-Danielsen M, Ostergaard M, Fana V, Glinatsi D, Dohn UM, Ornbjerg LM, et al. Intramuscular versus ultrasound-guided intratenosynovial glucocorticoid injection for tenosynovitis in patients with rheumatoid arthritis: a randomised, double-blind, controlled study. *Ann Rheum Dis.* 2017;76(4):666-72.

**Tables and figures:**

**Figure 1:** General organization of process

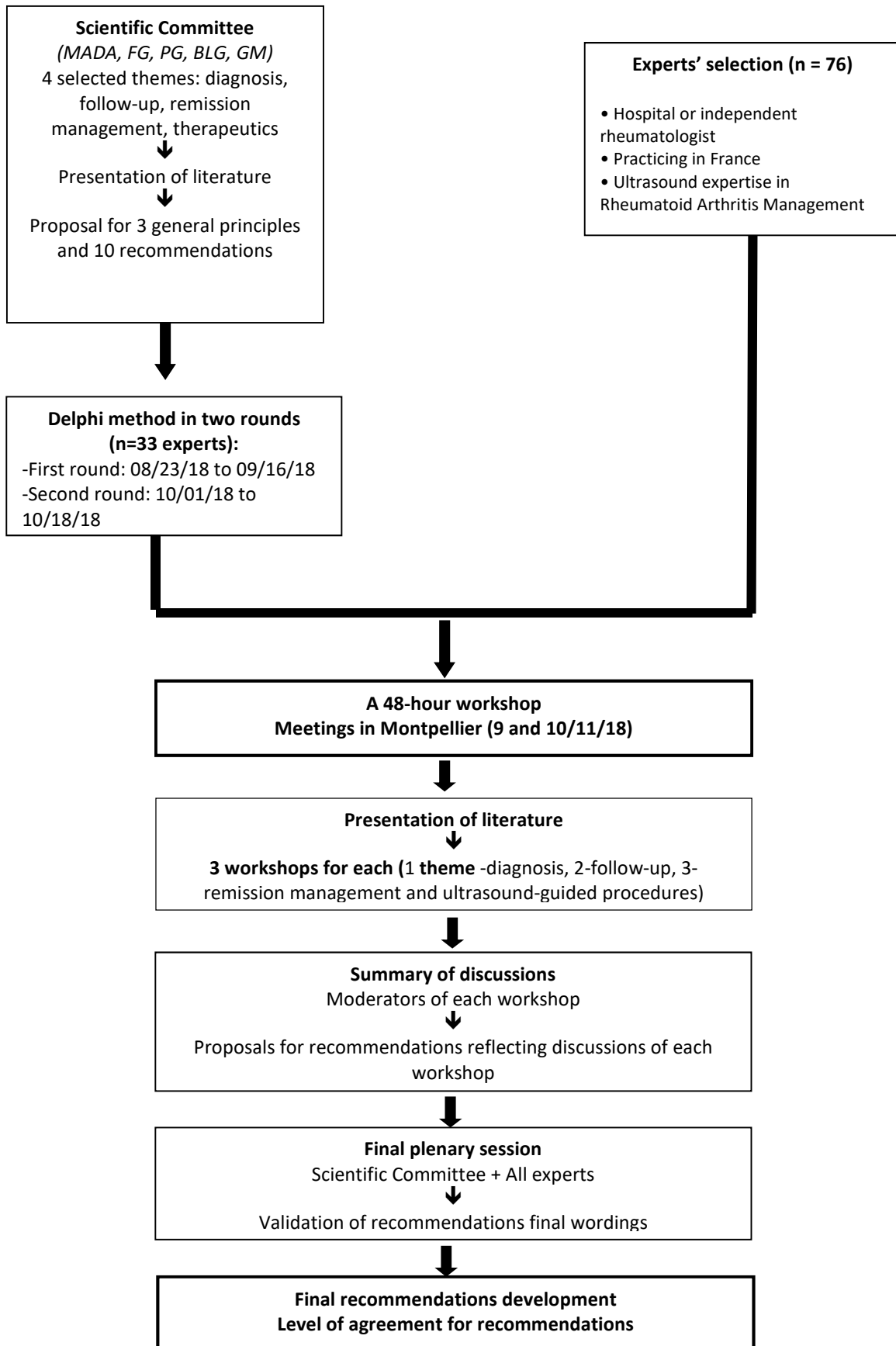
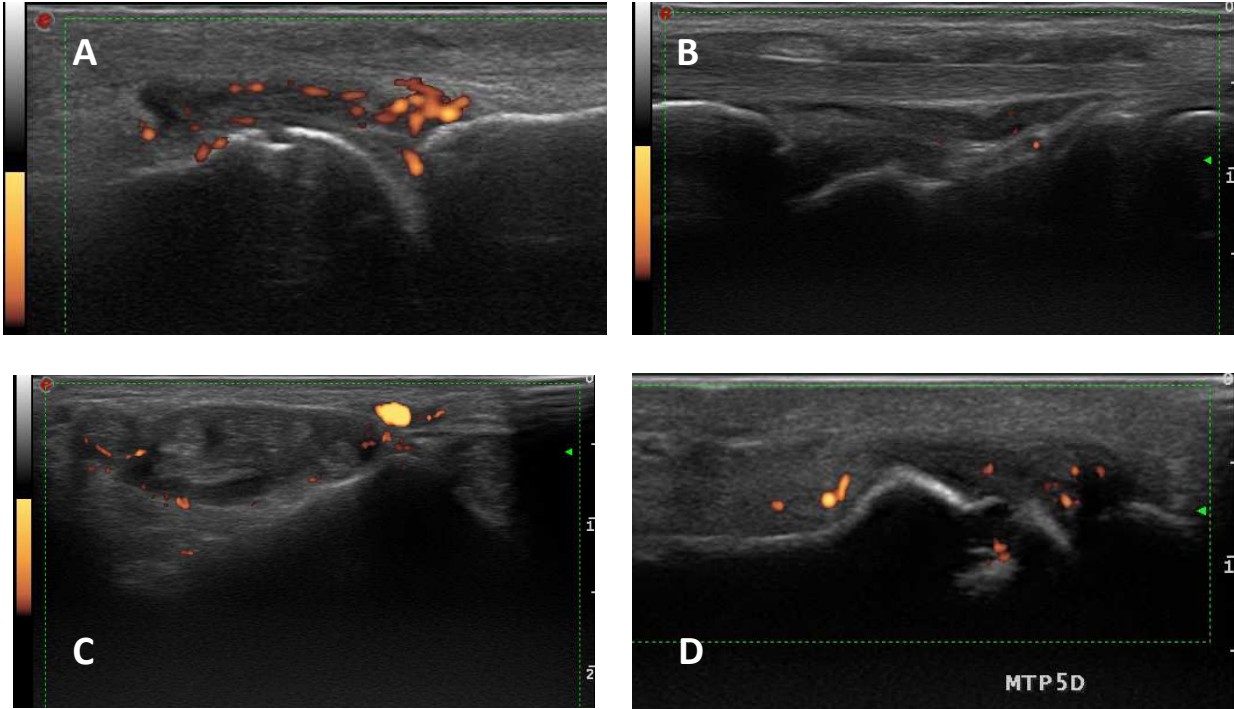


Figure 2: Example of ultrasound image of a synovitis in power Doppler mode in longitudinal scan (A) (Metatarsophalangeal 4 joint), a tenosynovitis in power Doppler mode in longitudinal and transversal scan (B and C) (extensor digitorum communis) and an erosion in power Doppler mode in longitudinal scan (D) (Metatarsophalangeal 5 joint).



**Table 1:** Level of agreement about the wording of the different recommendations from 33 experts who took part in the vote according to Delphi method on Likert scale (1-5).

<b>Recommendation</b>	<b>First round</b>	<b>Second round</b>
General principle 1	Vote 4 and 5/5: 97%	
General principle 2	Vote 4 and 5/5: 93.9%	
General Principle 3		
- Synovitis Topography	Vote 4 and 5/5: 69.7%	Vote 4 and 5/5: 77.8%
- Tenosynovitis Topography	Vote 4 and 5/5: 69.7%	Vote 4 and 5/5: 78.6%
- Erosion Topography	Vote 4 and 5/5: 90.9%	
Recommendation 1	Vote 4 and 5/5: 90.9%	
Recommendation 2	Vote 4 and 5/5: 93.9%	
Recommendation 3	Vote 4 and 5/5: 93.9%	
Recommendation 4	Vote 4 and 5/5: 49.5%	Vote 4 and 5/5: 92.9%
Recommendation 5	Vote 4 and 5/5: 87.9%	
Recommendation 6	Vote 4 and 5/5: 78.8%	
Recommendation 7	Vote 4 and 5/5: 78.8%	
Recommendation 8	Vote 4 and 5/5: 81.8%	
Recommendation 9	Vote 4 and 5/5: 97%	
Recommendation 10	Vote 4 and 5/5: 66.7%	Vote 4 and 5/5: 82.1%

**Table 2:** List of recommendations for the pragmatic use of ultrasound in rheumatoid arthritis

	<b>Experts' Level of agreement#</b> (N=76)	<b>Ease of implementing the recommendation#</b> (N=75)
<b>General principles:</b>		
<b>1/</b> Ultrasound examination in the management of chronic inflammatory arthritis such as RA requires: - Assessment using an appropriate equipment with a high frequency linear transducer and Doppler ultrasound suited to low-velocity flows; - Bilateral assessment in B mode and Doppler mode; - Semi-quantitative assessment of inflammatory lesions (synovitis and tenosynovitis) and screening for erosions according to Outcome Measures in Rheumatology (OMERACT) definitions and scores.	100%	85.3%
<b>2/</b> Ultrasound findings indicating synovial or tenosynovial inflammation are hypoechoic synovial or tenosynovial hyperplasia including the presence of Doppler signal within the hypoechoic synovial or tenosynovial hyperplasia.	100%	88%
<b>3/ Definition of which joint, tendon and bone sites to examine</b>		
<b>a)</b> The most useful sites for screening for RA-related synovitis are on the dorsal aspect of the following joints: wrists, metacarpophalangeal joints (MCPs) 1 to 5, proximal interphalangeal joints 1 to 5, metatarsophalangeal joints (MTPs) 2 to 5, and symptomatic joints	90.8%	73.3%
<b>b)</b> The most useful sites for screening for RA-related tenosynovitis are: finger flexor digitorum superficialis and profundus tendons 2 to 5, the extensor carpi ulnaris and the extensor digitorum communis at the wrist. Checking for tenosynovial involvement of the ankle (tibialis posterior and peroneal tendons) may also be	97.4%	74.7%

worthwhile, depending on the patient's symptoms.		
<b>c)</b> The most useful sites for screening for RA-related erosion are: all aspects of MCPs 2 and 5, MTP 5 and the styloid process of the ulna, which should be explored in all sides.	100%	82.7%
<b>Diagnosis:</b>		
<b>Reco 1:</b> In patients with inflammatory arthralgia without clinical detected synovitis or tenosynovitis, ultrasound of the hands, wrists, feet, and symptomatic joints is recommended to screen for synovitis or tenosynovitis.	97.4%	76%
<b>Reco 2:</b> In patients with early arthritis, it is worthwhile investigating the hands, wrists, feet and symptomatic joints on ultrasound to evaluate synovitis and tenosynovitis, to screen for erosion if erosion is not found on X-ray, or to inform possible differential diagnosis.	93.4%	70.7%
<b>Reco 3:</b> In patients with early RA meeting 2010 ACR/EULAR criteria, ultrasound can be used to confirm the extent of inflammatory and structural involvement (i.e. erosions, hypervascularity with Doppler mode), or inform the differential diagnosis.	93.4%	80%
<b>Follow-up:</b>		
<b>Reco 4:</b> ultrasound is required when any disease-modifying anti-rheumatic drug (DMARD) is initiated or modified to evaluate inflammatory activity and establish a benchmark examination for any subsequent follow-up.	89.5%	48%
<b>Reco 5:</b> Systematic ultrasound follow-up of treated RA patients is not recommended except when patients and physicians disagree on activity, or when modification of treatment or a local procedure are being considered.  If an ultrasound follow-up is considered, it should be performed at least 3 months after initiation or modification of treatment.	100%	76%
<b>Reco 6:</b> If ultrasound inflammation is accompanied by positive Doppler signal, a treatment modification should be considered.	98.7%	72%
<b>Reco 7:</b> The periodic evaluation of pre-existing ultrasound erosions cannot be recommended because of lack of consensus in the	98.7%	93.3%



literature.		
<b>Remission:</b>		
<b>Reco 8:</b> In patients in clinical remission, if a treatment reduction is being considered, it would be helpful to perform an ultrasound examination to confirm that no subclinical synovitis or tenosynovitis is present.	100%	61.3%
<b>Reco 9:</b> In patients in clinical remission, an absence of inflammatory activity on ultrasound confirm the possibility of treatment reduction. If Doppler-positive synovitis is detected, treatment reduction should be reconsidered based on the clinical context.	94.7%	69.3%
<b>ULTRASOUND-guided procedures:</b>		
<b>Reco 10:</b> ultrasound guidance is recommended when performing joint aspiration or injections, particularly in some particular circumstances like moderate synovitis or effusion, hard-to-reach joints, and tendon sheaths.	97.4%	78.7%

N= Number of voters.

# Percentage of participants with level of agreement  $\geq 4/5$

**Table 3:** Joints, tendons and bone sites to examine for screening for RA-related synovitis, tenosynovitis and erosions

<b>Sites</b>	<b>Scanning technique</b>	<b>Recommended</b>	<b>Optional</b>	<b>Level of agreement#</b>
<b>Joints</b>	Longitudinal dorsal scan of the joints	-wrists, -metacarpophalangeal joints (MCPs) 1 to 5, -proximal interphalangeal joints 1 to 5, -metatarsophalangeal joints (MTPs) 2 to 5,	-other symptomatic joints	<i>90.8%</i>
<b>Tendons</b>	Longitudinal and transverse scan of the tendons	-finger flexor digitorum superficialis and profundus tendons 2 to 5, -the extensor carpi ulnaris and the extensor digitorum communis at the wrist.	-tibialis posterior -peroneal tendons	<i>97.4%</i>
<b>Intra-articular Bone</b>	all available facets	-MCPs 2 and 5, -MTP 5 -styloid process of the ulna		<i>100%</i>

# Percentage of participants with level of agreement  $\geq 4/5$