



HAL
open science

Laparoscopic anatomical liver resection for malignancies using positive or negative staining technique with intraoperative indocyanine green-fluorescence imaging

Emanuele Felli, Takeaki Ishizawa, Zineb Cherkaoui, Michele Diana, Simona Tripon, Thomas F. Baumert, Catherine Schuster, Patrick Pessaux

► To cite this version:

Emanuele Felli, Takeaki Ishizawa, Zineb Cherkaoui, Michele Diana, Simona Tripon, et al.. Laparoscopic anatomical liver resection for malignancies using positive or negative staining technique with intraoperative indocyanine green-fluorescence imaging. *HPB*, 2021, 23 (11), 10.1016/j.hpb.2021.05.006 . hal-03698414

HAL Id: hal-03698414

<https://hal.science/hal-03698414>

Submitted on 5 Jan 2024

HAL is a multi-disciplinary open access archive for the deposit and dissemination of scientific research documents, whether they are published or not. The documents may come from teaching and research institutions in France or abroad, or from public or private research centers.

L'archive ouverte pluridisciplinaire **HAL**, est destinée au dépôt et à la diffusion de documents scientifiques de niveau recherche, publiés ou non, émanant des établissements d'enseignement et de recherche français ou étrangers, des laboratoires publics ou privés.



Distributed under a Creative Commons Attribution - NonCommercial 4.0 International License

Laparoscopic anatomical liver resection for malignancies using positive or negative staining technique with intraoperative indocyanine green-fluorescence imaging

Emanuele Felli^{1, 2, 3, 6}, Takeaki Ishizawa⁴, Zineb Cherkaoui^{1, 2}, Michele Diana^{1, 3}, Simona Tripon^{5, 6}, Thomas Baumert^{5, 6}, Catherine Schuster⁶, Patrick Pessaux^{1, 2, 3, 6}

Running title: a promising technique for minimally invasive anatomical liver resection

1. Digestive and Endocrine Surgery, Nouvel Hôpital Civil, University of Strasbourg, Strasbourg, France
2. IHU Strasbourg, Institute for Image-Guided Surgery, Strasbourg, France
3. IRCAD, Research Institute against Digestive Cancer, Strasbourg, France
4. Department of Gastroenterological Surgery, Cancer Institute Hospital, Japanese Foundation for Cancer Research, Ariake, Japan; Hepato-Biliary-Pancreatic Surgery Division, Department of Surgery, Graduate School of Medicine, The University of Tokyo, Tokyo, Japan
5. Hepatology and Gastroenterology department, Nouvel Hôpital Civil, University of Strasbourg, Strasbourg, France
6. Institute of Viral and Liver Disease, INSERM U1110, Strasbourg, France

Corresponding author:

Professor Patrick Pessaux, MD, PhD
Head of the Hepatobiliary and Pancreatic Surgical Unit
Nouvel Hôpital Civil (NHC)
1, Place de l'Hôpital
67091 Strasbourg, France.
Phone: +33 3 69 55 15 63
Email: patrick.pessaux@chru-strasbourg.fr

The authors declare that they have no conflict of interest

Manuscript type: review

Key words: anatomical liver resection – hepatocellular carcinoma- minimally invasive surgery

Abstract

Background: Indications for a minimally invasive resections are increasing worldwide, but respecting anatomical planes during intraparenchymal transection is demanding.

Intraoperative ICG fluorescence staining of liver parenchyma has been introduced as a tool for real-time intraoperative guidance. The aim of this study is to make a systematic review of the current relevant literature on indications, techniques, and results of laparoscopic anatomical liver resection (LALR) using intraoperative indocyanine green (ICG) fluorescence for positive and negative staining of liver segments in patients affected by liver malignancies.

Methods: Electronic bibliographical databases (MEDLINE and PubMed) were searched according to the PRISMA criteria. English language articles meeting the selection criteria and published until June 2020 were retrieved and reviewed.

Results: a total of 86 articles were initially found and 11 articles were finally included in the analysis with a total of 83 patients treated. Sixty-two patients (74.6%) underwent mono-segmentectomies. Thirty-five patients (42.1%) underwent the positive staining technique, and forty-eight patients (57.8%) the negative staining technique.

Conclusions: The positive or negative indocyanine green staining technique with real-time fluorescence guidance is an emerging and promising approach. However, the technique has to be standardized and advantages in terms of oncologic results still need validation in further studies.

Introduction

Hepatocellular carcinoma (HCC), cholangiocarcinoma, and colorectal liver metastases are the most common liver malignancies for which liver resection is indicated. Anatomical liver resection (ALR) is the current standard for HCC resection as it allows a better postoperative survival and disease-free survival¹⁻⁴. Concerning colorectal liver metastases, there is still no strong evidence to support ALR. However, some authors have recently reported a high rate of positive margins in RAS-mutated lesions and worse cancer-specific survival secondary to remnant liver ischemia^{5, 6}, suggesting that anatomical resection could improve results. For intrahepatic cholangiocarcinoma, a better oncological outcome as compared to non-anatomical resection has been reported in patients with stage IB or II tumors without vascular invasion⁷. The concept of anatomical resection has subsequently become an oncological necessity, which also has to be related to the progressive diffusion of minimally invasive liver resections. The different classifications of liver anatomy currently accepted provide an important, yet idealized, representation of anatomical planes and structures⁸. Defining the exact planes for resection is often difficult, especially in cirrhotic patients and for posterosuperior segment tumors. In fact, finding the correct intraparenchymal anatomical line is technically challenging and anatomical landmarks, such as hepatic veins and portal branches are then used under ultrasound guidance to guide transection⁹⁻¹². Makuuchi¹⁰ associated the ultrasound guidance to methylene blue injection in portal branches to delineate the precise limits of a determined segment or sector on the liver surface, the technique performed during open surgery. It necessitates as well the hepatic artery clamping, and the dye washout is relatively rapid. Replacing the blue dye with indocyanine green (ICG), and associating the use of near-infrared cameras, fluorescence-based segmentation to guide liver resections have been then introduced¹³. In 2008, Aoki et al. first reported an intraoperative technique for subsegments and segments staining during open hepatectomy, with a success rate of 93% in

identifying anatomical planes. The technique was considered safe, reproducible, and not time-consuming¹⁴. In parallel to this, the role of laparoscopic liver resection (LLR) has been established for liver malignancies, especially HCC, confirmed by consensus meetings and international recommendations^{15, 16}. However, laparoscopic anatomical liver resection (LALR) techniques have not been fully standardized because both selective inflow portal clamping and portal staining, when used, are difficult to perform in the minimally invasive setting, especially in cirrhotic livers and for posterosuperior segments. To improve the quality and precision of anatomical resection, and to guide intraparenchymal transection, combined ICG fluorescence imaging in LALR has been used with direct portal ICG injection under percutaneous-guided laparoscopic ultrasound, the so-called “positive staining” technique¹⁷⁻¹⁹ (Figures 1a, 2). Ishizawa was the first to perform this technique in 2012. Similarly, but with the opposite principle, is the “negative staining” technique (Figures 1b, 3a, 3b), achieved by the intravenous ICG dye injection after clamping the segmental portal pedicle, following the Glissonian concept of anatomical liver resection¹⁹⁻²³. We aimed to perform a systematic review of the current relevant literature concerning the different techniques and results of minimally invasive liver malignancies resections guided by means of ICG real-time fluorescence, using positive or negative staining.

Materials and methods

Study design

This review included different phases for the methodological algorithm, namely definition of search strategies, selection criteria, assessment of study quality, and analysis of relevant data. The preferred reporting items for systematic reviews and meta-analysis (PRISMA) statements checklist to report a systematic review were used (Fig. 4). Studies were then included in the IDEAL framework to contextualize this emerging technique in the field of surgical innovation.

Study inclusion criteria

At first, selection criteria to identify studies eligible for this review were stated. Prospective and retrospective studies, patient series, and patient reports were included and used for quantitative and qualitative synthesis of data.

Literature search strategy

Electronic bibliographical databases (i.e., MEDLINE, PubMed, EMBASE, and Scopus) were searched. The following terms were used for the search: laparoscopic hepatectomy, and indocyanine green fluorescence. English language articles meeting the selection criteria and published until June 2020 were retrieved and reviewed.

Study selection and quality assessment

The abstracts of the selected studies were blindly and independently screened for relevance by two reviewers (EF and ZC). In order to achieve the highest sensitivity and specificity, records were selected for further analysis only if none of the reviewers rejected it. The selected studies were analyzed and data extraction was performed independently by both reviewers. Any disagreement, if present, between the two reviewers in the selection and analysis was resolved via discussion between two other reviewers (CS and PP).

Data extraction and analysis

Qualitative and quantitative analysis were performed with data from the included studies.

Results

A total of 86 articles were initially found, 75 excluded because of preoperative ICG injection for liver tumors detection or simple ICG injection applications description. Experimental studies were also excluded. Ten articles were finally included in the analysis^{17-20, 22-27}. Three articles were case reports, the others reported single center series with a total of 83 patients treated with this technique (Table 1). Among these ten articles, seven were published in the last two years; sixty-six patients (79.5%) were reported in 2018-2020 articles. Sixty-two (74.6%) underwent mono-segmentectomies, 5 patients (6%) right anterior sectionectomies, 4 patients (4.8%) right posterior sectionectomies, 4 patients (4.8%) left hepatectomies, 3 patients (3.5%) trisegmentectomy IV-V-VIII, 2 patients (2.4%) right hepatectomies, 2 patient (2.4%) left lateral sectionectomy, 1 patient (1.2%) bisegmentectomy V-VI. Thirty-five patients (42.1%) underwent the positive staining technique, and forty-eight patients (57.8%) the negative staining technique. In the positive staining group, Aoki²⁷ reported 14 patients treated with an intraoperative, yet transcutaneous ultrasound-guided, ICG injection. In two patients, this technique did not succeed because of a small segmental portal branch diameter (<2mm). The other authors reported intraoperative ICG injection under laparoscopic ultrasound guidance through a BK laparoscopic transducer model (BK Medical, 8666) probe characterized by the presence of a needle hole to guide injection. The injection technique was different in terms of needle size and ICG volume and concentration. When reported, needles had a variable size ranging from 18G to 22G. For positive staining, ICG concentration varied from 0.025mg/10mL to 0.025mg/mL. For negative staining, a direct intravenous ICG injection was performed after the use of a Glissonian approach and the clamping of portal pedicles, with a reported ICG dose comprised between 1.5mg to 2.5mg. Fluorescence was reported to appear after a minimum interval of 3 minutes from injection. No vanishing of ICG fluorescence due to ICG diffusion or increased background fluorescence was reported. Fusion

real-time imaging was used with a PINPOINT camera in 55 patients (85.9%). The principle of this type of cameras is that near-infrared light source excites the fluorophore and the fluorescence signal is detected from it. The PINPOINT system is the most frequently used as it allows the possibility of a real time fusion of images; the system is composed by a 0°, 30° or 45° laparoscope, a complementary metal-oxide semiconductor camera head, and a near-infrared laser diode for ICG excitation at a wavelength of 805 nm. Different types of images are possible to obtain, color images under white-light illumination, a monochromatic fluorescence images under near-infrared light illumination, and finally the fusion images with a green pseudocolor that shows the fluorescent parts of the liver. The vision mode can be changed during the operation, as the different types are simultaneously displayed in sub-screens. Concerning the injection time, Aoki reported an average of 15 minutes (9-20 min). ICG injection in the positive staining technique is recommended to be slow to prevent any excessive pressure which could result in a retrograde flow into a portal branch supplying a neighboring segment, with consequent undesired staining. The average operation time in the same series (without initial injection time) was 243 min, and blood loss had an average of 185mL. Considering the resected liver volume, there was no statistically significant difference ($p=0.539$) between the preoperatively estimated average (149mL +/- 42mL), and the average specimen weight (158g +/- 44g). No intraoperative complications were reported, no conversion to laparotomy and no positive margins on the specimen neither. Indication to resection was hepatocellular carcinoma in 33 patients (51.6%), colorectal liver metastases in 12 patients (18.8%), breast cancer liver metastasis in one patient (1.5%), and no information was available in 18 patients (28.1%). Ueno²⁸ reported an hybrid approach with interventional radiology assistance using a preoperative intra-arterial infusion of ICG for positive staining in an hybrid operating room. In the preoperative work-up, 3D portal vein branches reconstruction were always performed to identify anatomical variations, first to easily

recognize small segmental portal branches, and then to determine the precise injection point and the estimated volume to be resected. In the most recent monocentric retrospective series reported by Xu³⁴, a total of 19 patients underwent positive (n=5) and negative (n=14) staining respectively. The median operative time was 260 with (150-360 min), median intraoperative blood loss was 300cc (50-800ml). No conversion to laparotomy was reported. There were also information on failure rate in both positive (n=4) (wrong portal segment injection, venous branch injection) and negative (n=13) (arterial collaterals staining the excluded segment-sector, wrong glissonean pedicle clamping, multiple single segments branches not entirely clamped) staining. According to IDEAL framework³⁵ this innovative technique is corresponding at present to Stage 1a (stage 0 to 4), where the development of the technique is still limited to single centre/single intervention and case series, or prospective cohort. The purpose at this stage is the development of the procedure to a stable version, the number of treated patients still limited and performed by few innovators and early adopters surgeons. No clear standardization of indications, technique and results exist, with necessity of further research to design appropriated prospective studies.

Discussion

ICG was approved by the U.S. Food and Drug Administration in 1954 and was widely used in many different clinical settings. The first clinical applications were to evaluate liver function and cardiac output. In the 1970s, a protein-bound ICG was found to emit fluorescence with a peak at about 840nm under near-infrared light illumination with (750-810nm)²⁸.

Intraoperative ICG use has been also described in visceral surgery (colorectal, upperGI, etc), with an increasing use especially for detection and estimation of stumps vascular perfusion and lymphnodes visualization. Indocyanine green applications in liver surgery have progressively gained attention over recent years and with different applications such as intraoperative guidance for anatomical liver resections, to localize subcapsular and

intraparenchymal tumors, or to recognize biliary anatomy²⁹⁻³¹. For anatomical resection, three main techniques are used: positive staining (intraoperative direct intraportal injection in the segment/section to be resected), negative staining (intraoperative intravenous injection of ICG to visualize the remnant perfused liver), and a hybrid combined percutaneous approach (with intra-arterial segmental injection of ICG)²⁵. Concerning intraoperative image visualization, both classic ICG camera and real-time fusion images vision are reported. Advantages of fluorescence imaging over the blue dye technique include the long-lasting identification of the anatomical part to resect, a clearer visualization of hepatic segments on hepatic surfaces (especially in patients with cirrhosis and/or previous liver resections), and the possibility to identify segmental boundaries not only from the liver surface but also from the raw surfaces during parenchymal dissection^{32, 33}. In contrast, a major disadvantage is the difficulty in the re-evaluation of segmental boundaries once ICG has been injected. The lack of tactile sensation, the physiological organ deformation according to patient position and liver exposure, the lack of a 3D vision, and the difficulty of precisely conduct an intraoperative laparoscopic ultrasound are some of the intrinsic difficulties of minimally invasive surgery, enhanced when performing a real anatomical liver resection. In addition, liver anatomy is complex and anatomical planes are difficult to visualize during intraparenchymal transection, especially in cirrhotic patients and for posterosuperior segments. It is well-established that for HCC, anatomical resection is associated with a better overall survival and a lower recurrence rate, and recent evidence suggests its role in the treatment of intrahepatic cholangiocarcinoma and potentially for colorectal liver metastases. It must be stressed that anatomical resection is an oncological necessity and a parameter of the quality of surgical resection. The worldwide progressive diffusion of minimally invasive liver surgery put this technical and oncological challenge as one of the priorities in HPB surgery. In 2008, Aoki reported direct ICG injection during laparotomy¹⁴ modifying the original Makuuchi technique, which consisted in blue dye

injection. In 2012, Ishizawa was the first to report positive and negative staining during a laparoscopic resection¹⁷. The positive and negative staining techniques require advanced laparoscopic skills and are technically demanding, though no additional operative time is reported by the different authors, with a mean of 18 minutes necessary for injection in the positive staining group. To overcome some of these difficulties, Aoki proposed a percutaneous preoperative direct ICG injection under trans-abdominal ultrasound guidance, immediately before resection. At present, only small single center series have been published, with a total of 83 patients treated, and no injection protocol standardization, nor strong specific reasons to choose between positive or negative staining. Considering positive staining, difficulties are related to the possibility of correctly inject and visualize the dye in the segmental portal branch, which can sometimes be multiple according to the patient's anatomy, and most of all difficult to perform for branches less than 2mm in diameter. Reflux to other portal segments and the lesion of biliary or arterial branches are some of the drawbacks of the technique. In fact, only a very small amount of ICG that could totally be taken up by hepatocytes in targeting hepatic segments should be administered, preventing the outflow of ICG from hepatic veins followed by reperfusion into the liver. Considering negative staining, the Glissonian approach can be hemorrhagic and a cause of biliary lesions, as well as technically demanding for posterior segments. Ueno²⁵ proposed a hybrid approach with interventional radiology assistance and intra-arterial ICG injection, hence avoiding previously mentioned difficulties. This strategy is nonetheless not easier, more complex from a logistic point of view, and necessitates additional time and costs, along with the presence of a hybrid operating room and of an experienced and dedicated radiologist. The recent introduction of fusion image cameras allows fluorescence visualization and normal vision simultaneously, preventing the surgeon to continuously switch from one to the other, which is a major advance for this innovating technique. Five out of eleven articles have been published

in the last two years, comprising the vast majority of patients (79.5%). It has to be observed that all of these reports come from Asia, where anatomical liver resection for HCC is historically more frequently performed. Very recently the first multicenter robotic series was reported by Chiow³⁶, with a total of 52 patients with negative (n=40) and positive (n=12) technique. Robotic liver surgery is at present still performed in a minority of minimally liver resections, but there is a constant increase of its use, along with published surgical series. As for laparoscopic surgery, in robotic liver resections clear identification of anatomical margins may help during dissection. It has to be considered that some technical differences exist between laparoscopy and robotics: robotic ultrasound probe is different to the laparoscopic one, in particular there are no probes available with an integrated hole to direct the needle in case of positive staining. A second consideration is that robotic arms usually occupy a large part of the external operative field, with a more difficult approach when inserting the needle percutaneously. Finally, inversely to laparoscopy where the liver surgeon usually performs together ultrasound, percutaneous injection and resection, in a robotic setting the operative surgeon is far from the surgical field. So in case of the positive staining technique, another surgeon with the same technical expertise both in intraoperative ultrasound and percutaneous needle insertion is needed. The advantages in terms of oncological results and technical feasibility of the positive and negative staining technique will necessitate further studies, as well as the standardization of the technique. This promising and interesting technique is a Stage 1a of the IDEAL framework, with only a few of innovators surgeons and early adopters, along with a limited number of patients treated. Consequently, it is still far from standardization, both for indications and technique. The present challenge for the minimally liver surgeon approaching to the positive or negative staining is complex. First, it is necessary the perfect use of the intraoperative ultrasound, with a precise detection of single, often multiples, segmental portal branches, according to the all possible anatomical variations.

Secondly, skills for percutaneous ultrasound guided injection with very thin needles are needed, with possible position variations secondary to respiratory movements and cardiac activity. Finally, the need of a team work, both for ICG dilution and preparation, as well for synchronization of clamping and intravenous injection for the negative staining. Concerning indications and results, another consideration that could possibly be made is in relation to liver transplantation. Bridge or salvage liver transplantation in patients affected by HCC on cirrhotic livers is still a matter of debate in terms of indications and results, but frequently performed in Western countries due the shortage of organs. As precise anatomical laparoscopic liver resection is rarely performed due to previously mentioned difficulties nowadays, the positive or negative ICG staining technique could possibly be a “surgeon”-related variable in this setting as the quality of resection may influence the oncologic results of transplantation³⁷.

Conclusions

Minimally invasive precise anatomical liver resection is a major challenge both for technical difficulties and the oncological implications in case of suboptimal resection, especially for HCC. The positive or negative indocyanine green staining technique with real-time fluorescence guidance is an emerging and promising approach, the feasibility of which has been demonstrated by advanced laparoscopic and liver surgeons. However, the technique has to be standardized and advantages in terms of oncologic results still need validation in further studies.

Disclosures:

The authors declare that they have no conflict of interest

Emanuele Felli have have no conflicts of interest or financial ties to disclose

Takeaki Ishizawa have no conflicts of interest or financial ties to disclose

Zineb Cherkaoui have no conflicts of interest or financial ties to disclose

Michele Diana have no conflicts of interest or financial ties to disclose

Simona Tripon have no conflicts of interest or financial ties to disclose

Thomas Baumert have no conflicts of interest or financial ties to disclose

Catherine Schuster have no conflicts of interest or financial ties to disclose

Patrick Pessaux have have no conflicts of interest or financial ties to disclose

Table 1.

Author	Year	Patients (n=)	Indication	Type of resection	Staining type	Fusion images	NIR camera system ^o
Ishizawa ¹⁷	2012	2	CRLM/ n/a	Segmentectomy III	1 P,1 N	no	n/a
Sakoda ¹⁸	2014	2	HCC	Segmentectomy V- VI Segmentectomy V	P P	no	IRI, Olympus
Terasawa ¹⁹	2017	12	HCC, CRLM	1 Segmentectomy II/III 3 segmentectomy III 3 segmentectomy IV 3 segmentectomy V 1 segmentectomy V/VI 1 segmentectomy VI	N	yes	PINPOINT fusion
Mizuno ²²	2017	1	Breast cancer liver metastasis	Segmentectomy VI	N		N/A
Nomi ²³	2018	16	n/a	2 left hepatectomies 3 right anterior sectionectomies 3 right posterior sectionectomies 8 segmentectomies	N		PINPOINT fusion
Urade ²⁴	2019	3	2HCC 1CRLM	segmentectomy	N		VISERA ELITE Olympus
Ueno ²⁵	2019	10	7HCC 3CRLM	segmentectomy	P hy brid		PINPOINT
Berardi ²⁶	2019	1	HCC	segmentectomy	N		n/a
Aoki ²⁷	2019	14	9HCC 5CRLM	segmentectomy	P		PINPOINT
Ito ²⁰	2020	3	2HCC 1CRLM	1 segmentectomy VI	P		PINPOINT

				2 segmentectomy VII		
Xu³⁴	2020	19	HCC	8 segmentectomies 6 bisegmentectomies 3 trisegmentectomies 2 right hepatectomies 2 left hepatectomies	14 N 5 P	N/A

NIR: near-infrared

P: positive staining

N: negative staining

HCC: hepatocellular carcinoma

CRLM: colorectal liver metastases

Positive staining

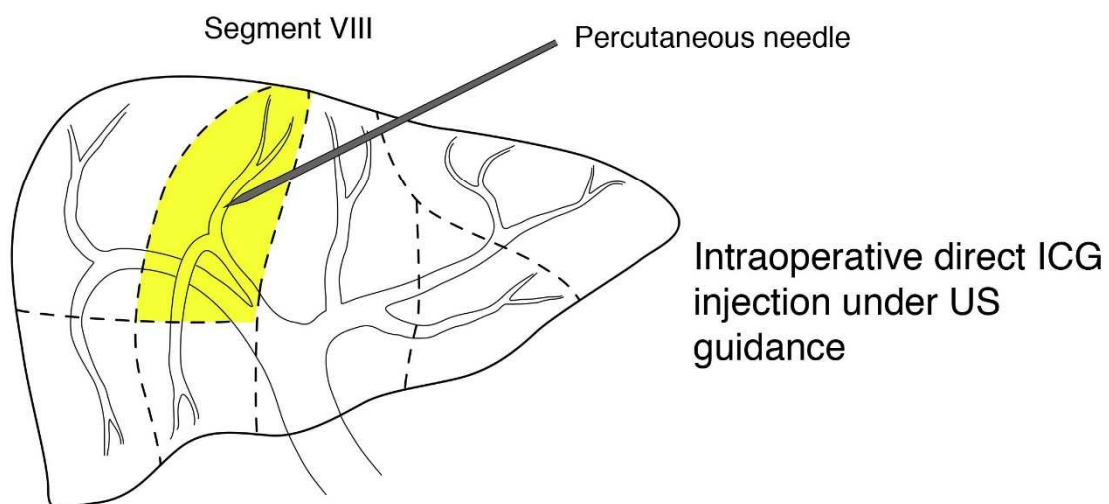


Figure 1a. Schematic representation of IGC positive staining

Negative staining

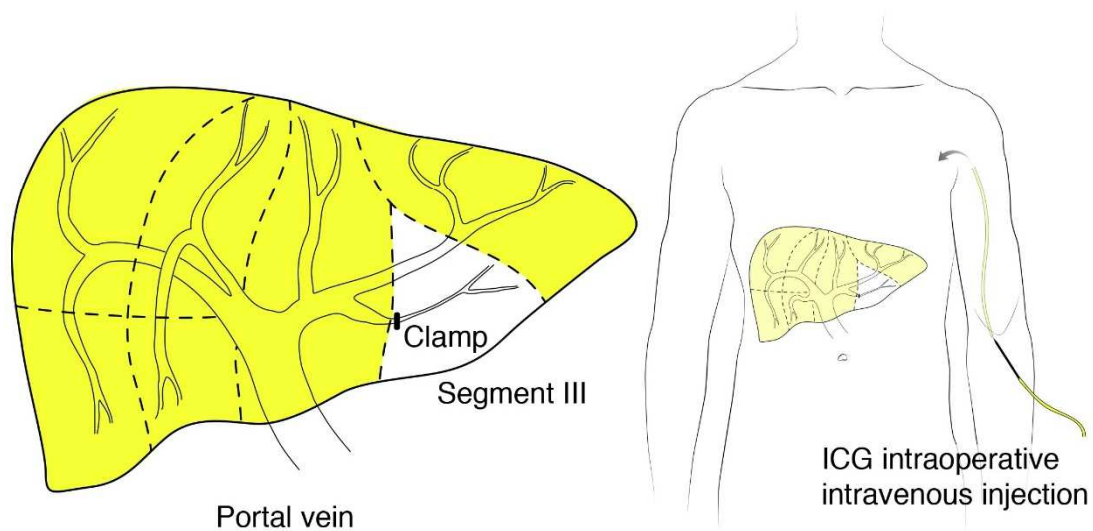


Figure 1b. Schematic representation of IGC negative staining

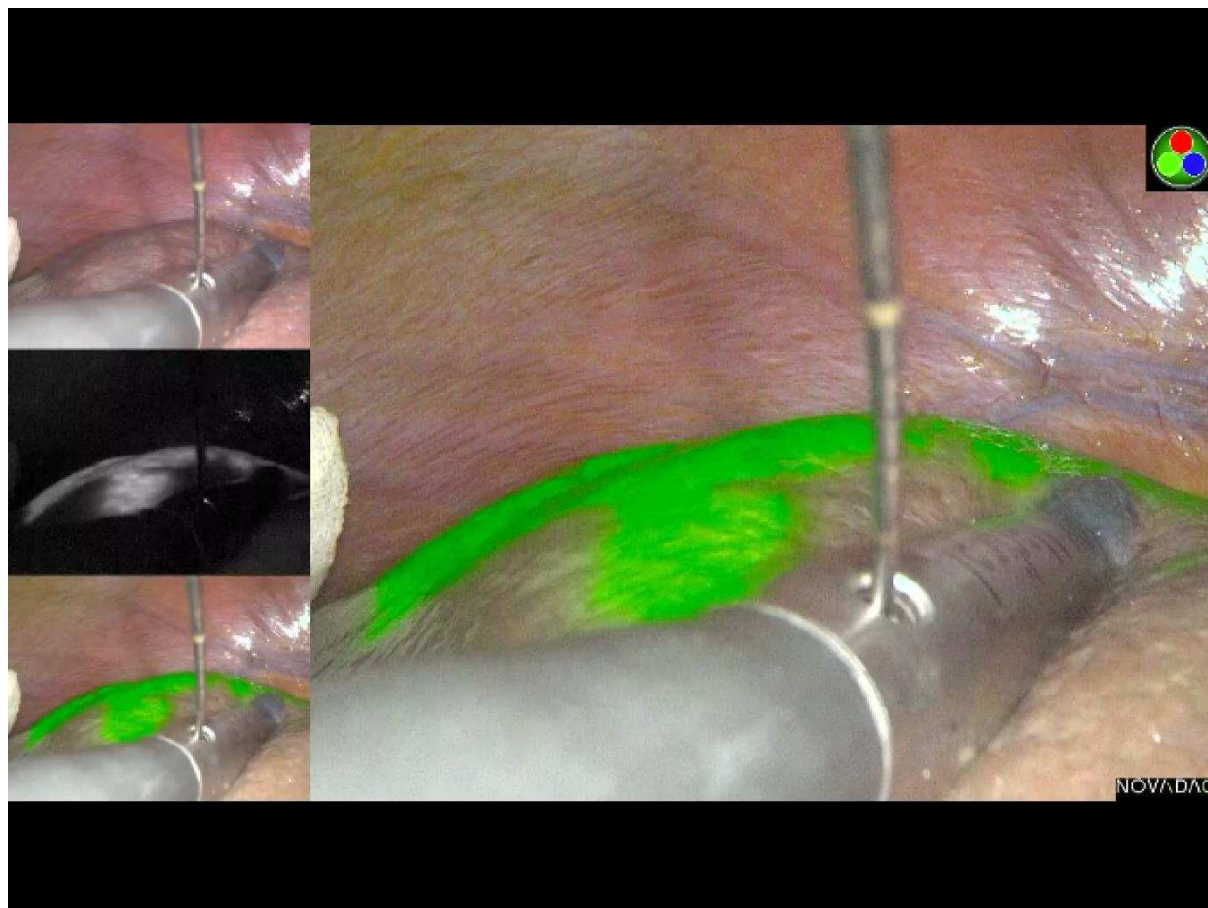


Figure 2. Positive staining: laparoscopic direct intraoperative ICG injection under ultrasound guidance. The stained segment becomes green with a fusion image camera.

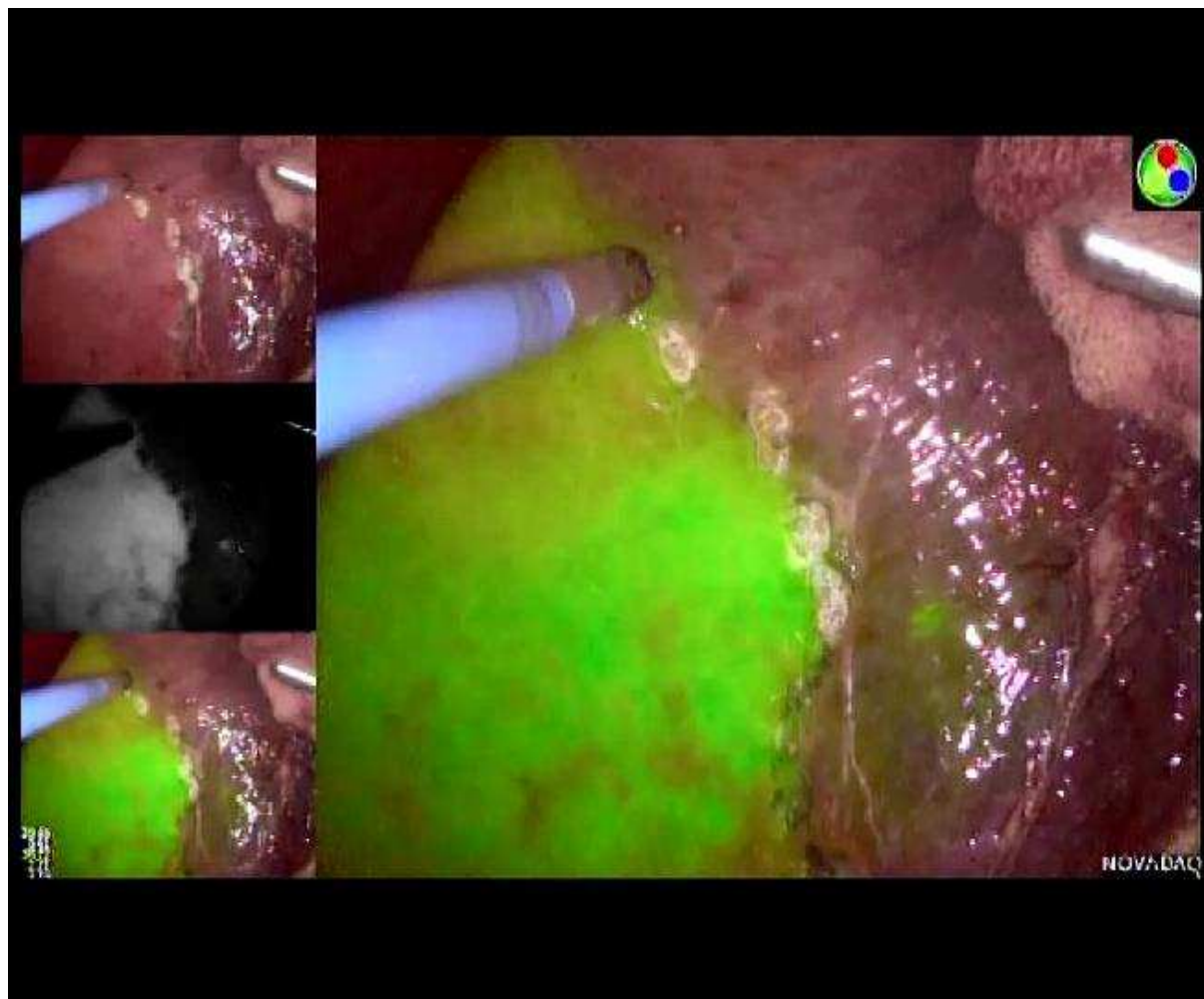


Figure 3a. Negative staining: intravenous ICG injection; fluorescence is present on the remnant liver.

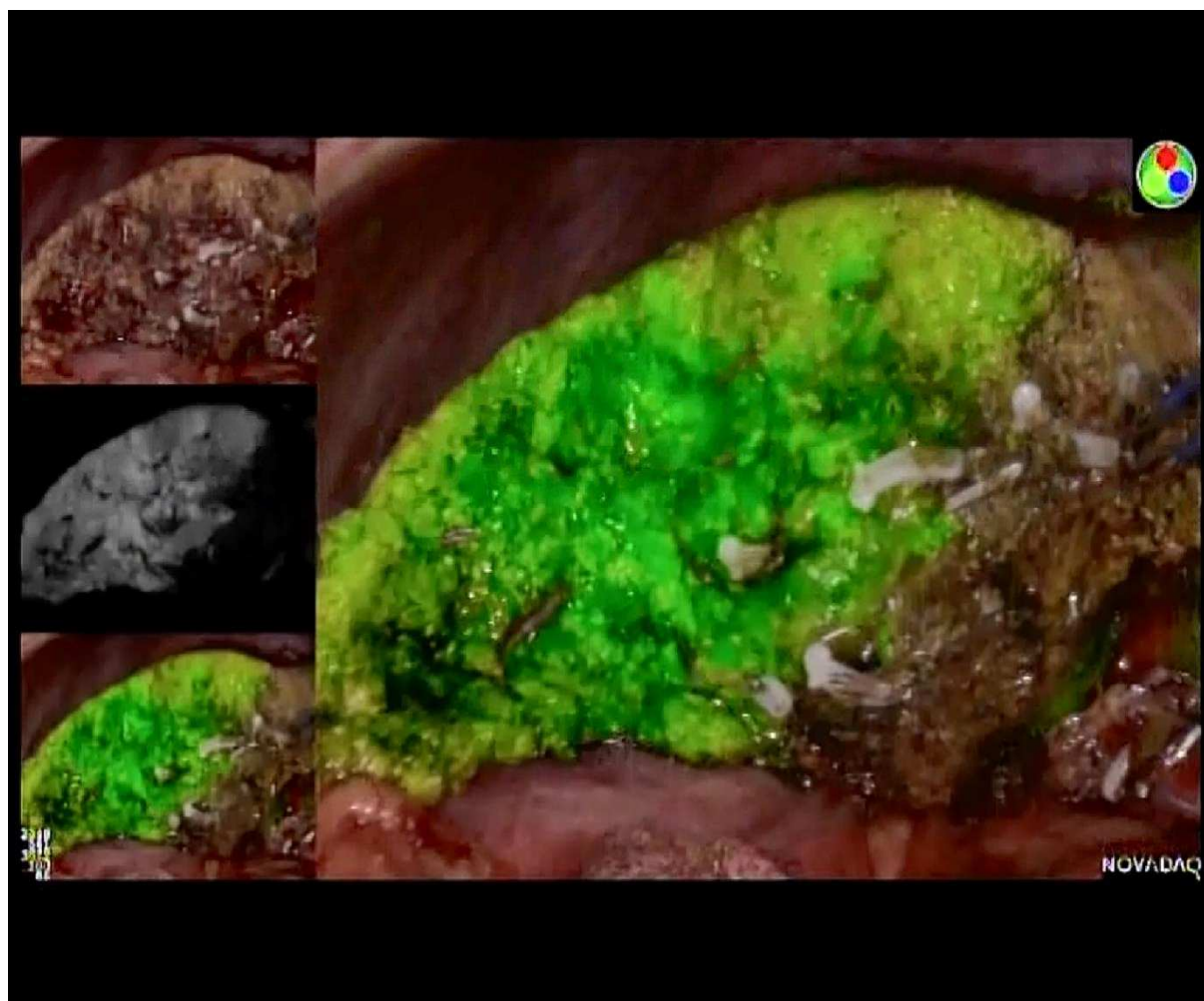


Figure 3b. Negative staining: during resection, the perfused remnant liver is green on the surface as well as intraparenchymally.



PRISMA 2009 Flow Diagram

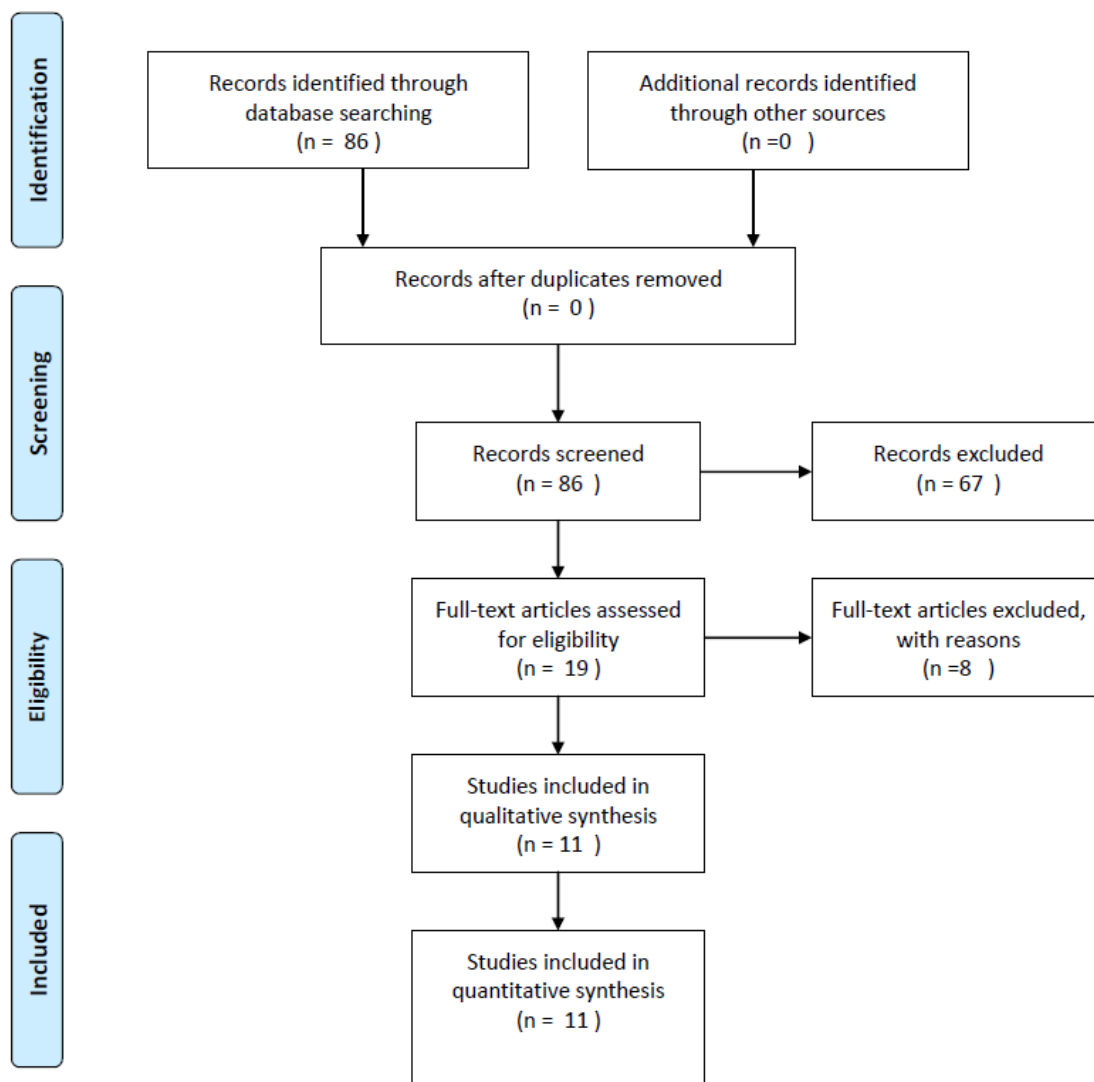


Figure 4. Preferred reporting items for systematic reviews and meta-analysis (PRISMA) flow diagram

References

1. Hasegawa K, Kokudo N, Imamura H, et al. Prognostic impact of anatomic resection for hepatocellular carcinoma. *Ann Surg* 2005; 242(2):252-9.
2. Kosuge T, Makuuchi M, Takayama T, et al. Long-term results after resection of hepatocellular carcinoma: experience of 480 cases. *Hepatogastroenterology* 1993; 40(4):328-32.
3. Ueno S, Kubo F, Sakoda M, et al. Efficacy of anatomic resection vs nonanatomic resection for small nodular hepatocellular carcinoma based on gross classification. *J Hepatobiliary Pancreat Surg* 2008; 15(5):493-500.
4. Yamamoto M, Takasaki K, Ohtsubo T, et al. Effectiveness of systematized hepatectomy with Glisson's pedicle transection at the hepatic hilus for small nodular hepatocellular carcinoma: retrospective analysis. *Surgery* 2001; 130(3):443-8.
5. Brudvik KW, Mise Y, Chung MH, et al. RAS Mutation Predicts Positive Resection Margins and Narrower Resection Margins in Patients Undergoing Resection of Colorectal Liver Metastases. *Ann Surg Oncol* 2016; 23(8):2635-43.
6. Yamashita S, Venkatesan AM, Mizuno T, et al. Remnant Liver Ischemia as a Prognostic Factor for Cancer-Specific Survival After Resection of Colorectal Liver Metastases. *JAMA Surg* 2017; 152(10):e172986.
7. Si A, Li J, Yang Z, et al. Impact of Anatomical Versus Non-anatomical Liver Resection on Short- and Long-Term Outcomes for Patients with Intrahepatic Cholangiocarcinoma. *Ann Surg Oncol* 2019; 26(6):1841-1850.
8. Majno P, Mentha G, Toso C, et al. Anatomy of the liver: an outline with three levels of complexity--a further step towards tailored territorial liver resections. *J Hepatol* 2014; 60(3):654-62.
9. Ferrero A, Lo Tesoriere R, Russolillo N, et al. Ultrasound-guided laparoscopic liver resections. *Surg Endosc* 2015; 29(4):1002-5.
10. Makuuchi M, Hasegawa H, Yamazaki S. Ultrasonically guided subsegmentectomy. *Surg Gynecol Obstet* 1985; 161(4):346-50.
11. Shindoh J, Seyama Y, Matsuda M, et al. Continuous ultrasound navigation for safe and precise anatomic resection of the liver. *Hepatogastroenterology* 2013; 60(123):590-4.
12. Torzilli G, Makuuchi M. Ultrasound-guided finger compression in liver subsegmentectomy for hepatocellular carcinoma. *Surg Endosc* 2004; 18(1):136-9.
13. Tanaka T, Takatsuki M, Hidaka M, et al. Is a fluorescence navigation system with indocyanine green effective enough to detect liver malignancies? *J Hepatobiliary Pancreat Sci* 2014; 21(3):199-204.
14. Aoki T, Yasuda D, Shimizu Y, et al. Image-guided liver mapping using fluorescence navigation system with indocyanine green for anatomical hepatic resection. *World J Surg* 2008; 32(8):1763-7.
15. Wakabayashi G, Cherqui D, Geller DA, et al. Recommendations for laparoscopic liver resection: a report from the second international consensus conference held in Morioka. *Ann Surg* 2015; 261(4):619-29.
16. Abu Hilal M, Aldrighetti L, Dagher I, Edwin B, et al. The Southampton Consensus Guidelines for Laparoscopic Liver Surgery: From Indication to Implementation. *Ann Surg*. 2018 Jul;268(1):11-18
17. Ishizawa T, Zuker NB, Kokudo N, et al. Positive and negative staining of hepatic segments by use of fluorescent imaging techniques during laparoscopic hepatectomy. *Arch Surg* 2012; 147(4):393-4.
18. Sakoda M, Ueno S, Iino S, et al. Anatomical laparoscopic hepatectomy for hepatocellular carcinoma using indocyanine green fluorescence imaging. *J Laparoendosc Adv Surg Tech A* 2014; 24(12):878-82.
19. Terasawa M, Ishizawa T, Mise Y, et al. Applications of fusion-fluorescence imaging using indocyanine green in laparoscopic hepatectomy. *Surg Endosc* 2017; 31(12):5111-5118.
20. Ito D, Ishizawa T, Hasegawa K. Laparoscopic positive staining of hepatic segments using indocyanine green-fluorescence imaging. *J Hepatobiliary Pancreat Sci* 2020.

21. Takasaki K. Glissonean pedicle transection method for hepatic resection: a new concept of liver segmentation. *J Hepatobiliary Pancreat Surg* 1998; 5(3):286-91.
22. Mizuno T, Sheth R, Yamamoto M, et al. Laparoscopic Glissonean Pedicle Transection (Takasaki) for Negative Fluorescent Counterstaining of Segment 6. *Ann Surg Oncol* 2017; 24(4):1046-1047.
23. Nomi T, Hokuto D, Yoshikawa T, et al. A Novel Navigation for Laparoscopic Anatomic Liver Resection Using Indocyanine Green Fluorescence. *Ann Surg Oncol* 2018; 25(13):3982.
24. Urade T, Sawa H, Iwatani Y, et al. Laparoscopic anatomical liver resection using indocyanine green fluorescence imaging. *Asian J Surg* 2020; 43(1):362-368.
25. Ueno M, Hayami S, Sonomura T, et al. Concomitant Use of Indocyanine Green Fluorescence Imaging and Interventional Radiology for Detection of Liver Segments During Laparoscopic Anatomical Liver Resection: Pilot Feasibility Study. *Surg Laparosc Endosc Percutan Tech* 2019; 29(4):242-246.
26. Berardi G, Wakabayashi G, Igarashi K, et al. Full Laparoscopic Anatomical Segment 8 Resection for Hepatocellular Carcinoma Using the Glissonian Approach with Indocyanine Green Dye Fluorescence. *Ann Surg Oncol* 2019; 26(8):2577-2578.
27. Aoki T, Koizumi T, Mansour DA, et al. Ultrasound-Guided Preoperative Positive Percutaneous Indocyanine Green Fluorescence Staining for Laparoscopic Anatomical Liver Resection. *J Am Coll Surg* 2020; 230(3):e7-e12.
28. Landsman ML, Kwant G, Mook GA, et al. Light-absorbing properties, stability, and spectral stabilization of indocyanine green. *J Appl Physiol* 1976; 40(4):575-83.
29. van Manen L, Handgraaf HJ, Diana M, et al. A practical guide for the use of indocyanine green and methylene blue in fluorescence-guided abdominal surgery. *Journal of surgical oncology* 2018; 118(2):283-300.
30. Baiocchi GL, Diana M, Boni L. Indocyanine green-based fluorescence imaging in visceral and hepatobiliary and pancreatic surgery: State of the art and future directions. *World journal of gastroenterology* 2018; 24(27):2921.
31. Diana M. Enabling precision digestive surgery with fluorescence imaging. *Translational gastroenterology and hepatology* 2017; 2.
32. Miyata A, Ishizawa T, Tani K, et al. Reappraisal of a Dye-Staining Technique for Anatomic Hepatectomy by the Concomitant Use of Indocyanine Green Fluorescence Imaging. *J Am Coll Surg* 2015; 221(2):e27-36.
33. Inoue Y, Arita J, Sakamoto T, et al. Anatomical Liver Resections Guided by 3-Dimensional Parenchymal Staining Using Fusion Indocyanine Green Fluorescence Imaging. *Ann Surg* 2015; 262(1):105-11.
34. Xu Y, Chen M, Meng X, LU P, et al. Laparoscopic anatomical liver resection guided by real-time indocyanine green fluorescence imaging: experience and lessons learned from the initial series in a single center *Surg End* (2020) 34, 4683-4691
35. Hirst A, Philippou Y, Blazeby J, Campbell B, et al. No Surgical Innovation Without Evaluation: Evolution and Further Development of the IDEAL Framework and Recommendations. *Ann Surg*. 2019 Feb;269(2):211-220.
36. Adrian K H Chiow, Seoung Yoon Rho, Ian J.Y. Wee, Lip Seng Lee, Gi Hong Choi. Robotic ICG guided anatomical liver resection in a multicentre cohort: an evolution from “positive staining” into “negative staining” method
37. Felli E, Baumert T, Pessaux P. Is minimally invasive true anatomical HCC resection a future way to improve results in bridge or salvage liver transplantation? *Clin Res Hepatol Gastroenterol* 2020.