



HAL
open science

Feasibility of Endovascular Recanalization in Post-Thrombotic Syndrome of Intentionally Interrupted Inferior Vena Cava

Valerie Monnin-Bares, Mathieu Rodiere, Mathieu Finas, Frederic Douane, Alexandre Lablee, Antoine Larralde, Zarqane Hamid, Vernhet-Kovacsik Helene, Frederic Thony, Sebastien Bommart

► To cite this version:

Valerie Monnin-Bares, Mathieu Rodiere, Mathieu Finas, Frederic Douane, Alexandre Lablee, et al.. Feasibility of Endovascular Recanalization in Post-Thrombotic Syndrome of Intentionally Interrupted Inferior Vena Cava. CardioVascular and Interventional Radiology, 2022, 10.1007/s00270-022-03179-y . hal-03695872

HAL Id: hal-03695872

<https://hal.science/hal-03695872>

Submitted on 17 Nov 2023

HAL is a multi-disciplinary open access archive for the deposit and dissemination of scientific research documents, whether they are published or not. The documents may come from teaching and research institutions in France or abroad, or from public or private research centers.

L'archive ouverte pluridisciplinaire **HAL**, est destinée au dépôt et à la diffusion de documents scientifiques de niveau recherche, publiés ou non, émanant des établissements d'enseignement et de recherche français ou étrangers, des laboratoires publics ou privés.

Feasibility of Endovascular Recanalization in Post-Thrombotic Syndrome of Intentionally Interrupted Inferior Vena Cava

Valerie Monnin-Bares¹, Mathieu Rodiere², Mathieu Finas², Frederic Douane³, Alexandre Lablee⁴, Antoine Larralde⁴, Zarqane Hamid¹, Vernhet-Kovacsik Helene¹, Frederic Thony², Sebastien Bommart^{1,5}

1 Radiology Department, CHRU, Montpellier, France

2 Radiology Department, CHRU, Grenoble, France

3 Radiology Department, CHRU, Nantes, France

4 Radiology Department, CHRU, Rennes, France

5 NSERM U 1046, CNRS UMR 9214, PHYMEDEXP , Montpellier University, Montpellier, France

Keywords

Endovascular recanalization _ Stenting _ Iliocaval occlusion _ Plicating clip _ Post-thrombotic syndrome

Abstract

Purpose

Surgical plication of inferior vena cava was commonly used until the 1980s for prevention of pulmonary embolism, associated with high incidence of postthrombotic syndrome (PTS). This study aims to assess the feasibility and safety of endovascular ilio caval recanalization after intentionally surgically interrupted inferior vena cava by external plicating clip.

Materials and methods

Endovascular ilio caval recanalizations in relation to previous vena cava clip plication were extracted from the retrospective French multicentre database and further analysed. All procedure data were retrospectively reviewed, including technical aspects, technical success and outcomes (clinical response and ultrasound stent patency).

Results

From 2016 to 2018, 8 patients from 4 different centres underwent endovascular ilio caval recanalization for PTS in relation to previous caval interruption by clip. Recanalization of ilio caval occlusion through the clip and stent reconstruction were successfully performed for all of them without complications. After angioplasty, plicating clip was opened in U shape (n = 3) or ovalized without significant residual stenosis (n = 5). Patency of the inferior vena cava was maintained for all patients with a mean follow-up of almost two years after stenting. All patients clinically improved.

Conclusions

In this small cases series, endovascular recanalization and stenting of surgical vena cava clip plication seem technically feasible without morbidity. Restoration of blood flow through the ilio caval occlusion, using non-invasive endovascular technique, even as late treatment may be durable, with improvement of patient's venous symptoms.

--

Introduction

Partial plication of inferior vena cava (IVC) using suture or specially designed clips was the standard of care following deep venous thrombosis and commonly used until the 1980s to prevent pulmonary embolism before the introduction of percutaneous vena cava filters. Although the latest practice using current retrieval devices is not free of complication, with a 0.4% complete occlusion rate [1, 2], IVC occlusion is more likely to occur following surgical plications [3]. Indeed, late venous sequelae after surgical IVC plication have been reported in the range of 20 to 50% of these patients [4]. Percutaneous recanalization with angioplasty and stenting have progressively replaced open surgery, becoming the

current method recommended to treat post-thrombotic syndrome (PTS) [5]. Whereas endovascular recanalization of thrombosed filter bearing IVCs has been previously widely described [6–12], the potential to recanalize intentionally interrupted IVC has been described in only few case reports [13, 14], and only once dealing specifically with external clipping [14]. This study aims to assess the feasibility and safety of endovascular recanalization to open the clip and reconstruct ilio caval confluence after vena cava plication.

Materials and Methods

Patient Identification

We did a retrospective observational registry-based study of the French Society of Diagnostic and Interventional Cardiovascular Imaging (SFICV) database [15]. Endovascular ilio caval recanalizations in relation to previous vena cava clip plication were extracted from this multicentre database and further analysed.

Endovascular Recanalization Procedures

Venous Doppler ultrasound and direct CT phlebography were systematically performed before each procedure, to confirm the diagnosis of ilio caval occlusion, assess femoral involvement and plan venous recanalization and stent reconstruction.

Procedures were performed using sedation (n = 7) or under general anaesthesia with endotracheal intubation (n = in a dedicated angio suite or hybrid operative room).

Intravenous bolus of 50 UI/kg of unfractionated heparin was injected during the procedure for all patients.

Ultrasound-guided percutaneous access was achieved using right jugular vein for all patients, completed by femoral vein for five patients (ipsilateral of thrombosed side n = 3 or bilateral n = 2).

Ilio caval recanalization and stent reconstruction were performed according to standards of practice guidelines [5].

Occlusions were crossed with a standard or stiff hydrophilic guidewire and a support catheter; then, inflow venography was performed to document the sites of venous occlusion. After progressive predilatation almost up to the nominal diameter of the subsequently used stent, large selfexpanding nitinol stent (Sinus XL, Optimed, Ettlingen, Germany) was deployed inside the clip. Stent expansion was checked by front and profile fluoroscopy or by cone beam CT. In case of residual stenosis, a steel balloon-expandable stent (Palmaz XL, Cordis, Johnson and Johnson Interventions, Warren, NJ) was added. Extensive stenting of upstream lesions was performed between two healthy landing zones.

All procedure data were reviewed to identify the way the clip was opened and details regarding nominal balloon diameters, stent sizes and stent brands used for each patient at the vein level.

Medical Treatment and Follow Up

After procedure, anticoagulation treatment included antiplatelet therapy and therapeutic dose of LMWH for the first month. Then oral anticoagulation was prescribed for at least 6 months. Patients were monitored clinically and with a Doppler ultrasound at day 1, months 1, 6 and 12, then every year thereafter. Venous score assessment was performed at 1 month.

Recorded Variables

Technical aspects of recanalization were reported: i) the way that the clip was opened, ii) balloon diameters, iii) stent sizes and stent brands for each vein level and iv) number of stents.

Primary technical success (as described previously as per the Cardiovascular and Interventional Radiologic Society guidelines [5]) and complications (in accordance with CIRSE clinical practice manual [16]) were recorded.

Clinical response (venous scores assessment) and primary/ primary-assisted/secondary stent patency rates (Doppler ultrasound assessment) were collected.

Table 1 Patient's characteristic

| Patient | Sex | Age | Delay from diagnosis to treatment (years) | Thrombophilia | Prothrombotic risk factors |
|---------|-----|-----|---|---|----------------------------|
| 1 | M | 55 | 35 | 0 | Trauma |
| 2 | F | 60 | 35.8 | 0 | Pregnancy -puerperium |
| 3 | M | 72 | 32.8 | 0 | 0 |
| 4 | F | 61 | 41.8 | Factor V Leiden heterozygous | Surgery |
| 5 | M | 65 | 40.9 | Anti-cardiolipin antibodies, factor II mutation | Antiphospholipid syndrome |
| 6 | F | 52 | 34.4 | 0 | 0 |
| 7 | M | 70 | 18.9 | Protein C deficiency | 0 |
| 8 | M | 46 | 22.9 | 0 | 0 |

Table 2 Technical results

| Pt | Bilateral ilio caval obstruction | Femoral vein involvement/ grade | Plicating clip disruption | | | | Number of stents | Technical Success | of hospital stay (days) | Complication |
|----|----------------------------------|---------------------------------|---------------------------|------------------------------------|--|--------------------|------------------|-------------------|-------------------------|--------------|
| | | | Balloon diameter (mm) | Self-expanding stent diameter (mm) | Use of Palmaz balloon expandable stent | Type of disruption | | | | |
| 1 | Y | Y (2) | 16 | 18 | N | Oval shape | 8 | Y | 2 | N |
| 2 | Y | Y (1) | 18 | 20 | Y | Oval shape | 5 | Y | 2 | N |
| 3 | N (left) | Y (2) | 18 | 22 | N | Complete rupture | 3 | Y | 2 | N |
| 4 | Y | Y (2) | 18 | 22 | Y | Complete rupture | 8 | Y | 2 | N |
| 5 | Y | Y (2) | 16 | 20 | N | Oval shape | 6 | Y | 2 | N |
| 6 | Y | N | 2 × 14 | 24 | N | Complete rupture | 4 | Y | 4 | N |
| 7 | Y | N | 18 | 22 | Y | Oval shape | 5 | Y | 2 | N |
| 8 | N (right) | Y (3) | 16 | 14 | Y (*) | Oval shape | 4 | Y | 2 | N |

(*) 1 month later

Results

Patient's Characteristics

From January 2009 to December 2019, 698 consecutive patients from 15 medical centres were registered in the SFICV database after endovenous recanalization for chronic PTS, of whom 122 with ilio caval occlusion. Among them, eight patients from four different centres fulfilled the definition criteria for inferior vena cava occlusion secondary to previous intentionally surgically caval interruption by external clipping.

There were 5 men and 3 women, with a mean age of 60 ± 9 years (range 46–72 years). All patients presented PTS characterized by venous claudication, leg swelling and/or skin changes. Mean Villalta score prior to treatment was 17 ± 5 (range 8–22) (moderate PTS $n = 1$, intermediate PTS $n = 1$, severe PTS $n = 6$ including 2 patients with venous leg ulceration). The mean delay from diagnosis of thrombosis to endovenous recanalization was 33 ± 8 years (range 19–42 years).

Characteristics of patients are summarized in Table 1.

Technical Results (Table 2)

Six patients presented a bilateral ilio caval occlusion, and two patients had only one lower limb involved associated with caval obstruction (left iliofemoral venous segment $n = 1$ and right iliac vein $n = 1$). Superficial femoral vein was involved in 6 patients, with severe lesions for 5 patients (grade 2 $n = 4$ and grade 3 $n = 1$ according to the scale proposed by Menez et al. [17]).

All the clip recanalization procedures were successfully performed with stent reconstruction, without complications.

In case of bilateral iliac occlusion, ilio caval confluence was treated by deploying a large diameter stent in IVC and two self-expanding stents into both iliac veins with an overlap of a few centimetres in inferior vena cava stent (confluence technique [18]).

For four patients, opening of plicating clip was easily performed with nitinol self-expanding stent and balloon angioplasty (Figs. 1 and 2). For others, the use of a Palmaz balloon-expandable stent inside the self-expanding stent (Fig. 3) was necessary to correctly open the clip and restore sufficient lumen in vena cava (at the same time of the initial procedure for 3 patients and one month later for one because of residual stenosis). Opening of the clip should be assessed by cone beam CT or by front and profile fluoroscopy because any residual necking is done in the anteroposterior direction. For five patients, plicating clip was ovalized after angioplasty with an opening sufficient to restore the flow without significant residual stenosis (Fig. 1). For the three others, angioplasty induced a rupture of the suture linking the two limbs of the clip in U shape (Figs. 2 and 3).

Fig. 1 Patient number 5. Direct computed tomography venography demonstrating the presence of a plicating clip across the vena cava in oblique axial reconstruction (A) and VRT reconstruction (B) with bilateral ilio-caval occlusion upstream. Plain fluoroscopy showing balloon imprint during angioplasty next to the clip (C, D) but not the clip itself. Opening of the clip assessed by post-procedural CT scan on VRT reconstructions with front (E) and profile (F) projections after ilio-caval reconstruction by nitinol self-expandable stents. Oblique multiplanar reconstruction showing ovalization without rupture of the clip (G)

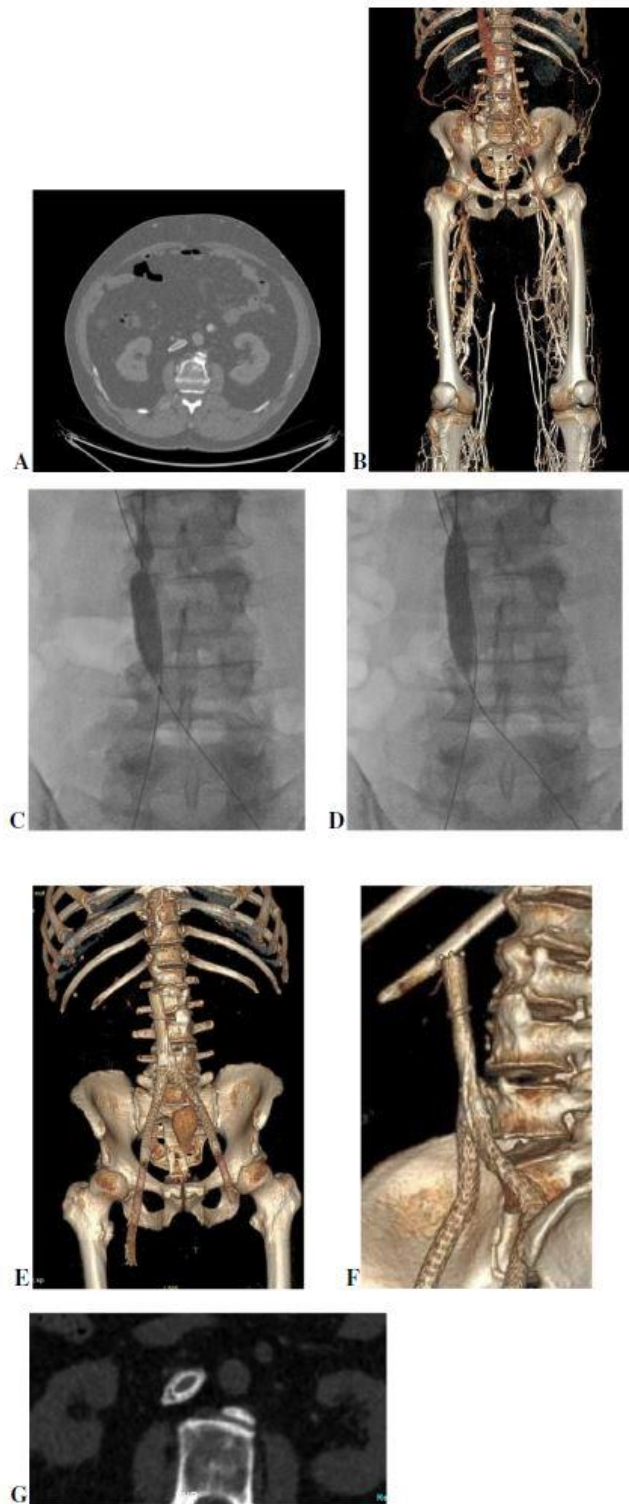
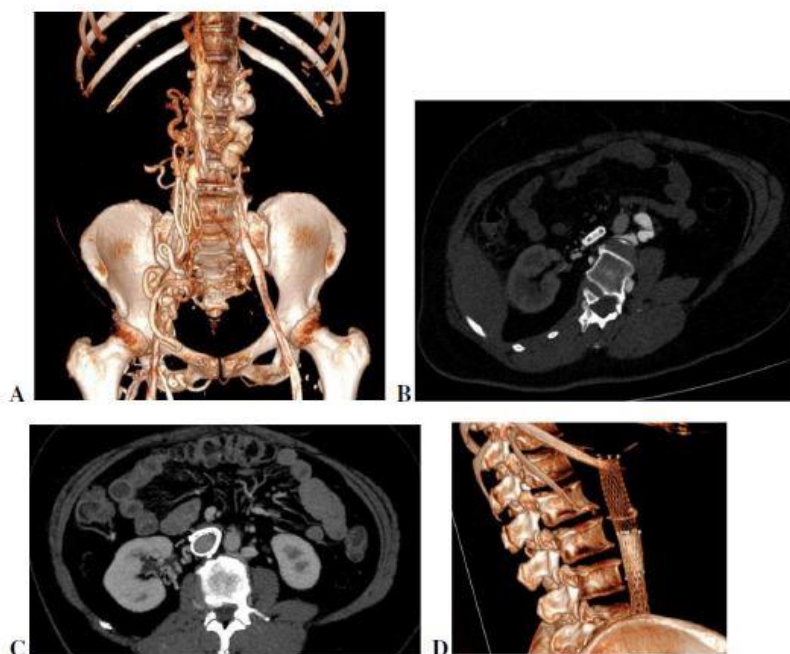


Fig. 2 Patient number 6.
 A Direct computed tomography venography with VRT reconstruction demonstrating the presence of a plicating clip across the vena cava with bilateral ilio-caval occlusion upstream being predominant on the right. B Pre-procedure CT scan with oblique axial reconstruction in the plane of the device showing the two limbs held together constricting vena cava. Post-procedure CT scan with MIP (C) and VRT (D) reconstruction showing the opening of the clip after balloon angioplasty and self-expanding stent, with complete rupture of the suture linking the two limbs of the clip in U shape



No Complications Occurred

Patients were discharged from the hospital after Doppler ultrasound assessment, and mean length of stay was 2 ± 1 days (range 2–4).

Clinical Outcomes and Mid-Term Stent Patency (Table 3)

The mean follow-up was 23 ± 14 months (range 10–52).

All patients clinically improved with a mean Villalta score [19] lowered from 17 down to 8 one month after the procedure. Chronic venous ulcers improved in both patients.

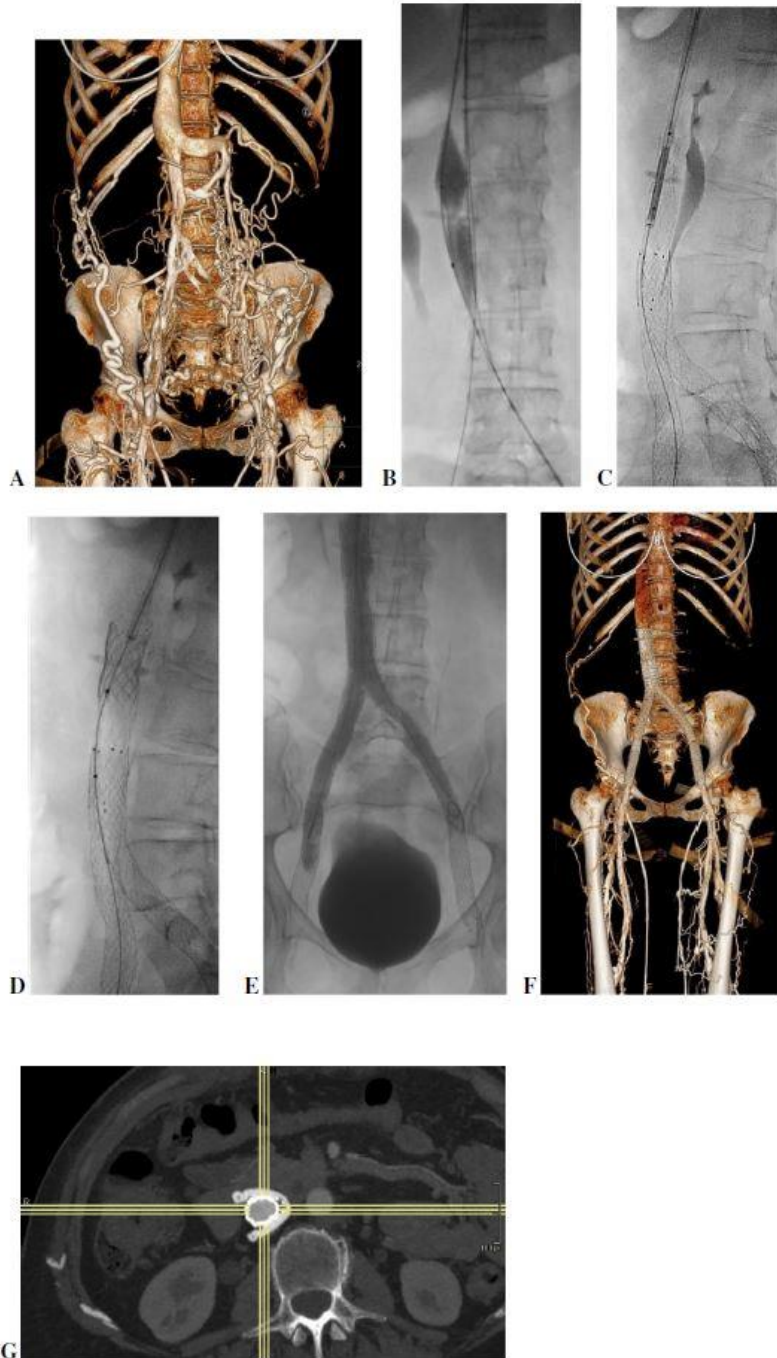
One patient (patient number 8) required re-intervention at one month because of residual stenosis at the plicating clip (without thrombosis), which was successfully treated by adding a Palmaz balloon-expandable stent.

We had two cases of late stent occlusion during followup.

The first one presented a re-thrombosis of left iliofemoral axis at 8 months (patient number 3), in relation to residual upstream stenosis. The second one presented a recurrence of right iliac stent thrombosis more than 2 years after the initial ilio-caval stent reconstruction (patient number 2). For both patients, vena cava stayed patent without recurrence of thrombosis at the clip. A second intervention was performed, involving unclogging thrombosed segments and angioplasty of residual stenosis. There was no subsequent recurrence of thrombosis during followup for either of them (respectively, 17 and 37 months).

Fig. 3 Patient number 4.

A Direct computed tomography venography with VRT reconstruction showing bilateral ilio-caval occlusion upstream and significant collaterality upstream a plicating clip across the vena cava. **B** Fluoroscopy antero-posterior projection showing imprint of the balloon at the clip. **C** Fluoroscopy on profile projection demonstrating a residual stenosis at the level of the clip after self-expandable stent, requiring complementary steel balloon-expandable Palmaz stent (**D**) for preventing elastic recoil (**E**). Post endovascular reconstruction of ilio-caval system angiographic control showing restoration of in-line flow without residual stenosis. **F** Post procedure direct computed tomography venography with VRT reconstruction showing resolution of occlusion and disappearance of collaterals. **G** Axial MIP reconstruction showing opening of the clip in U shape (complete rupture) without residual stenosis



Discussion

The most used serrated prosthetic clips for partial interruption of inferior vena cava in the seventies were Adams- De Weese and Miles clips [4]. The device was placed around the vein with two limbs held together by a suture tied around the grooves near the open end [20]. After crossing vena cava occlusion, balloon angioplasty allows to open the clip but removal of the balloon makes it return to its original shape. For half of the patients of this study, selfexpanding stent was sufficient to maintain a satisfactory diameter without significant

residual stenosis; however for the other half, an additional Palmaz balloon-expandable stent was needed for preventing elastic recoil. In 5 patients, angioplasty resulted in an ovalization of the clip while in 3 others; the clip was completely ruptured and opened in U shape. There was no obvious relationship between clip disruption in U shape or oval shape and the use of an additional Palmaz stent (Table 2). This also had no impact on long-term stent patency in our series.

The two cases of late stent occlusion in our study were only one-sided thrombosis in relation to local hemodynamic problems, without recurrence of caval occlusion despite inflow failure. Patency of the inferior vena cava was therefore maintained for all patients with a mean follow-up of almost two years after stenting, despite the existence of post-thrombotic venous lesions caudal to the common femoral vein in 75% of patients, including severe lesions.

The limit of this study is mainly the small sample size despite multicentric data collection because surgically IVC interruption by external clipping has been out of practice for a long time and few people are still currently suffering from post-thrombotic sequelae related to this type of intervention. Furthermore, the presence of the clip may lead to the mistaken belief that intervention is not possible for these patients.

Nevertheless, this case series of eight patients demonstrates that endovascular recanalization and stenting of surgical vena cava clip plication are technically feasible without morbidity (no retroperitoneal bleeding occurred at the opening of the clip). Restoration of blood flow through the ilio caval occlusion, using mini-invasive endovascular technique, even as a late treatment may be durable, with improvement of patient's venous symptoms.

References

1. Ahmad I, Yeddula K, Wicky S, Kalva SP. Clinical sequelae of thrombus in an inferior vena cava filter. *Cardiovasc Intervent Radiol.* 2010;33(2):285–9.
2. Fontaine M, Bosson JL, Bourgin Y, et al. Chronic venous insufficiency 7 to 10 years after partial vena cava interruption with a clip. *J Mal Vasc.* 1996;21(3):153–7.
3. Lagattolla NR, Burnand KG, Irvine A, Ferrar D. Twelve years experience of vena cava filtration. *Ann R Coll Surg Engl.* 1996;78(4):336–9.
4. Donaldson MC, Wirthlin LS, Donaldson GA. Thirty-year experience with surgical interruption of the inferior vena cava for prevention of pulmonary embolism. *Ann Surg.* 1980;191(3):367–72.
5. Mahnken AH, Thomson K, de Haan M, O'Sullivan GJ. CIRSE standards of practice guidelines on ilio caval stenting. *Cardiovasc Intervent Radiol.* 2014;37(4):889–97.
6. Chick JFB, Jo A, Meadows JM, et al. Endovascular Iliocaval Stent Reconstruction for Inferior Vena Cava Filter-Associated Iliocaval Thrombosis: Approach, Technical Success, Safety, and Two-Year Outcomes in 120 Patients. *J Vasc Interv Radiol.* 2017;28(7):933–9.
7. Partovi S, Kalva SP, Walker TG, Taj SM, Ganguli S. Long term follow-up of endovascular recanalization of chronic inferior vena cava occlusion secondary to inferior vena cava filters. *Vasa.* 2017;46(2):121–6.

8. Murphy EH, Johns B, Varney E, Raju S. Endovascular management of chronic total occlusions of the inferior vena cava and iliac veins. *J Vasc Surg Venous Lymphat Disord*. 2017;5(1):47–59.
9. Branco BC, Montero-Baker MF, Espinoza E, et al. Endovascular management of inferior vena cava filter thrombotic occlusion. *Vascular*. 2018;26(5):483–9.
10. Meltzer AJ, Connolly PH, Kabutey NK, Jones DW, Schneider DB. Endovascular recanalization of iliocaval and inferior vena cava filter chronic total occlusions. *J Vasc Surg Venous Lymphat Disord*. 2015;3(1):86–9.
11. Mesa A, Milazzo E, Rivera O, Hernandez T, Umanzor G. Chronic Inferior Vena Cava Filter Thrombosis: Endovascular Treatment and One-Year Follow-Up with Intravascular Ultrasonography. *Tex Heart Inst J*. 2020;47(2):140–3.
12. Ye K, Lu X, Li W, et al. Outcomes of Stent Placement for Chronic Occlusion of a Filter-bearing Inferior Vena Cava in Patients with Severe Post-thrombotic Syndrome. *Eur J Vasc Endovasc Surg*. 2016;52(6):839–46.
13. Gandhi AH, Wakefield TW, Williams DM. Recanalization of the intentionally interrupted inferior vena cava. *J Vasc Surg*. 2015;62(3):747–9.
14. Thomas SD, Ofri A, Tang T, Englund R. Endovascular reconstruction of an interrupted inferior vena cava. *Int J Surg Case Rep*. 2014;5(2):59–62.
15. David A, Thony F, Del Giudice C, et al. (2022) Short- and Mid- Term Outcomes of Endovascular Stenting for the Treatment of Post-Thrombotic Syndrome due to Iliofemoral and Caval Occlusive Disease: A Multi-Centric Study from the French Society of Diagnostic and Interventional Cardiovascular Imaging (SFICV). *Cardiovasc Intervent Radiol*
16. Mahnken AH, Boulosa Seoane E, Cannavale A, et al. CIRSE Clinical Practice Manual. *Cardiovasc Intervent Radiol*. 2021;44(9):1323–53.
17. Menez C, Rodiere M, Ghelfi J, et al. Endovascular Treatment of Post-thrombotic Venous Ilio-Femoral Occlusions: Prognostic Value of Venous Lesions Caudal to the Common Femoral Vein. *Cardiovasc Intervent Radiol*. 2019;42(8):1117–27.
18. de Graaf R, de Wolf M, Sailer AM, van Laanen J, Wittens C, Jalaie H. Iliocaval Confluence Stenting for Chronic Venous Obstructions. *Cardiovasc Intervent Radiol*. 2015;38(5):1198–204.
19. Villalta S, Prandoni P, Cogo A, et al. The utility of non-invasive tests for detection of previous proximal-vein thrombosis. *Thromb Haemost*. 1995;73(4):592–6.
20. Adams JT, DeWeese JA. Creation of the Adams-DeWeese inferior vena cava clip. *J Vasc Surg*. 2011;53(6):1745–7.