



HAL
open science

Mycobacterium simiae Infection in Two Unrelated Patients with Different Forms of Inherited IFN- γ R2 Deficiency

Rubén Martínez-Barricarte, Orli Megged, Polina Stepensky, Pierre Casimir, Marcela Moncada-Velez, Diana Averbuch, Marc Victor Assous, Omar Abuzaitoun, Xiao-Fei Kong, Vincent Pederghana, et al.

► **To cite this version:**

Rubén Martínez-Barricarte, Orli Megged, Polina Stepensky, Pierre Casimir, Marcela Moncada-Velez, et al.. Mycobacterium simiae Infection in Two Unrelated Patients with Different Forms of Inherited IFN- γ R2 Deficiency. *Journal of Clinical Immunology*, 2014, 34 (8), pp.904-909. 10.1007/s10875-014-0085-5 . hal-03691912

HAL Id: hal-03691912

<https://hal.science/hal-03691912v1>

Submitted on 18 Feb 2025

HAL is a multi-disciplinary open access archive for the deposit and dissemination of scientific research documents, whether they are published or not. The documents may come from teaching and research institutions in France or abroad, or from public or private research centers.

L'archive ouverte pluridisciplinaire **HAL**, est destinée au dépôt et à la diffusion de documents scientifiques de niveau recherche, publiés ou non, émanant des établissements d'enseignement et de recherche français ou étrangers, des laboratoires publics ou privés.

Published in final edited form as:

J Clin Immunol. 2014 November ; 34(8): 904–909. doi:10.1007/s10875-014-0085-5.

***Mycobacterium simiae* infection in two unrelated patients with different forms of inherited IFN- γ R2 deficiency**

Rubén Martínez-Barricarte^{1, #}, Orli Megged^{2, #}, Polina Stepensky^{3, #}, Pierre Casimir¹, Marcela Moncada-Velez^{1, 4}, Diana Averbuch⁵, Marc Victor Assous⁶, Omar Abuzaitoun⁷, Xiao-Fei Kong¹, Vincent Pedergnana⁸, Caroline Deswarte^{8, 9}, Mélanie Migaud^{8, 9}, Stefan Rose-John¹⁰, Yuval Itan¹, Bertrand Boisson¹, Aziz Belkadi^{8, 9}, Francesca Conti^{8, 9}, Laurent Abel^{1, 8, 9}, Guillaume Vogt^{8, 9}, Stephanie Boisson-Dupuis^{1, 8}, Jean-Laurent Casanova^{1, 8, 9, 11, §}, and Jacinta Bustamante^{8, 9, 12, §, *}

¹St. Giles Laboratory of Human Genetics of Infectious Diseases, Rockefeller Branch, The Rockefeller University, New York, NY, USA

²Pediatric Department and Pediatric Infectious Diseases Unit, Shaare Zedek Medical Center, Jerusalem, Israel

³Department of Pediatric Hematology-Oncology and Bone Marrow Transplantation, Hadassah-Hebrew University Medical Center Jerusalem, Israel

⁴Group of Primary Immunodeficiencies, Institute of Biology, University of Antioquia UdeA, Medellín, Colombia

⁵Pediatric Infectious Diseases Unit, Hadassah-Hebrew University Medical Center Jerusalem, Israel

⁶Clinical Microbiology Laboratory, Shaare Zedek Medical Center, Jerusalem, Israel

⁷Nablus Speciality Hospital, Nablus, Palestinian Authority

⁸Laboratory of Human Genetics of Infectious Diseases, Necker Branch, Institut National de la Santé et de la Recherche Médicale, INSERM-U1163, Paris, France, EU

⁹Paris Descartes University, Imagine Institute, France, EU

¹⁰Institute of Biochemistry, Universitaet Kiel, 24118, Germany, EU

¹¹Howard Hughes Medical Institute, USA

¹²Center for the Study of Primary Immunodeficiencies, Assistance Publique-Hôpitaux de Paris AP-HP, Necker-Enfants Malades Hospital, Paris, France, EU

Abstract

Interferon- γ receptor 2 (IFN- γ R2) deficiency is a rare primary immunodeficiency characterized by predisposition to infections with weakly virulent mycobacteria, such as environmental

*Corresponding author: Jacinta Bustamante: jacinta.bustamante@inserm.fr. Phone number: +33 1 42 75 43 20. Fax number: + 33 1 42 75 42 24.

#§ These authors contributed equally to this work.

Conflict of interest: The authors have no conflict of interest to declare.

mycobacteria and BCG vaccines. We describe here two children with IFN- γ R2 deficiency, from unrelated, consanguineous kindreds of Arab and Israeli descent. The first patient was a boy who died at the age of 4.5 years, from recurrent, disseminated disease caused by *Mycobacterium simiae*. His IFN- γ R2 defect was autosomal recessive and complete. The second patient was a girl with multiple disseminated mycobacterial infections, including infection with *M. simiae*. She died at the age of five years, a short time after the transplantation of umbilical cord blood cells from an unrelated donor. Her IFN- γ R2 defect was autosomal recessive and partial. Autosomal recessive IFN- γ R2 deficiency is life-threatening, even in its partial form, and genetic diagnosis and familial counseling are therefore particularly important for this condition. These two cases are the first of IFN- γ R2 deficiency associated with *M. simiae* infection to be described.

Keywords

MSMD; *Mycobacterium simiae*; interferon and IFN- γ R2 deficiency

Introduction

Mendelian susceptibility to mycobacterial disease (MSMD) is a rare disorder predisposing otherwise healthy individuals to severe clinical disease upon infection with weakly virulent mycobacteria. These mycobacterial species include: *Mycobacterium bovis* Bacille Calmette-Guerin (BCG) vaccine substrains and non-tuberculous environmental mycobacteria (EM), such as *M. fortuitum*, *M. chelonae*, *M. abscessus*, *M. avium complex*, *M. kansasii*, *M. marinaram*, *M. scrofulaceum*, *M. smegmatis*, *M. peregrinum*, *M. tilburgii* and, more rarely, *M. simiae* [1-4]. Affected individuals, usually young children, are also susceptible to *Salmonella* [4-7] and to the more virulent mycobacterium *M. tuberculosis*, in endemic areas [1, 4, 7-9]. A high degree of consanguinity was observed in MSMD patients [2, 5]. The genetic dissection of MSMD has revealed germline mutations in nine genes (*IFNGR1*, *IFNGR2*, *STAT1*, *IL12B*, *IL12RB1*, *IRF8*, *ISG15*, *NEMO* and *CYBB*), the products of which are involved in IFN- γ -mediated immunity [5, 6, 10-13]. *GATA2* mutations also confer a predisposition to mycobacterial infection, but no patient with a strict MSMD phenotype and such a mutation has yet been reported [14, 15]. Mutations in the gene encoding the second chain of the interferon- γ receptor (*IFNGR2*) have been identified as one of the genetic causes of MSMD [16-18]. AR complete IFN- γ R2 deficiency displays complete penetrance and the most severe phenotype of any IFN- γ R2 deficiency, with frequent recurrences and high mortality [18-23]. The partial form is generally less severe but it also displays complete clinical penetrance [18, 23, 24]. A heterozygous mutation in *IFNGR2* caused autosomal dominant (AD) IFN- γ R2 deficiencies through haploinsufficiency with incomplete penetrance [17]. A dominant-negative effect has been demonstrated *in vitro* for one mutation in a healthy individual [22]. In total, 12, 5 and 2 cases of AR complete, partial, and AD forms of MSMD, respectively, have been reported to date [17, 19-25]. We report here the cases of two unrelated children suffering from MSMD and *M. simiae* infection, caused by AR complete and partial IFN- γ R2 deficiencies due to two previously unknown homozygous mutations, one resulting in a complete absence of detectable receptor expression and completely abolished signaling upon stimulation with IFN- γ , and the other involving

residual receptor expression and reduced signaling. As in other cases of AR IFN- γ -R2 deficiency [18, 21, 24], both patients have high level of IFN- γ in plasma.

Case report

Patient 1 (P1) (born in 2009): This male child, was born after 40 weeks of gestation, by normal spontaneous vaginal delivery. He weighed 3.6 kg at birth and was the 5th child of consanguineous Israeli Arab parents (Figure 1A). The parents and siblings were all healthy. The mother had 13 siblings, eight of whom had died before six weeks of age of unknown cause. The other five siblings remain healthy. All the other members of the extended family are healthy and were vaccinated with BCG without complications. At the age of 13 months, P1 was admitted to the hospital with left lower lobe pneumonia and mild pleural effusion not responding to oral amoxicillin treatment. The patient recovered after treatment with ceftriaxone and azithromycin. At the age of two years, he was hospitalized for right middle and lower lobe pneumonia with pleural effusion. He recovered after drainage of the pleural effusion and treatment with cefuroxime. No pathogen was isolated from the pleural effusion or blood cultures. At the age of 2.5 years, P1 was admitted to the hospital for an episode of fever and abdominal pain. He underwent surgery, which revealed a mass of lymph nodes close to the ileo-cecal valve. These lymph nodes were cultured, yielding non-typhoidal *Salmonella* (group C) that was susceptible to ampicillin, erythromycin and ceftriaxone and *M. simiae* displaying a high level of resistance to all drugs other than cycloserine (CYC). Blood culture was also positive for *M. simiae*. P1 was treated with clarithromycin (CLR) for the *Salmonella* infection, and with rifabutin (RIF), ethambutol (EMB), CYC and CLR for the mycobacterial infection. His condition gradually improved over a six-month period with negative blood cultures, the resolution of fever, weight gain and improvements in markers of inflammation, such as complete blood count (CBC), C-reactive protein (CRP) concentration and erythrocyte sedimentation rate (ESR). P1, still on the same drug regimen, was re-admitted at the age of 3.5 years, due to right upper and middle lobe pneumonia and mild pleural effusion. An enlarged spleen and liver were noted on physical examination, together with an enlargement of abdominal lymph nodes. Blood and sputum cultures again yielded *M. simiae*. The treatment was replaced with CYC, CLR, moxifloxacin and high-dose trimethoprim-sulfamethoxazole, with no improvement. Immunological evaluation included testing for immunoglobulins (Ig) and subclasses of IgG, immunophenotyping and assessments of the T-cell response to mitogens, HIV and neutrophil function tests, to rule out chronic granulomatous disease. Negative results were obtained in all these tests. The patient died at home at the age of 4.5 years, and no information is available concerning the immediate cause of death.

Patient 2 (P2) (born in 2009): This female child was born from consanguineous parents of Palestinian descent. She was the fourth out of five children. The oldest had developed an undiagnosed recurrent infection that led to progressive respiratory failure at the age of three months, leading to his death. The rest of the siblings and parents are healthy and were vaccinated with BCG at the age of one month. At the age of five months, P2 was admitted to the hospital while suffering an episode of severe diarrhea and a hemoglobin (Hgb) concentration of 5g per 100ml of blood. Upon physical examination, a significantly enlarged axillary lymph node was observed. Lymph node and bone marrow biopsy were both positive

for *M. bovis*. Combined antimycobacterial treatment was started with Isoniazid (INH), RIF and EMB, and continued for 27 months until P2 presented with high fever, limping, excessive leukocytosis and an increase in acute-phase reactants (ESR and CRP). Extensive testing was carried out and a few lytic bone lesions and hyperechogenic liver lesions were observed. Bone biopsy culture was negative, but liver biopsy culture was positive for *M. simiae* resistant to INH, RIF and EMB. However, *M. simiae* was susceptible to CYC, and therefore, was immediately added to the antimycobacterial treatment. At three years of age, she presented with significant axillary lymphadenopathy, whose culture was positive for *M. fortuitum*. This new episode was treated by adding macrolide to the regimen, which achieved some lymph node improvement. At five years of age, the patient was taken to the local hospital due to focal seizure. Lumbar puncture (LP) did not detect any pleocytosis or increase in protein content. However, the computed tomography (CT) revealed the presence of a few brain abscesses. Biopsy of these abscesses was positive for *M. simiae*. A massive antimycobacterial treatment was implemented, but the patient's condition worsened and she lost her vision from one eye and developed hemiparesis. In addition, brain imaging showed a progression of the abscesses despite repeated surgical debridement. As a last effort, umbilical cord blood (UCB) transplantation was performed from an unrelated donor, which was shown to be successfully engrafted at day +17. However, the progression of the mycobacterial brain abscess continued, and the patient's neurological status continued to deteriorate until her death on day +61 after transplantation.

The clinical presentation of these two cases led us to hypothesize that both patients suffered from MSMD. We carried out whole-exome sequencing (WES) on genomic DNA (gDNA) from P1 (kindred A, P1)[26]. Using this method and the human gene connectome [27], we identified a homozygous nonsense mutation in *IFNGR2*. This mutation was located in exon 4 and replaced the C residue in position 537 with a G, leading to the insertion of a premature stop codon (Y179X) (Figures 1B-C). In the case of P2 (kindred B, P2), we performed whole-genome linkage analysis on the family, and *IFNGR2* was found to be located within one of the linkage regions. Sanger sequencing revealed the insertion of a single nucleotide, a T residue in position 958, c.958insT, resulting in a frameshift leading to the production of a predicted protein of 382 amino acids, rather than the 337-amino acid wild-type protein (319Sfs382X) (Figures 1B-C). These mutations were not found in any of the public databases searched — dbSNP, the 1000 Genomes database (1092 subjects) or the NHLBI GO exome sequencing project database (6503 subjects) — or in our own exome database containing data for more than 1800 patients with other diseases. The familial segregation pattern (Figures 1B-C) showed that there were no other homozygous carriers of the mutations. We introduced a wild-type or each mutant *IFNGR2* cDNA into a pcDNA3.1 (Invitrogen) vector containing a C-terminal V5-tag. Overexpression of these constructs in IFN- γ R2-deficient SV40-immortalized fibroblasts (SV40-fibroblasts) showed that the Y179X mutation led to a complete lack of IFN- γ R2 expression whereas the c.958insT variant resulted in residual expression (Figure 1D). Transfection efficiency was assessed by determining *IFNGR2* mRNA levels by RT-qPCR (Supplemental figure 1A). We stimulated these SV40-fibroblasts transfected with each allele and an additional plasmid containing the already described mutant responsible for partial IFN- γ R2 deficiency [18] with IFN- γ (10^4 IU/ml) for 20 minutes and GAF DNA-binding activity was then assessed by electrophoretic

mobility shift assay (EMSA), as previously described [18]. Cells transfected with the Y179X allele displayed a total abolition of GAF DNA-binding activity, whereas this activity was impaired but not abolished with the c.958insT variant, suggesting complete deficiency for Y179X and partial deficiency for c.958insT (Figure 1E). Overall, cytokine responsiveness via the JAK/STAT pathway was confirmed by stimulation of the cells with Hyper-IL-6, a fusion protein of IL-6 and soluble IL-6R, and subsequent measurement of pSTAT3 [28] (Supplementary figure 1B). The partial deficiency of P2 was confirmed by stimulating with IFN- γ SV40-fibroblasts from this patient and appropriate controls, including the partially IFN- γ R2-deficient cells described in a previous study and a complete deficient c.278delAG [18] (Supplemental figure 2A). The cytokine response through the JAK/STAT pathway was assessed by stimulating the cells with Hyper-IL-6 and measuring the phosphorylation of STAT3 by western blot (Supplementary figure 2B). No biological material from P1 was available. As previously described for AR IFN- γ R2 deficiency, the patients had high plasma concentrations of IFN- γ (Figure 2) [21, 24]. As both patients died, we were unable to carry out functional assays on primary blood cells of these two patients.

Discussion

MSMD is a rare, severe condition affecting about 1 in 100,000 individuals [2]. Over the last 20 years, 17 genetic etiologies involving nine different genes have been described, all impairing IFN- γ immunity. In the two unrelated cases described here, the patients presented infection with EM, including *M. simiae*. Infection with *M. simiae* is extremely rare and an emerging pathogenic species in the Middle East. Such infections have been reported in only a few patients with various immunodeficiencies, including HIV infection [4, 29-31], in patients with chronic renal failure [31] and, even more exceptionally in immunocompetent individuals [32]. However, to the best of our knowledge, this infection has never before been reported in a context of IFN- γ R2 deficiency. The patients reported here carry two different unreported homozygous mutations of the *IFNGR2* gene, p.Y179X and c.958insT. These two mutations lead to impaired cellular responses to IFN- γ . These patients have high plasma IFN- γ concentrations, as reported in other cases of AR IFN- γ R2 deficiency [16, 19, 22]. The severity of the two forms of AR IFN- γ R2 deficiency is further illustrated by the deaths of the two patients described here from infectious complications, despite stem cell transplantation in P2. The development of molecular diagnostic tools potentially allowing physicians to offer preventive treatments to patients and genetic counseling to families suffering from this and other severe infections [33] is of considerable interest. For example, an early diagnosis of *IFNGR2* mutation is a contraindication for BCG vaccination and may constitute an indication for hematopoietic stem cell transplantation (for complete defects) or IFN- γ treatment (for partial defects) [15]. The two cases described here provide support for the notion that *IFNGR2* mutations or related genetic disorders should be considered in patients with *M. simiae* disease.

Supplementary Material

Refer to Web version on PubMed Central for supplementary material.

Acknowledgments

We would like to thank the patients and their families for their collaboration, and both branches of the Laboratory of Human Genetics of Infectious Diseases for helpful discussions and support. We would like to thank the staff of the Pediatric Hemato-oncology and Bone Marrow Transplantation, Hadassah and Pediatric Department, Shaarei Zedek Hospital Jerusalem, where the patients were treated. We would also like to thank Yelena Nemirovskaya, Lahouari Amar, Eric Anderson, Martine Courat and Tiffany Nivare for administrative support. This research was funded in part by the National Institute of Allergy and Infectious Diseases grant number 5R37AI095983, the National Center for Research Resources and the National Center for Advancing Sciences (NCATS) of the National Institutes of Health grant number 8UL1TR000043, The Rockefeller University, Institut National de la Santé et de la Recherche Médicale (INSERM), Paris Descartes University, the St. Giles Foundation and by the French National Research Agency (Agence Nationale de la Recherche ANR13-ISV3-0001-01). RMB was funded by the European Molecular Biology Organization (EMBO) and XFK was supported by Stony Wold-Herbert Fund, Choh-Hao Li Memorial Fund Scholar award and the Shanghai Educational Development Foundation.

References

- Alcaïs A, Fieschi C, Abel L, Casanova JL. Tuberculosis in children and adults: two distinct genetic diseases. *J Exp Med*. 2005; 202:1617–21. [PubMed: 16365144]
- Casanova JL, Abel L. Genetic dissection of immunity to mycobacteria: the human model. *Annu Rev Immunol*. 2002; 20:581–620. [PubMed: 11861613]
- Schepers K, Schandené L, Bustamante J, Vooren JP, Suremain M, Casanova JL, Yombi J, Jacobs F, Mascart F, Goffard JC. IL-12R β 1 Deficiency and Disseminated Mycobacterium tuberculosis Disease. *J Clin Immunol*. 2013; 33:1285–8. [PubMed: 24114017]
- de Beaucoudrey L, Samarina A, Bustamante J, Cobat A, Boisson-Dupuis S, Feinberg J, Al-Muhsen S, Jannièrè L, Rose Y, de Suremain M, Kong XF, Filipe-Santos O, Chappier A, Picard C, Fischer A, Dogu F, İkinciogullari A, Tanir G, Al-Hajjar S, Al-Jumaah S, Frayha HH, AlSum Z, Al-Ajaji S, Alangari A, Al-Ghoniaim A, Adimi P, Mansouri D, Ben-Mustapha I, Yancoski J, Garty BZ, Rodriguez-Gallego C, Caragol I, Kutukculer N, Kumararatne DS, Patel S, Doffinger R, Exley A, Jeppsson O, Reichenbach J, Nadal D, Boyko Y, Pietrucha B, Anderson S, Levin M, Schandené L, Schepers K, Efir A, Mascart F, Matsuoka M, Sakai T, Siegrist CA, Freceirova K, Blüetters-Sawatzki R, Bernhöft J, Freiherst J, Baumann U, Richter D, Haerynck F, De Baets F, Novelli V, Lammas D, Vermynen C, Tuerlinckx D, Nieuwhof C, Pac M, Haas WH, Müller-Fleckenstein I, Fleckenstein B, Levy J, Raj R, Cohen AC, Lewis DB, Holland SM, Yang KD, Wang X, Wang X, Jiang L, Yang X, Zhu C, Xie Y, Lee PPW, Chan KW, Chen TX, Castro G, Natera I, Codoceo A, King A, Bezrodnik L, Di Giovanni D, Gaillard MI, de Moraes-Vasconcelos D, Grumach AS, da Silva Duarte AJ, Aldana R, Espinosa-Rosales FJ, Bejaoui M, Bousfiha AA, Baghdadi JE, Özbek N, Aksu G, Keser M, Somer A, Hatipoglu N, Aydogmus Ç, Asilsoy S, Camcioglu Y, Güllü S, Ozgur TT, Ozen M, Oleastro M, Bernasconi A, Mamishi S, Parvaneh N, Rosenzweig S, Barbouche R, Pedraza S, Lau YL, Ehlayel MS, Fieschi C, Abel L, Sanal O, Casanova JL. Revisiting human IL-12R β 1 deficiency: a survey of 141 patients from 30 countries. *Medicine*. 2010; 89:381–402.10.1097/MD.0b013e3181fdd832 [PubMed: 21057261]
- Filipe-Santos O, Bustamante J, Chappier A, Vogt G, de Beaucoudrey L, Feinberg J, Jouanguy E, Boisson-Dupuis S, Fieschi C, Picard C, Casanova JL. Inborn errors of IL-12/23- and IFN- γ -mediated immunity: molecular, cellular, and clinical features. *Semin Immunol*. 2006; 18:347–61. [PubMed: 16997570]
- Haverkamp MH, van de Vosse E, vD JT. Nontuberculous mycobacterial infections in children with inborn errors of the immune system. *J Infect*. 2014; 68:S134–S50. [PubMed: 24119826]
- Prando C, Samarina A, Bustamante J, Boisson-Dupuis S, Cobat A, Picard C, AlSum Z, Al-Jumaah S, Al-Hajjar S, Frayha H, Alangari A, Al-Mousa H, Mobaarek K, Ben-Mustapha I, Adimi P, Feinberg J, de Suremain M, Jannièrè L, Filipe-Santos O, Mansouri N, Stephan J, Nallusamy R, Kumararatne D, Bloorasaz M, Ben-Ali M, Elloumi-Zghal H, Chemli J, Bouguila J, Bejaoui M, Alaki E, AlFawaz T, Al Idrissi E, ElGhazali G, Pollard A, Murugasu B, Wah Lee B, Halwani R, Al-Zahrani M, Al Shehri M, Al-Zahrani M, Bin-Hussain I, Mahdavian S, Parvaneh N, Abel L, Mansouri D, Barbouche R, Al-Muhsen S, Casanova J. Inherited IL-12p40 deficiency: genetic, immunologic, and clinical features of 49 patients from 30 kindreds. *Medicine*. 2013; 92:109–22. [PubMed: 23429356]

8. Boisson-Dupuis S, El Baghdadi J, Parvaneh N, Bousfiha A, Bustamante J, Feinberg J, Samarina A, Grant A, Janniere L, El Hafidi N, Hassani A, Nolan D, Najib J, Camcioglu Y, Hatipoglu N, Aydogmus C, Tanir G, AYTEKIN C, Keser M, Somer A, Aksu G, Kutukculer N, Mansouri D, Mahdaviani A, Mamishi S, Alcais A, Abel L, Casanova J. IL-12R β 1 deficiency in two of fifty children with severe tuberculosis from Iran, Morocco, and Turkey. *PLoS One*. 2011; 6:e18524. [PubMed: 21533230]
9. Tabarsi P, Marjani M, Mansouri N, Farnia P, Boisson-Dupuis S, Bustamante J, Abel L, Adimi P, Casanova JL, Mansouri D. Lethal tuberculosis in a previously healthy adult with IL-12 receptor deficiency. *J Clin Immunol*. 2011; 31:537–9. [PubMed: 21487897]
10. Casanova JL, Abel L. The genetic theory of infectious diseases: a brief history and selected illustrations. *Annu Rev Genomics Hum Genet*. 2013; 14:215–43. [PubMed: 23724903]
11. Bustamante J, Arias AA, Vogt G, Picard C, Galicia LB, Prando C, Grant AV, Marchal CC, Hubeau M, Chapgier A, de Beaucoudrey L, Puel A, Feinberg J, Valinetz E, Janniere L, Besse C, Boland A, Brisseau JM, Blanche S, Lortholary O, Fieschi C, Emile JF, Boisson-Dupuis S, Al-Muhsen S, Woda B, Newburger PE, Condino-Neto A, Dinayer MC, Abel L, Casanova JL. Germline *CYBB* mutations that selectively affect macrophages in kindreds with X-linked predisposition to tuberculous mycobacterial disease. *Nat Immunol*. 2011; 12:213–21. [PubMed: 21278736]
12. Bogunovic D, Byun M, Durfee LA, Abhyankar A, Sanal O, Mansouri D, Salem S, Radovanovic I, Grant AV, Adimi P, Mansouri N, Okada S, Bryant VL, Kong XF, Kreins A, Velez MM, Boisson B, Khalilzadeh S, Ozcelik U, Darazam IA, Schoggins JW, Rice CM, Al-Muhsen S, Behr M, Vogt G, Puel A, Bustamante J, Gros P, Huibregtse JM, Abel L, Boisson-Dupuis S, Casanova JL. Mycobacterial disease and impaired IFN- γ immunity in humans with inherited ISG15 deficiency. *Science*. 2012; 337:1684–8. [PubMed: 22859821]
13. Hambleton S, Salem S, Bustamante J, Bigley V, Boisson-Dupuis S, Azevedo J, Fortin A, Haniffa M, Ceron-Gutierrez L, Bacon CM, Menon G, Trouillet C, McDonald D, Carey P, Ginhoux F, Alsina L, Zumwalt TJ, Kong XF, Kumararatne D, Butler K, Hubeau M, Feinberg J, Al-Muhsen S, Cant A, Abel L, Chaussabel D, Doffinger R, Talesnik E, Grumach A, Duarte A, Abarca K, Moraes-Vasconcelos D, Burk D, Berghuis A, Geissmann F, Collin M, Casanova JL, Gros P. IRF8 mutations and human dendritic-cell immunodeficiency. *N Engl J Med*. 2011; 365:127–38. [PubMed: 21524210]
14. Spinner MA, Sanchez LA, Hsu AP, Shaw PA, Zerbe CS, Calvo KR, Arthur DC, Gu W, Gould CM, Brewer CC, Cowen EW, Freeman AF, Olivier KN, Uzel G, Zelazny AM, Daub JR, Spalding CD, Claypool RJ, Giri NK, Alter BP, Mace EM, Orange JS, Cuellar-Rodriguez J, Hickstein DD, Holland SM. GATA2 deficiency: a protein disorder of hematopoiesis, lymphatics, and immunity. *Blood*. 2014; 123:809–21. [PubMed: 24227816]
15. Holland, SM.; Casanova, JL. Inherited disorders of the interleukin-12-interleukin-23/interferon- γ circuit. In: Ochs, HD.; Smith, CIE.; JM, P., editors. *Primary immunodeficiency diseases: a molecular and genetic approach*. 3rd. Vol. 1. USA: Oxford university Press; 2014. p. 450-66.
16. Dorman S, Picard C, Lammas D, Heyne K, van Dissel J, Baretto R, Rosenzweig S, Newport M, Levin M, Roesler J, Kumararatne D, Casanova J, Holland S. Clinical features of dominant and recessive interferon gamma receptor 1 deficiencies. *Lancet*. 2004; 364:2113–21. [PubMed: 15589309]
17. Kong XF, Vogt G, Itan Y, Macura-Biegun A, Szaflarska A, Kowalczyk D, Chapgier A, Abhyankar A, Furthner D, Djambas Khayat C, Okada S, Bryant VL, Bogunovic D, Kreins A, Moncada-Vélez M, Migaud M, Al-Ajaji S, Al-Muhsen S, Holland SM, Abel L, Picard C, Chaussabel D, Bustamante J, Casanova JL, Boisson-Dupuis S. Haploinsufficiency at the human *IFNGR2* locus contributes to mycobacterial disease. *Hum Mol Genet*. 2013; 22:769–81. [PubMed: 23161749]
18. Moncada-Vélez M, Martínez-Barricarte R, Bogunovic D, Kong XF, Blancas-Galicia L, Tirpan C, Aksu G, Vincent QB, Boisson B, Itan Y, Ramírez-Alejo N, Okada S, Kreins AY, Bryant VL, Franco JL, Migaud M, Espinosa-Padilla S, Yamazaki-Nakashimada M, Espinosa-Rosales F, Kutukculer N, Abel L, Bustamante J, Vogt G, Casanova JL, Boisson-Dupuis S. Partial IFN- γ R2 deficiency is due to protein misfolding and can be rescued by inhibitors of glycosylation. *Blood*. 2013; 122:2390–14. [PubMed: 23963039]
19. Vogt G, Chapgier A, Yang K, Chuzhanova N, Feinberg J, Fieschi C, Boisson-Dupuis S, Alcais A, Filipe-Santos O, Bustamante J, de Beaucoudrey L, Al-Mohsen I, Al-Hajjar S, Al-Ghonaium A,

- Adimi P, Mirsaeidi M, Khalilzadeh S, Rosenzweig S, de la Calle Martin O, Bauer T, Puck J, Ochs H, Furthner D, Engelhorn C, Belohradsky B, Mansouri D, Holland S, Schreiber R, Abel L, Cooper D, Soudais C, Casanova J. Gains of glycosylation comprise an unexpectedly large group of pathogenic mutations. *Nat Genet.* 2005; 37:692–700. [PubMed: 15924140]
20. Vogt G, Bustamante J, Chapgier A, Feinberg J, Boisson Dupuis S, Picard C, Mahlaoui N, Gineau L, Alcaïs A, Lamaze C, Puck JM, de Saint Basile G, Khayat CD, Mikhael R, Casanova JL. Complementation of a pathogenic IFNGR2 misfolding mutation with modifiers of N-glycosylation. *J Exp Med.* 2008; 205:1729–37. [PubMed: 18625743]
21. Toyoda H, Ido M, Nakanishi K, Nakano T, Kamiya H, Matsumine A, Uchida A, Mizutani H, de Beaucoudrey L, Vogt G, Boisson-Dupuis S, Bustamante J, Casanova JL, Komada Y. Multiple cutaneous squamous cell carcinomas in a patient with interferon γ receptor 2 (IFN γ R2) deficiency. *J Med Genet.* 2010; 47:631–4. [PubMed: 20587411]
22. Rosenzweig SD, Dorman SE, Uzel G, Shaw S, Scurlock A, Brown MR, Buckley RH, Holland SM. A novel mutation in IFN- γ receptor 2 with dominant negative activity: biological consequences of homozygous and heterozygous states. *J Immunol.* 2004; 173:4000–8. [PubMed: 15356149]
23. Döflinger R, Jouanguy E, Dupuis S, Fondanèche MC, Stephan JL, Emile JF, Lamhamedi-Cherradi S, Altare F, Pallier A, Barcenas-Morales G, Meinel E, Krause C, Pestka S, Schreiber RD, Novelli F, Casanova JL. Partial interferon- γ receptor signaling chain deficiency in a patient with Bacille Calmette-Guérin and *Mycobacterium abscessus* Infection. *J Infect Dis.* 2000; 181:379–84. [PubMed: 10608793]
24. Kilic SS, van Wengen A, de Paus RA, Celebi S, Meziane B, Hafizoglu D, van Dissel JT, van de Vosse E. Severe disseminated mycobacterial infection in a boy with a novel mutation leading to IFN- γ R2 deficiency. *J Infect.* 2012; 65:568–72. [PubMed: 22902943]
25. Dorman S, Holland S. Mutation in the signal-transducing chain of the interferon-gamma receptor and susceptibility to mycobacterial infection. *J Clin Invest.* 1998; 101:2364–9. [PubMed: 9616207]
26. Byun M, Abhyankar A, Lelarge V, Plancoulaine S, Palanduz A, Telhan L, Boisson B, Picard C, Dewell S, Zhao C, Jouanguy E, Feske S, Abel L, Casanova JL. Whole-exome sequencing-based discovery of STIM1 deficiency in a child with fatal classic Kaposi sarcoma. *J Exp Med.* 2010; 207:2307–12. [PubMed: 20876309]
27. Itan Y, Zhang SY, Vogt G, Abhyankar A, Herman M, Nitschke P, Fried D, Quintana-Murci L, Abel L, Casanova JL. The human gene connectome as a map of short cuts for morbid allele discovery. *Proc Natl Acad Sci USA.* 2013; 110:5558–63. [PubMed: 23509278]
28. Fischer M, Goldschmitt J, Peschel C, Brakenhoff JP, Kallen KJ, Wollmer A, Grötzinger J, R-J S. A bioactive designer cytokine for human hematopoietic progenitor cell expansion. *Nat Biotechnol.* 1997; 15:142–5. [PubMed: 9035138]
29. Vitoria M, González-Domínguez M, Salvo S, Crusells M, Letona S, Samper S, Sanjoaquin I. *Mycobacterium simiae* pulmonary infection unmasked during immune reconstitution in an HIV patient. *Diagn Microbiol Infect Dis.* 2013; 75:101–3. [PubMed: 23040511]
30. Narang R, Narang P, Jain AP, Mendiratta DK, Joshi R, Lavania M, Das R, Katoch VM. Disseminated disease caused by *Mycobacterium simiae* in AIDS patients: a report of three cases. *Clin Microbiol Infect.* 2010; 16:912–4. [PubMed: 19694759]
31. Cortés-Torres N, González-Y-Merchand J, González-Bonilla C, García-Elorriaga G. Molecular analysis of mycobacteria isolated in Mexican patients with different immunodeficiencies in a tertiary care hospital. *Arch Med Res.* 2013; 44:562–9. [PubMed: 24054995]
32. Balkis M, Kattar M, Araj G, Kanj S. Fatal disseminated *Mycobacterium simiae* infection in a non-HIV patient. *Int J Infect Dis.* 2009; 13:e286–e7. [PubMed: 19155183]
33. Alcaïs A, Quintana-Murci L, Thaler DS, Schurr E, Abel L, Casanova JL. Life-threatening infectious diseases of childhood: single-gene inborn errors of immunity? *Ann N Y Acad Sci.* 2010; 1214:18–33. [PubMed: 21091717]

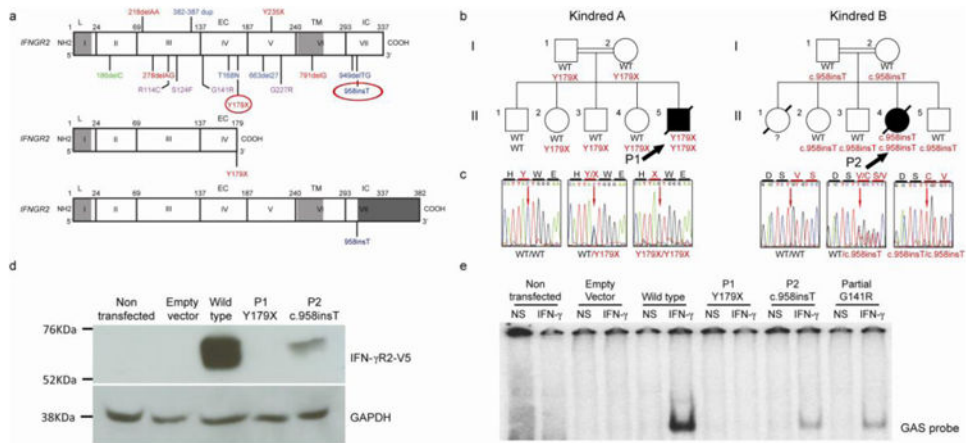


Fig. 1. Loss-of-function *IFNGR2* alleles associated with MSMD

- a) Schematic representation of the human *IFNGR2* gene and corresponding protein with all previously described MSMD-associated mutations: in blue, mutations causing AR complete IFN- γ R2 deficiency with detectable surface expression; in red, AR IFN- γ R2 deficiency with no receptor expression; in purple, AR partial IFN- γ R2 deficiency, and in green, AD IFN- γ R2 deficiency. The different domains of the protein are indicated as L (leader peptide), EC (extracellular domain), TM (transmembrane domain) and IC (intracellular domain). Below this diagram, the consequences of the two mutations described here are shown: in the middle panel, a short IFN- γ R2 caused by the creation of a premature stop codon (Y179X) and at the bottom, a longer predicted protein caused by the c.958insT variant. The extra portion of the protein due to the frame shift is indicated at dark gray at the end of the diagram.
- b) Familial segregation of the two mutations (Y179X and c.958insT) found in *IFNGR2*. The index case (P1 and P2) of each pedigree is indicated with solid symbols and an arrow. Each kindred is designated by a capital letter (A-B), and each generation by a Roman numeral (I-II).
- c) Electropherograms of a wild-type homozygous individual, a heterozygous carrier and a homozygous carrier are shown in this panel, in which the position of the mutant form is indicated with an arrow.
- d) Overexpression of the WT and mutant alleles of *IFNGR2* in IFN- γ R2-deficient SV40-fibroblasts, revealing a lack of expression of Y179X and the residual expression of 958insT. The results presented are from one experiment representative of the three independent experiments carried out.
- e) EMSA was carried out after IFN- γ stimulation of the same transfected cells as in D. A complete absence of DNA binding was observed for the nonsense mutation. The frameshift insertion showed a partial DNA binding, which was comparable to a previously reported partial deficient mutation. The results shown are representative of five independent experiments.

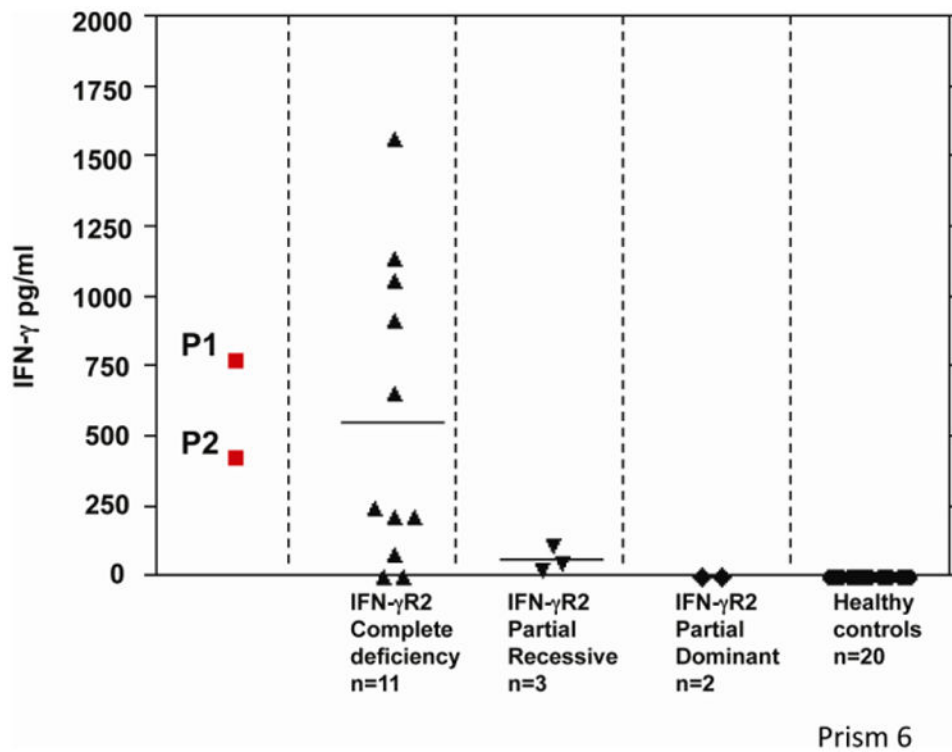


Fig. 2. Plasma IFN- γ concentration

Plasma IFN- γ concentrations of the patients carrying the reported mutations. These concentrations are higher than those in healthy controls. The graph shows IFN- γ concentrations for the different forms of IFN- γ R2 deficiency. The values obtained for these two patients (P1, P2) are similar to those reported for other patients with AR IFN- γ R2 deficiency.