



**HAL**  
open science

## Hydrochlorothiazide-induced hepatotoxicity: A rare case of DILI

Emilie Malézieux, Lucy Meunier, Benjamin Rivière, Dominique Larrey

### ► To cite this version:

Emilie Malézieux, Lucy Meunier, Benjamin Rivière, Dominique Larrey. Hydrochlorothiazide-induced hepatotoxicity: A rare case of DILI. *Clinics and Research in Hepatology and Gastroenterology*, 2021, 45 (5), pp.101599. 10.1016/j.clinre.2020.101599 . hal-03672923

**HAL Id: hal-03672923**

**<https://hal.science/hal-03672923v1>**

Submitted on 10 Mar 2023

**HAL** is a multi-disciplinary open access archive for the deposit and dissemination of scientific research documents, whether they are published or not. The documents may come from teaching and research institutions in France or abroad, or from public or private research centers.

L'archive ouverte pluridisciplinaire **HAL**, est destinée au dépôt et à la diffusion de documents scientifiques de niveau recherche, publiés ou non, émanant des établissements d'enseignement et de recherche français ou étrangers, des laboratoires publics ou privés.



Distributed under a Creative Commons Attribution - NonCommercial 4.0 International License

## **Hydrochlorothiazide-induced hepatotoxicity: a rare case of DILI**

**Emilie Malézieux<sup>1</sup>, Lucy Meunier<sup>1</sup>, Benjamin Rivière<sup>2</sup>, Dominique Larrey<sup>1</sup>**

<sup>1</sup> Liver and Transplantation Unit, St-Eloi University Hospital, Montpellier, France

<sup>2</sup> Department of Pathology, St-Eloi University Hospital, Montpellier, France.

### **Corresponding address:**

Lucy MEUNIER

Liver and Transplantation Unit,

St-Eloi University Hospital

80 rue Augustin Fliche

34295 MONTPELLIER Cedex 5

France

Tel: 00 33 4 67 33 02 24

Fax: 00 33 4 67 33 69 42

Email: [lucy.meunier@chu-montpellier.fr](mailto:lucy.meunier@chu-montpellier.fr)

**No conflict of interest**

**No financial support**

**Authors contributions: Emilie Malezieux, Lucy Meunier, Benjamin Riviere and Dominique Larrey:** manuscript preparation, comments and review. All authors approved the manuscript.

**Running title: Hydrochlorothiazide-induced hepatotoxicity**

**Body of the text: 885 words**

**Reference: 227 words**

**Figures and tables: 2 figures, 1 table**

**List of abbreviation:**

DILI: drug-induced liver injury

BMI: body mass index

ALT: serum alanine aminotransferase

AST: serum aspartate Aminotransferase

GGT: gammaglutamyl transferase

ALP: alkaline phosphatase

HAV: hepatitis A virus

HbsAg: hepatitis B virus antigen

Anti-Hbc: anti- hepatitis B virus core antibodies

HEV: hepatitis E virus

HIV: Human Immunodeficiency Virus

HCV: hepatitis C virus

CMV: cytomegalovirus

HSV: herpes simplex virus

RNA : ribonucleic acid

EBV: Epstein-Barr Virus

LKM1 : anti-liver-kidney-microsomal type 1

ASCA : Anti-Saccharomyces cerevisiae antibodies

ANCA : Anti-neutrophil cytoplasmic antibodies

MRI: Magnetic resonance imaging

**Abstract:**

Thiazide diuretics are prescribed daily and rarely hepatotoxic. We report the case of 86-year-old woman who was admitted in hospital for jaundice after taking hydrochlorothiazide. All differential diagnoses have been eliminated. The liver biopsy was compatible with drug-induced hepatitis. Clinical and biological manifestations improved after discontinuation of the treatment. The reported case is compared to three other cases in the literature.

**Keywords: hydrochlorothiazide, thiazide diuretics, acute hepatitis, hepatotoxicity, DILI**

## **Introduction**

Thiazide diuretics are drugs that are prescribed daily. This drug family includes several molecules: bendroflumethiazide, chlorothiazide, chlorthalidone, hydrochlorothiazide, indapamide, metolazone and polythiazide (1). Their main indication is the treatment of high blood pressure. The most prescribed subclass of thiazide is hydrochlorothiazide, either alone or in combination, since 1997. The main side effects of thiazidics include vertigo, headache, paresthesia, nausea, vomiting, diarrhea, and hypokalemia. Several cases of acute cholecystitis and pancreatitis have been reported (2). Very few cases of hepatotoxicity have been reported (3–5). We report herein a case of acute hepatitis attributed to hydrochlorothiazide.

## **Case presentation**

An 86-year-old woman was admitted to the hospital for jaundice, asthenia, weight loss and pruritus after taking hydrochlorothiazide orally (25 mg daily) since 4 weeks for high blood pressure. The treatment has been initially interrupted because of syncopal episodes. She claimed not to have used herbal medicines, illicit substances, or of being exposed to harmful chemicals or industrial products. She had history of peritonitis on strangulated inguinal hernia and appendicitis, no prior history of excessive alcohol consumption, or drug addiction. There were no prior symptoms suggestive of a history of autoimmunity or of drug-induced liver injury (DILI), nor history of disturbed liver tests. There is no past familial history of autoimmunity.

Clinical examination was normal, apart from jaundice. There was no hepatomegaly or splenomegaly. BMI was 23.2 kg/m<sup>2</sup>. The results of liver tests are presented in **Figure 1**: serum aspartate aminotransferase (AST) was 263 IU/L (N<32), serum aminotransferase level (ALT) was 633 IU/L (N<33), serum gamma-glutamyl transpeptidase (GGT) was 261 IU/L (N<40), serum alkaline phosphatase (ALP) was 419 IU/L (N 35-105), total bilirubin 72 µmol/L (N<21), and conjugated bilirubin 61 µmol/L (N<5), the prothrombin time was 10 seconds (100%), factor V was normal, and serum albumin level was 40 g/L (N 35-52). There was no blood hypereosinophilia. Viral screening was negative for the following: serum anti-HAV IgM, HbsAg, anti-Hbc IgM, anti-HEV IgM, HIV antibodies, anti-HCV, anti-CMV IgM, anti-HSV IgM, HCV RNA, HEV RNA, EBV RNA. However, screening was positive for anti-CMV IgG and HSV-IgG. Serum total gammaglobulin level was 10 g/L (N 6.9-14g/L). Tests for auto-antibodies were positive for anti-nuclear antibodies (1/640) but negative for anti-smooth muscle, anti-LKM1, anti-cytosol, anti-mitochondrial, anti-

ASCA and anti-ANCA antibodies. Abdominal CT scan and abdominal ultrasound examinations showed a liver of normal size and morphology, without splenomegaly or biliary tract abnormalities (**Figure 2a**). A MRI of the bile ducts found showed no sign of cholangitis.

A liver biopsy was performed and histological examination showed some portal inflammatory associated with biliary dystrophies, some cholangitis foci, lobular canalicular cholestasis lesions (**Figure 2b**). Few eosinophilic polynuclear cells were observed. These lesions were suggestive of a DILI.

After drug discontinuation, clinical manifestations disappeared quickly and liver tests returned progressively to normal except mild persisting elevation of ALP and GGT (**Figure 1**).

## Discussion

This is a serious case of acute hepatocellular hepatitis associated with cholangitis documented by liver biopsy. Severity was moderate without signs of liver failure according to revisited international definitions (6).

The diagnosis of hydrochlorothiazide-induced acute hepatitis is supported by the following arguments: occurrence of hepatic injury 4 weeks after the exposure to hydrochlorothiazide; clinical and biological improvement observed after drug discontinuation; elimination of other causes of acute hepatitis; liver biopsy suggestive of DILI. The diagnosis is further supported by international causality assessment methods for DILI (DILIN Expert Opinion and RUCAM) classifying the role of hydrochlorothiazide as probable/highly probable (6–8).

Although hydrochlorothiazide is being used for more than 30 years, there are very few reported cases of hepatotoxicity (3–5) as detailed in **table 1**. Liver biopsy data are not available for all cases but there are clinical and biological similarities with a mixed pattern associating biological hepatocellular and cholestatic features. No cases of fulminant hepatitis, liver transplantation, or death secondary to hydrochlorothiazide have been reported. The scarcity of cases of liver injury with hydrochlorothiazide and the occurrence with recommended use, supports an idiosyncratic reaction. The presence of eosinophils in the inflammatory infiltration revealed by the liver biopsy suggests the role of an immune mechanism. Hydrochlorothiazide is the only diuretic in this class for which cases of hepatotoxicity are described. No cases are reported for other thiazide diuretics.

Thiazide diuretics have been frequently prescribed treatments for decades without report of liver injury. This case of acute hepatitis illustrates that its role should not be dismissed in cases of liver injury occurring after polymedications only on the basis of the liver safety reputation. It underlines that in case of drug-induced hepatitis, the causality of all drugs should be discussed, even if the apparent risk is low compared to other treatments.

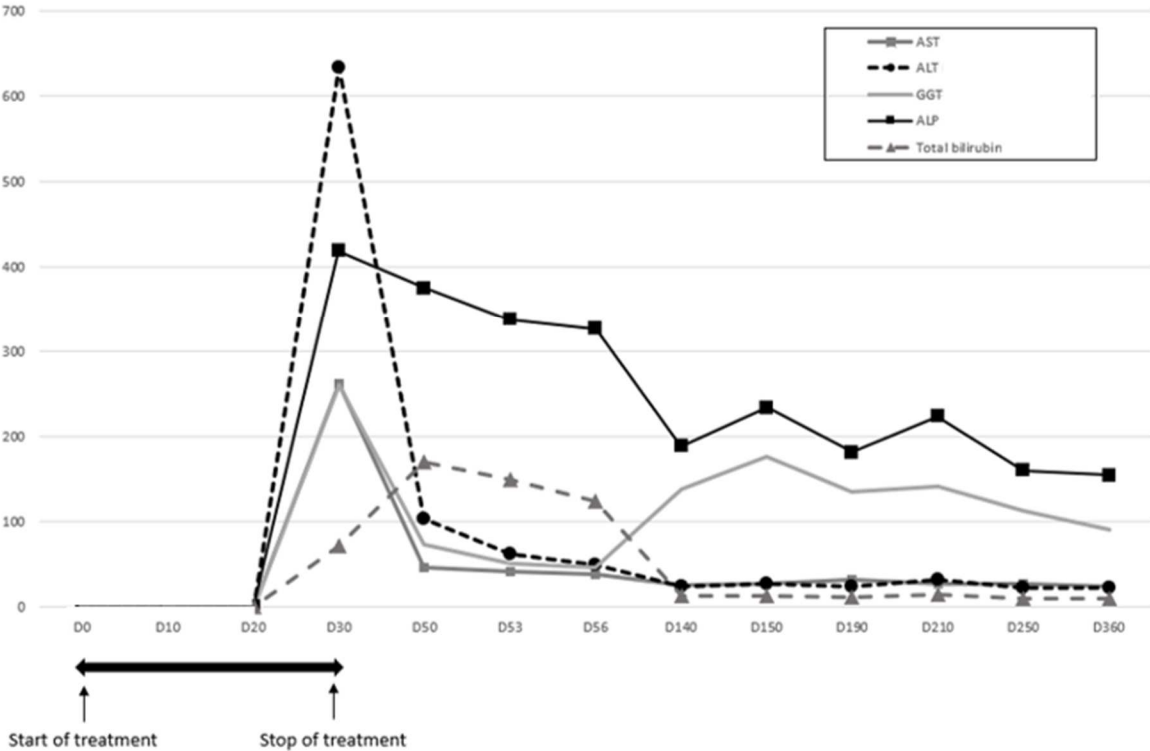
## Conclusion

Despite a reputation of innocuous drug to the liver for decades, this case supports that hydrochlorothiazide can cause acute hepatitis and cholangitis. Its role should be considered in cases of liver injury after exposure to polymedications or in case of unexplained liver injury.

## References

1. Diuretics. In: LiverTox: Clinical and Research Information on Drug-Induced Liver Injury Bethesda (MD): National Institute of Diabetes and Digestive and Kidney Diseases; 2012
2. Van der Linden W, Ritter B, Edlund G. Acute cholecystitis and thiazides. *Br Med J (Clin Res Ed)*. 15 sept 1984;289(6446):654-5.
3. Arinzon Z. Hydrochlorothiazide induced hepato-cholestatic liver injury. *Age and Ageing*. 1 sept 2004;33(5):509-10.
4. Taglietti F, Del Nonno F, Baiocchini A, Falasca L, Pieri S, Capone A, et al. Acute hepatocellular and cholestatic injury during therapy with hydrochlorothiazide - clinicohistopathologic findings: a case report. *J Med Case Reports*. déc 2010;4(1):332.
5. Lorena M, Autolitano A, Natale G, Uberti F, Vitali F, Schiantarelli C, et al. Letter to the Editor Telmisartan/hydrochlorothiazide-induced hepatotoxicity. *aoms*. 2015;4:893-4.
6. Andrade RJ, Aithal GP, Björnsson ES, Kaplowitz N, Kullak-Ublick GA, Larrey D, et al. EASL Clinical Practice Guidelines: Drug-induced liver injury. *Journal of Hepatology* 26 mars 2019 [
7. Aithal GP, Watkins PB, Andrade RJ, Larrey D, Molokhia M, Takikawa H, et al. Case definition and phenotype standardization in drug-induced liver injury. *Clin Pharmacol Ther*. juin 2011;89(6):806-15.
8. Fontana RJ, Seeff LB, Andrade RJ, Björnsson E, Day CP, Serrano J, et al. Standardization of nomenclature and causality assessment in drug-induced liver injury: summary of a clinical research workshop. *Hepatology*. août 2010;52(2):730-42.

**Figure 1 : Course of liver function tests**

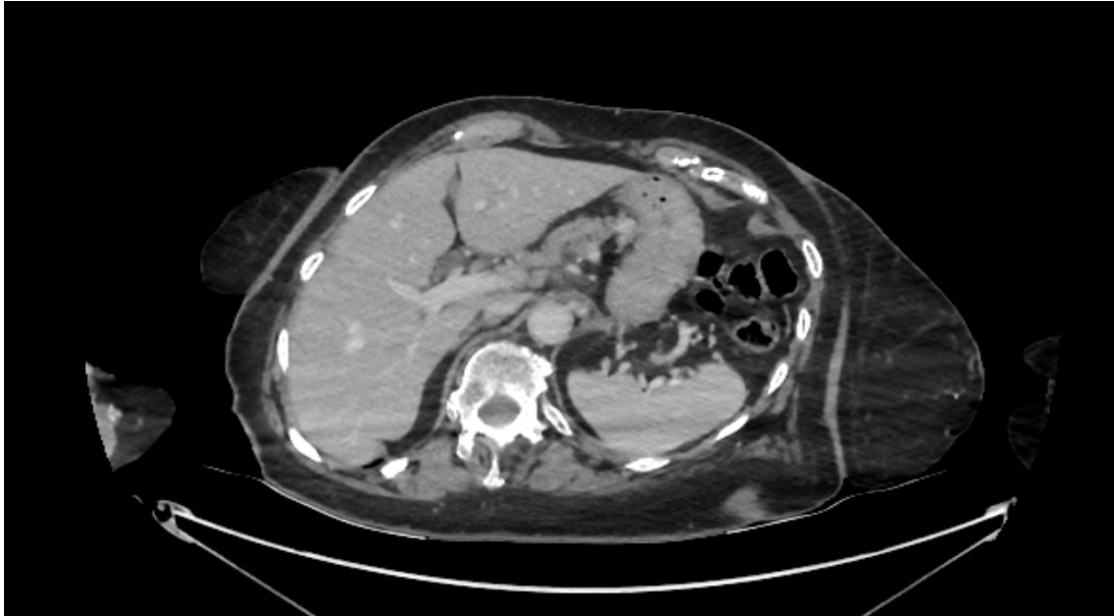


	D30	D50	D53	D56	D140	D150	D190	D210	D250	D360
—■— AST (IU/L)	263	47	42	38	26	28	32	27	27	25
-●- ALT (IU/L)	633	104	62	49	25	27	25	32	23	23
— GGT (IU/L)	261	73	52	47	139	176	136	142	113	91
—■— ALP (IU/L)	419	375	338	327	189	234	182	224	160	155
—▲— Total bilirubin (μmol/L)	72	171	150	125	13	13	11	15	10	10

ALT (serum alanin aminotransferase), N<32 IU/L; AST (serum aspartate aminotransferase) N<33 IU/L; GGT (gamma glutamyl transferase), N<40 IU/L; ALP (alkaline phosphatase), N 35-105 IU/L; Total bilirubin, N<5 μmol/L

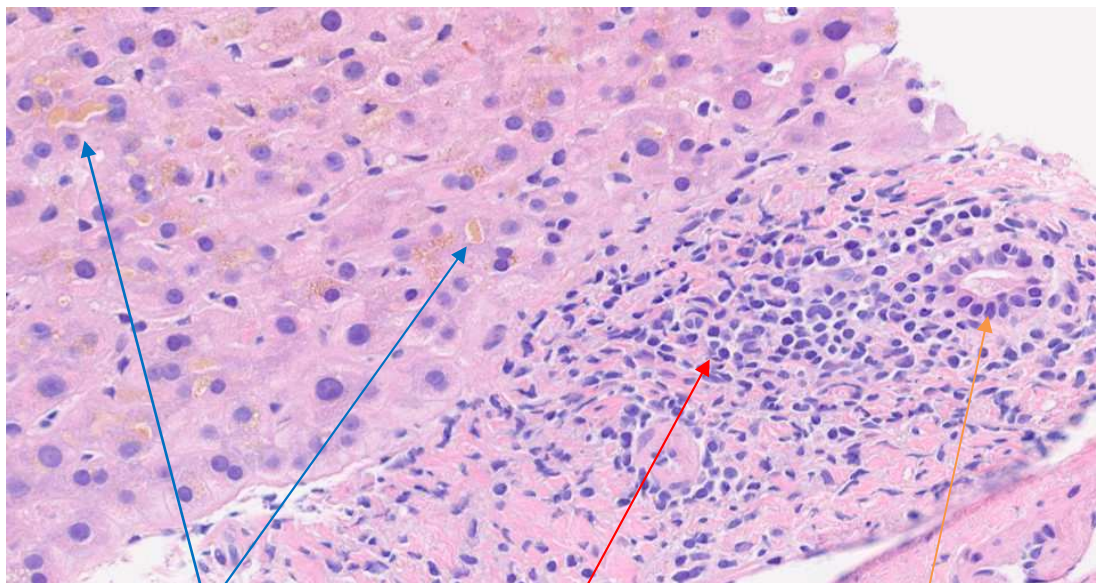
**Figure 2a: Abdominal CT scan**

Liver of normal size and morphology, without splenomegaly or biliary tract abnormalities



**Figure 2b: Liver biopsy**

*Portal inflammation with biliary dystrophies, lymphocytic cholangitis and canalicular bilirubinostasis (Hematoxylin Eosin x40)*



Canalicular bilirubinostasis

Portal inflammation

Lymphocytic cholangitis

**Table 1: Clinical cases of hydrochlorothiazide-induced hepatotoxicity published**

			Time to onset of				
--	--	--	------------------	--	--	--	--



Sex, age (years)	Clinical symptoms	Drugs	liver injury (days)	Liver tests	Outcome after discontinuation	Liver biopsy	Reference
F, 72	Anorexia, nausea, vomiting and pain in the right upper abdomen	HCTZ 25mg daily	6	AST 4N ALT 6N GGT 13N ALP 1,5N	Improvement after 3 days	Not done	Arinzon Z <i>et al.</i> (3)
M, 68	Jaundice, asthenia, nausea, vague right upper quadrant abdominal pain and hyperchromic urine.	HCTZ 12,5mg daily	20	AST 5N ALT 9N GGT 8N ALP 10N Total bilirubin 6N	Improvement after 22 days	Acute cholestatic hepatitis	Taglietti <i>et al.</i> (4)
F, 72	Weakness, anorexia, nausea, progressive jaundice, dark-coloured urine and pruritus	Telmisartan/ HCTZ	30	AST 1N ALT 3N GGT 15N ALP 2N Total bilirubin 5N	Improvement after 10 days	Mild mononuclear inflammatory infiltrates in portal tracts without hepatocyte necrosis	Lorena <i>et al.</i> (5)

*HCTZ : Hydrochlorothiazide*