



Somatic TEK variant with intraarticular venous malformation and knee hemarthrosis treated with rapamycin

Salma Adham, Nicole Revencu, Sandrine Mestre, Monira Nou-howaldt, H  l  ne
Vernhet-kovacsik, Isabelle Qu  r  

► To cite this version:

Salma Adham, Nicole Revencu, Sandrine Mestre, Monira Nou-howaldt, H  l  ne Vernhet-kovacsik, et al.. Somatic TEK variant with intraarticular venous malformation and knee hemarthrosis treated with rapamycin. Molecular Genetics & Genomic Medicine, In press, 10.1002/mgg3.1931 . hal-03671182

HAL Id: hal-03671182

<https://hal.science/hal-03671182>

Submitted on 26 May 2023

HAL is a multi-disciplinary open access archive for the deposit and dissemination of scientific research documents, whether they are published or not. The documents may come from teaching and research institutions in France or abroad, or from public or private research centers.

L'archive ouverte pluridisciplinaire **HAL**, est destinée au dépôt et à la diffusion de documents scientifiques de niveau recherche, publiés ou non, émanant des établissements d'enseignement et de recherche français ou étrangers, des laboratoires publics ou privés.



Distributed under a Creative Commons Attribution - NonCommercial - NoDerivatives 4.0 International License

1 | INTRODUCTION

Venous malformations (VMs) are the most common vascular anomalies leading to referral in specialized tertiary referral centers. VM have been associated with somatic variants not only in *PIK3CA* but also in *TEK* (OMIM 600221; NM 000459.5), the gene for the endothelial tyrosine kinase receptor TIE2 (Natynki et al., 2015). Both names (*TEK* and *TIE2*) are commonly used to refer to the protein.

Current treatment of VM joint component is based on surgical resection, orthopedic surgery, and/or sclerotherapy and might be challenging due to the size or location of some lesions or ineffective with recurrence of malformed veins (Spencer & Sorger, 2020). In these patients, targeted molecular therapies after identification of genetic defects might be an alternative (Boscolo et al., 2015).

We report for the first time to our knowledge a case with intraarticular bleeding due to VM with a pathogenic somatic variant in *TEK* treated as a first line with rapamycin. Informed written consent for publication was obtained from the patient.

2 | REPORT OF A CASE

A 26-year-old female patient was referred for assessment of a right inferior limb hypotrophy with cutaneous and adipose tissue atrophy and thigh amyotrophy confirmed on MRI and CT-scan. An epiphysiodesis of the left inferior leg was performed at the age of 13 to correct the asymmetry. She had superficial venous dysplasia of the right calf and thigh (Figure 1a–c) and wore compression

stockings. She also had a history of superficial and deep venous thrombosis (DVT) requiring anticoagulant therapy (VKA). There was no localized or disseminated intravascular coagulopathy under VKA treatment: hemoglobin 12.9 g/dl, hematocrit 37.3%, platelet count $244 \times 10^3/\mu\text{l}$, D-dimers $<0.2 \mu\text{g/ml}$, fibrinogen 360 mg/dl, APTT 1.31 and PT 23%. Molecular diagnosis on a cutaneous biopsy of the right thigh evidenced a pathogenic somatic *TEK* variant previously described (Limaye et al., 2009): c.2740C>T, p.Leu914Phe, allelic frequency 4.4%.

Her main complaint was right calf pain. MRA evidenced (i) multiple venous anomalies infiltrating the right inferior limb with multiple subcutaneous and intramuscular venous dilations (ii) no arterio-venous fistula (iii) intraarticular VM in the right knee, leading to identify hemarthrosis as the cause of her pain (Spencer & Sorger, 2020) (Figure 2a). VKA was replaced by LMWH at standard thromboprophylaxis dosing, but she came back a year later with pulmonary embolism and DVT requiring long-term full-dose anticoagulation with VKA.

She was lost to follow-up for 8 years and came back due to six episodes of hemarthrosis in the last 18 months. At that time, MRI evidenced degenerative chondropathy of the right knee. Due to the very high risk of venous thromboembolic event and the complexity of the VM, rapamycin was discussed as a first-line therapy instead of sclerotherapy to stop bleeding (Bessis et al., 2016). Tolerance was good with moderate oral aphthous. After 6 months of treatment (2 mg per day, drug level 4.6 ng/ml) she did not report any new hemarthrosis episode. The beneficence of rapamycin is still present after 2 years of treatment with unchanged dosage (drug level 7.3 ng/ml). Although there was no significant decrease in the

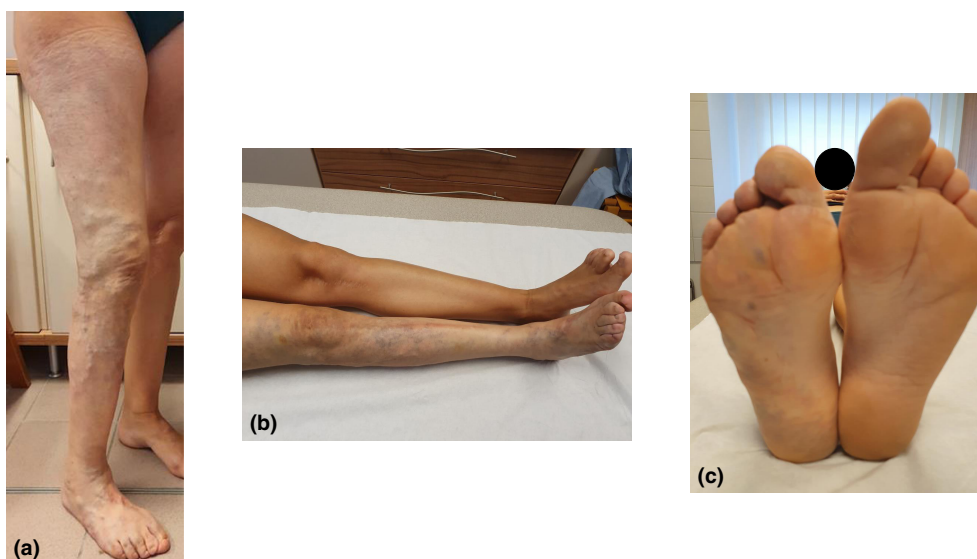


FIGURE 1 Clinical examination of the inferior limbs. (a) Superficial venous dysplasia of the right inferior limb. (b) Inferior limb asymmetry. (c) Foot asymmetry

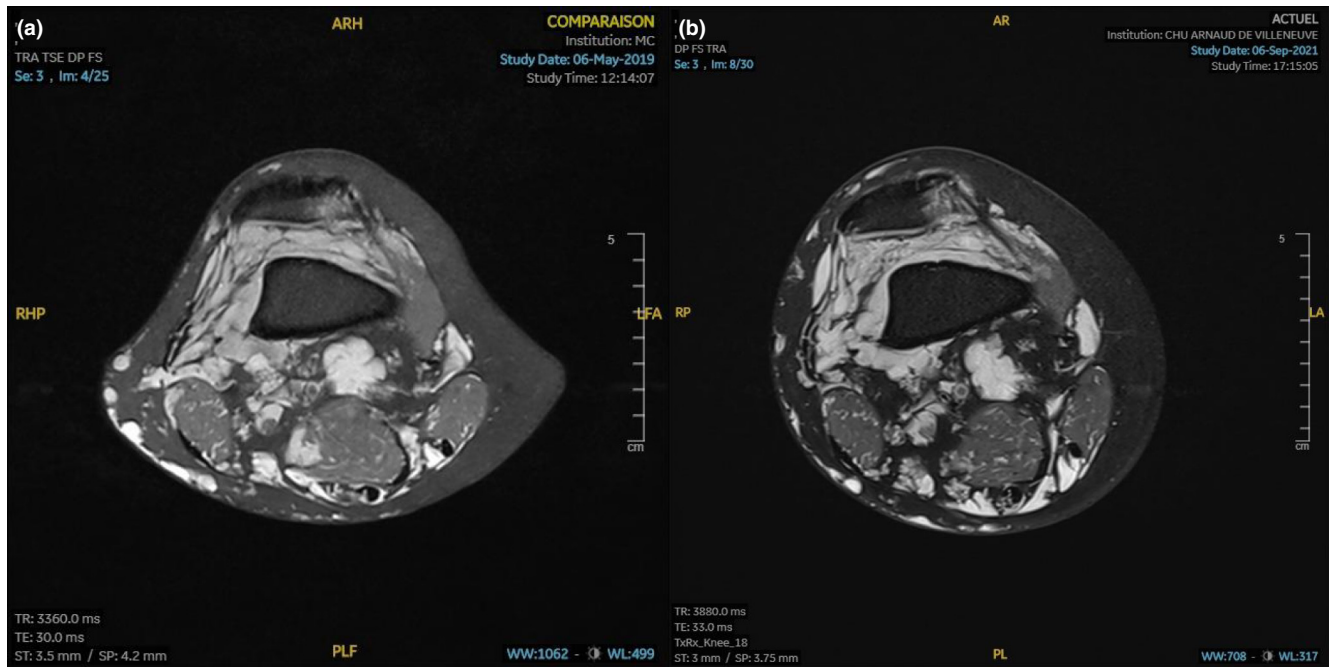


FIGURE 2 Intraarticular venous malformation of the right knee on PD-weighted (fat-saturated) MRI. (a) Before rapamycin treatment. (b) Two years after introduction of rapamycin. No major imaging change was evidenced as the intraarticular VM was still massively present but degenerative chondropathy did not worsen

intraarticular VM with similar biological results under anticoagulant therapy, degenerative chondropathy seemed stable (Figure 2b).

3 | DISCUSSION

Poor outcomes have been reported in diffuse limb VM with intraarticular involvement (Spencer & Sorger, 2020). In this case, repeated hemarthrosis due to intraarticular VM bleeding led to degenerative knee chondropathy. Intraarticular VM sclerotherapy is limited by the extent and architecture of the VM. Joint synovectomy or total joint arthroplasty are preferred for patients with localized disease (Spencer & Sorger, 2020). The TEK receptor signals through the PI3K/AKT/mTOR pathway and *TEK* mutations have been linked to AKT activation (Boscolo et al., 2015). Rapamycin acts against angiogenesis and reduces phosphorylated-AKT levels (Boscolo et al., 2015). Rapamycin has already been used on VM and has prevented bleeding in Klippel-Trenaunay syndrome and Blue Rubber Bleb Nevus syndrome (Bessis et al., 2016; Isoldi et al., 2019). Here, it provided rapid and effective control of intraarticular bleeding and pain in this patient with a pathogenic somatic *TEK* variant. Targeted molecular therapy should be discussed as first-line therapy in patients with proven molecular diagnosis and diffuse VM inaccessible to conventional treatment (Boscolo et al., 2015). As

this case reports the potential prevention of chondropathy by stopping bleeding, rapamycin in this indication should be studied in a larger study.

ACKNOWLEDGMENTS

None.

AUTHOR CONTRIBUTIONS

SA, NR, HVK, IQ: Have made substantial contributions to conception and design, or acquisition of data, or analysis and interpretation of data; SA, HVK, IQ: Been involved in drafting the manuscript or revising it critically for important intellectual content; NR, SM, MNH, HVK, IQ: Given final approval of the version to be published. Each author should have participated sufficiently in the work to take public responsibility for appropriate portions of the content; SA, NR, SM, MNH, HVK, IQ: Agreed to be accountable for all aspects of the work in ensuring that questions related to the accuracy or integrity of any part of the work are appropriately investigated and resolved.

CONFLICT OF INTEREST

None.

ETHICS STATEMENT

Free informed oral and written consent has been obtained from the patient and is available on request from the corresponding author.

DATA AVAILABILITY STATEMENT

Data available on request from the authors.

ORCID

Salma Adham  <https://orcid.org/0000-0003-2955-0922>

REFERENCES

- Bessis, D., Vernhet, H., Bigorre, M., Quere, I., & Rossler, J. (2016). Life-threatening cutaneous bleeding in childhood Klippel-Trenaunay syndrome treated with oral sirolimus. *JAMA Dermatology*, 152(9), 1058–1059.
- Boscolo, E., Limaye, N., Huang, L., Kang, K. T., Soblet, J., Uebelhoer, M., Mendola, A., Natynki, M., Seront, E., Dupont, S., Hammer, J., Legrand, C., Brugnara, C., Eklund, L., Vikkula, M., Bischoff, J., & Boon, L. M. (2015). Rapamycin improves TIE2-mutated venous malformation in murine model and human subjects. *The Journal of Clinical Investigation*, 125(9), 3491–3504.
- Isoldi, S., Belsha, D., Yeop, I., Uc, A., Zevit, N., Mamula, P., Loizides, A. M., Tabbers, M., Cameron, D., Day, A. S., Abu-el-Haija, M., Chongsrisawat, V., Briars, G., Lindley, K. J., Koeglmeier, J., Shah, N., Harper, J., Syed, S. B., & Thomson, M. (2019). Diagnosis and management of children with blue rubber bleb nevus syndrome: A multi-center case series. *Digestive and Liver Disease*, 51(11), 1537–1546.
- Limaye, N., Wouters, V., Uebelhoer, M., Tuominen, M., Wirkkala, R., Mulliken, J. B., Eklund, L., Boon, L. M., & Vikkula, M. (2009). Somatic mutations in angiopoietin receptor gene TEK cause solitary and multiple sporadic venous malformations. *Nature Genetics*, 41(1), 118–124.
- Nätyнки, M., Kangas, J., Miinalainen, I., Sormunen, R., Pietilä, R., Soblet, J., Boon, L. M., Vikkula, M., Limaye, N., & Eklund, L. (2015). Common and specific effects of TIE2 mutations causing venous malformations. *Human Molecular Genetics*, 24(22), 6374–6389.
- Spencer, S. A., & Sorger, J. I. (2020). Orthopedic issues in vascular anomalies. *Seminars in Pediatric Surgery*, 29(5), 150973.

How to cite this article: Adham, S., Revencu, N., Mestre, S., Nou-Howaldt, M., Vernhet-Kovacsik, H. & Quéré, I. (2022). Somatic *TEK* variant with intraarticular venous malformation and knee hemarthrosis treated with rapamycin. *Molecular Genetics & Genomic Medicine*, 10, e1931. <https://doi.org/10.1002/mgg3.1931>