



**HAL**  
open science

## **Anterior cranial fossa dural arteriovenous fistula: Transarterial embolization from the ophthalmic artery as first-line treatment**

Lorenzo Piergallini, Maxime Tardieu, Federico Cagnazzo, Grégory Gascou,  
Cyril Dargazanli, Imad Derraz, Vincent Costalat, Alain Bonafé, Pierre-Henri  
Lefevre

### ► To cite this version:

Lorenzo Piergallini, Maxime Tardieu, Federico Cagnazzo, Grégory Gascou, Cyril Dargazanli, et al.. Anterior cranial fossa dural arteriovenous fistula: Transarterial embolization from the ophthalmic artery as first-line treatment. *Journal de Neuroradiologie / Journal of Neuroradiology*, 2021, 48 (3), pp.207-214. 10.1016/j.neurad.2019.05.009 . hal-03651158

**HAL Id: hal-03651158**

**<https://hal.science/hal-03651158>**

Submitted on 9 May 2023

**HAL** is a multi-disciplinary open access archive for the deposit and dissemination of scientific research documents, whether they are published or not. The documents may come from teaching and research institutions in France or abroad, or from public or private research centers.

L'archive ouverte pluridisciplinaire **HAL**, est destinée au dépôt et à la diffusion de documents scientifiques de niveau recherche, publiés ou non, émanant des établissements d'enseignement et de recherche français ou étrangers, des laboratoires publics ou privés.



Distributed under a Creative Commons Attribution - NonCommercial 4.0 International License

# **Anterior cranial fossa dural arteriovenous fistula: transarterial embolization from the ophthalmic artery as first-line treatment**

Lorenzo Piergallini<sup>1,2</sup>, Maxime Tardieu<sup>3</sup>, Federico Cagnazzo<sup>1</sup>, Grégory Gascou<sup>1</sup>, Cyril Dargazanli<sup>1</sup>, Imad Derraz<sup>1</sup>, Vincent Costalat<sup>1</sup>, Alain Bonafé<sup>1</sup>, Pierre-Henri Lefevre<sup>1</sup>

<sup>1</sup> Department of Interventional and Diagnostic Neuroradiology, Montpellier University Hospital, Montpellier, France

<sup>2</sup> Postgraduation School of Radiodiagnosics, Università degli Studi di Milano, Milan, Italy

<sup>3</sup> Department of Radiology, Perpignan Hospital, Perpignan, France

## Corresponding author:

Pierre-Henri Lefevre

ph.lefevre30@gmail.com

Service de Neuroradiologie interventionnelle et diagnostique

CHU de Montpellier, Hôpital Gui de Chauliac

80 avenue Augustin Fliche

34295 Montpellier

France

## **Acknowledgments**

The authors wish to thank Ms Elisabetta Andermarcher for her contribution to the english revision.

## **Competing Interests**

PHL, GG, VC and AB report personal fees from Medtronic outside the submitted work

## **Funding**

This research received no specific grant from any funding agency in the public, commercial or not-for-profit sectors

### **Contributorship**

PHL, LP and AB : Conceptualization

MT, LP, PHL, FC and AB : Data curation

CD, ID, VC and PHL, LP Formal analysis

GG, AB and VC : Funding acquisition

MT, PHL, FC, LP and AB Investigation

AB, LP and PHL : Methodology and Project administration

AB and PHL : Supervision

ID, CD, VC, MT and GG : Validation and Visualization

LP, FC, AB and PHL : Writing – original draft

LP and PHL : Writing – review & editing

# **Anterior cranial fossa dural arteriovenous fistula: transarterial embolization from the ophthalmic artery as first-line treatment**

## **ABSTRACT**

**Objective:** To retrospectively review the outcome of patients with dural arteriovenous fistula of the anterior cranial fossa (afDAVF) treated by transarterial embolization.

**Material and Methods:** Six consecutive patients were referred to our hospital for afDAVF treatment. After a multidisciplinary discussion, they underwent endovascular embolization with Onyx injection through the ophthalmic artery. Their clinical presentation, management and outcomes were retrospectively assessed.

**Results:** All interventions were performed with the liquid embolic agent Onyx through the transarterial route from the ophthalmic artery to access the fistulous point. All patients showed a good outcome with complete afDAVF obliteration.

**Conclusion:** This study demonstrates that afDAVFs can be safely and completely obliterated by transarterial embolization via the ophthalmic artery.

**Key words:** Dural Arteriovenous Fistula, Endovascular therapy, Embolization, Intracranial Hemorrhage, Skull Base

## **TEXT**

### **Introduction**

Anterior cranial fossa dural arteriovenous fistula (afDAVF) is a rare entity (about 10% of all DAVFs), but with a very aggressive behavior, and a high rate (90%) of hemorrhagic presentation [1, 2]. The significant bleeding risk of these lesions is likely to be related to their angio-architecture. Indeed, it is thought that 90% of afDAVFs display a direct leptomeningeal retrograde vein drainage (Borden type III [3], Cognard type III [4]) that in many cases is associated with venous ectasia (Cognard type IV) [5].

Historically, surgery has been considered the treatment of choice for afDAVFs, because the results of endovascular treatment were poor in terms of cure rates and with high risk of vision damage [6]. However, in recent years, the endovascular approach has been used successfully as first-line treatment due to the major improvement of digital subtraction angiography (DSA) image quality, which allowed a thorough comprehension of the lesion anatomy, as well as the development of soft, hydrophilic-coated microcatheters that can be advanced very distally and of non-adhesive liquid embolic agents [7, 8, 9, 10, 11, 12, 13, 14, 15].

Here, we present the retrospective analysis of six consecutive patients with afDAVFs who underwent endovascular treatment via the ophthalmic artery at a single center.

### **Material and methods**

In 2006, a prospective registry for patients with afDAVF was established at the Montpellier University Hospital Center from which clinical data were retrospectively retrieved and analyzed in this study. From 2006 to 2018, six patients with afDAVF were included in the registry. After multidisciplinary discussion, endovascular treatment of the afDAVF was proposed and accepted by all six patients.

All patients underwent six-vessel DSA to visualize the fistula anatomy and plan a treatment strategy. The post-treatment follow-up included a clinical examination, DSA and MRI at six months and one year, and a visit and MRI at two years. In the absence of signs of residual fistula or symptoms, imaging follow-up was stopped after two years.

The patients' characteristics and the afDAVF description (arterial supply, venous drainage and Cognard classification) were extracted from the registry, as well as the presentation symptoms.

The treatment outcome [based on the modified Rankin Scale (mRS)], the need for additional interventions, and the patients' clinical status at each follow-up visit were also collected. Poor outcome was defined by a mRS score  $\geq 3$ .

Due to the retrospective nature of this study, the requirement for informed patient consent was waived by the Ethics Committee of our Institution.

## **Literature review**

As afDAVs represent a rare pathology and there are no robust data about the efficacy and safety of endovascular treatment of such lesions, a literature review was performed.

A systematic review of PubMed using the keywords "dural arteriovenous fistula" and "anterior fossa" or "ethmoidal" was performed in the month of April 2019, searching for series of endovascular treatment of anterior fossa DAVFs. In addition, the references of the articles were scrutinized for additional publications on the subject. When the published endovascular series included also surgery, the surgical results are also presented. The results are shown in Table 2.

The endovascular treatment of afDAVFs has recently been the object of a meta-analysis, although some series were not taken into consideration [16].

## **Results**

From January 2006 to June 2018 six patients with afDAVF (five men and one woman; median age: 60 years, range 23-74 years) underwent endovascular treatment at our institution. All patients were functionally independent at the time of diagnosis, with a mRS score = 0. The median follow-up was 19,5 months (range 6 - 108 months).

### *Clinical presentation*

Two patients presented with hemorrhage: one with a frontal lobe intraparenchymal hematoma with subdural extension, and the other patient with diffuse sub-arachnoid hemorrhage. These two patients reported strong headaches as the main symptom. Only one patient had a pulsatile tinnitus (Figure 1).

The patients' characteristics are summarized in Table 1.

### *Arterial supply*

DSA image analysis highlighted the bilateral contribution by the ethmoidal arterial branches of the ophthalmic arteries in all patients. Other minor arterial contributions came from the internal maxillary artery through the sphenopalatine arteries (n=3 patients), from the middle meningeal artery (n=2 patients), from the anterior meningeal artery (n=1 patient), and from the superficial temporal artery (n=1 patient).

### *Venous drainage*

The afDAVFs drained directly into one (n=4 patients), or two (n=1) cortical veins that displayed venous ectasia (Cognard type IV) (Table 1). One patient presented a triple venous drainage through a fronto-polar vein directed to the superior sagittal sinus, an olfactory vein to the cavernous sinus, and through the basal vein of Rosenthal as shown in figure 1.

### *Treatment - Case series*

Five patients were referred for endovascular embolization as first-line treatment after a multidisciplinary discussion. One patient underwent surgery as first-line treatment, with unilateral trans-orbital ligation of the ethmoidal arteries (Figure 2). As the post-surgery DSA showed that the fistula was unchanged, the patient was referred for endovascular treatment.

After one failed attempt to reach the fistulous point in the first patient through the venous route, which was complicated by a small subdural hematoma due to a micro-perforation, the transarterial approach from the ophthalmic artery was preferred for all patients. Specifically, the fistula was reached through the largest ethmoidal branch of the ophthalmic artery. In all six patients, the liquid embolic agent Onyx 18 (Medtronic, Irvine, USA) was used.

In two patients, a balloon catheter (Hyperform, Medtronic, Irvine, USA; or Eclipse, Balt, Montmorency, France) was inflated in the internal carotid artery immediately distally to the ophthalmic artery origin to provide support for the selective microcatheterization of the ophthalmic artery [14] (Figures 2 and 3). This was performed using a DMSO-compatible, distal detachable tip Sonic microcatheter (Balt, Montmorency, France), a Duo microcatheter (Microvention, Tustin, USA) or a Marathon microcatheter (Medtronic, Irvine, USA).

In four patients it was possible to reach a very distal position with the microcatheter, immediately before the fistulous point, in the first intervention. From there, the distal part of the feeding branch was occluded, as well as the fistulous point and the first part of the draining vein, causing the fistula immediate occlusion. In two patients, a bilateral approach through both ophthalmic arteries was required because the first attempt had resulted only in the proximal occlusion of the ethmoidal feeders. The second treatment was performed in one patient one month after the first intervention (Figure 4), and in the second patient (Figure 3) during the same intervention (this patient presented with acute intraparenchymal hemorrhage). The bilateral approach allowed the definitive occlusion of the afDAVF in both patients.

### *Outcomes*



Transarterial embolization was successful, with complete obliteration of the fistula in all six patients and full recovery (mRS = 0 at 6 months post-intervention). At the 2-year follow-up visit, only one patient still reported rare episodes of seizures, the initial symptom that led to the afDAVF diagnosis. No patient reported visual problems.

## **Discussion**

### *Natural history*

Our six patients with afDAVF were predominantly men, and only one patient was younger than 40 years of age. The latter had a history of severe head injury, which has been associated with dural fistula development [30]. The age of presentation is concordant with previous series [9, 17], with most of patients in their fifth to seventh decade of life.

In an historical paper, all cases of DAVFs with aggressive neurological symptoms, including hemorrhages, were associated with cortical vein reflux, galenic venous drainage, or venous ectasia [5]. In the anterior cranial fossa, where there is no dural sinus, bleeding events could be related to the engorgement of fragile, enlarged pial veins in the frontal sulci, and to the presence of some degree of venous ectasia in most patients [6]. However, the contribution of venous ectasia to the hemorrhagic risk in patients with afDAVF is still a matter of debate. Previous reports could not show any significant correlation between hemorrhagic presentation and venous ectasia [9, 27]. In agreement, in our series, the two patients with intracranial hemorrhage at diagnosis did not present any specific angiographic feature compared with patients with non-hemorrhagic presentation. However, the association between venous ectasia and hemorrhages might have not been detected due to the insufficient statistical power of the existing studies linked to the very small number of included patients.

### *Ophthalmic artery access: feasibility, efficacy and risk*

In all patients, transarterial embolization was performed through the largest ethmoidal branch of the ophthalmic artery. Targeting the arterial route with the highest flow (instead of a secondary arterial supply, such as the sphenopalatine arteries or the middle meningeal artery) can provide a higher pressure by the blood flow to the liquid embolic agent towards the point of fistula, and thus increase the chances of reaching and occluding the origin of the draining vein for long-lasting cure. The 100% success rate of endovascular embolization through the ophthalmic artery in our patients is the highest value amongst the published series (Table 2). On the other hand, the success rate of afDAVF embolization through secondary arterial suppliers is very low (0% in some series) [6, 18]. No case of visual loss due to vasospasm or ophthalmic artery injury during microcatheterization has been reported so far. Only one case of visual loss, who partially recovered, caused by the rupture of the microcatheter and proximal Onyx reflux was reported [29]. Nevertheless, the risk of visual problems was minimized by the clear identification in all patients of the origin of the posterior ciliary arteries, from which the central retinal artery originates in more than 60% of the cases, or the origin of the central retinal artery itself [32], and the corresponding bony landmarks on the lateral projection (*Figure 1*). In all patients, Onyx reflux never progressed beyond the distal third of the ophthalmic artery. This could lead to a very small risk of visual damage because the central retinal artery originates from this portion in 1.9% of individuals [32].

Although it has been reported that in some cases the ophthalmic artery is inaccessible to microcatheterization [8, 9], it could be easily accessed in all our patients. Considering the low number of patients of our series and the great anatomical variability (accentuated by the possible ophthalmic artery dilation due to the fistulous shunt), this result can hardly be generalized, and some ophthalmic arteries may be truly inaccessible. Nonetheless, we can hypothesize that when the shunting flow of the fistula is higher, it might be easier to access the ophthalmic artery due to the consequent enlargement. Currently it is difficult to predict the need of a balloon catheter for accessing the ophthalmic artery on the basis of pre-intervention DSA images alone. Moreover, the

frequent bilateral ophthalmic artery supply to the afDAVF allowed the successful access from the contralateral side, when required.

A liquid embolic agent (Onyx) was employed in all cases, because it was thought that transarterial embolization with glue might carry a higher risk of occlusion of the microcatheter and also of the proximal small ethmoidal feeders, and consequently of not reaching the fistula [8, 10]. Nevertheless, good outcomes have been obtained with this embolic agent, although the success rate with glue is associated with high inter-operator variability [9].

#### *Other treatment options: embolization via the venous route and surgery*

After the first case in 2009, where an attempt to pass through the venous route was unsuccessful and a micro-perforation caused a subdural hematoma, it was decided to avoid the venous access due to the perceived higher risk of rupture of fragile and enlarged cortical veins. This was confirmed by other reports of venous perforations [33, 34, 35]. The second reason to avoid the venous route was the intrinsic difficulties often encountered to reach the point of fistula, due to thrombosed or stenotic sinuses, the arduous access to cortical veins from the superior sagittal sinus and the very tortuous cortical vein anatomy in some patients.

In 1999, Lawton and colleagues [6] proposed that surgery, and not endovascular treatment, should be the preferred first-line treatment for afDAVFs for two reasons: i) the arterial contribution to these fistulas is usually only from the ICA, with an associated risk of embolization of the retinal artery, and ii) the tortuosity of the ophthalmic artery ethmoidal branches that usually supply the fistula.

Concerning the first issue, our results show that nowadays it is possible to identify very clearly the posterior ciliary arteries on DSA images (*Figure 1*), and that DMSO-compatible microcatheters can arrive very close to the fistulous point. A meticulous choice of the branch to embolize and the careful injection of the embolic liquid agent under adequate fluoroscopic guidance, with previously established safety landmarks for the reflux obviated the issue of reflux into the central retinal artery.

Although no patient reported any ocular symptom (specific questions were asked at each follow-up visit), one limitation of the present study is the absence of formal ophthalmological evaluation before and after the treatment.

The second issue concerning the tortuosity of the vessels going to the fistula can be addressed by the recent availability of liquid embolic agents that can penetrate the small ethmoidal vessels when they traverse the cribriform plate and reach the fistulous point, as successfully done in all six patients. Even with an accidental proximal occlusion of the ophthalmic artery ethmoidal branches, the arterial supply to the fistula from both ophthalmic arteries in most patients allowed the safe and successful embolization from the contralateral ophthalmic artery in the case of a first attempt failure from one side (*Figure 3*).

## **Conclusion**

AfDAVFs are a rare disease with high reported rates of hemorrhagic presentation. The present study describes the safe and complete obliteration of the fistula by transarterial endovascular treatment through the ophthalmic artery.

Table 1: Patients' characteristics, presentation and treatment

<i>Patient age, gender</i>	<i>Presentation</i>	<i>Arterial feeders</i>	<i>Draining veins</i>	<i>Cognard classification</i>	<i>Embolic agent</i>	<i>Complications</i>	<i>Follow-up</i>
69 yo Male	Seizures	EA, SPA	FPV	IV	Onyx	None	Complete occlusion at 24 months
63 yo Male	Hemorrhage, headaches	EA	FPV, OV, BVR	IV	Onyx	Subdural hematoma (reabsorbed at 24 hours)	Complete occlusion at 9 years
64 yo Male	Headaches, pulsatile tinnitus	EA, SPA, AMA	FPV, OV	IV	Onyx	None	Complete occlusion at 15 months
74 yo Male	Hemorrhage, seizures	EA, MMA	FOV	IV	Onyx	None	Complete occlusion at 24 months
64 yo Female	Visual disturbances	EA, SPA, STA	FPV	IV	Onyx	None	Complete occlusion at 6 months
23 yo Male	Olfactory disturbances, headaches	EA, SPA	FPV	IV	Onyx	None	Complete occlusion at 12 months

*Abbreviations:* EA = Ethmoidal arteries from ophthalmic artery; SPA = Spheno-palatine arteries; FPV = Fronto-polar vein; AMA = Anterior meningeal vein; OV = Olfactory vein; BVR = Basal vein of Rosenthal; MMA = Middle meningeal vein; FOV = Fronto-orbital vein; STA = Superficial temporal artery;

Table 2: Literature review on series of endovascular treatment for anterior fossa arteriovenous dural fistulas

First Author, year	Endovascular treatment (n)	Cure (%)	Artery injected	Embolic agent	Surgery (n)	Cure (%)	Comments
Lefkowitz, 1998 [17]	3	0%	Ophtalmic artery (3/3), IMAX (1/3)	PVA particles	3	NA	Complications rate: endovascular 0%. Surgery NA
Lawton, 1999 [6]	3	0%	IMAX (3/3)	PVA particles	16	100%	Complications rate: endovascular 0%. Surgery 0%.
Defreyne, 2000 [10]	2	100%	Transvenous (2/2)	Coils	-	-	No complications
Abrahams, 2002 [18]	3	0%	Not specified ECA branch (3/3)	NA	6	100%	Complications rate: endovascular 0%. Surgery 0%. Two of the embolizations were planned as pre-surgical.
Katsaridis, 2007 [19]	1	100%	Ophtalmic artery (1/1)	Glue	-	-	Complications rate: 0%.
Flynn, 2007 [20]	1	100%	Ophtalmic artery (1/1)	Glue	-	-	Complications rate: 0%. Only clinical follow-up described (no DSA control)
Tahon, 2008 [12]	1	100%	MMA (1/1)	Glue	-	-	Complications rate: 0%.
Cognard, 2008 [21]	2	100%	Ophtalmic artery (2/2)	Onyx	-	-	Complications rate: 0%.
Lv, 2008 [7]	3	100%	Transvenous (2/3), Ophtalmic artery (1/3)	Coils, Onyx	-	-	Complications rate: 0%. (1 pt treated transvenously had post-intervention chemosis and pain to the eye, fully recovered after 3 days)
Agid, 2009 [9]	11	63%	Ophtalmic artery (11/11)	Glue	15	100%	2 pts underwent radiosurgery (Cure rate 50%). No complications. The 5 patients presented in Guedin et al. 2010 are present in this series.
Tsutsumi, 2009 [22]	1	100%	Anterior cerebral	Glue	-	-	Complications rate: 0%.

			artery branch (1/1)				
Trivelato, 2010 [13]	2	100%	Ophtalmic artery (2/2), IMAX (1/2)	Onyx	-	-	Complications rate: 0%.
Abud, 2011 [23]	6	NA	Ophtalmic artery (6/6), MMA (1/6)	Onyx	-	-	Complications rate: NA. The two cases of Cognard et al. 2008 are likely included in this series
Kirsch, 2011 [24]	1	100%	Transvenous (1/1)	Coils	-	-	Complications rate: 0%. A previous transarterial embolization through the OA with glue was unsuccessful
Mack 2011 [25]	2	100%	Ophtalmic artery (2/2)	Onyx, Glue	-	-	Complications rate: 0%. (1 pt had post-operative confusion and lethargy that fully recovered)
Zhao, 2012 [14]	6	100%	Ophtalmic artery (6/6)	Onyx	-	-	Complications rate: 0%.
Spiotta, 2014 [11]	3	100%	Transvenous	Onyx	-	-	Complications rate: 0%. One patient had already been treated through the OA, unsuccessfully
Li, 2014 [15]	6	83%	Ophtalmic artery (6/6), MMA (1/6)	Onyx	-	-	Complications rate: 0%.
Deng, 2014 [26]	5	100%	MMA (5/5)	Onyx	-	-	Complications rate: 0%.
Robert, 2015 [8]	10	80%	Ophtalmic artery (10/10), MMA (2/10)	Onyx, Glue	2	100%	Complications rate: endovascular 0%. Surgery 50% (subdural hematoma, drained, pt recovered)
Gross, 2016 [27]	9	22%	Transvenous (1/9 patients), Ophtalmic artery (8/11 arteries embolized), ACA (2/11), IMAX (1/11)	Onyx, Glue	24	100%	Complications rate: endovascular 0%. Surgery 13% (transient, none permanent)

Cannizzaro, 2016 [28]	6	100%	Transarterial, not specified (4/6). Transvenous (2/6).	Glue, Onyx, coils.	7	100%	Complications rate: endovascular 17%. Surgery 14%
Limbucci, 2017 [29]	4	100%	Transvenous (4/4)	Onyx, Coils	-	-	Complications rate: endovascular 25% (Small intraparenchymal frontobasal hematoma)

Studies are ordered by date of publication. When the published endovascular series included also surgery, the surgical results are also presented.

*Abbreviations* n, number of patients treated; IMAX, Internal maxillary artery; NA, not available; ECA, external carotid artery; DSA, digital subtraction angiography; MMA, middle meningeal artery; ACA, anterior cerebral artery.



## References

- 1) Lasjaunias P, Chiu M, ter Brugge K, et al. Neurological manifestations of intracranial dural arteriovenous malformations. *J Neurosurg.* 1986 May;64(5):724-30. DOI: 10.3171/jns.1986.64.5.0724
- 2) Lucas CP, Zabramski JM, Spetzler RF, Jacobowitz R. Treatment for intracranial dural arteriovenous malformations: a meta-analysis from the English language literature. *Neurosurgery.* 1997 Jun;40(6):1119-30 DOI: 10.1097/0006123-199706000-00002
- 3) Borden JA, Wu JK, Shucart WA. A proposed classification for spinal and cranial dural arteriovenous fistulous malformations and implications for treatment. *J Neurosurg.* 1995 Feb;82(2):166-79. Erratum in: *J Neurosurg.* 1995 Apr;82(4):705-6. DOI: 10.3171/jns.1995.82.2.0166
- 4) Cognard C, Gobin YP, Pierot L, et al. Cerebral dural arteriovenous fistulas: clinical and angiographic correlation with a revised classification of venous drainage. *Radiology.* 1995 Mar;194(3):671-80. DOI: 10.1148/radiology.194.3.7862961
- 5) Awad IA, Little JR, Akarawi WP, Ahl J. Intracranial dural arteriovenous malformations: factors predisposing to an aggressive neurological course. *J Neurosurg.* 1990 Jun;72(6):839-50.
- 6) Lawton MT, Chun J, Wilson CB, Halbach VV. Ethmoidal dural arteriovenous fistulae: an assessment of surgical and endovascular management. *Neurosurgery.* 1999 Oct;45(4):805-10
- 7) Lv X, Li Y, Liu A, Lv M, Jiang C, Wu Z. Endovascular embolization of dural arteriovenous fistulas of the anterior cranial fossa: three case reports. *Neurol Res.* 2008 Oct;30(8):852-9. doi: 10.1179/174313208X310313.

- 8) Robert T, Blanc R, Smajda S, et al. Endovascular treatment of cribriform plate dural arteriovenous fistulas: technical difficulties and complications avoidance. *J Neurointerv Surg*. 2016 Sep;8(9):954-8. doi: 10.1136/neurintsurg-2015-011956.
- 9) Agid R, Terbrugge K, Rodesch G, Andersson T, Söderman M. Management strategies for anterior cranial fossa (ethmoidal) dural arteriovenous fistulas with an emphasis on endovascular treatment. *J Neurosurg*. 2009 Jan;110(1):79-84. doi: 10.3171/2008.6.17601.
- 10) Defreyne L, Vanlangenhove P, Vandekerckhove T, et al. Transvenous embolization of a dural arteriovenous fistula of the anterior cranial fossa: preliminary results. *AJNR Am J Neuroradiol*. 2000 Apr;21(4):761-5.
- 11) Spiotta AM, Hawk H, Kellogg RT, et al. Transfemoral venous approach for Onyx embolization of anterior fossa dural arteriovenous fistulae. *J Neurointerv Surg*. 2014 Apr 1;6(3):195-9. doi: 10.1136/neurintsurg-2012-010642.
- 12) Tahon F, Salkine F, Amsalem Y, Aguetaz P, Lamy B, Turjman F. Dural arteriovenous fistula of the anterior fossa treated with the Onyx liquid embolic system and the Sonic microcatheter. *Neuroradiology*. 2008 May;50(5):429-32. doi: 10.1007/s00234-007-0344-8.
- 13) Trivelato FP, Abud DG, Ulhôa AC, et al. Dural arteriovenous fistulas with direct cortical venous drainage treated with Onyx: a case series. *Arq Neuropsiquiatr*. 2010 Aug;68(4):613-8.
- 14) Zhao WY, Krings T, Yang PF, et al. Balloon-assisted superselective microcatheterization for transarterial treatment of cranial dural arteriovenous fistulas: technique and results. *Neurosurgery*. 2012 Dec;71 doi: 10.1227/NEU.0b013e3182684b70.
- 15) Li C, Wu Z, Yang X, et al. Transarterial treatment with Onyx of Cognard type IV anterior cranial fossa dural arteriovenous fistulas. *J Neurointerv Surg*. 2014 Mar;6(2):115-20. doi: 10.1136/neurintsurg-2012-010641.

- 16) Xu 2019, Xu K, Ji T, Li C, Yu J. Current status of endovascular treatment for dural arteriovenous fistulae in the anterior cranial fossa: A systematic literature review. *Int J Med Sci.* 2019 Jan 1;16(2):203-211.
- 17) Lefkowitz M, Giannotta SL, Hieshima G, et al. Embolization of neurosurgical lesions involving the ophthalmic artery. *Neurosurgery.* 1998 Dec;43(6):1298-303.
- 18) Abrahams JM, Bagley LJ, Flamm ES, Hurst RW, Sinson GP: Alternative management considerations for ethmoidal dural arteriovenous fistulas. *Surg Neurol* 58:410–416, 2002
- 19) Katsaridis V, Papagiannaki C, Violaris C. Endovascular treatment of a bilateral ophthalmic-ethmoidal artery dural arteriovenous fistula. *J Neuroophthalmol.* 2007 Dec;27(4):281-4.
- 20) Flynn TH, McSweeney S, O'Connor G, Kaar G, Ryder DQ. Dural AVM supplied by the ophthalmic artery. *Br J Neurosurg.* 2007 Aug;21(4):414-6.
- 21) Cognard C, Januel AC, Silva NA Jr, Tall P. Endovascular treatment of intracranial dural arteriovenous fistulas with cortical venous drainage: new management using Onyx. *AJNR Am J Neuroradiol.* 2008 Feb;29(2):235-41.
- 22) Tsutsumi S, Shimizu Y, Nonaka Y, et al. Arteriovenous fistula arising from the persistent primitive olfactory artery with dual supply from the bilateral anterior ethmoidal arteries. *Neurol Med Chir (Tokyo).* 2009 Sep;49(9):407-9.
- 23) Abud TG, Nguyen A, Saint-Maurice JP, et al. The use of Onyx in different types of intracranial dural arteriovenous fistula. *AJNR Am J Neuroradiol.* 2011 Dec;32(11):2185-91. doi: 10.3174/ajnr.A2702.
- 24) Kirsch M, Henkes H. A ruptured intraorbital ophthalmic artery aneurysm, associated with a dural arteriovenous fistula: combined transarterial and transvenous endovascular treatment. *Minim Invasive Neurosurg.* 2011 Jun;54(3):128-31. doi: 10.1055/s-0031-1277230.
- 25) Mack WJ, Gonzalez NR, Jahan R, Vinuela F. Endovascular management of anterior cranial fossa dural arteriovenous malformations. A technical report and anatomical discussion. *Interv Neuroradiol.* 2011 Mar;17(1):93-103.

- 26) Deng JP, Li J, Zhang T, Yu J, Zhao ZW, Gao GD. Embolization of dural arteriovenous fistula of the anterior cranial fossa through the middle meningeal artery with Onyx. *Clin Neurol Neurosurg*. 2014 Feb;117:1-5. doi: 10.1016/j.clineuro.2013.11.013.
- 27) Gross BA, Moon K, Kalani MY, et al. Clinical and Anatomic Insights From a Series of Ethmoidal Dural Arteriovenous Fistulas at Barrow Neurological Institute. *World Neurosurg*. 2016 Sep;93:94-9. doi: 10.1016/j.wneu.2016.05.052.
- 28) Cannizzaro D, Peschillo S, Cenzato M, et al. Endovascular and surgical approaches of ethmoidal dural fistulas: a multicenter experience and a literature review. *Neurosurg Rev*. 2018 Apr;41(2):391-398. doi: 10.1007/s10143-016-0764-1.
- 29) Limbucci N, Leone G, Nappini S, et al. Transvenous Embolization of Ethmoidal Dural Arteriovenous Fistulas: Case Series and Review of the Literature. *World Neurosurg*. 2018 Feb;110:e786-e793. doi: 10.1016/j.wneu.2017.11.095.
- 30) Chaudhary MY, Sachdev VP, Cho SH, et al. Dural arteriovenous malformation of the major venous sinuses: an acquired lesion. *AJNR Am J Neuroradiol*. 1982 Jan-Feb;3(1):13-9.
- 31) Parkinson D. Dural arteriovenous malformations. *Surg Neurol* 29:164-165, 1988
- 32) Singh S, Dass R. The central artery of the retina. I. Origin and course. *Br J Ophthalmol*. 1960 Apr;44:193-212.
- 33) King WA, Hieshima GB, Martin NA. Venous rupture during transvenous approach to a carotid-cavernous fistula. Case report. *J Neurosurg* 71:133–137, 1989
- 34) Kiyosue H, Hori Y, Okahara M, et al. Treatment of intracranial dural arterio-venous fistulas: current strategies based on location and hemodynamics, and alternative techniques of transcatheter embolization. *Radiographics* 2004;24:1637-1653.
- 35) Tomak PR, Cloft HJ, Kaga A, et al. Evolution of the management of tentorial dural arteriovenous malformations. *Neurosurgery* 2003;52:750-762.

## Figure legends

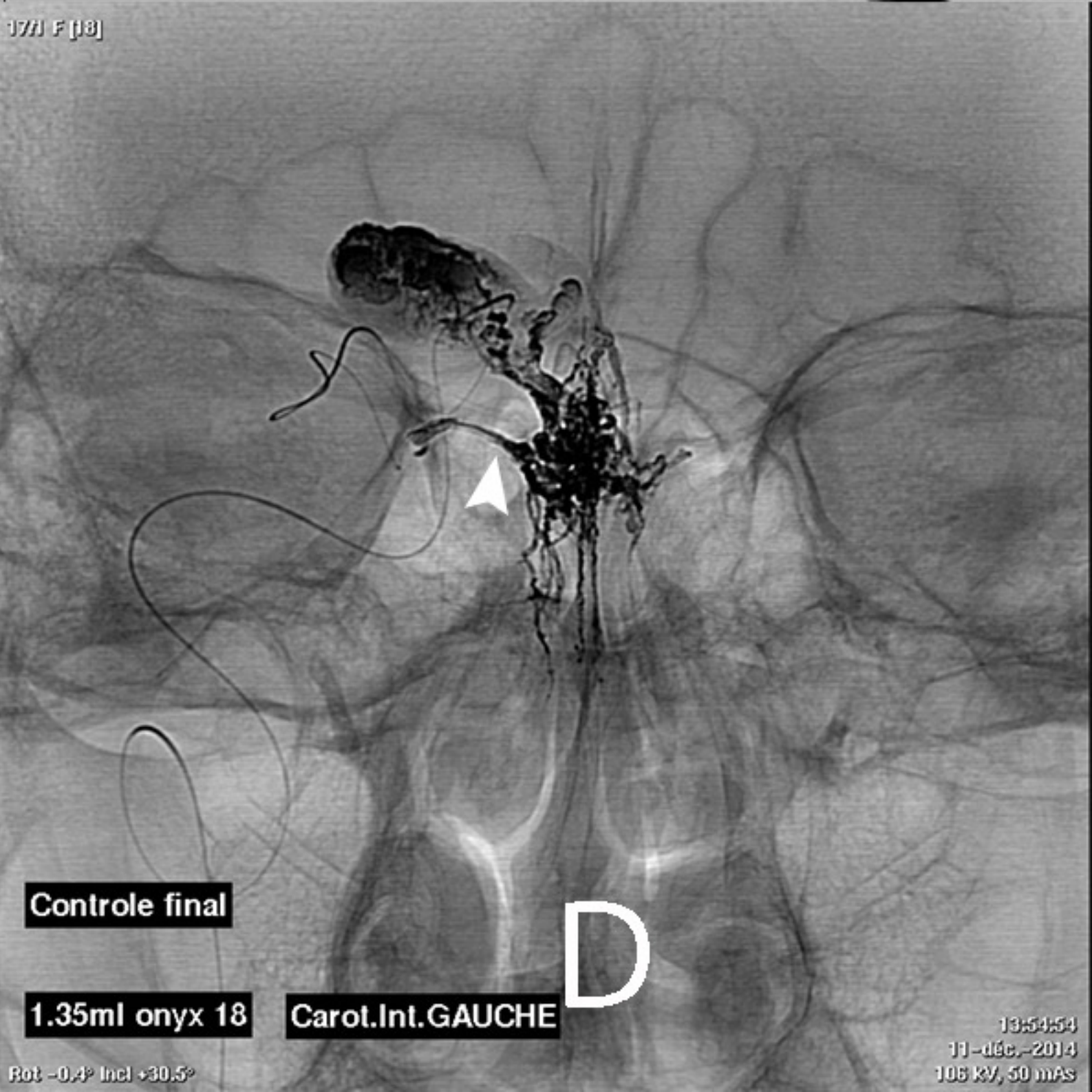
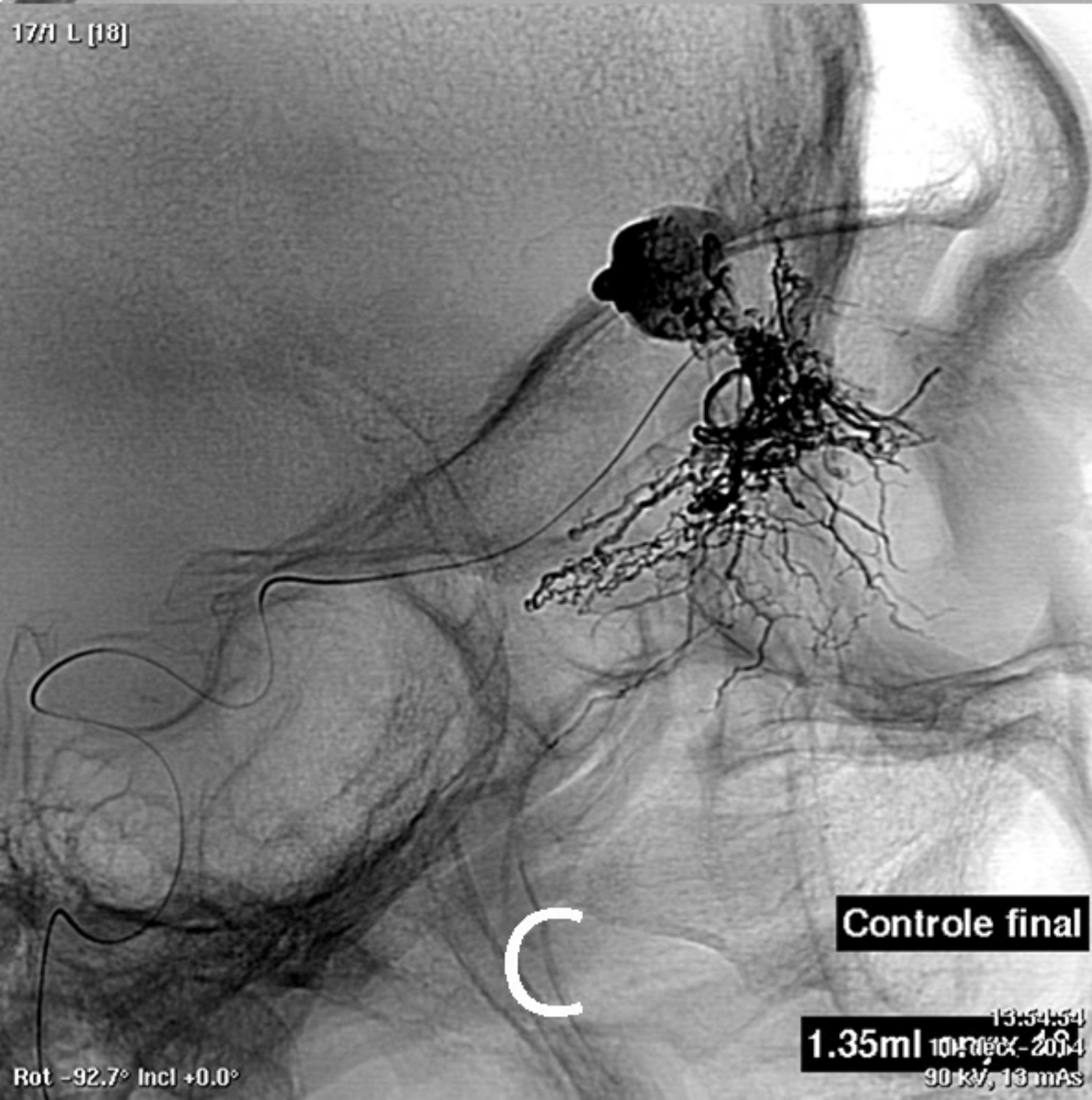
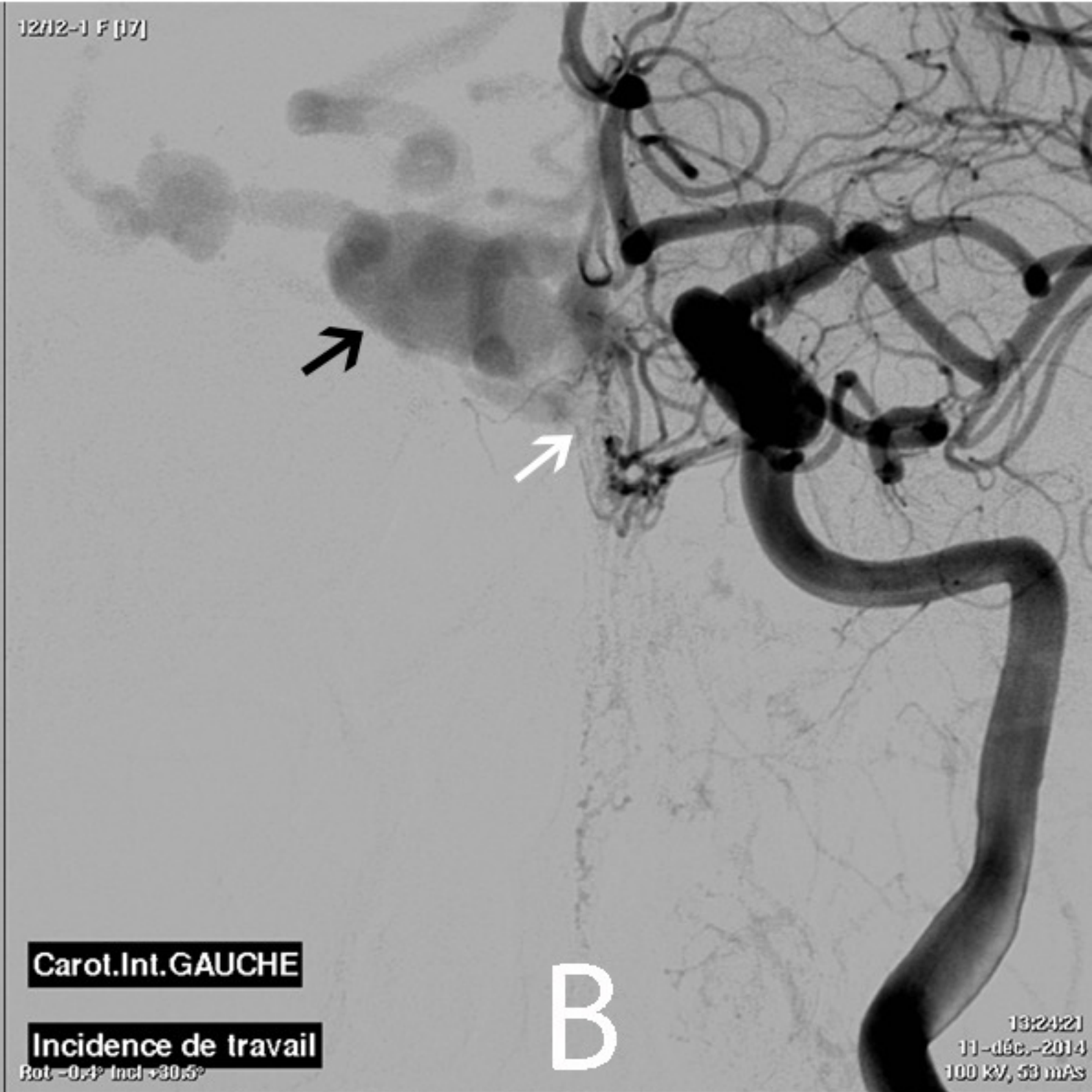
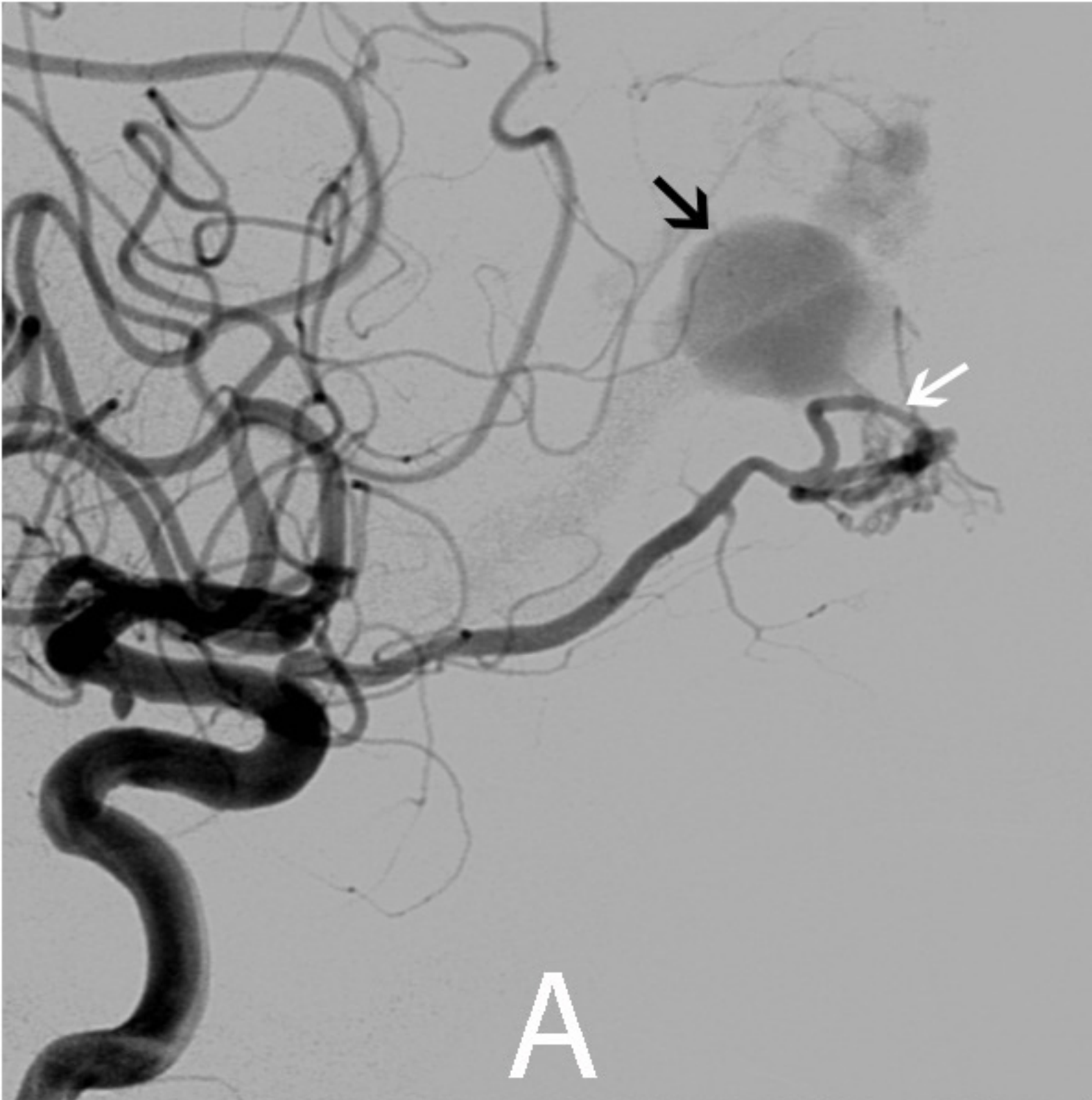**Figure 1 :** 64yo male with bilateral ophthalmic artery supply. Sagittal view on the right side (A) and left side (B) with superior ethmoidal arteries (white arrow) supplying an AV shunt with a venous ectasia (black arrow). Distal catheterization with a Headway Duo microcatheter (white arrowhead) through the right ophthalmic artery. Final cast of Onyx is seen on C and D with a total occlusion after venous contamination.

**Figure 2 :** On the upper row, a 49 year old male with right ophthalmic artery supply (A). After a failed surgery, the latter was navigated with a Marathon microcatheter (distal tip, white arrowhead, B). Total exclusion after Onyx injection in the draining vein with ectasia (white arrow, C). The lower row shows a 23 yo patient with dural shunt from the right ophthalmic artery without involvement of the left side. Venous reflux in an olfactory vein (D). Headway duo 1.3F microcatheter with Chikai 10 wire was negotiated up to the distal 3rd segment of the right ophthalmic artery (black arrowhead on the distal tip), E). A remodeling balloon (HyperForm 7x7) was used as a support device to facilitate the navigation in the ostium. Complete shunt obliteration after Onyx injection, with mild venous reflux in the shunt (black arrow, E and F).

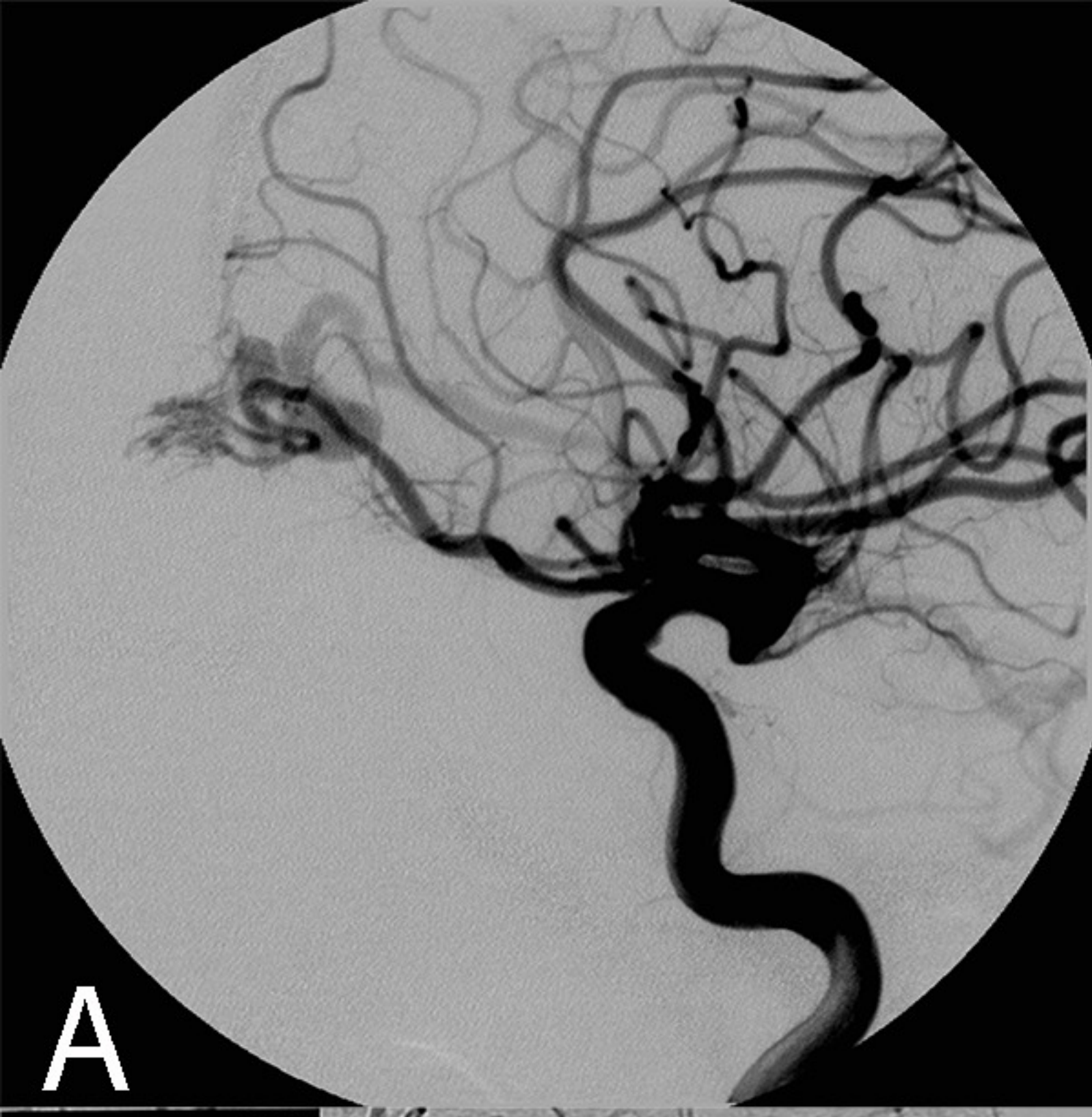
**Figure 3 :** 74 yo patient with bilateral ophthalmic supply and venous reflux in a single ethmoidal vein (black arrowheads). Headway duo microcatheter navigated first by the right side then by the left (A and B) after unexpected catheter occlusion during Onyx injection. Final control (C and D) shows a complete occlusion with a clear contamination of the draining vein (white arrowheads). An Eclipse remodeling balloon (A, black arrow) was used to reach the ophthalmic ostium on a triaxial system with a Mach 7F and Sofia 5F (Microvention).

**Figure 4 :** On the upper row, a sagittal opacification of 69 yo male patient with an AV shunt from both ophthalmic arteries (A). A failed attempt from the right side was done one month before. A marathon microcatheter was navigated on Xpedion-10 wire in the left ophthalmic artery (distal tip white arrow, B). Final cast (C) depicts a complete obliteration with Onyx cast in the main venous ectasia (white arrowheads). A 64 yo female with bilateral ophthalmic supply is shown on the lower row. Very distal microcatheterization from the left ophthalmic artery up the superior ethmoidal artery with a Headway 17 microcatheter and a Sofia 5F intermediate catheter left at the ostium of the ophthalmic artery (A and B, distal tip black arrow). Final control shows a strong venous contamination with Onyx without residual shunt (black arrowheads, C).

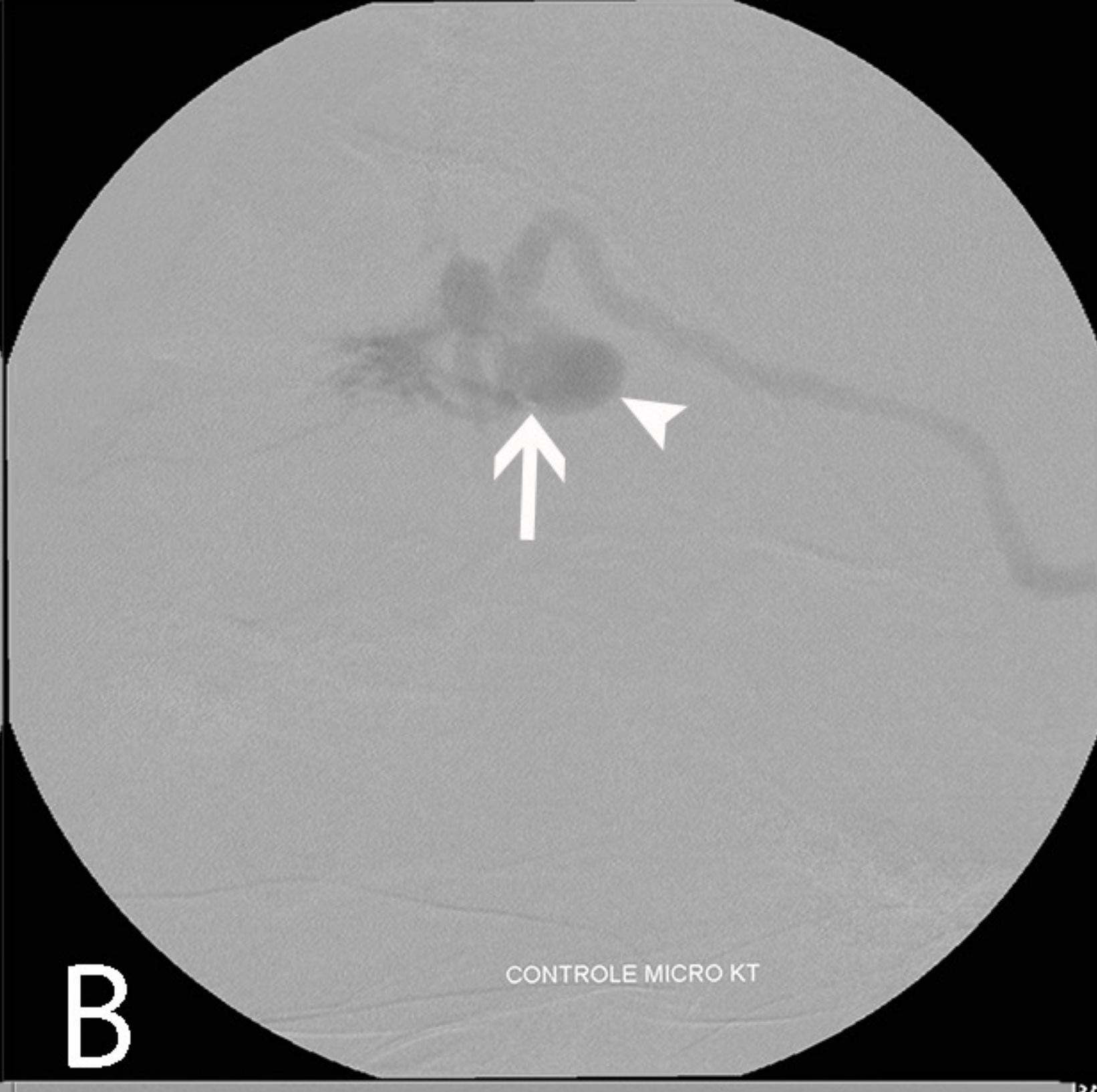




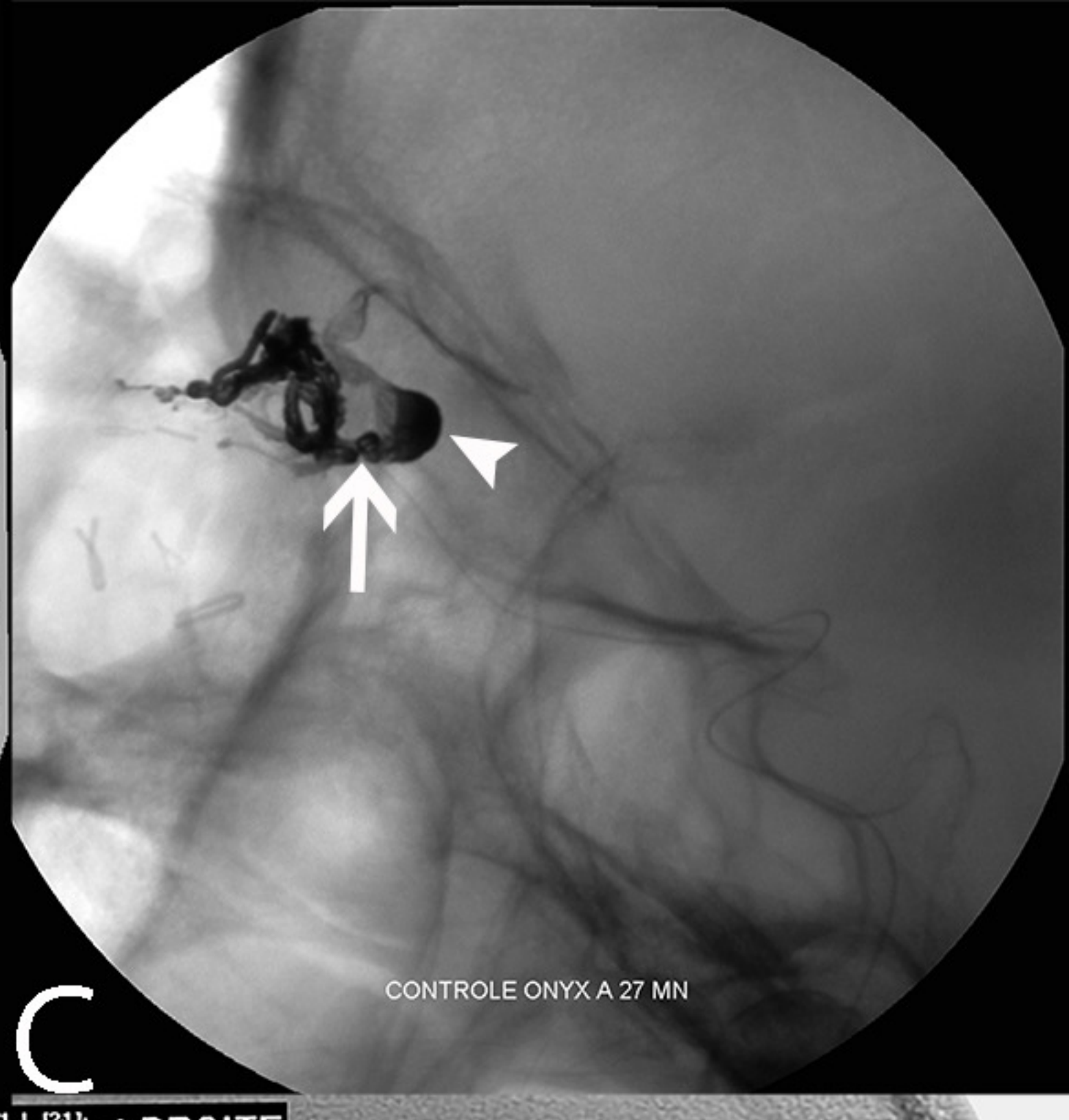




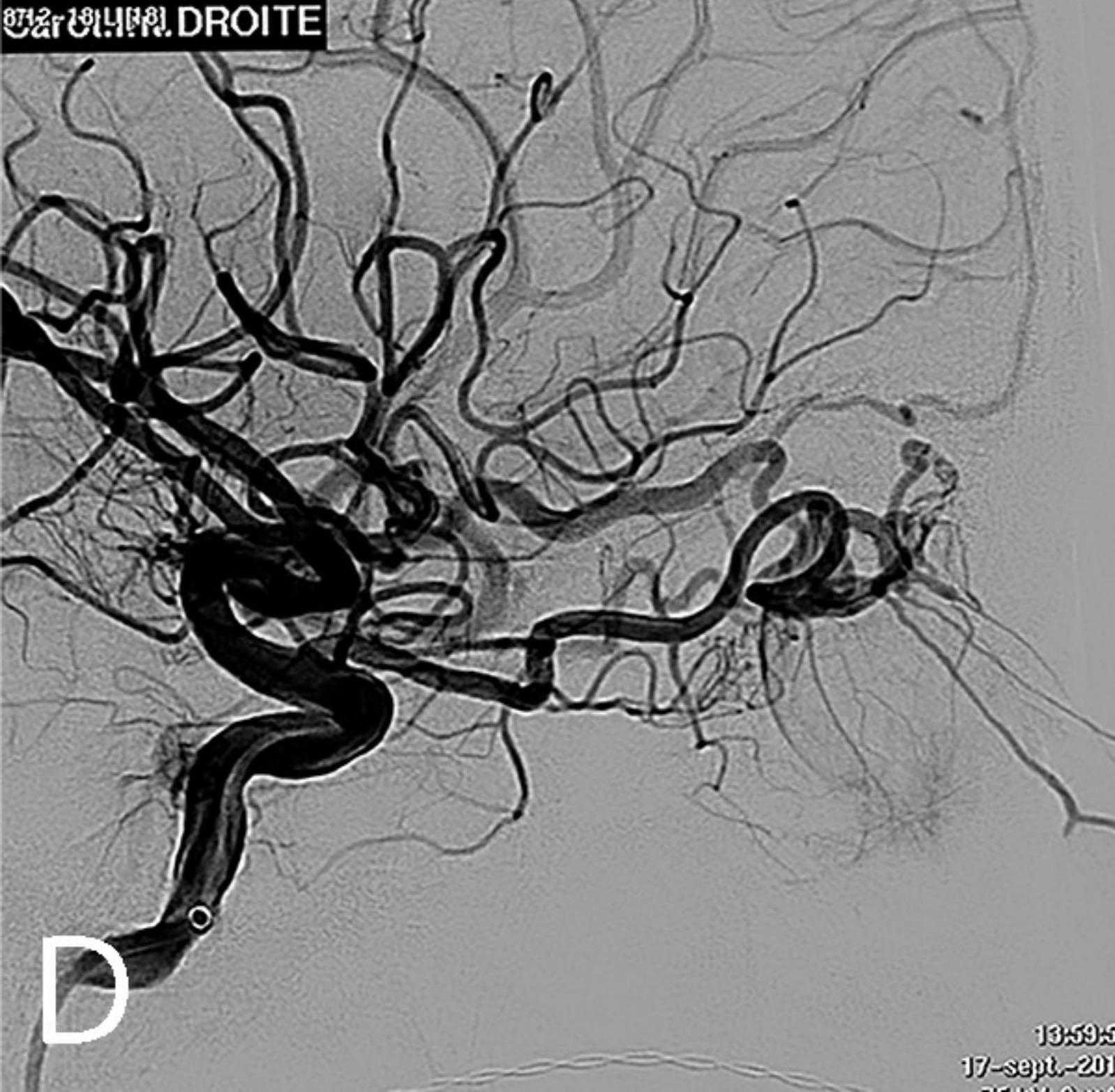
**A**



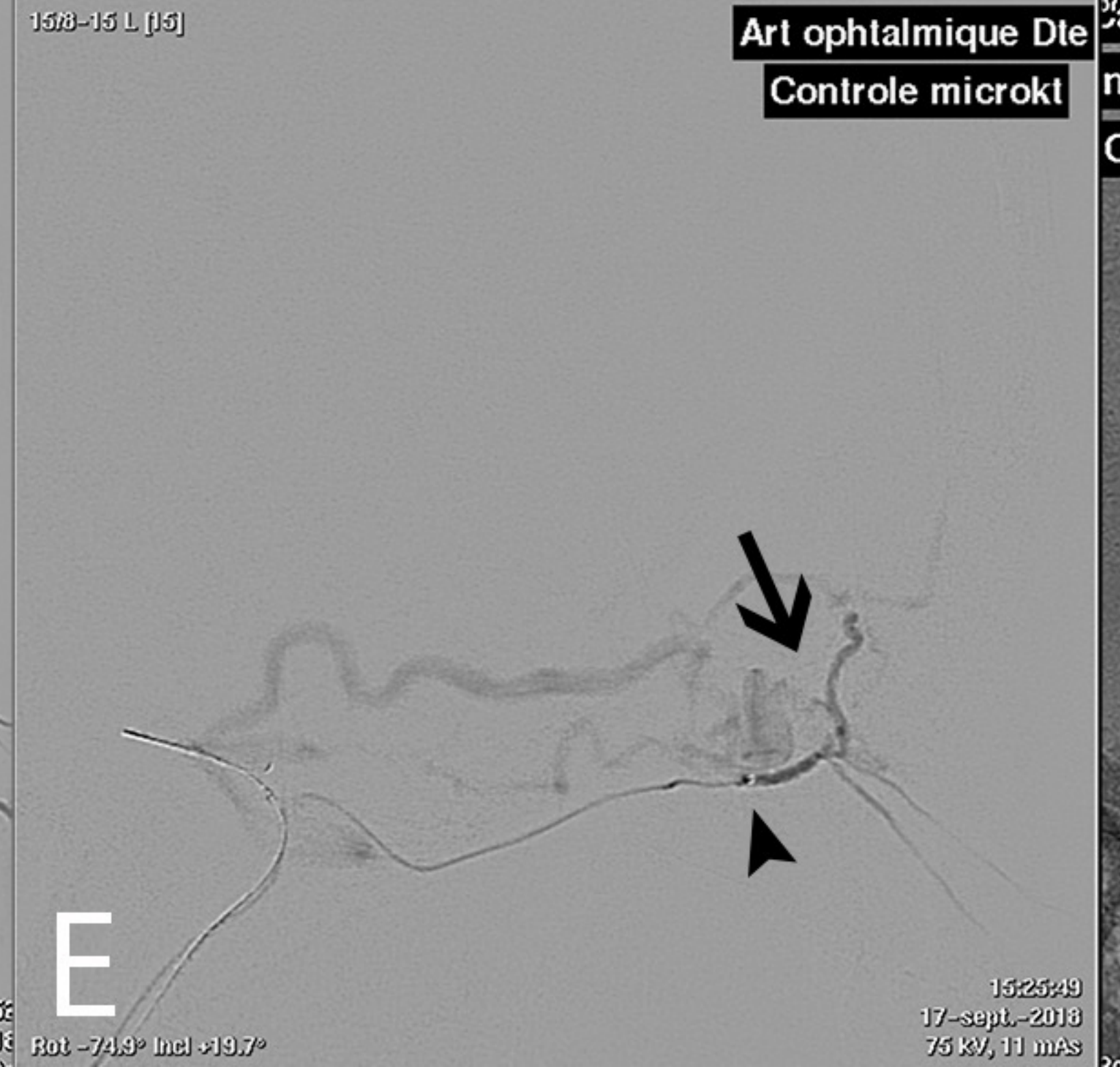
**B**



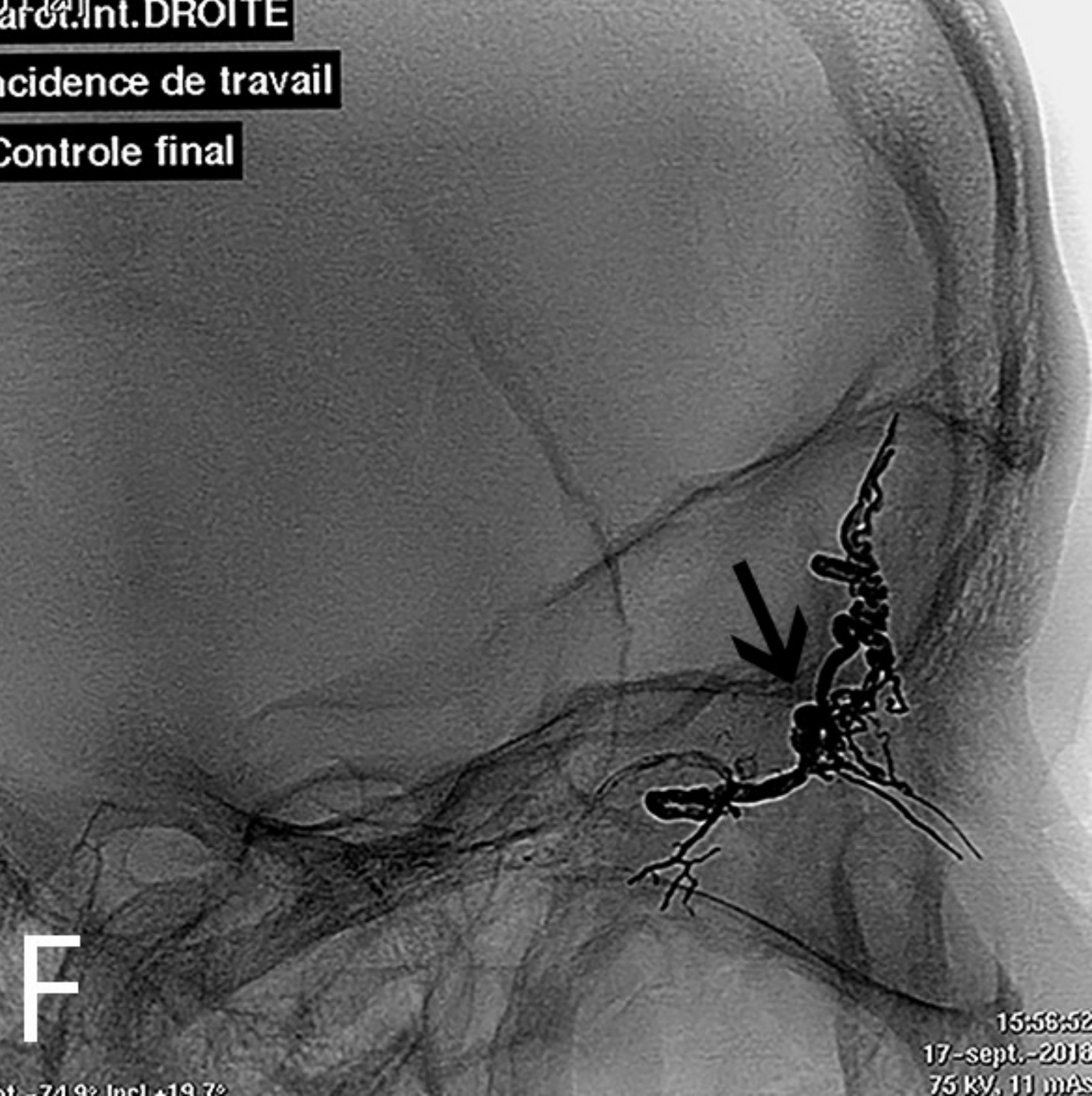
**C**



**D**



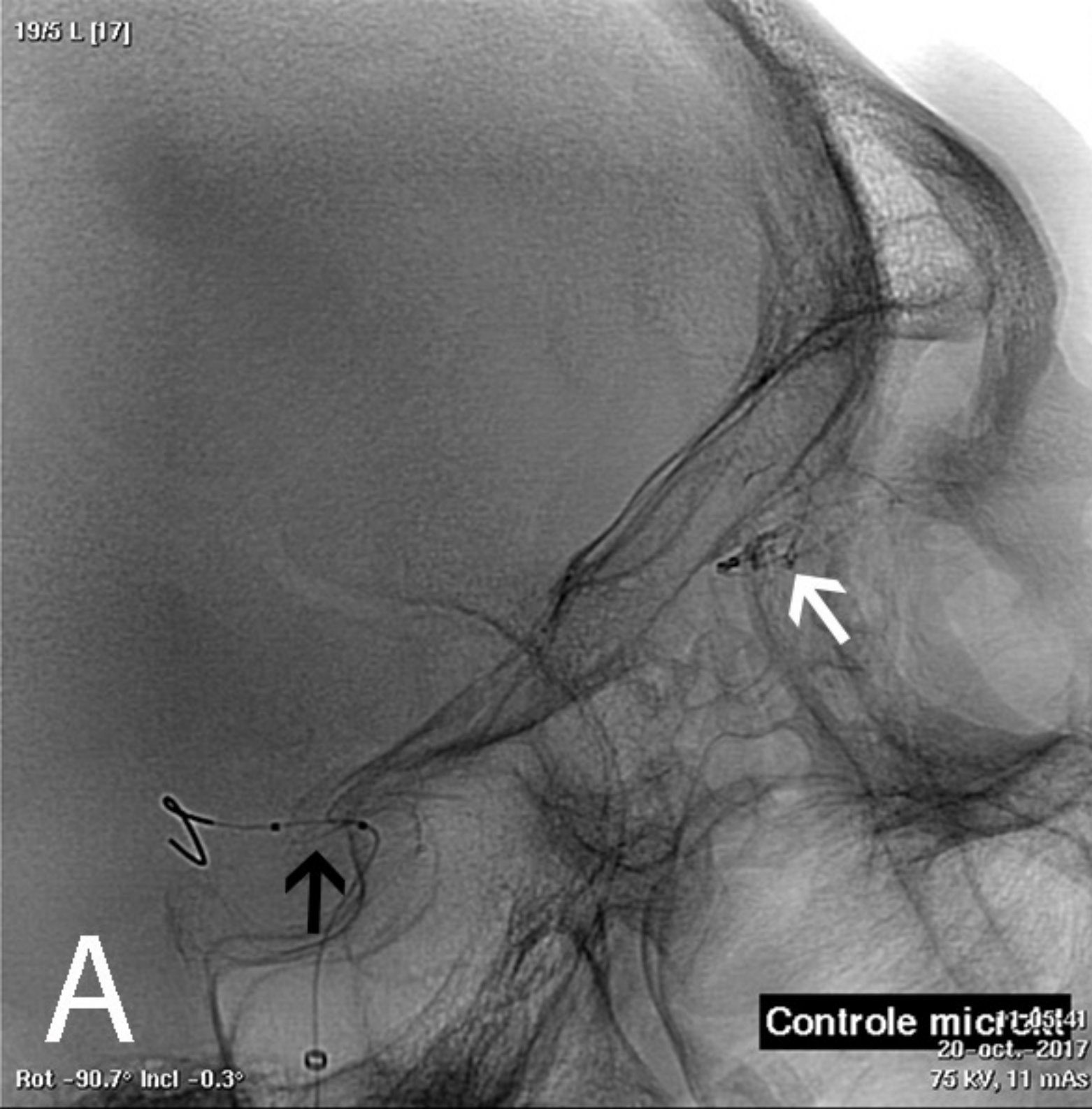
**E**



**F**



19/5 L [17]



18/13-14 L [14]

