



**HAL**  
open science

## **Sjögren Syndrome overlapping with ANCA-associated vasculitis: four additional cases and systematic literature review**

Cyrille Coustal, Béatrice Guillope, Chris Serrand, Jacques Morel, Guillaume Taieb, Elodie Castille, Kaoutar Meliani, Olivier Darmon, Radjiv Goulabchand, Philippe Guilpain

### ► To cite this version:

Cyrille Coustal, Béatrice Guillope, Chris Serrand, Jacques Morel, Guillaume Taieb, et al.. Sjögren Syndrome overlapping with ANCA-associated vasculitis: four additional cases and systematic literature review. *Autoimmunity Reviews*, 2022, 21 (6), pp.103099. 10.1016/j.autrev.2022.103099 . hal-03650085

**HAL Id: hal-03650085**

**<https://hal.science/hal-03650085v1>**

Submitted on 3 Nov 2022

**HAL** is a multi-disciplinary open access archive for the deposit and dissemination of scientific research documents, whether they are published or not. The documents may come from teaching and research institutions in France or abroad, or from public or private research centers.

L'archive ouverte pluridisciplinaire **HAL**, est destinée au dépôt et à la diffusion de documents scientifiques de niveau recherche, publiés ou non, émanant des établissements d'enseignement et de recherche français ou étrangers, des laboratoires publics ou privés.



Distributed under a Creative Commons Attribution 4.0 International License

# Sjögren syndrome overlapping with ANCA-associated vasculitis: Four additional cases and systematic literature review

Cyrille Coustal<sup>a</sup>, Béatrice Guillope<sup>b</sup>, Chris Serrand<sup>c</sup>, Jacques Morel<sup>d</sup>, Guillaume Taieb<sup>e</sup>, Elodie Castille<sup>a</sup>, Kaoutar Meliani<sup>a</sup>, Olivier Darmon<sup>a</sup>, Radjiv Goulabchand<sup>f</sup>, Philippe Guilpain<sup>a,g,\*</sup>

<sup>a</sup> Department of Internal Medicine - Multi-Organic Diseases, Local Referral Center for Rare Auto-immune Diseases, Montpellier University Hospital, Montpellier, France

<sup>b</sup> Department of nephrology, Université de Montpellier, CHU de Montpellier, Montpellier, France.

<sup>c</sup> Department of Epidemiology and Biostatistics, Montpellier University Hospital, Montpellier, France

<sup>d</sup> Department of Rheumatology, Montpellier University Hospital, University of Montpellier, PhyMedExp, University of Montpellier, INSERM U1046, CNRS UMR, 9214 Montpellier, France

<sup>e</sup> Department of Neurology, University Hospital of Montpellier, Montpellier, France

<sup>f</sup> Internal Medicine Department, Nîmes University Hospital, Montpellier University, Nîmes, France

<sup>g</sup> Institute of Regenerative Medicine and Biotherapy, Institut national de la santé et de la recherche médicale U1183, Montpellier, France

## ARTICLE INFO

### Keywords:

Overlap syndrome  
ANCA-associated vasculitis  
Sjögren's syndrome  
Systematic review  
Granulomatous vasculitis

## ABSTRACT

**Objectives:** Sjögren's syndrome (SS) and ANCA-associated vasculitis (AAV) have distinct clinical presentation and evolution, with paucity of reports on overlap syndrome. We aimed to better characterize this entity.

**Methods:** We report four additional cases from the Montpellier university hospital. We also performed a systematic literature review, according to PRISMA guidelines, in Medline, Embase, Web of science, Cochrane Library, and grey literature. Demographic, clinical, and paraclinical data on SS and AAV were analysed.

**Results:** A total of 3133 articles was identified in databases, with 2695 articles screened for eligibility. After exclusion, we had 30 articles on 40 patients to analyse, in addition to 4 patients from our local recruitment (44 patients overall). Patients were female in 81.8%, with median age at AAV onset of 63.5 years. All patients but one presented with SS before, or concomitantly to the diagnosis of AAV, with a median delay of 12 months between both diagnoses. AAV predominantly had renal involvement (35/44 patients, 79.5%), anti-MPO antibodies being the most frequent (35 patients), even in patients presenting with granulomatosis with polyangiitis. We observed significantly more Raynaud phenomenon and associated auto-immune diseases in the group of non-granulomatous AAV (10 patients versus 1,  $p = 0.015$  and 8 patients versus 0,  $p = 0.013$ , respectively).

**Conclusions:** This is the largest descriptive study on the association between SS and AAV, providing information on this challenging diagnosis and interplay between these two diseases. Particular attention should be paid in the first months after diagnosis, given the specific complications and outcomes of each disease.

## 1. Introduction

Antineutrophil cytoplasm antibody (ANCA)-associated vasculitis (AAV) is a group of small-sized vessel necrotizing and pauci-immune vasculitides. According to the Chapel Hill Nomenclature [1], AAV include granulomatosis with polyangiitis (GPA, formerly called Wegener's granulomatosis), microscopic polyangiitis (MPA), eosinophilic granulomatosis with polyangiitis (EGPA, formerly called Churg–Strauss syndrome) and single organ AAV (for example renal limited AAV). While

ANCA are inconstantly detected, their target antigens are mainly represented by proteinase 3 (PR3) and myeloperoxidase (MPO) [2]. Interestingly, AAV may overlap with other inflammatory and autoimmune diseases, such as inflammatory bowel diseases [3], IgG4-related disease (IgG4-RD) [4], systemic sclerosis [5], lupus [5] and Sjögren syndrome (SS) [6].

Sjögren syndrome (SS) is a systematic autoimmune disease, targeting exocrine glands (especially lachrymal and salivary), leading to sicca syndrome. However, patients can exhibit other 'extraglandular'

\* Corresponding author at: Internal Medicine: Multi-Organic Diseases, Saint Eloi Hospital, Montpellier University Hospital, 80 avenue Augustin Fliche, 34295, Montpellier cedex 5, France.

E-mail address: [p-guilpain@chu-montpellier.fr](mailto:p-guilpain@chu-montpellier.fr) (P. Guilpain).

manifestations, such as arthritis, pneumonitis, peripheral neuropathy, or haematological complications (cryoglobulinemia, B cell lymphoma...) [7]. Among these complications, renal involvement occurs in <10% of patients. It is mainly represented by tubulointerstitial nephritis, and more rarely membranoproliferative glomerulonephritis (most of the time secondary to cryoglobulinemia) or membranous glomerulonephritis [8]. Small or medium-vessel vasculitis has also been reported in up to 10% of SS, mainly secondary to cryoglobulinemia [7,9]. Overlapping conditions of SS and AAV are rarely reported. The first observation probably dates to 1951 (prior to ANCA discovery): in this case, SS was associated with a necrotizing granulomatous arteritis responsible of renal and neurologic impairment [10]. Since then, several other observations of SS-AAV have been reported [6]. However, a detailed description of this overlap syndrome is still lacking, literature providing mostly case reports and small case series. In our tertiary centre, we identified 4 new cases of SS-AAV overlap and decided to conduct a systematic review of literature, in order to better characterize this rare entity.

## 2. Methods

New case reports all originated from Montpellier University hospital.

### 2.1. Search method

Systematic review protocol was performed according to the Preferred Reporting Items for Systematic reviews and Meta-Analysis (PRISMA) guidelines (<http://www.prisma-statement.org/>). We conducted a search in Medline, Embase, Web of science, and Cochrane Library, from their inception to June 2021. We also searched through grey literature using OpenGrey and Grey Literature Report. We used the following MeSH terms on PubMed ('Antineutrophil cytoplasm antibody' OR 'ANCA-associated vasculitis' OR 'granulomatosis with polyangiitis' OR 'Wegener' OR 'microscopic polyangiitis' OR 'eosinophilic granulomatosis with polyangiitis' OR 'Churg-Strauss' OR 'polyangiitis' OR 'ANCA' OR 'granulomatosis' OR 'small-vessel') AND ('Sjögren's syndrome'), and their equivalent on the other databases. There was no language neither time restriction.

Inclusion criteria were: (a) single reports, case series or review of literature; (b) patients with an association of verified SS and AAV. There was no limitation on age and ethnicity. SS diagnosis relied on physician's opinion and was based on ACR/EULAR 2017 classification criteria [11]. Isolated sicca syndrome was not included. AAV diagnosis was based on the American College of Rheumatology (ACR) 1990 classification criteria and/or definitions by the 2012 revised Chapel Hill Consensus [1,12,13].

### 2.2. Data extraction

We first screened the titles and abstracts and selected relevant full-text articles. A manual search from reference lists of included articles was performed. Full-text versions of potentially relevant papers identified in the initial screening were retrieved. When necessary, we contacted the authors of the original reports to request any unpublished data. If the authors did not reply, we used the available data for our analyses.

Screening, data collection and analysis was performed independently by two investigators (CC, BG), following a predefined standard electronic collection form. Discrepancies were resolved by consensus, and if not reached, with the aid of a third researcher (RG). Because we did not aim at comparing variables between studies but rather being as exhaustive as possible, we did not apply any quality index for the included articles.

### 2.3. Endpoints/outcomes

Data collected about SS included clinical presentation, i.e. age at diagnosis, presence of sicca syndrome and extraglandular manifestations (arthralgia, Raynaud's phenomenon, cutaneous, pulmonary, neurologic and renal involvement, lymphoma); laboratory results such as: antinuclear antibodies (ANA), rheumatoid factor (RF), anti-Ro/SSA, and anti-La/SSB antibody positivity, C3/C4 levels, presence of cryoglobulinemia, results of minor salivary gland biopsy (MSGB). Data collected about AAV included age at diagnosis, delay with SS diagnosis, clinical presentation (general symptoms, articular, ear-nose-throat, pulmonary, renal, cutaneous or other systemic involvement, CHCC classification), and laboratory findings (urinary sediment, ANCA status (immunofluorescence assay and/or anti-MPO/anti-PR3 assays), kidney or other organ biopsy if available). In addition, available data on other associated-autoimmune diseases, modalities of treatment, and outcomes were also recorded.

### 2.4. Statistical analysis

Quantitative variables were described with medians and inter-quartile range and compared with Mann-Whitney test. Qualitative variables were described as percentages and compared with  $\chi^2$  or Fischer's exact test as appropriate. All statistical analysis were performed using GraphPad Prism 8.0.2 (San Diego CA). Statistical difference was considered significant for  $p < 0.05$ . No funding has been received for this study.

### 2.5. Ethical consent

The study was approved by the Montpellier university hospital institutional review board (number 2021\_05\_202100844).

## 3. Results

### 3.1. Case reports

Patient 1: A 73-year-old woman was addressed to internal medicine department for a chronic cough, associated to asthenia, weight loss, and a CT scan showing bilateral upper lobes opacities. She declared a Raynaud phenomenon since her puberty. She had no additional involvement, in particular no asthma and no obstructive airway disease. Admission white blood cell count showed elevated eosinophils (1.6 G/L), with positive c-ANCA anti-MPO (titer 542 UI/mL), leading to the diagnosis of GPA with circulating eosinophilia. Because Five Factor Score (FFS) [14] was 0, she was discharged with corticosteroids 1 mg/kg, with a scheduled progressive dose tapering, according to the French Guidelines [15]. Clinical outcome was good under treatment. Nevertheless, she complained about persistent sicca syndrome during the first months of follow-up. Schirmer test was abnormal and MSGB showed a focus score of 2, leading to SS diagnosis. Anti-SSA/SSB antibodies were not detected. Finally, the patient developed permanent sensitive symptoms (paresthesia, pinprick and thermal hypoesthesia) in the feet, with normal nerve conduction study (NCS). These neurological manifestations were associated with recurrent gastric autonomic symptoms, overall consistent with a probable small fiber neuropathy (SFN), according to 2010 criteria [16].

Patient 2: A 62-year-old man was hospitalised for weight loss (5 kg), fever, cough, and hemoptysis. CT scan showed lung nodules while bronchoscopy exhibited diffuse inflammation, with granulomatous vasculitis on biopsies. Positive p-ANCA with MPO specificity (145 UI/mL) were detected. Prednisone was initiated at 1 mg/kg, with favorable outcome. Four months later, under prednisone 25 mg/a day, the patient experienced quickly progressive painful paresthesia of the feet and hands. Physical examination was normal. NCS showed sensory loss in all limbs, with normal motor nerve conduction. These findings were

consistent with the diagnosis of sensory neuropathy [17] and very suggestive of SS diagnosis. Diagnostic work-up revealed abnormal Schirmer test and focus score of 2 on MSGB, leading to SS diagnosis. After AAV remission, chronic cough, sensitive complaints of the lower limbs and chronic diffuse pains (like fibromyalgia syndrome) occurred and were considered as SS-related with no further evidence of active AAV.

**Patient 3:** A 70-year-old man with no medical history, was admitted for rapidly progressive asymmetric lower limbs weakness, along with a recent asthmatic bronchitis and an opacity of left lower lung lob on CT scan. Neurological symptoms extended to upper limbs within a few days, associated with neuropathic pain and diffuse deep-tendon areflexia. NCS showed features of multiple mononeuropathy, while biology demonstrated elevated eosinophils (10 G/L) and positive p-ANCA with MPO specificity (739 UI/mL). All these findings were consistent with EGPA. As he complained about sicca syndrome, Schirmer test and MSGB (focus score of 2) validated concomitant SS diagnosis, despite the absence of antinuclear antibodies or anti-SSA/SSB antibodies. After three intravenous pulses of corticosteroids, the patient was treated with prednisone at the dose of 1 mg/kg per day and seven plasma exchange courses were performed. Follow-up was marked by pulmonary embolism, but outcome was globally favorable with a good but incomplete neurological recovery despite AAV global remission.

**Patient 4:** A 69-year-old woman was admitted with asthenia, weight loss, recurrent fever, rapidly progressive glomerulonephritis (plasma creatinine 404 µmol/L, microscopic haematuria, proteinuria/creatinuria ratio 256 mg/mmol) and elevated CRP (163 mg/L). She had a history of seronegative non-deformative polyarthritis without any defined diagnosis. CT scan revealed pseudo-nodular opacities of the lungs, associated with interstitial thickening. p-ANCA were tested positive (1/1600) with anti-MPO at 151 UI/mL. Kidney biopsy showed crescentic proliferative glomerulonephritis with fibrinoid necrosis. She complained about xerostomia, with abnormal unstimulated salivary

flow, positive anti-SSA (31 UI/mL) and positive MSGB (focus score of 1), leading to concomitant diagnosis of SS. Outcome was good under glucocorticoids and Rituximab regimen.

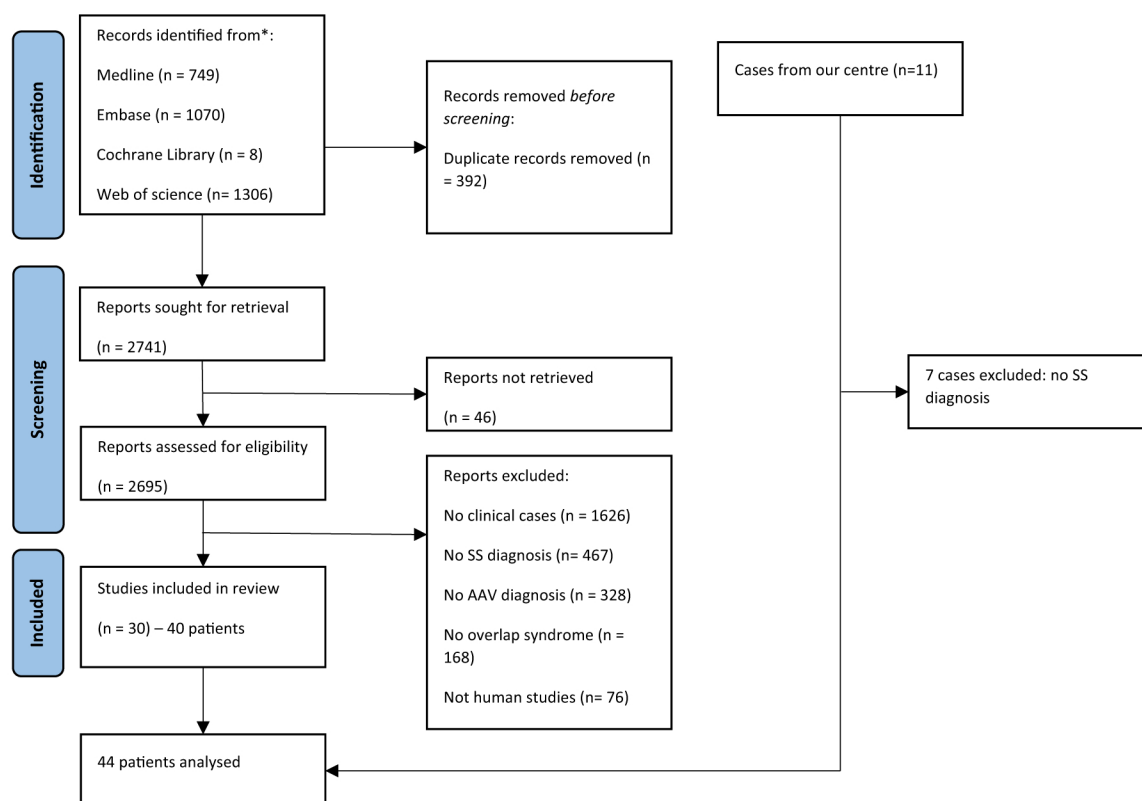
### 3.2. Systematic literature review

Our literature search identified a total of 3133 articles on the selected databases. No relevant articles were found in grey literature. 392 redundant studies were removed. 2741 articles were screened: 46 articles were not retrieved for eligibility assessment. On the 2695 remaining articles, 2663 were excluded (Fig. 1) because they did not meet the diagnosis criteria for SS ( $n = 467$ ), or AAV ( $n = 328$ ), or there were no clinical cases ( $n = 1626$ ). Particularly, some case reports have been excluded for the following reasons: MSGB revealing signs of vasculitis instead of SS features [18], exclusively cutaneous vasculitis associated with ANCA-IgA [19], or drug-induced ANCA-positive cutaneous vasculitis [20]. Furthermore, three cases were excluded because there were missing data about SS diagnostic features (MSGB results or anti-SSA) [6,21,22]. Eventually, 30 articles, involving 40 patients, were included, along with the four new patients from our tertiary centre.

### 3.3. Description of overall SS patients with AAV (from published articles and from our centre)

#### 3.3.1. General characteristics

The characteristics (sex, age on diagnoses, clinical and paraclinical features, AAV classification) of the 44 included patients are detailed in Table 1. The individual characteristics of all patients are described in Supplementary Table S1. Patients were mainly female (36/44 patients, 81.8%). The median age on AAV diagnosis was 63.5 [50.2–69.7] years. The median follow-up was 24 months [IQR: 3.75–24.75], and seven deaths occurred.



**Fig. 1.** Flow diagram of the selection of relevant articles included in our systematic literature research of patients with Sjögren's syndrome and ANCA-associated vasculitis.

**Table 1**  
Demographic and disease characteristics of 44 patients with Sjögren's syndrome and ANCA-associated vasculitis selected from our literature review, according to immunological status.

	Total (n = 44)	Anti-SSA+ (n = 28)	Anti-SSA- (n = 10)	Anti-SSA NR (n = 6)	<i>p</i> *
Female, n (%)	36 (81.8)	23 (82.1)	8 (80)	5 (83.3)	1
Age of SS diagnosis, years [IQR]	60 [48–67]	56.5 [47.2–67.7]	60.5 [48–64]	62 [33.5–68]	0.915
Age of AAV diagnosis, years [IQR]	63.5 [50.2–69.7]	64.5 [52.5–69.7]	62.5 [48.7–67]	59 [34.7–72]	0.497
Delay, months [IQR]	12 [0–60]	6 [0–87]	17 [0–45]	60 [30–66]	0.64
SS features, n (%)					
- Sicca syndrome	35 (79.5)	22 (78.6)	9 (90)	6 (100)	0.649
- Cutaneous	4 (9.1)	4 (14.3)	0	0	0.556
- Lung	5 (11.4)	3 (10.7)	1 (10)	1 (16.7)	1
- Raynaud	11 (25)	6 (21.4)	2 (20)	3 (50)	1
- Arthralgia	16 (36.4)	10 (35.7)	4 (40)	2 (33.3)	1
- Neuropathy	2 (4.5)	0	2 (20)	0	0.064
- Lymphoma	1 (2.3)	1 (3.6)	0	0	1
- Positive MSGB	34 (77.3)	18 (64.3)	10 (100)	6 (100)	0.037
- Rheumatoid factor	17 (38.6)	12 (42.9)	4 (40)	1 (16.7)	1
- Cryoglobulinemia	4 (9.1)	4 (14.3)	0	0	0.556
AAV features, n (%)					
- Fever	18 (40.9)	12 (42.9)	4 (40)	2 (33.3)	1
- Arthritis	4 (9.1)	4 (14.3)	0	0	0.556
- Eye	2 (4.5)	1 (3.6)	0	1 (16.7)	1
- ENT	10 (22.7)	4 (14.3)	3 (30)	3 (50)	0.351
- Cutaneous	8 (18.2)	6 (21.4)	2 (20)	0	1
- Neuropathy	11 (25)	5 (17.9)	4 (40)	2 (33.3)	0.205
- Lung	24 (54.5)	16 (57.1)	5 (50)	3 (50)	0.726
- Renal	35 (79.5)	23 (82.1)	7 (70)	5 (83.3)	0.411
- Anti-MPO / PR3	35 (79.5) / 6 (13.6)	23 (82.1) / 4 (14.3)	8 (80) / 2 (20)	4 (66.7) / 0	0.644
Proteinuria, mg/mmol	160 (43–650)	160 (43–650)	150 (48–240)	115 (60–170)	0.782
Type of AAV, n (%)					
- MPA	14 (31.8)	10 (35.7)	2 (20)	2 (33.3)	0.452
- GPA	16 (36.3)	11 (39.3)	4 (40)	1 (16.7)	1
- EGPA	2 (4.5)	0	1 (10)	1 (16.7)	0.263
- RLV	12 (27.3)	7 (25)	3 (30)	2 (33.3)	1
Other autoimmune diseases, n (%)	8 (18.2)	5 (17.9)	1 (10)	2 (33.3)	1
Deaths, n (%)	7 (15.9)	3 (10.7)	2 (20)	2 (33.3)	0.592

SjS: Sjögren syndrome; MSGB: Minor salivary gland biopsy; AAV: ANCA-associated vasculitis; ENT: Ear-nose-throat; MPA: Micropolyangiitis; GPA: Granulomatosis with polyangiitis; EGPA: Eosinophilic granulomatosis with polyangiitis; RLV: Renal-limited vasculitis.

\* Comparisons are made between anti-SSA+ and anti-SSA- patients.

### 3.3.2. SS features

Concerning SS features, 35/44 (79.5%) patients complained of xerophthalmia and/or xerostomia, only 4/44 (9.1%) exhibited salivary gland swelling, with 27/30 (90%) and 4/8 (50%) respectively showing abnormal Schirmer test and abnormal unstimulated salivary flow. Extraglandular manifestations were mainly represented by arthritis (16 patients, 36.4%), Raynaud phenomenon (11 patients, 25%), and interstitial lung disease (5 patients, 11.4%). One patient presented with lymphoma during clinical history. Biology revealed positive rheumatoid factor in 17/27 patients (63%), and 4 positive cryoglobulinemia among the 17 patients tested (23.5%). Twenty-eight patients on 38 (73.7%) tested displayed anti-SSA/SSB positivity.

### 3.3.3. AAV features

At the time of AAV diagnosis, patients presented predominantly with renal involvement, (35 patients, 79.5%), fever (18 patients, 40.9%), and ear-nose-throat symptoms (10 patients, 22.7%). Notably, 13 patients (29.5%) presented with either peripheral neuropathy or central nervous system implication. Immunofluorescence staining was available for 27 patients, 22 with perinuclear staining (pANCA) and 5 with cytoplasmic staining (cANCA); 35 patients had anti-MPO antibodies, 4 had anti-PR3 antibodies, and 2 patients had both antibodies. The remaining three patients were diagnosed with AAV based on histology. Eighteen patients were diagnosed with granulomatous vasculitis (16 patients with GPA and two patients with EGPA), and 26 patients with non-granulomatous vasculitis (14 patients with MPA and 12 patients with renal-limited vasculitis (RLV)). Of note, among patients diagnosed with GPA, six had a limited form (37.5%), and anti-MPO were slightly more prevalent than anti-PR3 (8 and 6 patients respectively). All but one patient with RLV exhibited anti-MPO antibodies.

### 3.3.4. Renal involvement

We focused on kidney involvement, which was the main organ targeted by the overlap syndrome (35/44 patients, 79.5%). Patients with available data ( $n = 19$ ) showed a median creatinine of 210  $\mu\text{mol/L}$  [IQR: 142–295] and a median proteinuria of 160 mg/mmol [IQR: 73–256]. Thirty-three patients underwent renal biopsy, all but one showing glomerulonephritis (among which ten showing necrosis), and four biopsies (12.1%) exhibiting vasculitis. The last patient had fibrinoid necrosis in an interlobular arterial wall (Supplementary table 1, patient #19). No granuloma was noticed, and immunofluorescence always showed pauci-immune features when performed (22 patients). Alongside a typical glomerulonephritis, seven patients (21.2%) had dense patchy tubulointerstitial lymphocytic infiltrates, which could eventually lead to discuss specific SS involvement. There was no statistically significant difference between these patients and other patients.

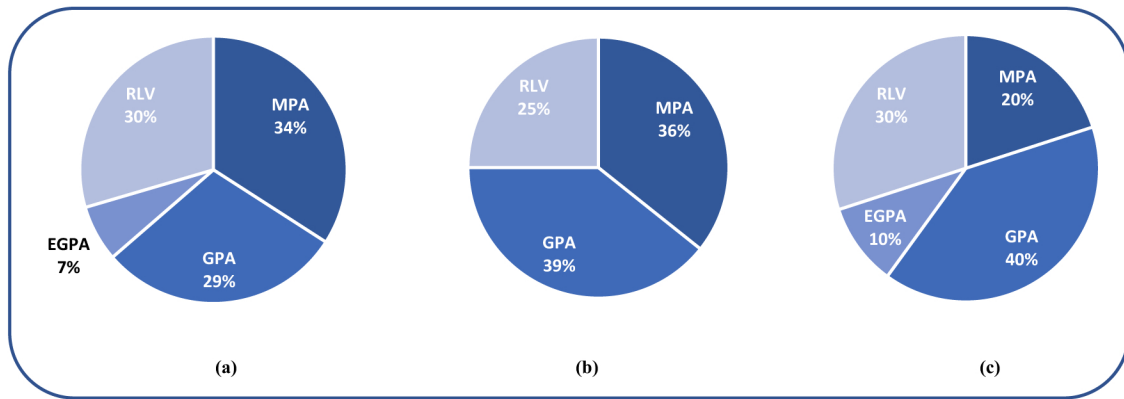
### 3.3.5. Subgroups analyses

There were no significant differences between anti-SSA positive and anti-SSA negative subgroups of SS patients, regarding clinical presentation of SS (Table 1). The SSA status did not seem to influence AAV clinical presentation, as illustrated by Fig. 2.

When comparing the features of granulomatous (GPA, EGPA) and non-granulomatous (MPA, RLV) forms of AAV (Table 2), we observed significantly more Raynaud phenomenon and associated auto-immune diseases in the group of non-granulomatous AAV (10 patients versus 1,  $p = 0.015$  and 8 patients versus 0,  $p = 0.013$ , respectively).

### 3.3.6. Chronological occurrences

All patients but one presented with SS before, or concomitantly, to the diagnosis of AAV, with a median delay of 12 months [IQR:0–60]



**Fig. 2.** Repartition of subtypes of ANCA-associated vasculitis diagnoses in Sjögren's syndrome with AAV selected from our literature review. (a) Total of patients ( $n = 44$ ); (b) Anti-SSA positive patients ( $n = 28$ ); (c) Anti-SSA negative patients ( $n = 10$ ).

MPA: Micropolyangiitis; GPA: Granulomatosis with polyangiitis; EGPA: Eosinophilic granulomatosis with polyangiitis; RLV: Renal-limited vasculitis.

**Table 2**

Demographic and diseases' characteristics of 44 patients with Sjögren's syndrome and ANCA-associated vasculitis, according to the subtypes of ANCA-associated vasculitis.

	Non granulomatous AAV		Granulomatous AAV		$p^*$
	MPA ( $n = 14$ )	RLV ( $n = 12$ )	GPA ( $n = 16$ )	EGPA ( $n = 2$ )	
Female, n (%)	11 (78.6)	10 (83.3)	14 (87.5)	2 (66.7)	1
Age SS diagnosis, years (min-max)	56.5 (20–74)	58 (47–86)	58.5 (18–76)	70	0.772
Age AAV diagnosis, years (min-max)	64 (40–77)	64.5 (48–86)	61 (22–75)	70 (39–75)	0.242
Delay, months (min-max)	35.5 (0–528)	18 (0–228)	6 (–120–108)	6 (0–12)	0.07
SjS features, n (%)					
- Sicca syndrome	12 (85.7)	9 (75)	12 (75)	3 (100)	1
- Cutaneous	2 (14.3)	1 (8.3)	1 (6.7)	0	0.633
- Lung	3 (21.4)	2 (16.7)	0	0	0.068
- Raynaud	5 (35.7)	5 (41.7)	1 (6.5)	0	0.015
- Arthralgia	5 (35.7)	6 (50)	5 (31.3)	0	0.36
- Neuropathy	0	0	2 (12.5)	0	0.147
- Lymphoma	1 (7.1)	0	0	0	1
- Positive MSGB	9 (64.3)	10 (83.3)	13 (81.3)	2 (100)	0.488
- Rheumatoid factor	5 (35.7)	2 (16.7)	9 (56.3)	1 (33.3)	0.067
- Cryoglobulinemia	1 (7.1)	0	3 (18.8)	0	0.288
Anti-SSA positivity, n (%)	10 (71.4)	7 (58.3)	11 (68.8)	0	1
AAV features, n (%)					
- Fever	6 (42.9)	1 (8.3)	11 (68.8)	0	0.032
- Arthritis	1 (7.1)	0	3 (18.8)	0	0.288
- Eye	1 (7.1)	0	1 (6.3)	0	1
- ENT	2 (14.3)	0	6 (37.5)	2 (100)	0.008
- Cutaneous	5 (35.7)	0	3 (18.8)	0	1
- Neuropathy	6 (42.9)	0	4 (25)	1	0.737
- Lung	7 (50)	0	15 (93.8)	2	8.17E-06
- Renal	14 (100)	12 (100)	9 (56.3)	0	6.85E-05
- Anti-MPO / PR3	14 / 0	Nov-00	8 / 6 (50 / 37.5)	Feb-00	0.558
Proteinuria, mg/mmol (min-max)	150 (48–197)	165 (58–650)	201.5 (43–300)	NA	0.904
Other autoimmune diseases, n (%)	5 (35.7)	3 (25)	0	0	0.013

\* Comparisons are made between granulomatous and non-granulomatous AAV.

between both diagnoses. Twenty-seven patients (61.4%) were diagnosed with AAV at least one year after SS diagnosis (Fig. 3A). Interestingly, the repartition of AAV subtypes according to the diagnostic delay with SS (Fig. 3A) suggests a dichotomy between granulomatous and non-granulomatous forms of AAV. Indeed, although not reaching statistical significance ( $p = 0.07$ ), there is a trend for a longer period between SS and non-granulomatous AAV (MPA, RLV) compared to granulomatous AAV (GPA, EGPA).

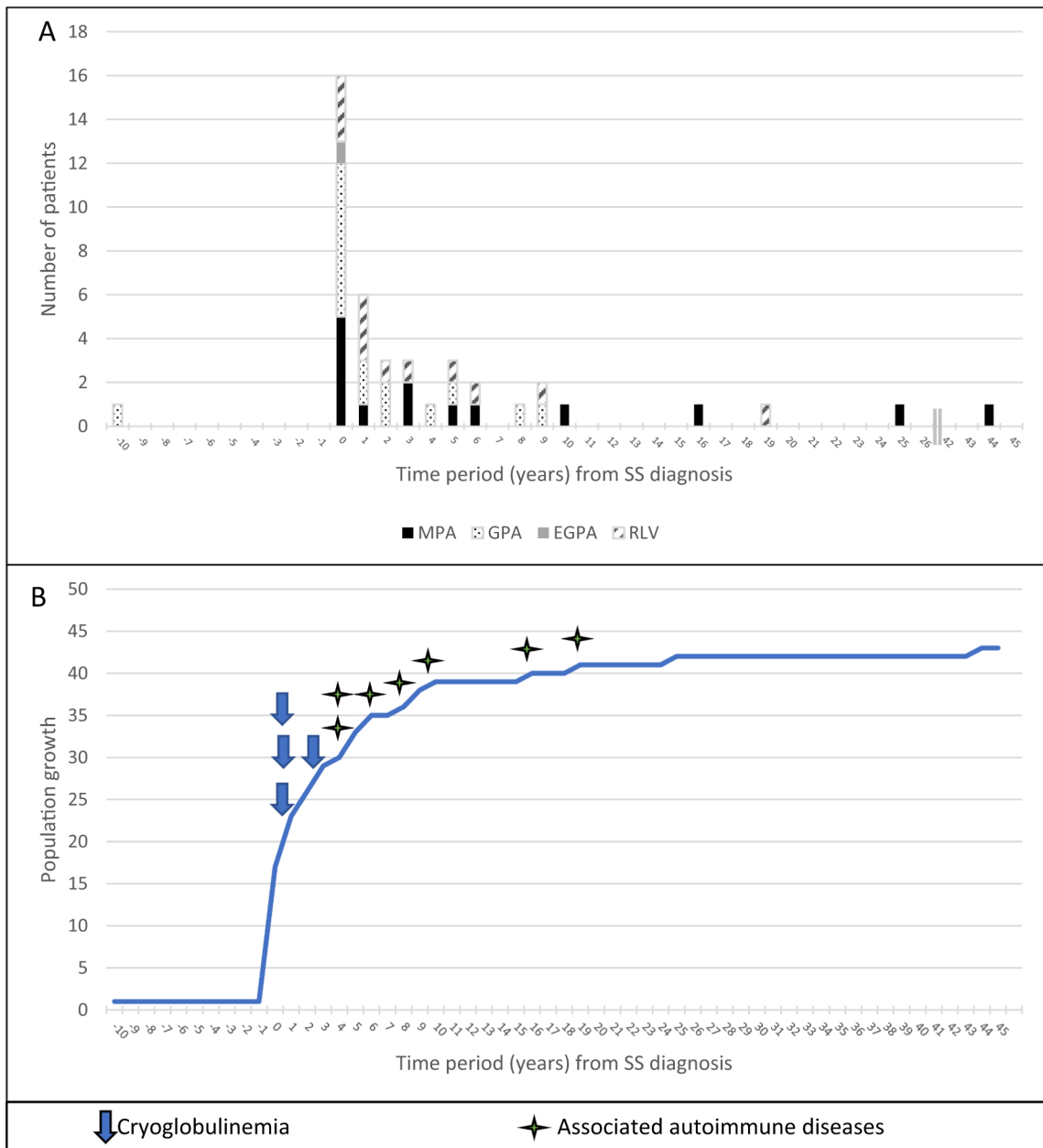
Patients with a diagnosis of cryoglobulinemia (as a complication of SS) were all diagnosed with AAV within the first 2 years after SS diagnosis. Otherwise, 8 patients presented another autoimmune disease (different from AAV or SS) (supplementary table 1), and exhibited a longer delay between AAV and SS diagnoses (Fig. 3B).

#### 4. Discussion

In the present study, we provide the largest descriptive study on the association between SS and AAV, which includes 40 published cases and 4 additional cases from our center. Compared to previous reports, this work allows us to clarify and discuss the clinical and immunological patterns of this overlap, which is a rare entity raising pathophysiological questions.

#### 5. Challenging diagnoses

The diagnosis of SS may be complex and differential diagnoses may be investigated when the patients exhibit sicca syndrome. Herein, we decided to apply the ACR/EULAR 2017 classification criteria to be more



**Fig. 3.** A) Temporal relationship between ANCA-associated vasculitis onset and Sjögren's syndrome according to ANCA-vasculitis subtype (T<sub>0</sub>: time when Sjögren's syndrome was diagnosed); B) Distribution of ANCA-associated vasculitis diagnosis according to the time period with Sjögren's syndrome diagnosis, and representation of cryoglobulinemia or an associated autoimmune disease occurrence during clinical course.

specific in SS diagnosis. As indicated in our flow chart (Fig. 1), we excluded patients with sicca syndrome for whom diagnosis remained uncertain. The ACR/EULAR classification criteria revised in 2017 exclude several conditions, including granuloma. This raises a specific comment concerning MSGB, since GPA can present with exocrine gland granulomatous involvement, resulting in sicca syndrome, with sometimes confusing presentations [18,23]. Indeed, if the cross-section passes on the rim of granuloma, one can observe only lymphocytic infiltrates and miss out the other components of granuloma. The MSGB may misconclude in the presence of a focus (of SS), instead of granuloma. In our work, we only identified 4 GPA with positive MSGB and negative anti-SSA status (Supplementary table 1, patients #2, #38, # 42 and #43). We consider that these cases can be classified as SS, because of specific SS symptoms: Raynaud phenomenon and small fiber neuropathy (patient #42), keratoconjunctivitis and sensitive neuropathy (patient #43), abnormal sialoscintigraphy (patient #2). The diagnosis of patient

#38 could be more questionable, as she presented only sicca syndrome and arthralgia, two years before AAV diagnosis. Anyway, such an uncertainty regarding MSGB pathological findings would only concern a minority of patients. Another comment about pathological findings concerns a potential overlap with IgG4-RD, potentially mimicking Sjögren's syndrome, and potentially overlapping with AAV [4]. Thus, IgG4-RD may be misdiagnosed as SS, and the distinction between the two entities may be difficult, requiring -among others- the search for IgG4-positive lymphoplasmocytic cells within minor salivary glands. No available data in the included clinical cases could let us suspect such a diagnosis.

Sjögren's syndrome is classically divided into primary or secondary (to another connective tissue disorder (CTD)). How would be labelled Sjögren's syndrome in patients with AAV? i.e., primary, or secondary SS? The chronological sequence between the two diseases provides important information and illustrates that many patients could be considered

as primary SS, since SS occurred before AAV onset. Nevertheless, a few patients also exhibited other CTD (like mixed CTD and systemic sclerosis), making SS more difficult to be classified as primary. Generally speaking, the distinction between primary and secondary SS may be difficult to ascertain.

Thus, our work also illustrates the complexity of overlapping syndromes, as well as the shifting and unstable nature of nosology and the interplay between diseases. Interestingly, the presence of ANCA was previously reported in SS patients, showing an association with extraglandular and immunological manifestations, especially vascular involvement (cutaneous vasculitis, peripheral neuropathy, Raynaud's phenomenon...) [24]. So, one could hypothesize that some reported SS patients with cutaneous vasculitis were in fact SS-AAV.

Otherwise, it seems not excluded that SS may be under-diagnosed in patients with already-diagnosed AAV, which would explain the great predominance of AAV cases after the diagnosis of SS. So, physicians should also pay attention to some -even slight- symptoms (e.g. sicca syndrome, neurologic symptoms evocative of small fibres neuropathy, hypergammaglobulinemia, cryoglobulinemia) in the nearby months and years of AAV diagnosis, in the hypothesis of an overlapping SS.

## 6. Impact of SS-ANCA overlapping diagnoses on treatment and follow-up

Why is it critical to diagnose both diseases? First, because the treatment of each disease is different, and AAV merits quick and intense immunosuppressive strategy. Because of the chronological interplay of the 2 diseases, a comprehensive diagnostic work-up should be discussed in case of lung/renal involvement in a patient with SS in order to discard a potential overlap with AAV. Eventually, when identifying both conditions, tailored treatment strategies could be suggested (e.g. anti-CD20 treatment rather than CYC). Second, because the overlap might also impact the follow-up of the patients: AAV patients with CTD (including SS) have significantly more vasculitis relapses than patients without CTD [25]. From another side, among AAV patients with a previous history of SS, lymphoma should still be screened in the long-term follow-up of such patients, besides the classical risk of relapse associated with AAV.

## 7. SS-ANCA overlap: a specific pattern?

In the present work, the characteristics of SS-AAV patients also raise several comments. As expected with SS, we observed a female predominance of the population, which is unusual in the field of AAV. While AAV is known to affect predominantly Caucasians and Hispanics [26], patients issued from Asia were frequent in this report, which may be in line with the peculiar overlap with SS. This privileged association may be linked to variation of HLA haplotype, or mutations prone to autoimmunity like PTPN22, recently reported in a patient with both conditions [27]. Concerning clinical features, despite the low number of patients, SSA positivity does not seem associated with a specific pattern of AAV or SS. A striking finding is the high frequency of anti-MPO-ANCA, linked to the predominant presentation of non-granulomatous AAV (MPA or RLV). However, granulomatous forms of AAV (essentially GPA) also exhibit MPO-ANCA in almost half of cases. Notably, among patients diagnosed with GPA in our study, there were six patients with lung-limited disease, including two with negative ANCA screening. Such a GPA/SS association emphasizes the need to perform biopsies when a patient with SS history develops lung opacities.

The suggested dichotomy between granulomatous and non-granulomatous forms of AAV is strengthened by the chronological interplay between AAV subtypes and SS. Furthermore, the temporal relationships between SS, AAV, and the few cases of cryoglobulinemia or other associated autoimmune diseases suggest that this overlap syndrome is an evolving process, during which the clinical presentation may be enriched. However, the mechanisms underlying this process

remain to be elucidated. Interestingly, most AAV cases occur within 3 years after SS diagnosis. As mentioned above, this should prompt the clinician to pay particular attention to the enrichment of the clinical presentation (towards AAV) during SS.

Definitive conclusions from this literature review are difficult to establish, due to the small number of patients, the retrospective nature, and the wide period of inclusion, leading to heterogenous standard of diagnosis and care. Furthermore, the time of SS onset is uncertain, because first symptoms can occur long before and are frequently underreported by patients. Despite these limitations, the present work is the largest study focusing on this overlap, suggesting an interplay between both diseases modulating clinical presentation and outcome of each disease.

## 8. Conclusion

As illustrated by this literature systematic review, the association between AAV and pSS brings a high level of complexity to the clinical presentation and represents a challenging diagnosis. Striking features are the high frequency of anti-MPO ANCA and the predominance of non-granulomatous forms of AAV. This association is possibly under-recognized, because difficult to diagnose. The specific temporal relationships and clinical presentation of this overlap syndrome may be complex and should prompt the clinician to pay particular attention to the apparition of new symptoms in the context of SS or AAV.

## Data availability

The data underlying this article will be shared on reasonable request to the corresponding author.

## Funding

No specific funding was received from any bodies in the public, commercial or not-for-profit sectors to carry out the work described in this article.

## Declaration of Competing Interest

The authors declare that they have no known competing financial interests or personal relationships that could have appeared to influence the work reported in this paper.

## References

- [1] Jennette JC, Falk RJ, Bacon PA, Basu N, Cid MC, Ferrario F, et al. 2012 revised international Chapel Hill consensus conference nomenclature of Vasculitides. *Arthritis Rheum* 2013 Jan;65(1):1–11.
- [2] Lamprecht P, Kerstein A, Klapa S, Schinke S, Karsten CM, Yu X, et al. Pathogenetic and clinical aspects of anti-neutrophil cytoplasmic autoantibody-associated vasculitides. *Front Immunol* 2018 Apr;9(9):680.
- [3] Humbert S, Guilpain P, Puéchal X, Terrier B, Rivière S, Mahr A, et al. Inflammatory bowel diseases in anti-neutrophil cytoplasmic antibody-associated vasculitides: 11 retrospective cases from the French Vasculitis Study Group. *Rheumatol Oxf Engl* 2015 Nov;54(11):1970–5.
- [4] Danlos F-X, Rossi GM, Blockmans D, Emmi G, Kronbichler A, Durupt S, et al. Antineutrophil cytoplasmic antibody-associated vasculitides and IgG4-related disease: a new overlap syndrome. *Autoimmun Rev* 2017 Oct;16(10):1036–43.
- [5] Martín-Nares E, Zuñiga-Tamayo D, Hinojosa-Azaola A. Prevalence of overlap of antineutrophil cytoplasmic antibody associated vasculitis with systemic autoimmune diseases: an unrecognized example of polyautoimmunity. *Clin Rheumatol* 2019 Jan;38(1):97–106.
- [6] Guellec D, Cornec-Le Gall E, Groh M, Hachulla E, Karras A, Charles P, et al. ANCA-associated vasculitis in patients with primary Sjögren's syndrome: detailed analysis of 7 new cases and systematic literature review. *Autoimmun Rev* 2015 Aug;14(8):742–50.



- [7] Argyropoulou OD, Tzioufas AG. Common and rare forms of vasculitis associated with Sjögren's syndrome. *Curr Opin Rheumatol* 2020 Jan;32(1):21–8.
- [8] François H, Mariette X. Renal involvement in primary Sjögren syndrome. *Nat Rev Nephrol* 2016 Feb;12(2):82–93.
- [9] Brito-Zerón P, Ramos-Casals M, Bove A, Sentis J, Font J. Predicting adverse outcomes in primary Sjögren's syndrome: identification of prognostic factors. *Rheumatol Oxf Engl* 2007 Aug;46(8):1359–62.
- [10] Haas E. über die rheumatische Genese einer generalisierten Gefäß-erkrankung mit Sjögren'schem Syndrom (Dacryo-sialo-adenopathia atrophicans). *Virchows Arch Für Pathol Anat Physiol Für Klin Med* 1951 May 1;320(3):264–76.
- [11] Shiboski CH, Shiboski SC, Seror R, Criswell LA, Labetoulle M, Lietman TM, et al. 2016 ACR-EULAR classification criteria for primary Sjögren's syndrome: a consensus and data-driven methodology involving three international patient cohorts. *Arthritis Rheumatol Hoboken NJ* 2017 Jan;69(1):35–45.
- [12] Masi AT, Hunder GG, Lie JT, Michel BA, Bloch DA, Arend WP, et al. The American College of Rheumatology 1990 criteria for the classification of Churg-Strauss syndrome (allergic granulomatosis and angiitis). *Arthritis Rheum* 1990 Aug;33(8):1094–100.
- [13] Leavitt RY, Fauci AS, Bloch DA, Michel BA, Hunder GG, Arend WP, et al. The American College of Rheumatology 1990 criteria for the classification of Wegener's granulomatosis. *Arthritis Rheum* 1990 Aug;33(8):1101–7.
- [14] Guillevin L, Lhote F, Gayraud M, Cohen P, Jarrousse B, Lortholary O, et al. Prognostic factors in polyarteritis nodosa and Churg-Strauss syndrome. A prospective study in 342 patients. *Medicine (Baltimore)* 1996 Jan;vol. 75(1):17–28.
- [15] Terrier B, Charles P, Aumaitre O, Belot A, Bonnotte B, Crabol Y, et al. ANCA-associated vasculitides: Recommendations of the French Vasculitis Study Group on the use of immunosuppressants and biotherapies for remission induction and maintenance. *Presse Medicale Paris Fr* 1983 2020 Oct;49(3):104031.
- [16] Tesfaye S, Boulton AJM, Dyck PJ, Freeman R, Horowitz M, Kempler P, et al. Diabetic neuropathies: update on definitions, diagnostic criteria, estimation of severity, and treatments. *Diabetes Care* 2010 Oct;33(10):2285–93.
- [17] Camdessanché J-P, Jousserand G, Ferraud K, Vial C, Petiot P, Honnorat J, et al. The pattern and diagnostic criteria of sensory neuronopathy: a case-control study. *Brain J Neurol* 2009 Jul;132(Pt 7):1723–33.
- [18] Böttinger EP, Niles JL, Collins AB, McCluskey RT, Arnaout MA. Antineutrophil cytoplasmic autoantibody-associated vasculitis presenting as Sjögren's syndrome. *Arthritis Rheum* 1992 Nov;35(11):1373–6.
- [19] Shimizu S, Nakamura Y, Togawa Y, Kamada N, Kambe N, Matsue H. Erythema elevatum diutinum with primary Sjögren syndrome associated with IgA antineutrophil cytoplasmic antibody. *Br J Dermatol* 2008 Sep;159(3):733–5.
- [20] Bakkour W, Coulson IH, Sahasrabudhe N. Adalimumab-induced medium-sized vessel vasculitis. *Clin Exp Dermatol* 2012;37(5):562–4.
- [21] Ramos-Casals M, Nardi N, Brito-Zerón P, Aguiló S, Gil V, Delgado G, et al. Atypical autoantibodies in patients with primary Sjögren syndrome: clinical characteristics and follow-up of 82 cases. *Semin Arthritis Rheum* 2006 Apr;35(5):312–21.
- [22] Sakai TA, Fujimura T, Miyamoto M, Ono S, Yoshimoto K, Tsushima H, et al. Familial granulomatosis with polyangiitis: Two sibling cases with similar clinical features in one Japanese family. *Rheumatol U K* 2017;56 ((Sakai T.A.; Miyamoto M.; Ono S.; Yoshimoto K.; Akai Y.; Nishio K.) Department of the General Medicine, Nara, Japan):iii66.
- [23] Schmidt R, Koderisch J, Krastel H, Zeier M, Andrassy K. Sicca syndrome in patients with Wegener's granulomatosis. *Lancet*. 1989;1(8643):904–5.
- [24] Font J, Ramos-Casals M, Cervera R, Bosch X, Mirapeix E, García-Carrasco M, et al. Antineutrophil cytoplasmic antibodies in primary Sjögren's syndrome: prevalence and clinical significance. *Br J Rheumatol* 1998 Dec;37(12):1287–91.
- [25] Guibert F, Garnier A-S, Wacrenier S, Piccoli G, Djema A, Gansey R, et al. Patients with ANCA-associated glomerulonephritis and connective tissue diseases: a comparative study from the Maine-Anjou AAV registry. *J Clin Med* 2019;8(8):1218.
- [26] Pagnoux C. Updates in ANCA-associated vasculitis. *Eur J Rheumatol* 2016 Sep;3(3):122–33.
- [27] Fuchs PS, Lötscher J, Berkemeier CM, Hirsiger JR, Ghosh A, Li Q-Z, et al. Co-occurrence of ANCA-associated Vasculitis and Sjögren's syndrome in a patient with acromegaly: a case report and retrospective single-center review of acromegaly patients. *Front Immunol* 2020;11:613130.