



HAL
open science

Confirming Autochthonous Buruli Ulcer Cases in Burkina Faso, West Africa

Anselme Millogo, Dezemon Zingue, Amar Bouam, Sylvain Godreuil, Michel
Drancourt, Nassim Hammoudi

► **To cite this version:**

Anselme Millogo, Dezemon Zingue, Amar Bouam, Sylvain Godreuil, Michel Drancourt, et al.. Confirming Autochthonous Buruli Ulcer Cases in Burkina Faso, West Africa. *American Journal of Tropical Medicine and Hygiene*, 2021, 105 (3), pp.627-629. 10.4269/ajtmh.20-0895 . hal-03649265

HAL Id: hal-03649265

<https://hal.science/hal-03649265v1>

Submitted on 11 May 2022

HAL is a multi-disciplinary open access archive for the deposit and dissemination of scientific research documents, whether they are published or not. The documents may come from teaching and research institutions in France or abroad, or from public or private research centers.

L'archive ouverte pluridisciplinaire **HAL**, est destinée au dépôt et à la diffusion de documents scientifiques de niveau recherche, publiés ou non, émanant des établissements d'enseignement et de recherche français ou étrangers, des laboratoires publics ou privés.

Confirming Autochthonous Buruli Ulcer Cases in Burkina Faso, West Africa

Anselme Millogo,^{1,2,3,4} Dezemon Zingue,⁵ Amar Bouam,^{1,3} Sylvain Godreuil,² Michel Drancourt,^{1,3*} and Nassim Hammoudi^{1,3}

¹Institut Hospitalo-Universitaire Méditerranée Infection, Marseille, France; ²Université de Montpellier, Institut de Recherche pour le Développement, Maladies Infectieuses et Vecteurs: Ecologie, Génétique, Evolution et Contrôle, Montpellier, France; ³Aix-Marseille-Univ., Institut de Recherche pour le Développement, Microbes, Evolution, Phylogénie et Infection, Institut Hospitalo-Universitaire Méditerranée Infection, Marseille, France;

⁴Département des Laboratoires, Centre Hospitalier Universitaire Soro Sanou, Bobo-Dioulasso, Burkina Faso; ⁵Centre Muraz, Bobo-Dioulasso, Burkina Faso

Abstract. Environmental *Mycobacterium ulcerans* causes a disabling skin disease called Buruli ulcer. Recent studies completed the knowledge of the evolving geographic extension and epidemiology of Buruli ulcer in West Africa, where Côte d'Ivoire is reporting the highest number of cases. We report seven polymerase chain reaction-documented patients in Burkina Faso, a neighboring country of Côte d'Ivoire, where previously Buruli ulcer cases were confirmed primarily using clinical arguments.

Two West African countries that were not previously established as endemic countries for Buruli ulcer have recently reported cases of this disease, suggesting an ongoing geographic extension of the epidemic in the sub-region.^{1–4} These results prompted us to investigate Buruli ulcer in Burkina Faso by swabbing chronic wounds from patients living in rural areas.

Nurses from three primary-level health facilities working in Djikologo village (Diébougou, southwestern Burkina Faso), Bomborokuy village (Nouna, northwestern Burkina Faso), and Kotédougou village (Bobo-Dioulasso, western Burkina Faso) informed members of rural populations about our project of chronic wound sampling. Patients presented on the day of our visit, and samples were acquired based on the authorizations obtained from the regional health directors of Hauts Bassins and the district of Nouna, and a favorable opinion from the ethics committee of the National Institute of Public Health of Burkina Faso (no. 23, 2019). Figure 1 illustrates the different sites of sampling in Burkina Faso.

A total of 64 swabs (Σ -Transwab[®]; MWE, Corsham, Wiltshire, UK) were obtained from 64 patients. The ulcers were classified as WHO category II and WHO category III (Figure 2). DNA extracted using the QIAGEN Kit (Qiagen, Hilden, Germany) combined with the glass powder treatment, heating at 56°C for 2 h, sonication for 30 min, and automatic elution with an EZ1 DNA tissue kit (Qiagen) as reported previously⁵ was incorporated into three real-time quantitative polymerase chain reactions targeting *Mycobacterium ulcerans* insertion sequences IS2404, IS2606 and the *KR-B* gene as described by Fyfe.⁶ These manipulations were carried out at the Marseille Institut Hospitalier Universitaire (Marseille, France) in the presence of negative controls (Supplemental Table 1). Sixteen (16 of 64) swabs collected from 4 women and 12 men (75% of whom were between the ages of 15 and 50 years) tested positive for at least two *M. ulcerans* markers, in the presence of negative controls (Figure 3, Supplemental Table 1). Eight of these 16 patients (50%) remembered that the ulcer appeared after skin swelling, whereas 20 of 48 patients (41.6%) tested negative for *M. ulcerans*. One patient lived in southwest Burkina Faso, two in the northwest, and 13 in the west—all rural areas characterized by irrigated perimeters and dams.⁷ Six

patients (37.5%) were farmers and seven patients had visited relatives or farms in Côte d'Ivoire, two in Ghana, whereas seven other patients confirmed they had never left Burkina Faso (Figure 3). The laboratory-confirmed results were reported to the major nurses in the affiliated primary health-care centers.

Burkina Faso is bordered by Buruli ulcer-endemic Côte d'Ivoire, Ghana, Togo, and Bénin, yet this West African country was not confirmed as a Buruli ulcer country. The patients we report from Burkina Faso have poor access to health services, and the majority are referred to traditional medicine. In fact, a skin ulcer investigation in Burkina Faso concluded there were six cases of Buruli ulcer in 1998, yet the causative *Mycobacterium* was not identified conclusively.⁸ These six cases lived in southern Burkina Faso, which is characterized by irrigation and intermittent rivers, whereas some of these patients had stayed in Côte d'Ivoire.⁸ Furthermore, seven suspected cases reported around the Bagré and Kompienga irrigated perimeters, in southeast Burkina Faso were not confirmed microbiologically after swabs had been tested in Benin.⁹

We confirmed the occurrence of Buruli ulcer in Burkina Faso by molecular documentation of *M. ulcerans* in 16 patients in the presence of negative controls (Supplemental Table 1). Although Buruli ulcer has not been previously integrated specifically into the national health public plans in Burkina Faso, its detection is not surprising. Indeed, recent studies reported a geographic extension and modification of the epidemiology of Buruli ulcer in West Africa.^{1,2,4,10} In addition, we previously reported skin infection by *M. ulcerans* in asymptomatic rural people in the very same region where cases of Buruli ulcer were documented in our current study.¹¹ Of note, our study confirms the detection of *M. ulcerans* in symptomatic patients with chronic large ulcers in the lower and upper limbs (WHO categories II and III). Although these findings cannot be generalized to the larger population, they have established molecular evidence of *M. ulcerans* infection in seven rural autochthonous Burkinabè patients.

In some rural populations in Burkina Faso, as reported previously in Ghana, Buruli ulcer is believed to be the result of a bad spell or a curse and is not perceived as an infectious disease,^{12,13} resulting in the fact that affected people rely on traditional medicine as their first therapeutic option.¹³ The 16 patients we report have never benefited from a laboratory examination and most have been treated with medicinal plants.

*Address correspondence to Michel Drancourt, Aix-Marseille-Univ., IRD, MEPHI, IHU Méditerranée Infection, Marseille, France. E-mail: michel.drancourt@univ-amu.fr

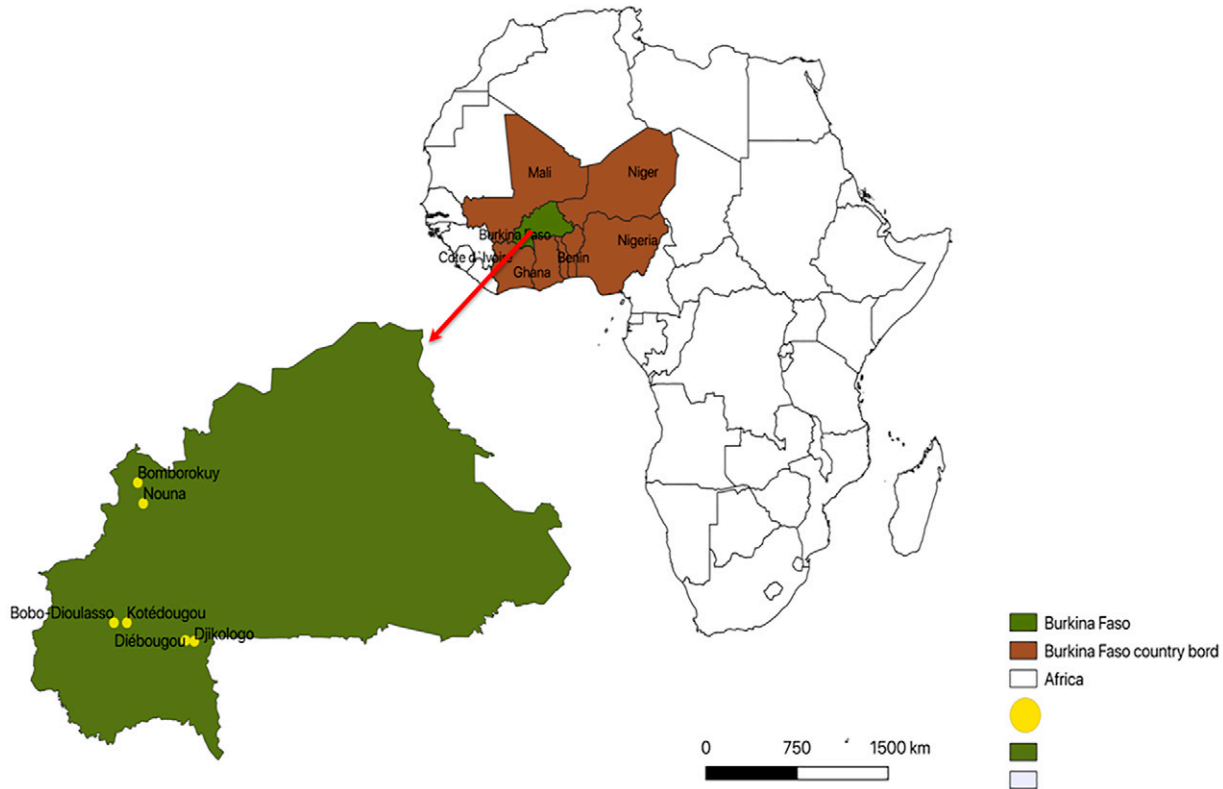


FIGURE 1. Map of Africa focusing on the West African countries. In particular, Burkina Faso is where sampling sites were located. This figure appears in color at www.ajtmh.org.

Our data, as well as the data published recently in Senegal and Mali,¹⁰ alerts us to a possible geographic extension of Buruli ulcer in West Africa. The presence of *Mycobacterium ulcerans*, confirmed by specific, molecular quantitative polymerase chain reaction in patients living in Burkina Faso, contributes to clarifying the epidemiology of this disease and allows for adequate patient care.

Received July 23, 2020. Accepted for publication April 16, 2021.

Published online August 2, 2021.

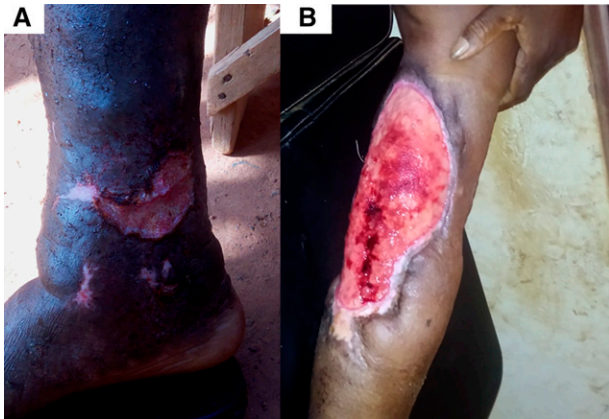

FIGURE 2. Photos of two skin ulcers from two patients. (A) Photo of patient's right leg skin ulcer P50 at the time of swab sampling in August 2018. (B) Photo of patient's left leg skin ulcer P31 at the time of swab sampling in August 2018. This figure appears in color at www.ajtmh.org.

Note: Supplemental table appears at www.ajtmh.org.

Financial support: This work was supported by the French government under the Investissements d'Avenir (Investments for the Future) Program managed by the Agence Nationale de la Recherche (Méditerranée Infection 10-IAHU-03) and by Région Le Sud (Provence Alpes Côte d'Azur) and European funding (FEDER BIOTK).

Authors' addresses: Anselme Millogo, IHU Méditerranée Infection, Marseille, France, Université de Montpellier, IRD, MIVEGEC, Montpellier, France, Aix-Marseille-Univ., IRD, MEPHI, IHU Méditerranée Infection, Marseille, France, and Département des Laboratoires, Centre Hospitalier Universitaire Sourou Sanou, Bobo-Dioulasso, Burkina Faso, E-mail: fortius2000@yahoo.fr. Dezemon Zingue, Centre Muraz, Bobo-Dioulasso, Burkina Faso, E-mail: zinguedezezon@yahoo.fr. Amar Bouam, Michel Drancourt, and Nassim Hammoudi, IHU Méditerranée Infection, Marseille, France, and Aix-Marseille-Univ., IRD, MEPHI, IHU Méditerranée Infection, Marseille, France, E-mails: amarbouam@yahoo.fr, michel.drancourt@univ-amu.fr, and nassimveto15@live.fr. Sylvain Godreuil, Université de Montpellier, IRD, MIVEGEC, Montpellier, France, E-mail: s-godreuil@chu-montpellier.fr.

REFERENCES

- Ezzedine K, Pistone T, Guir V, Malvy D, 2010. Painful Buruli ulcer in a Malian visitor to France. *Acta Dermatol Venereol* 90: 424.
- Bessis D, Kempf M, Marsollier L, 2015. *Mycobacterium ulcerans* disease (Buruli ulcer) in Mali: a new potential African endemic country. *Acta Dermatol Venereol* 95: 489–490.
- Dupechez L, Carvalho P, Hebert V, Marsollier L, Eveillard M, Marion E, Kempf M, 2019. Senegal, a new potential endemic country for Buruli ulcer? *Int J Infect Dis* 89: 128–130.
- Turner GA et al., 2019. Confirmed case of Buruli ulcer, Senegal, 2018. *Emerg Infect Dis* 25: 600–601.

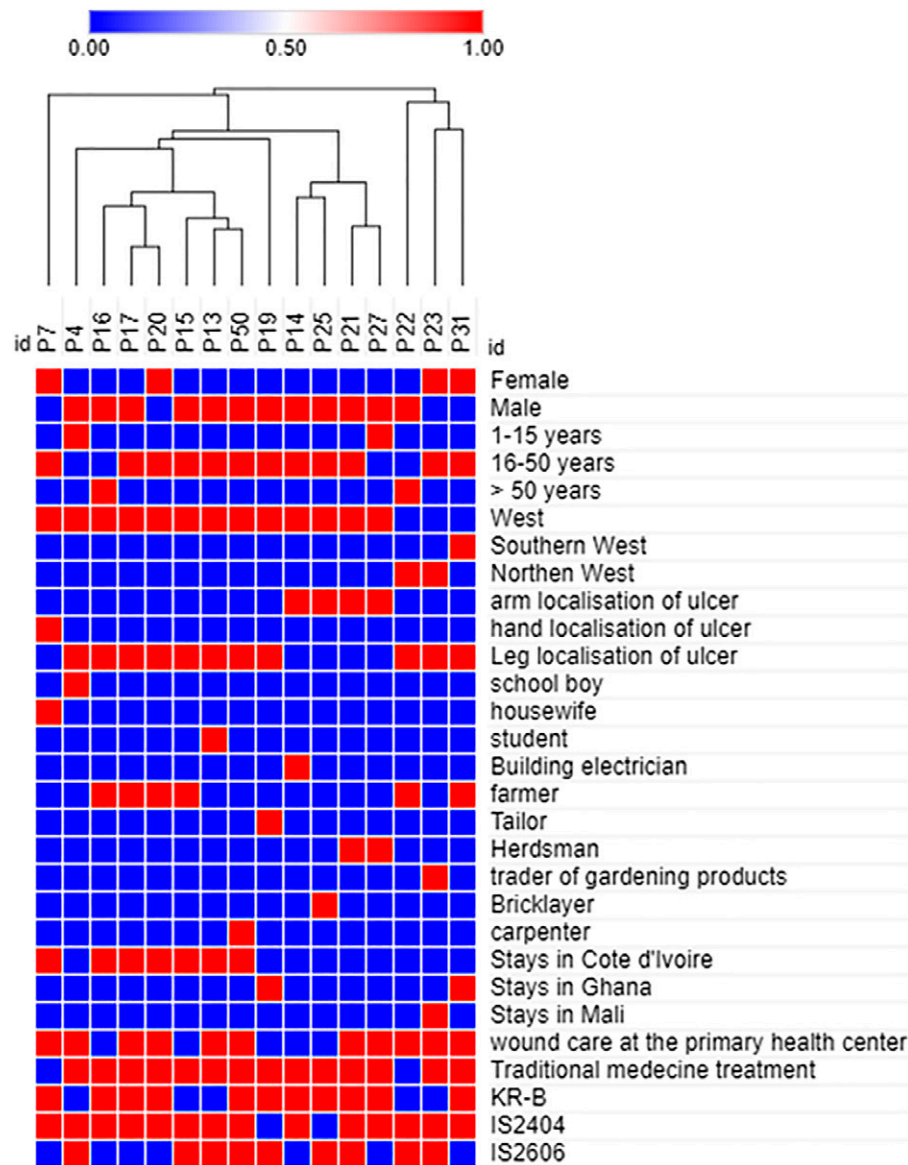


FIGURE 3. Map and hierarchical clustering showing the information for 16 patients (age, location, localization of lesions) and polymerase chain reaction detection results of *M. ulcerans* using the web-based tool Morpheus (<https://software.broadinstitute.org/morpheus/>). Red = positive/yes; blue = negative/no; P = patient. This figure appears in color at www.ajtmh.org.

- Millogo A, Loukil A, Fellag M, Diallo B, Ouedraogo AS, Godreuil S, Drancourt M, 2020. Fluorescent hybridization of *Mycobacterium leprae* in skin samples collected in Burkina Faso. *J Clin Microbiol* 58: e02130-19.
- Fyfe JAM et al., 2007. Development and application of two multiplex real-time PCR assays for the detection of *Mycobacterium ulcerans* in clinical and environmental samples. *Appl Environ Microbiol* 73: 4733-4740.
- Food and Agriculture Organization, 2015. *AQUASTAT Profil de Pays: Burkina Faso*. Rome, Italy: Food and Agriculture Organization, 2.
- Ouoba K et al., 1998. Les ulcères de Buruli au Burkina Faso: à propos de 6 observations. *Tunis Med* 76: 46-50.
- Zeba SB et al., 2018. Résultats de l'évaluation intégrée de la situation de la lèpre, de l'ulcère de Buruli et du pian autour des périmètres irrigués de Bagré et Kompienga au Burkina Faso. *Ann Dermatol Venerol* 145: S246.
- Sears AV, Hay RJ, 2015. Commentary: Buruli ulcer: a rapidly changing scene. *Acta Dermatol Venerol* 95: 387-388.
- Hammoudi N et al., 2019. Investigation of skin microbiota reveals *Mycobacterium ulcerans-Aspergillus* sp. trans-kingdom communication. *BioRxiv*. Available at: <https://doi.org/10.1101/869636>.
- Ackumey MM, Gyapong M, Pappoe M, Kwakye-Maclean C, Weiss MG, 2012. Illness meanings and experiences for pre-ulcer and ulcer conditions of Buruli ulcer in the Ga-West and Ga-South municipalities of Ghana. *BMC Public Health* 12: 264.
- Abel AA, Lucien AD, Konan DO, 2016. Itinéraires thérapeutiques pluriels et recours tardif des malades de l'ulcère de Buruli dans les centres de Prise en Charge dans le district Sanitaire de Yamoussoukro (Côte d'Ivoire). *ESJ* 12: 264-279.