



HAL
open science

Reader performances in breast lesion characterization via DBT: One or two views and which view?

Antonia Boisselier, Caroline Mandoul, Benjamin Monsonis, Jessica Delebecq,
Ingrid Millet, Emma Pages, Patrice Taourel

► **To cite this version:**

Antonia Boisselier, Caroline Mandoul, Benjamin Monsonis, Jessica Delebecq, Ingrid Millet, et al..
Reader performances in breast lesion characterization via DBT: One or two views and which view?.
European Journal of Radiology, 2021, 142, pp.109880. 10.1016/j.ejrad.2021.109880 . hal-03648582

HAL Id: hal-03648582

<https://hal.science/hal-03648582>

Submitted on 22 Aug 2023

HAL is a multi-disciplinary open access archive for the deposit and dissemination of scientific research documents, whether they are published or not. The documents may come from teaching and research institutions in France or abroad, or from public or private research centers.

L'archive ouverte pluridisciplinaire **HAL**, est destinée au dépôt et à la diffusion de documents scientifiques de niveau recherche, publiés ou non, émanant des établissements d'enseignement et de recherche français ou étrangers, des laboratoires publics ou privés.



Distributed under a Creative Commons Attribution - NonCommercial 4.0 International License

Reader Performances in Breast Lesion Characterization via DBT: One or Two Views and Which View?

Original research

Antonia Boisselier¹, Caroline Mandoul¹, Benjamin Monsonis¹, Jessica Delebecq¹, Ingrid Millet¹, Emma Pages¹, Patrice Taourel^{1*}

¹ Department of Medical Imaging, Montpellier University Hospital, Lapeyronie Hospital, 371 avenue du Doyen Gaston Giraud, 34295 Montpellier, France

Antonia Boisselier, MD
boisseliera@ipc.unicancer.fr

Caroline Mandoul, MD
c-mandoul@chu-montpellier.fr

Benjamin Monsonis, MD
b-monsonis@chu-montpellier.fr

Jessica Delebecq, MD
j-delebecq@chu-montpellier.fr

Ingrid Millet, MD, PhD
i-millet@chu-montpellier.fr

Emma Pages, MD
e-pages@chu-montpellier.fr

Patrice Taourel, MD, PhD *Corresponding author
p-taourel@chu-montpellier.fr

Funding: Hologic France

Informed Consent: Written informed consent was obtained from all patients

Ethical Approval: The local institutional review board approved this retrospective study on 138 women from the population of a previous prospective multicentric study (Registry Identifier: ID-RCB 2012-A00105-38)

Abstract

Purpose: To compare the performance in breast lesion characterization of one-view mediolateral (MLO) digital mammography plus digital breast tomosynthesis (DM-DBT) versus one-view craniocaudal (CC) DM-DBT versus two-view DM-DBT..

Materials and Methods: The institutional review board approved this retrospective study conducted on 138 women from the population of a previous prospective multicenter study, with 69 consecutive patients with benign or high-risk lesions and 69 randomized patients with breast cancer, all confirmed at pathology. Four radiologists (two senior and two junior) blinded to the clinical, mammographic and pathological data independently reviewed the MLO DM-DBT views, the CC DM-DBT views and the MLO+CC DM-DBT views using the American College of Radiology Breast Imaging-Reporting and Data System criteria for index lesion characterization. Areas under the receiver were calculated and compared for each reader and imaging protocol.

Results: No significant differences in breast cancer characterization were observed between single MLO and CC views for all the readers. The added value of a second view was statistically significant for characterization in pooled data and for junior readers but not for senior readers (p ranging from 0.15 to 0.57 depending on the view and the senior reader). Finally, in 4 breast cancer cases, lesions were only detectable on the CC DM-DBT view in two cases and on the MLO DM-DBT view in the two other cases.

Conclusion: Our results support the use of two-view DM-DBT for breast lesion characterization when the readers are inexperienced. There is no significant difference between CC and MLO views when diagnosis is performed with one view.

Keywords: mammography; tomosynthesis; craniocaudal; breast lesion characterization.

Abbreviations: MLO: mediolateral oblique; DM: digital mammography; DBT: digital breast tomosynthesis; CC: craniocaudal; BI-RADS: Breast Imaging Reporting And Data System
ROC: Receiver Operating Characteristic; ACR: American College of Radiology; US: Ultrasound.

Introduction

Digital mammography (DM) is the standard examination for breast cancer screening. However, one of its major widely acknowledged limitations is the superimposition of breast tissue, which creates anatomical noise likely to lead to false positive or false negative findings.

Digital breast tomosynthesis (DBT) is a pseudo-3D reconstruction of several low-dose 2D breast acquisitions performed within a limited angular range (15 to 60°). Through the approximation of the splitting of the breast into slices, this technique allows the separation of overlapping tissue, thereby overcoming the aforementioned limitation of DM [1, 2].

Numerous studies have confirmed that two-view DBT combined with DM [3-9] improved breast screening performance. A meta-analysis showed that the use of DBT enhanced both cancer detection rate (pooled incremental cancer detection rate of 1.6 cancers per 1000 screens) and abnormal interpretation rate (pooled absolute recall rate reduction of 2.2%) [10].

As DBT involves pseudo 3D images, a single DM-DBT view could theoretically be sufficient for screening, since it makes it possible to minimize the effect of overlapping breast tissue and to localize abnormalities by scrolling through the breast tissue. Accordingly, some authors have suggested carrying out screening through the use of a single mediolateral oblique (MLO) DBT view [11-14]. In the Malmö breast tomosynthesis screening trial, which used a wide-angle DBT, a single MLO DBT view led to a better cancer detection rate than two DM views, even though the recall rate increased significantly [11-14]. An enriched retrospective reader study showed that the detection performance of a single MLO DBT view was not statistically inferior to that of two-view DM or two-view DM-DBT [12]. In another enriched study, it was demonstrated that, compared with two DM views, the combination of a single MLO DBT view with one CC DM view improved breast lesion detection and characterization [13]. Despite these encouraging results with one-view DBT, most prospective and retrospective DBT screening studies are based on two-view DBT, which is generally considered necessary for a complete evaluation [15]. This inconsistency could be due to the fact that most clinical studies published to date have been conducted with narrow-angle DBT systems, even though, according to DBT reconstruction theory, there is not only superior depth resolution and, accordingly, a potentially greater discrimination of lesions, but also a better contrast of subtle masses [16].

Concerning the conspicuity of breast cancer according to the number of DBT projections and the type of projection (CC versus MLO view), few data exist regarding the number of necessary DBT projections and which DBT projection would be most effective when the examination is performed with a single DM-DBT view. In an analysis of breast cancers, Rafferty et al. [17] and Beck et al. [18] reported in oral communications that the cancers were observed in only one view

in 9% and 7% of cases, respectively. Recently in the only published study comparing the conspicuity of breast cancers on CC versus MLO DBT views, the authors concluded that some cancers may only be detected on one of the two views, usually on the CC view. They considered a two-view DM-DBT study as optimal [19]. This study had however a limitation: it only included cancer cases with readers unblinded to the lesion location. To our knowledge, no published studies have as yet focused on the characterization of breast lesions according to the type (CC versus MLO) and the number (one- versus two-views) of views. Such a study should include malignant and benign lesions, with readers blinded to the lesion pathology.

We conducted a retrospective multireader study to compare the performances of three different imaging protocols (single CC DM-DBT view, single MLO DM-DBT view and MLO plus CC DM-DBT views) for breast lesion characterization.

Materials and Methods

The original dataset was prospectively acquired from a previous study, which was approved as a Health Insurance Portability and Accountability Act-compliant study. Written informed consent was obtained prior to imaging from all study participants. Hologic (Bedford, MA) provided financial support for the initial study (ClinicalTrials.gov: NCT01881880).

Patient population

A prospective multicentric research project focused on assessing the value of DBT in breast cancer diagnosis and staging was conducted between May 2012 and May 2014 among 424 women from seven different French institutions. These women were over 40 years old, with lesions categorized as Breast Imaging Reporting and Data Systems (BI-RADS) 4 or 5 lesions and no previous breast surgery history. Fifty-eight of the patients had been included in a previously published study on local tumor staging [19].

The suspected breast lesions were diagnosed on the basis of mammographic and/or DBT, ultrasound (US) or MRI findings obtained during the diagnostic or screening examinations.

Exclusion criteria were women with previous breast surgery, high-risk women included in an MRI breast cancer screening program, pregnant women and those unwilling to give consent.

Bilateral DM and DBT images were performed in both CC and MLO views. Lesions were diagnosed by pathologic assessment of image-guided biopsies. In patients with benign lesions, a follow-up of at least 1 year without progression of the lesion was included in the protocol.

We retrospectively excluded patients with incomplete data (missing DBT or DM views or lost at follow-up) and those whose data could not be anonymized upon inclusion.

Among the patients of the current study, all women with benign lesions - including high-risk or B3 lesions composed of atypical ductal hyperplasia, lobular neoplasia (including the subcategories lobular carcinoma in situ and atypical lobular hyperplasia), flat epithelial atypia, radial scar and papillary lesions, and phyllode tumor [21] - were eventually analyzed (69 patients) and 69 other patients with breast cancer were randomized in order to match the number of benign cases (**Figure 1**).

Image acquisition

DM was performed using a full-field DM unit with integrated DBT acquisition (Selenia Dimensions; Hologic, Bedford, MA). Images were acquired using bilateral two-view DM and DBT (combo mode), with a single breast compression per projection. Synthetic 2D images were not obtained.

Image analysis

All DM and DBT images were uploaded on a dedicated workstation (SecurView; Hologic, Bedford, MA). Four radiologists reviewed all DM and DBT exams: two senior radiologists with 15 years (R1) and 7 years (R2) experience in breast imaging with DBT and two junior radiologists with 1 year (R3) and 6 months (R4) experience in breast imaging with DBT.

To reduce learning bias, the readers first reviewed the MLO DM-DBT views of all the patients. They interpreted the CC DM-DBT views after an interval of at least 1 month. Finally, they read both MLO DM-DBT and CC DM-DBT views after a further interval of at least 1 month.

All readers were blinded to clinical findings, side and location of the index lesion, and to the final pathological diagnosis. At each step, they were also blinded to their prior interpretations. The order of all the examinations was randomized.

For each examination, the readers spotted the most suspicious lesion and plotted its location on a diagram corresponding to the analyzed view, specifying its side, quadrant and distance to the nipple.

The lesion was described according to the BI-RADS lexicon of the American College of Radiology (ACR) and it was classified using of the following six categories: negative findings (including BI-RADS 1 and 2), BI-RADS 3 (probably benign finding), BI-RADS 4A (low suspicious abnormality), BI-RADS 4B (medium suspicious abnormality), BI-RADS 4C (highly

suspicious abnormality) and BI-RADS 5 (highly suggestive of malignancy). Only the most suspicious finding was considered for each patient. BI-RADS 0 was not allowed.

When patients were initially included in the prospective study, breast density was subjectively assessed by a global parenchymal density evaluation and categorized as low density (corresponding to Grades A and B of the ACR BI-RADS lexicon for breast density descriptors) and high density (corresponding to Grades C and D).

Meanwhile the most suspicious mammographic abnormality was characterized as a mass, an asymmetric density, a cluster of microcalcifications or as an architectural distortion.

The data were collected and entered into a Microsoft Excel (Microsoft, Redmond, WA) spreadsheet.

Reference standard

Another radiologist correlated the readings with the pathology results and performed lesion matching between pathology reports and DM-DBT images by taking into account the lesion size and type, its location relative to the mammary zones and its depth to the nipple.

The original pathology report was relied upon for the description of the lesion as a mass, an architectural distortion, an asymmetry of density or as a cluster of microcalcifications. When non calcified lesions were associated with microcalcifications, they were categorized as the non-calcified part of the lesion.

Each reader's description of the lesion was considered accurate if it was not more than 2 cm from the location of the main lesion. If the lesion described did not correspond to this location, it was considered as missed and regarded as a negative reading.

The final histopathological diagnoses were established both on the basis of surgical findings of malignant tumors and high-risk lesions and on percutaneous biopsy findings for benign lesions, with at least 1 year of follow-up without any change in the biopsied lesion.

Statistical analysis

Comparisons were performed as follows between the different imaging protocols, for each reader and for the pooled data: CC DM-DBT versus MLO DM-DBT, CC DM-DBT versus CC+ MLO DM-DBT and MLO DM-DBT versus CC + MLO DM-DBT.

Receiver operating characteristic (ROC) curves of each of the three imaging protocols CC DM-DBT, MLO DM + DBT MLO, and CC+ MLO DM-DBT were plotted for each reader and for the pooled readers and the areas under the curve (AUC) were calculated considering the BI-RADS

classification 1 or 2, 3, 4A, 4B, 4C and 5 with the exact binomial 95% confidence intervals (95% CI). The comparison between the AUC values of each modality was carried out, reader-by-reader and for all the readers, applying the DeLong's test.

The degree of inter-observer agreement regarding the ACR classification of the lesion was assessed for each modality using the weighted Kappa coefficient with the following scale: 0.00–0.20 indicating poor agreement; 0.21–0.40, fair agreement; 0.41–0.60, moderate agreement; 0.61–0.80, substantial agreement; and 0.81–1.00, almost perfect agreement.

Statistical significance was set at $p \leq 0.05$.

Analyses were performed using SAS version 9.4 (SAS Institute, Cary, NC, USA).

Results

Descriptive results

The average age of the sampled population was 57 (in a range between 40 and 86 years old).

Breast density was rated as low (A or B) in 40.58% (56/138) and as high (C or D) in 59.42% (82/138) of cases.

The lesions were characterized as an asymmetric density in 9 cases (6.52%), as a distortion in 19 cases (13.77%), as a mass in 75 cases (54.35%) and as a cluster of microcalcifications in 29 cases (21.01%).

All examinations considered normal in DM and DBT corresponded to benign diagnosed lesions. Four of the lesions were diagnosed by MRI and two on ultrasound. Three other lesions diagnosed on ultrasound, including 2 cancers, were subtle images identified a posteriori on DM+DBT by at least one of the readers.

Pathological diagnoses were classified as malignant or benign (including high-risk) lesions. The malignant lesions corresponded in majority to invasive ductal carcinomas (52/69), but also to invasive lobular carcinomas (13/69), ductal carcinomas *in situ* (2/69) and to other malignant lesions (2/69). Among the benign lesions, the majority were benign fibro-cystic changes (38/69), but also fibroadenomas (12/69) and other benign lesions. Nine high-risk lesions were identified (**Table 1**).

Population:	138 women	Average age: 57 (range 40-86 years old)	Family history of breast cancer: 40/138 (28.99%)	Menopausal women : 87/138 (63.04%)
Benign lesions: 69 Including high- risk lesions	fibro-cystic changes: 38/69 (55.07%)	Fibroadenoma: 12/69 (17.39%)	Other benign lesions: 10/69 (14.49%) - Sclerosing adenosis 2/69 (2.9%) - Inflammatory processes +/- abscesses: 5/69 (7.25%) - Other: 3/69 (4.35%): complex cyst, cystosteatonecrosis, PASH (pseudoangiomatous stromal hyperplasia)	High-risk lesions: 9/69 (13.04%) - Radial scar: 2/69 (2.9%) -Atypical ductal hyperplasia: 3/69 (4.35%) -Metaplasia cylindrical with atypia: 3/69 (4.35%) -Atypical papilloma: 1/69 (1.45%)
Malign lesions: 69	Invasive ductal carcinoma: 52/69 (75.36%)	Invasive lobular carcinoma: 13 /69 (18.84%)	Ductal carcinoma in situ: 2/69 (2.9%)	Other: 2/69 (2.9%) (mucinous carcinoma, papilloma carcinoma)

Table 1: Population and breast lesion diagnosis

Concerning breast cancers, one cancer (1.4%) was not seen by all the readers and by the referent radiologist, regardless of the projection, because it was visible only in the breast magnetic resonance images. Four cancers (5.8%) were not seen by all readers and by the referent radiologist on one view, but they were subsequently diagnosed by the referent radiologist and by

at least one reader on the other view (two cancers on the MLO view (**Figures 2 and 3**) and two on the CC view (**Figure 4**)).

For malignant lesions, the pathologic average size was 18mm and the standard deviation was 14, 6 mm.

Comparative performance of MLO, CC and MLO plus CC views for breast lesion characterization

ROC analysis

The pooling of the curves obtained by the four readers showed no significant differences between the AUCs of the MLO view (0.779) and of the CC view (0.762) ($p = 0.34$), with a slight tendency in favor of the MLO view and with the same results for each reader (Fig. 5; Tables 4 and 5). The AUC was superior for the two views compared to each of the one-view readings (AUCs: 0.845 for two views versus 0.779 for the MLO view ($p < 0.0001$) and 0.762 for the CC view ($p < 0.0001$)).

Junior readers' characterization performances were better with two views, with an AUC significantly superior to the AUC of a single MLO or CC view ($p \leq 0.01$). Yet, statistically, senior readers performed equally well with one or two views, despite a tendency in favor of the two views (**Figure. 5, Table 2**).

	MLO DM- DBT view	CC DM- DBT view	MLO+CC DM-DBT views	MLO DM- DBT view vs CC DM-DBT view P value	MLO DM- DBT view vs MLO+CC DM-DBT views P value	CC DM-DBT view vs MLO+CC DM-DBT views P value
R1	0.83 (0.76, 0.83)	0.81 (0.74, 0.81)	0.84 (0.78, 0.84)	0.4779	0.5755	0.1547
R2	0.80 (0.73, 0.8)	0.80 (0.73, 0.8)	0.83 (0.77, 0.83)	0.998	0.3705	0.279
R3	0.75 (0.67, 0.75)	0.74 (0.66, 0.74)	0.86 (0.81, 0.86)	0.837	0.0012*	0.0005*
R4	0.75 (0.67 0.75)	0.71 (0.62, 0.71)	0.85 (0.8, 0.85)	0.2881	0.0002*	<0. 0001*
Pooled	0.78 (0.74, 0.78)	0.76 (0.72, 0.76)	0.84 (0.82, 0.85)	0.3422	<0. 0001*	<0. 0001*

Table 2: Areas under the Receiver Operating Characteristics (ROC) curves (with 95% confidence interval) for each modality and P values for the comparison of Areas Under the Curve (AUC) between the screening modalities for each reader and for the pooled readers.

***: p<0.05**

Interobserver agreement

The interobserver agreements ranged from 0.51 to 0.71. Among the 18 calculated interobserver agreements, they were moderate in 7 combinations and substantial in 11 combinations. There was substantial agreement between the senior readers (R1 and R2) and between the junior readers (R3 and R4) for all the modalities and for the two-view readings of all the combinations (Table 3).

	MLO DM-DBT view	CC DM-DBT view	MLO+CC DM-DBT views
Between juniors			
R3 vs R4	0.6061	0.6852*	0.7088*
Between seniors			
R1 vs R2	0.7027*	0.6526*	0.6863*
senior vs junior			
R1 vs R3	0.5703	0.5743	0.7092*
R1 vs R4	0.5895	0.5328	0.6966*
R2 vs R3	0.5727	0.5209	0.6335*
R2 vs R4	0.6532*	0.5123	0.6815*

0.00–0.20: poor agreement

0.21–0.40: fair agreement

0.41–0.60: moderate agreement

0.61–0.80: substantial agreement *

0.81–1.00: almost perfect agreement

Table 3: Interobserver agreement for the BI-RADS classification of breast lesions

Discussion

Our findings showed that two views enhance the reliability of the characterization of breast lesions in the pooled readings, because the junior readers performed better on the basis of two views than on one view only. Our study also revealed that the CC and MLO views reached similar performances in the characterization of breast lesions. To our knowledge, no published studies have as yet compared one-view and two-view DM-DBT in breast lesion characterization. In an enriched series with a 16% cancer prevalence rate, Rafferty et al. [22] showed that two-view DM-DBT was significantly better than the combination of two-view DM and one-view DBT. Conversely, Haq et al. concluded in an ancillary study of the TOMMY trial that one-view

DBT was sufficient to characterize an abnormality seen only on one view of the initial DM when screening women recalled for further assessment [23]. Our study was designed to assess the utility of two- versus one-view DM-DBT. Although our study focused on breast lesion characterization by DM-DBT, we did not merely include conspicuous lesions, which is consistent with clinical practice. Accordingly, our inclusion criteria were BI-RADS 4 and 5 lesions, with six lesions initially detected with US or MRI, and all malignant lesions prospectively identified with DM-DBT. An advantage of DBT is that it can enhance lesion characterization by reducing the effect of overlapping breast tissue [23]. Consequently, the characteristics of the lesions, such as the shape and margins, are more visible to the radiologist. In an observer performance study comparing DM and DBT for characterization of breast masses [24], it was both concluded that benign lesions exhibited circumscribed margins, whereas more malignant lesions appeared as spiculated masses, and that DBT improved margin characterization. Moreover, in a study including only cancer patients, cancers were more conspicuous in DBT in 30% of cases, equally conspicuous in DBT and in DM in 64% of cases and less conspicuous in DBT in 6% of cases [19]. Interestingly, in the same study when comparing breast cancer conspicuity according to the view, there was a superiority of one of the two views over the other one in nearly one third of the cases, suggesting that two-view DBT may have added value compared to one-view DBT in breast lesion characterization. We obtained similar results with higher AUCs for each reader with two-view DM-DBT compared with one-view DM-DBT. These findings were statistically significant in the pooled results and for junior readers. We hypothesized that the added value of two-view DBT for breast lesion characterization could be explained by the fact that even though DBT reduces the effect of overlapping breast tissue, it does not completely eliminate it. Moreover, this effect may vary between CC and MLO views according to the breast tissue pattern.

Interestingly, the advantage of two views for the characterization of breast abnormalities proved to be significant only for junior readers, whereas junior and senior readers performed equally well with two views. The fact that junior readers needed more information to characterize a lesion was expected. Indeed, as already reported in the literature, the added value of DBT compared with DM depended on the reader experience and was maximal in junior readers [25, 26]. Likewise, it is not surprising that junior readers obtained the same performance as senior readers. This is in agreement with the findings of a study comparing the readings performed by radiographers and radiologists: the screening units with radiographers reached the same cancer detection rate as those with radiologists. However, the recall rate was higher in the radiographer units than in the radiologist ones [27].

Contrary to the results of Korhonen et al. [19], we did not observe significant differences between MLO and CC DM-DBT views for breast lesion characterization (p ranging from 0.28 to 1 according to the reader). Our results implied that, if – as suggested by Haq et al. and Thomassin et al. [23, 25] - a radiologist opts for one-view DBT rather than two-view DM to screen breast lesions while limiting radiation exposure, either MLO or CC could be chosen. Although MLO showed a small non-significant superiority in our study, probably because MLO views cover a broader expanse of breast tissue, especially the axillary portion, this advantage could be qualified in that CC makes it easier to locate a lesion in the orthogonal plane by scrolling through the breast [28], making it easier to find the lesion on second-look US. By contrast, scrolling only provides an approximation of the lesion location in the non-orthogonal MLO view [29].

Theoretically, the choice between one and two views on DBT could depend on the type of lesion: for instance, two views should be performed for microcalcifications; if only one DBT view is performed, the choice of CC over MLO could be made according to the best 2D incidence angle to see the lesion. However, in most DBT systems, DM and DBT images are acquired simultaneously in the same compression.

In four cases, cancers were only visible on a single DM-DBT view, which could be explained by several phenomena, already described for DM. The visibility of some cancers may be better on one of the views, depending on the orientation relative to the incoming X-ray beam or on the compression of the breast [30]. There are blind areas in MLO views (inferior medial breast tissue) and CC views (upper portion of the breast or very lateral positions) [30, 31]. As the quasi-3D format of DBT reduces the confounding effect of tissue overlap, malignancy should always be a diagnostic consideration for abnormalities that are only or more visible on one-view DBT [26].

Our study had some limitations. First, synthetic 2D images were not available since the generation of such images reconstructed from DBT data has only become technically possible after completion of our data collection. These images could have allowed comparison of DBT views without DM. The fact that our study relied on the combination of DBT and DM for each projection prevented us from specifically assessing the performances of DBT alone. Second, a selection bias was likely induced by the readers being aware that there were only a few normal exams due to the inclusion criteria, while the interpretation of the DM-DBT view could have produced distorted ROC results. This bias was nevertheless equivalent for all modalities, thereby minimizing its impact on our primary outcome. Finally, our data were derived from a single DBT vendor and the DBT images were acquired with a narrow sweep angle (15°). Consequently, our results cannot be applicable to other DBT manufacturers, particularly to those that acquire

images with a wider acquisition angle, because of the impact of the angular range on the visualization of calcifications, masses, and architectural distortion [32].

In conclusion, our results support the use of two-view digital breast tomosynthesis for the characterization of breast lesions, particularly when the readers are inexperienced. Moreover, in about 5% of the cases, abnormality could only be identified on one of the two DM-DBT projections. No significant differences were observed between CC and MLO views when a single view was performed for diagnosis.

FIGURE CAPTIONS

Figure. 1- Flow chart

Figure. 2- 51-year-old menopausal woman, with a family history of breast cancer.

Right breast **A:** CC DM view; **B:** CC DBT view: visibility of a small mass with discretely irregular shape classified BI-RADS 4B (arrow); **C:** MLO DM view; **D:** MLO DBT view: the mass is difficult to individualize even when the location of the lesion (arrow) was known; it was missed by all readers on the MLO views. Diagnosis of invasive ductal carcinoma.

Figure. 3 - 48-year-old non-menopausal woman, with a family history of breast cancer.

Left breast **A:** CC DM view; **B:** CC DBT view: a mass with distortion classified BI-RADS 5 (arrow) is only visible on DBT; **C:** MLO DM view; **D:** MLO DBT view: the mass is difficult to individualize even when the location of the lesion (arrow) is known; it was missed by all the readers on MLO views. Diagnosis of invasive ductal carcinoma.

Figure. 4 - 47-year-old non-menopausal woman, with a family history of breast cancer.

Right breast **A:** MLO DM view; **B:** MLO DBT view: a mass with spiculated margins was visible on DBT and classified Bi-RADS 4C. **C:** CC view DM: the mass is not visible due to its location, too distal in the axillary tail. Diagnosis of invasive ductal carcinoma.

Figure. 5 - ROC curves for breast lesion characterization according to the BI-RADS classification for each modality, for each reader and for the pooled readers.

roc (Gold_standard – ACR_MLO): curve ROC for the MLO view

roc (Gold_standard – ACR_F): ROC curve for the CC view

roc (Gold_standard – ACR_F_MLO): ROC curve for the two views

Conflict of interest statement: none

Funding: Hologic France

Informed Consent: Written informed consent was obtained from all patients

Ethical Approval: The local institutional review board approved this retrospective study on 138 women from the population of a previous prospective multicentric study (Registry Identifier: ID-RCB 2012-A00105-38)

References:

- [1] Sechopoulos I. A review of breast tomosynthesis. Part I. The image acquisition process. *Med Phys* 2013; 40:014301
- [2] Sechopoulos I. A review of breast tomosynthesis. Part II. Image reconstruction, processing and analysis, and advanced applications. *Med Phys* 2013; 40:014302
- [3] Ciatto S, Houssami N, Bernardi D, et al. Integration of 3D digital mammography with tomosynthesis for population breast-cancer screening (STORM): a prospective comparison study. *Lancet Oncol* 2013; 14:583-589
- [4] Skaane P, Bandos AI, Gullien R, et al. Prospective trial comparing full-field digital mammography (FFDM) versus combined FFDM and tomosynthesis in a population-based screening programme using independent double reading with arbitration. *Eur Radiol* 2013; 23:2061-2071
- [5] Friedewald SM, Rafferty EA, Rose SL, et al. Breast cancer screening using tomosynthesis in combination with digital mammography. *JAMA* 2014; 311:2499-2507
- [6] Rafferty EA, Durand MA, Conant EF, et al. Breast Cancer Screening Using Tomosynthesis and Digital Mammography in Dense and Nondense Breasts. *JAMA* 2016; 315:1784-1786
- [7] Lourenco AP, Barry-Brooks M, Baird GL, Tuttle A, Mainiero MB. Changes in recall type and patient treatment following implementation of screening digital breast tomosynthesis. *Radiology* 2015; 274:337-342
- [8] McDonald ES, Oustimov A, Weinstein SP, Synnestvedt MB, Schnall M, Conant EF. Effectiveness of Digital Breast Tomosynthesis Compared With Digital Mammography: Outcomes Analysis From 3 Years of Breast Cancer Screening. *JAMA Oncol* 2016; 2:737-743
- [9] Bahl M, Mercaldo S, Vijapura CA, McCarthy AM, Lehman CD. Comparison of performance metrics with digital 2D versus tomosynthesis mammography in the diagnostic setting. *Eur Radiol* 2019; 29:477-484
- [10] Marinovich ML, Hunter KE, Macaskill P, Houssami N. Breast Cancer Screening Using Tomosynthesis or Mammography: A Meta-analysis of Cancer Detection and Recall. *J Natl Cancer Inst* 2018; 110:942-949
- [11] Lång K, Andersson I, Rosso A, Tingberg A, Timberg P, Zackrisson S. Performance of one-view breast tomosynthesis as a stand-alone breast cancer screening modality: results from the Malmö Breast Tomosynthesis Screening Trial, a population-based study. *Eur Radiol* 2016; 26:184-190
- [12] Rodriguez-Ruiz A, Gubern-Merida A, Imhof-Tas M, et al. One-view digital breast tomosynthesis as a stand-alone modality for breast cancer detection: do we need more? *Eur Radiol* 2018; 28:1938-1948
- [13] Gennaro G, Hendrick RE, Toledano A, et al. Combination of one-view digital breast tomosynthesis with one-view digital mammography versus standard two-view digital mammography: per lesion analysis. *Eur Radiol* 2013; 23:2087-2094
- [14] Zackrisson S, Lång K, Rosso A, et al. One-view breast tomosynthesis versus two-view mammography in the Malmö Breast Tomosynthesis Screening Trial (MBTST): a

- prospective, population-based, diagnostic accuracy study. *Lancet Oncol* 2018; 19:1493-1503
- [15] Chong A, Weinstein SP, McDonald ES, Conant EF. Digital Breast Tomosynthesis: Concepts and Clinical Practice. *Radiology* 2019; 292:1-14
- [16] Georgian-Smith D, Obuchowski NA, Lo JY, et al. Can Digital Breast Tomosynthesis Replace Full-Field Digital Mammography? A Multireader, Multicase Study of Wide-Angle Tomosynthesis. *American Journal of Roentgenology* 2019 212:6, 1393-1399
- [17] Rafferty EA NL, Jameson-Meehan L. Breast tomosynthesis: one view or two? . In: *Radiological Society of North America Scientific Assembly and Annual Meeting*. Chicago, 2006
- [18] Beck N BR, Durand M One-view versus two-view tomosynthesis: a comparison of breast cancer visibility in the mediolateral oblique and craniocaudal views. In: *ARRS Annual Meeting 2013*. Washington, DC, 2013
- [19] Korhonen KE, Conant EF, Cohen EA, Synnestvedt M, McDonald ES, Weinstein SP. Breast Cancer Conspicuity on Simultaneously Acquired Digital Mammographic Images versus Digital Breast Tomosynthesis Images. *Radiology* 2019; 292:69-76
- [20] Fontaine M, Tourasse C, Pages E, et al. Local Tumor Staging of Breast Cancer: Digital Mammography versus Digital Mammography Plus Tomosynthesis. *Radiology* 2019; 291:594-603
- [21] Catanzariti, F., Avendano, D., Cicero, G. et al. High-risk lesions of the breast: concurrent diagnostic tools and management recommendations. *Insights Imaging* 12, 63 (2021).
- [22] Rafferty EA, Park JM, Philpotts LE, et al. Diagnostic Accuracy and Recall Rates for Digital Mammography and Digital Mammography Combined With One-View and Two-View Tomosynthesis: Results of an Enriched Reader Study. *American Journal of Roentgenology* 2014; 202:273-281
- [23] Haq R, Lim YY, Maxwell AJ, et al. Digital breast tomosynthesis at screening assessment: are two views always necessary? *Br J Radiol* 2015; 88:20150353
- [24] Chan HP, Helvie MA, Hadjiiski L, et al. Characterization of Breast Masses in Digital Breast Tomosynthesis and Digital Mammograms: An Observer Performance Study. *Acad Radiol* 2017; 24:1372-1379
- [25] Thomassin-Naggara I, Perrot N, Dechoux S, Ribeiro C, Chopier J, de Bazelaire C. Added value of one-view breast tomosynthesis combined with digital mammography according to reader experience. *Eur J Radiol* 2014; 84:235-241
- [26] Wallis MG, Moa E, Zanca F, Leifland K, Danielsson M. Two-view and single-view tomosynthesis versus full-field digital mammography: high-resolution X-ray imaging observer study. *Radiology* 2012; 262:788-796
- [27] Euler-Chelpin MV, Lillholm M, Napolitano G, Vejborg I, Nielsen M, Lynge E. Screening mammography: benefit of double reading by breast density. *Breast Cancer Res Treat* 2018; 171:767-776
- [28] Korhonen KE, Weinstein SP, McDonald ES, Conant EF. Strategies to Increase Cancer Detection: Review of True-Positive and False-Negative Results at Digital Breast Tomosynthesis Screening. *Radiographics* 2016; 36:1954-1965
- [29] Friedewald SM, Young VA, Gupta D. Lesion localization using the scroll bar on tomosynthesis: Why doesn't it always work? *Clin Imaging* 2018; 47:57-64
- [30] Giess CS, Frost EP, Birdwell RL. Interpreting one-view mammographic findings: minimizing callbacks while maximizing cancer detection. *Radiographics* 2014; 34:928-940
- [31] Sickles EA. Practical solutions to common mammographic problems: tailoring the examination. *AJR Am J Roentgenol* 1988; 151:31-39
- [32] Winter AM, Moy L, MD, Gao Y, et al, Comparison of Narrow-angle and Wide-angle Digital Breast Tomosynthesis Systems in Clinical Practice, *Journal of Breast Imaging* 2021;3:240–255

Women over 40 years old with no previous surgery with a BIRADS 4 or 5 lesion recommended for biopsy

Included
n=424

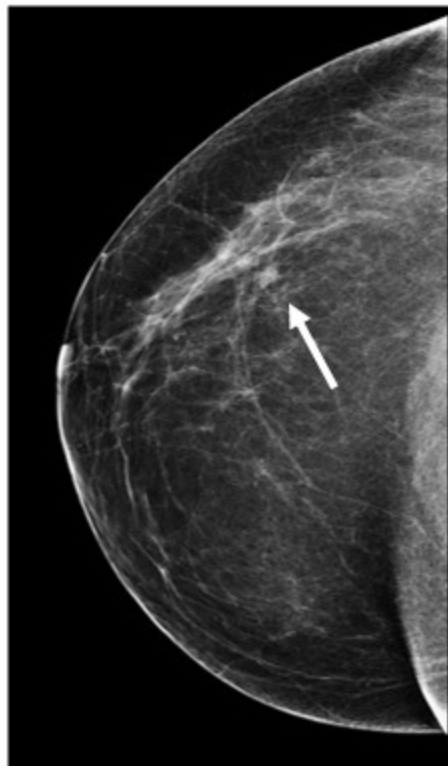
Breast cancer
lesions
n=302

Biopsy result
benign and high
risk lesions n=122

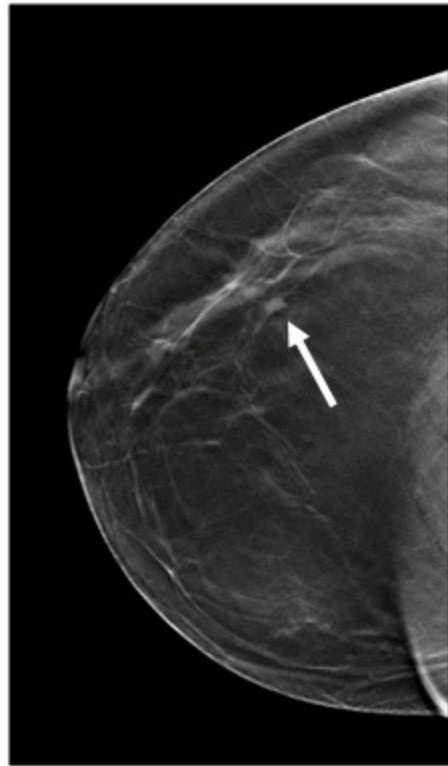
Excluded from
analysis:
Anonymization
failure: n=25 (5 high-
risk lesions)
Missing data: n=28
(5 high-risk lesions)

Breast cancer lesions
included: n=69
(Randomised)

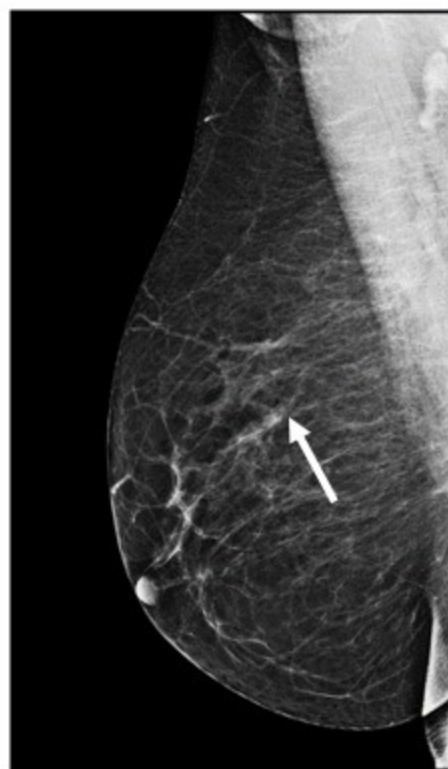Benign and high-risk
lesions included
n=69



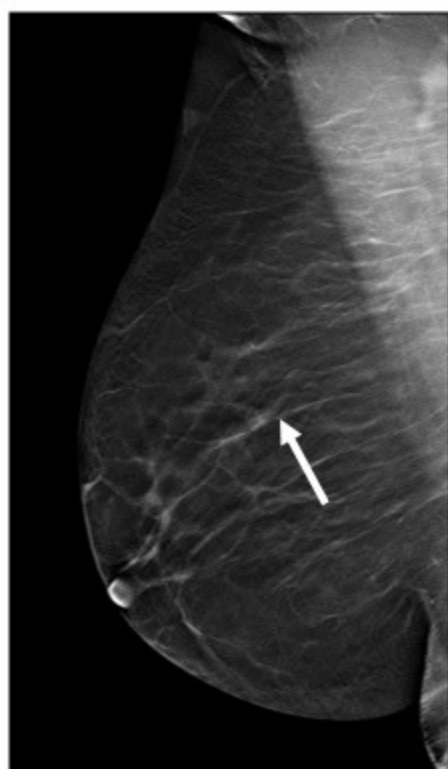
A



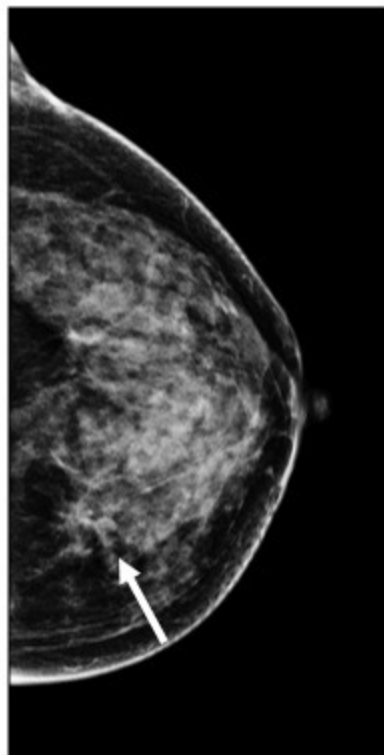
B



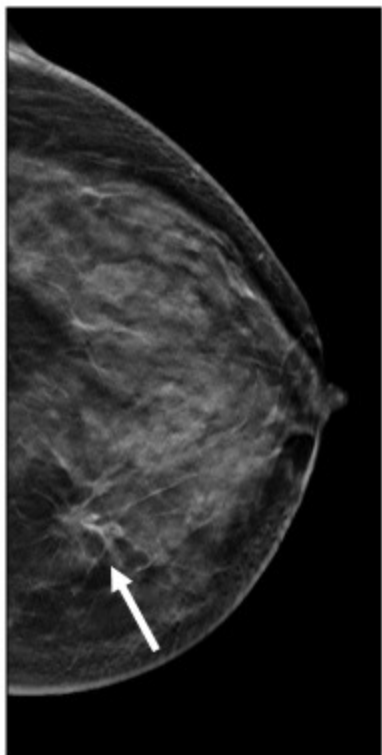
C



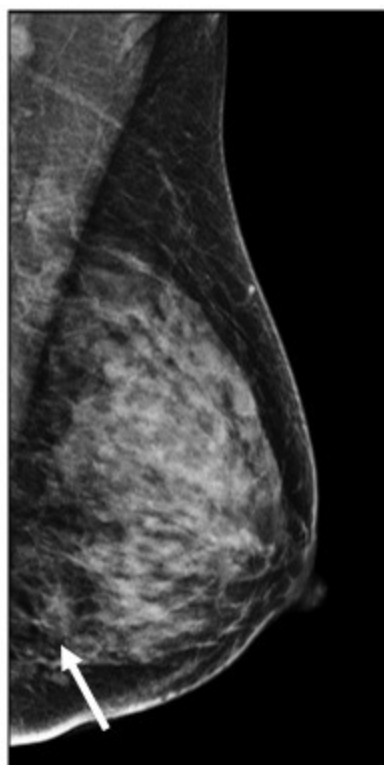
D



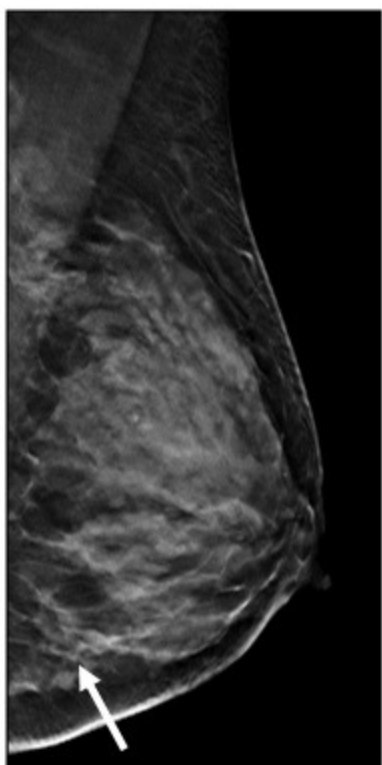
A



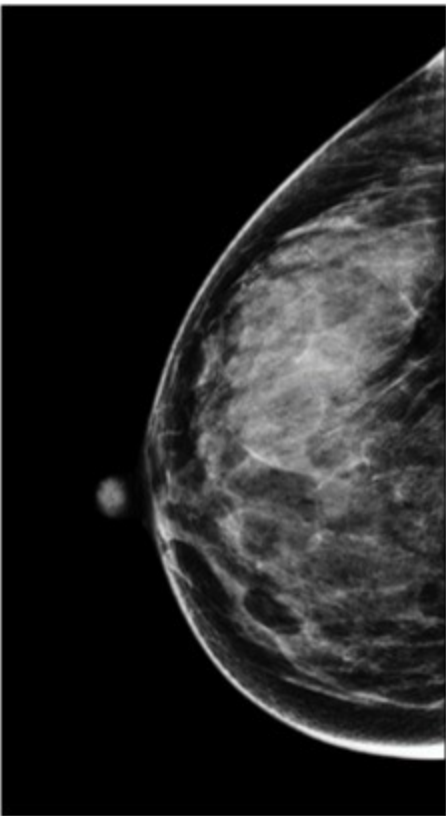
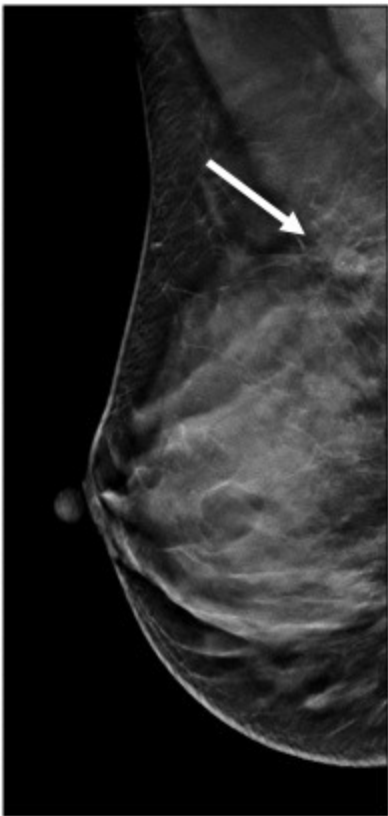
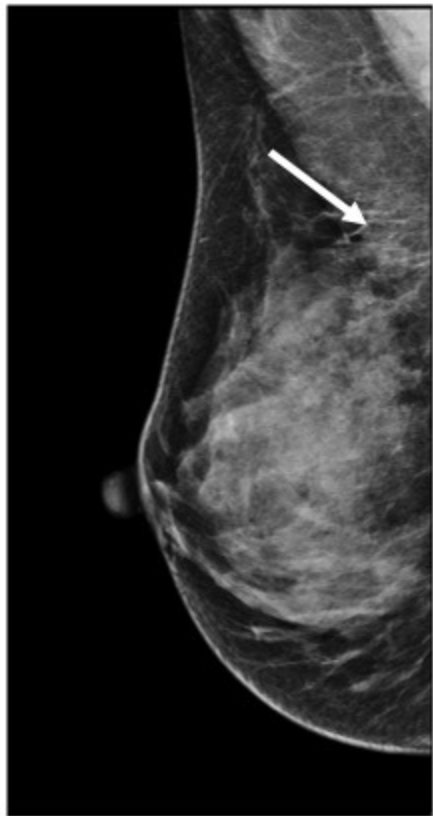
B



C



D

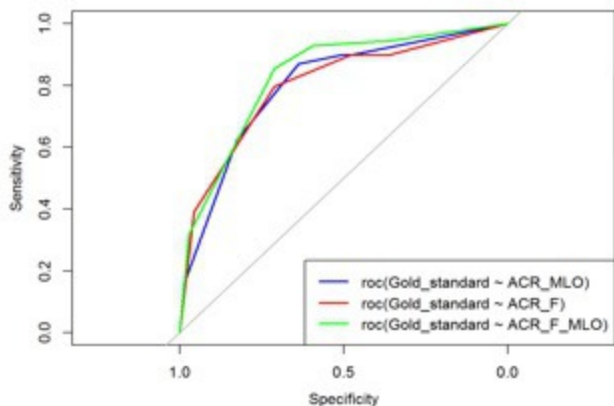


A

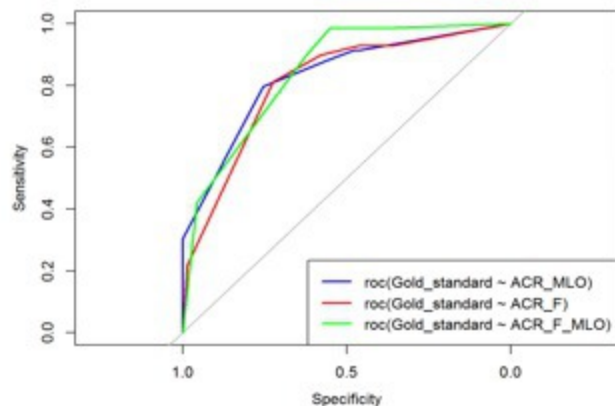
B

C

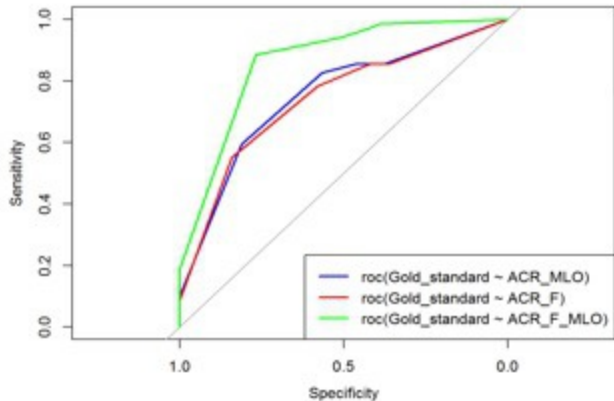
Senior's ROC curves: R1



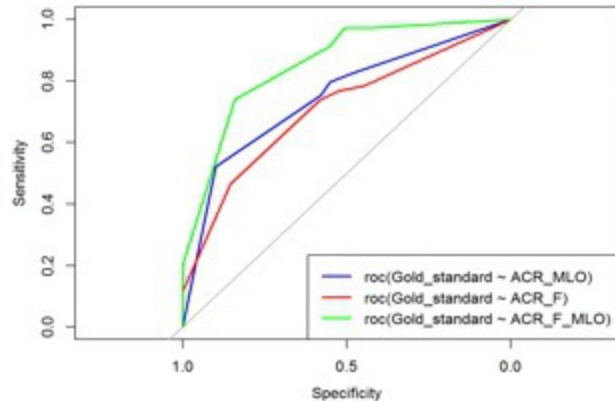
R2



Junior's ROC curves: R3



R4



Readers pooled ROC curves

